

Residual Common Duct Calculi

A. O. SINGLETON, JR., M.D. AND JAMES L. COLEMAN, M.D.

Galveston, Texas

From the Medical Branch, University of Texas, Galveston

A RESIDUAL or overlooked common duct calculi may be forcibly brought to the attention of a surgeon in two ways: a patient whose common duct has been explored, may have suggestive symptoms of common duct calculi such as jaundice, pain, chronic digestive symptoms or chills and fever, or a postoperative cholangiogram may appear to show a calculus in the duct. In an attempt to find consolation, he may first inquire how often such an error occurs; secondly, how such a situation should be managed; and, finally, how can similar difficulties be avoided in the future.

While persistent symptoms after common duct exploration may be suggestive of residual stones, other pathologic conditions, such as injury to the common duct, pancreatitis and so forth, must be ruled out. We can only be certain that calculi have been left behind by actually finding calculi on subsequent exploration. One must also differentiate between an overlooked calculus and a new calculus formed in the duct after operation. The former should be suspected when evidence of the stone appears within a few months after operation. A calculus appearing later, after an interval free from symptoms, may well have been newly formed.

Many diagnoses of overlooked biliary calculi should have been made soon after the operation by postoperative cholangiogram. Such a diagnosis should be accepted with some reservation. Although perhaps more accurate than a cholangiogram made at operation, false positives will be reported. It

is always hard to say, when a defect is seen and subsequently disappears, whether it was an artefact or a stone which had passed out of the duct.

It has been estimated that cholelithiasis is present in 10 to 30 per cent of the population. These calculi are commonly limited to the gallbladder, but in about 10 to 20 per cent of cases calculi will also be present in the common duct.^{19, 21} Crump¹⁰ found 24 per cent of autopsy cases with calculi in the gallbladder, also had common duct calculi. In 6 per cent of cases undergoing operation, calculi are found only in the common duct.³²

While common duct calculi may be found in children and young people, 52 per cent are found in the third to sixth decades.¹ Strohl²⁸ reported that 76 per cent of patients, whose common ducts were explored, were in the 5th, 6th and 7th decades. There is a rising incidence with age. Strohl reported that calculi were found in 49 per cent of common ducts explored, in a group of patients under 60 years of age, while 65 per cent of explorations for calculi were positive in individuals over 60 years.

The more common ducts that are explored the greater the number of calculi that will be found. At the Lahey Clinic, 15 per cent of the patients who had a cholecystectomy, also had a common duct exploration, and calculi in the duct were found in 8 per cent of these patients. When the incidence of exploration reached 34 per cent, calculi were found in the common duct in 18 per cent.⁹

It would appear that, with the usual indications for common duct exploration, there

* Presented before the Southern Surgical Association, Hot Springs, Virginia, December 6, 1955.




FIG. 1. Gall stone in test tube on left may be immersed in ether or chloroform for weeks without dissolution. After a few minutes' agitation as shown in tube on right no trace of stone remains except for sediment in bottom of tube.

would be a 50 per cent chance of finding calculi.^{4, 29} The accepted indications for common duct exploration vary, and this tends to affect reported statistics.

Although calculi may be missed by not exploring the common duct, it may be even more embarrassing to a surgeon to explore the common duct and overlook calculi. The reported incidence of residual common duct calculi ranges from 33 to 2 per cent of cases.^{7, 8, 13, 17, 19, 25, 26, 30} It is interesting to note that in a group of 110 cases of residual calculi reviewed by Hicken,¹⁸ the incidence of residual choledochal calculi was ten times as great in the 25 per cent of patients who had a cholecystectomy performed by an inexperienced surgeon as in the 75 per cent of patients operated upon by a properly trained individual.

That the most skilled surgeon may overlook a common duct calculus is well attested. Hicken¹⁷ found that 95 per cent of secondary operations upon the common duct have been performed for overlooked calculi. The general explanation for missed calculi is that they are caught in pockets in the duct or are located in the hepatic ducts where they cannot be reached. Norman²⁴ reported an incidence of 24 per cent cho-

dochal calculi lodged high in the hepatic ducts.

In an attempt to reduce the number of overlooked common duct calculi, cholangiograms made at the operating table have been widely used and many authors have been enthusiastic about the procedure. Mixer²² reported that calculi, which otherwise would have been missed, were found by this method in 8 per cent of cases. However, technical difficulties result in unsatisfactory cholangiograms in about five to 15 per cent of cases. Errors in interpretation have been noted by many surgeons.²⁵ Both false positive and false negative results are reported in around 15 per cent of cases.¹⁹ Douglass¹¹ reported nine false positive and three false negative findings in 108 cholangiograms taken at the operating table. Norman²⁴ reported overlooked stones in 24 out of 46 cases where the stones were located in the hepatic radicles even with operative cholangiograms. Johnston, Waugh and Good¹⁹ felt that the number of stones they overlooked following manual exploration of the common duct (eight per cent) compared favorably with the result reported by those using operative cholangiograms. They believe that operative cholangiograms should not be used as a substitute to opening and exploring the duct where indicated.

Assuming that operative cholangiograms are reported as negative, or have not been done, what course is a surgeon to follow when a postoperative cholangiogram is reported to show residual calculi? Some do nothing except to withdraw, or clamp off, the tube in the common duct and wait to see how the patient gets along. Others believe re-exploration should be carried out. Still others favor a non-operative course with an active attempt to get rid of the calculi.

Attempts to rid the common duct of calculi have followed three general plans: to flush the calculi from the ducts, to relax the sphincter of Vater, to dissolve the stone, or some combination of these meth-

ods. These methods all require an indwelling tube in the common duct. Irrigation and flushing the biliary tree by injecting solutions and giving hydrocholeretics can be effective only with smaller stones. Relaxants, such as amylnitrite, nitroglycerine or belladonna given systemically, have been recommended. Nupercaine® and Metycaine® have been reported to give good results.^{3, 14, 16} when injected into the common duct by relaxing the sphincter and making the duct insensitive to pain and allowing greater pressure to be put on the irrigating solution. In some cases we have found that the Nupercaine® solution, when mixed with bile, formed a heavy, white precipitate, not an ideal substance to inject into the biliary tract. Therefore, we recommend that the effect of mixing the irrigating solution and bile from the patient be determined before Nupercaine® solution is injected into the T tube. Papaverine appeared to act as the best dilator of the sphincter of Oddi according to the work of Eisenstein.¹²

Attempts to break up or dissolve calculi in the common duct by injecting various chemical agents have long been enthusiastically championed in the literature. While opposition to this method does not appear in print as often, it has been our experience that it is not generally used. Many surgeons have tried the procedure once or twice, only to abandon it.

If the solution, especially ether or chloroform, is injected at a rapid rate the patient will probably request that another operation be done rather than a repetition of such a painful procedure. However, if the solvent is injected drop by drop and the plunger of the syringe immediately pulled back when the patient complains of discomfort, then the procedure can be repeated many times without objection. In carrying out this form of treatment it is obvious that great patience must be exhibited. Pribam²⁶ and Best⁵ have indicated that special double lumen tubes, which direct the solvent downward in the duct and supposedly directly toward the

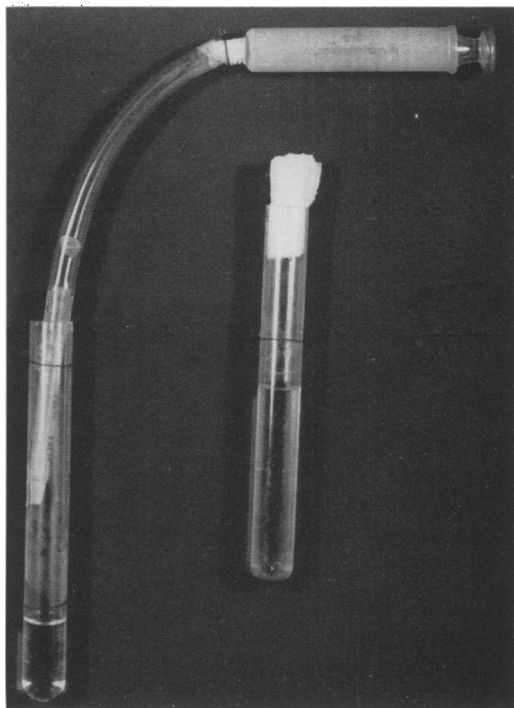


FIG. 2. On left, gall stone lodged in plastic tube was subjected to a flow of ether forced back and forth around it by means of syringe. Note medicine dropper in end of tube allows only minute fragments to drop down into the test tube. On right, test tube contains sediment which represents all that remains of the stone after 8 minutes of gentle irrigation.

calculus, are superior to the usual T tube; however, if the calculus is located in the hepatic portions of the duct, the stream will be directed away from the calculus.

Gall stones have a varied chemical composition; bilirubin, cholesterol and calcium are present in varying combinations, and pure cholesterol or bilirubin stones occur. While many agents have been tried, fat solvents in the form of ether or chloroform are the only ones that generally have been effective. Best⁵ studied the action of 113 agents in vitro on gall stones. Surface tension lowering, hydrotrophic, calcium binding and dispersing agents were non-effective, as were acids and "solution G". Certain enzymes and fatty acids were occasionally helpful but not enough to justify general use. On the other hand he found chloroform heated to 142° F. to be very effective. Ether

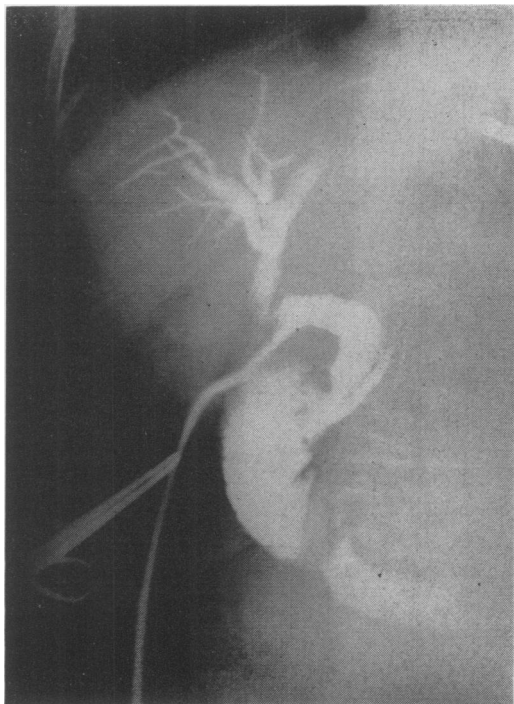


FIG. 3. Operative cholangiogram following removal of calculi from common duct. This and post-operative cholangiogram reported as negative for residual calculi. Patient explored 2 months later and gallstone removed from common duct. Pancreatic duct is also visualized.

was less effective especially with bilirubin stones. The higher boiling point of chloroform (141.8° F.) as compared with that of ether (95° F.) is supposed to offer an additional advantage. Alcohol used in combination with the above only delayed the reaction.

In carrying out *in vitro* experiments with common duct calculi, we were greatly impressed by the value of agitation of the solvent around the stone rather than allowing it to remain in passive contact with the solution. When "mixed" stones about 5 mm. in diameter were merely allowed to "sit" in ether they were found to be still intact at the end of three weeks, but with a few minutes of agitation the stone would quickly dissolve (Fig. 1). Sitting in chloroform without motion of the fluid caused some crumbling after 40 hours but complete fragmentation did not occur until three weeks. In

warmed solutions observed for shorter periods, the process did not seem to be speeded up. However, agitating the solution slightly by drawing up and expelling the solution with an eye dropper caused dissolution of the stone in an average of 15 minutes in ether and 13 minutes in chloroform. If one gently shook the container, the stone dissolved within eight minutes in ether or chloroform. Where the walls of the container were lined with cotton to prevent knocking against the sides, it took as long as 18 minutes to fragment the stone. When stones were lodged within the lumen of catheters and the solvents drawn to and fro through the tube by means of a syringe, fragmentation readily occurred (Fig. 2). Warm chloroform seemed to be the most effective agent; the stone broke up within seven minutes.

The erosive effects of running water are well known. We found that when a stream of water was allowed to trickle through the catheters, evidence of erosion and fragmentation appeared in 30 minutes with complete dissolution of the stone in 10 hours. In attempting to rid common ducts of stones by dissolution, drawing of the solvent back and forth as often as possible would seem to be of prime importance.

The question has arisen as to the toxicity of these agents, especially chloroform which has been noted for its toxic effects on the liver. Probstein and Eckert²⁷ have reported epithelial slough and a general decline in dogs receiving ether through a cholecystostomy tube. Kelly²⁰ detected an ulcer in the common duct by cholangiogram after 21 days of ether irrigation. However, most authorities have found no harmful effects. Amsterdam and Sterling's² patient instilled ether daily for 11 months into the common duct without complications. Pribam²⁶ in 51 cases and Best⁵ in 73 cases found no difficulties arising from the procedure. Whipple and Smith³³ noted that small amounts of chloroform by mouth in the dog caused depression of bile output but few evidences

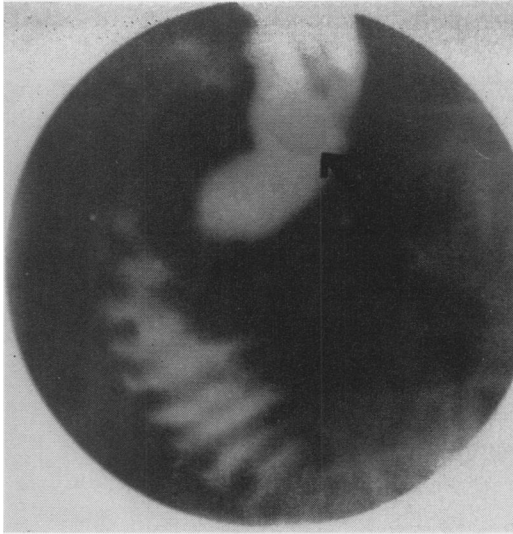


FIG. 4. Postoperative cholangiogram. Persistent shadow in common duct diagnosed as residual calculus. This subsequently disappeared after ether and Nupercaine® irrigations over a week's period. Patient had no further difficulty.

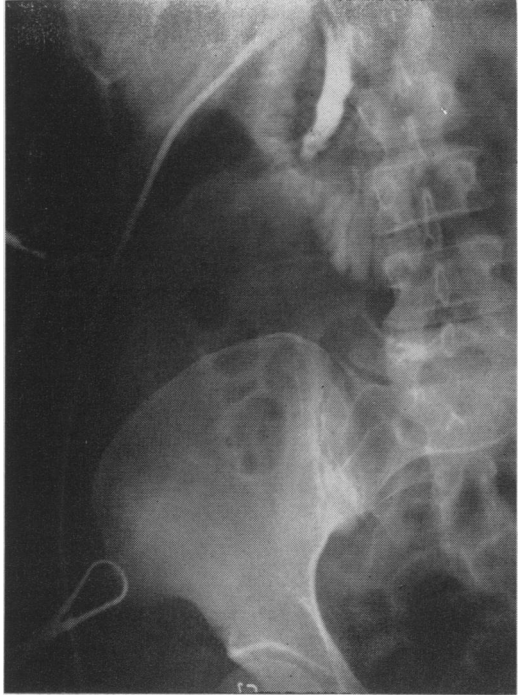

FIG. 5. Operative cholangiogram showed suspicious shadow at ampulla. This persisted in postoperative cholangiograms. After a few days of irrigation with chloroform and Nupercaine®, shadow disappeared. Patient had no further difficulty.

of toxicity by histological examination. Whipple³³ and Goldschmidt¹⁵ found that adequate protein protected the liver from damage. Narat and Cipolla²³ found no evidence of damage from chloroform, but still were hesitant about its clinical use. Best,⁶ using chloroform experimentally in dogs and man, found no harmful effects with its use as an irrigating agent and solvent.

Those who have used ether and chloroform extensively in dissolving choledochal stones have usually found them to be very effective agents though Hicken¹⁸ reported success in only one out of 15 cases. Best⁶ had only two failures in 14 cases. Three cases were cleared up using a so-called three day regimen, and nine following several such regimens. Strickler,²⁸ using ether and Nupercaine,[®] had only one failure out of four cases, carrying on as long as 14 weeks. Pribram²⁶ had no failures in 51 cases using ether.

It should be noted that a certain number of stones will spontaneously pass on into the bowel, especially if they become fragmented. Johnston and Waugh¹⁹ had to re-

operate on only six of 12 cases of residual common duct stones, though they made no attempt to dissolve or wash out the stone.

A group of 159 cases, where the common duct was explored at the original operation at the John Sealy Hospital during the last five years, was reviewed. In 34 patients the exploration was limited to an operative cholangiogram done without any specific indication. No pathologic condition was noted and the duct was not opened. No further difficulty was noted in these patients. The common duct was manually explored because of some indication in the other 125 patients. The indications for exploration (multiple in some cases) were: a history of jaundice in 116, a dilated common duct in six, small calculi in the gallbladder in one, palpable calculi in the common duct in two and a mass in the pancreas in the region of the duct in one. Forty-three of the 125 patients had calculi in the common duct. No

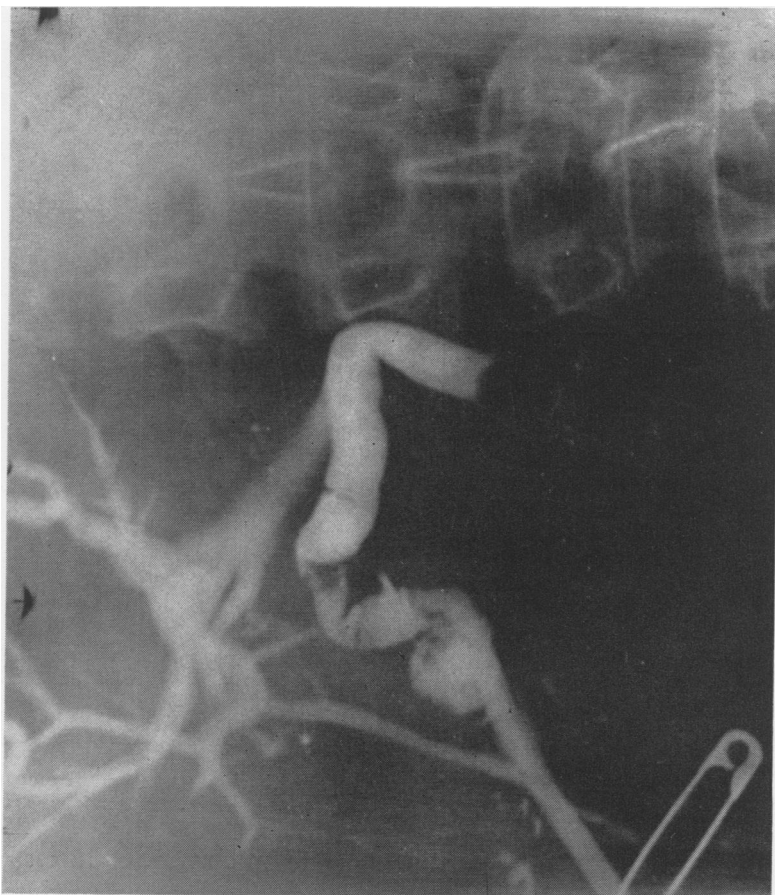


FIG. 6. Postoperative cholangiogram through tube in gallbladder shows calculus in lower end of common duct. The calculus was palpated at operation but not removed. At a subsequent operation the calculus was found to be no longer present.

obstruction could be found in 38 patients. Twenty-eight patients had carcinoma of the pancreas or biliary system. In 11 patients there was a stricture of the common duct. In the remaining five patients, the obstruction of the duct was due to miscellaneous conditions: congenital atresia in three, metastatic carcinoma pressing on the duct in one and blood clots in the duct in one.

In the 43 patients in whom common duct calculi were found, three had residual stones proven at subsequent operations. One of these had had negative operative (Fig. 3) and postoperative cholangiograms and was explored two months later on the basis of symptoms, the "T" tube having been removed. Another had not had an operative

cholangiogram and the stone was found in a postoperative cholangiogram. In the last patient no cholangiogram had been obtained but the patient was re-explored later on because of jaundice. One patient, in whom manual exploration and postoperative cholangiograms were negative had to be re-explored eight months later and a calculus was found and removed. On reviewing the old roentgen films the calculus was thought to be seen. No attempt was made to dissolve or wash out these calculi.

Thus there was an incidence of 9 per cent of overlooked common duct calculi. On the other hand, we have had a number of patients with suspicious evidence, or a definite diagnosis, of a retained common duct calcu-

lus on a postoperative cholangiogram with a persistent defect in the roentgen film. The defects disappeared within one to two week's time on subsequent films (Figs. 4 and 5). In some cases various combinations of relaxants and solvents were used; in others no active therapy was attempted. It is impossible to prove whether calculi were actually present and successfully removed or whether we were dealing with artefacts. It is possible for calculi to pass spontaneously as demonstrated by one of our cases where a calculus found at operation was not removed and was seen on subsequent cholangiograms (Fig. 6) only to find that it had been passed at a subsequent operation.

SUMMARY AND CONCLUSIONS

In summary, we have reached the following conclusions in handling postoperative common duct calculi:

1. The incidence of overlooked calculi in our institution is not as high as has frequently been reported elsewhere.

2. Those so diagnosed can be resolved without operative intervention in many cases.

3. The diagnosis of retained common duct calculus made by postoperative cholangriogram should be viewed with some suspicion and the patient treated conservatively unless the lesion persists in spite of irrigation therapy.

4. While many deny the effectiveness of relaxants and solvents, the experimental and clinical evidence is that these are very useful agents.

5. Operative cholangiograms while useful, have not in our hands shown the dramatic benefits attributed by many authors.

BIBLIOGRAPHY

- 1 Adams, R., and A. Stranahan: Cholecystitis and Cholelithiasis. *Surg., Gynec. & Obst.*, **85**: 776, 1947.
- 2 Amsterdam, G. H., and J. H. Sterling: Conservative Therapy of Residual Calculi Following Operations on the Common Bile Duct. *Ann. Surg.*, **128**: 30, 1948.
- 3 Baker, J. W., and M. W. Durham: Associated Pancreatic Necrosis and Biliary Disease. *Surgery*, **23**: 301, 1948.

- 4 Baker, J. W.: The Problem of Common Duct Exploration at the Time of Cholecystectomy. *The Western Journal of Surgery*, **59**: 495, 1951.
- 5 Best, R. R., J. A. Rasmussen and C. E. Wilson: An Evaluation of Solutions for Fragmentation and Dissolution of Gallstones and Their Effect on Liver and Ductal Tissue. *Ann. Surg.*, **138**: 570, 1953.
- 6 —————: Management of Remaining Common Duct Stones by Various Solvents and Biliary Flush Regimen. *Arch. of Surg.*, **67**: 839, 1953.
- 7 Buxton, R. B., and J. B. Burls, Jr.: Cholechochotomy. *Surg.*, **23**: 760, 1948.
- 8 Byrne, R. V.: The Problem of the Remaining Common Duct Stone. *Am. J. Surg.*, **78**: 514, 1949.
- 9 Clute, H.: Common Duct Stones. *J.A.M.A.*, **95**: 1568, 1930.
- 10 Crump, C.: Incidence of Gallstones in Gallbladder Disease. *Surg., Gynec. & Obst.*, **53**: 447, 1931.
- 11 Douglass, T. C., R. B. Lewis and W. H. Mehn: Operative Room Cholangiography; Errors in Technique and Interpretation. *Arch. Surg.*, **68**: 422, 1954.
- 12 Eisenstein, M. W.: Study on the Relief of Obstruction in the Common Bile Duct and in the Papilla of Vater. *Surg., Gynec. & Obst.*, **89**: 49, 1949.
- 13 Glenn, F.: Common Duct Exploration for Stones. *Surg., Gynec. & Obst.*, **95**: 431, 1952.
- 14 Glenn, W. R., and W. H. Hill: Common Duct Obstructions Relieved by Injections of a Topical Anaesthetic. *South. Surgeon*, **14**: 3, 1948.
- 15 Goldschmidt, S., H. M. Vars and I. S. Ravdin: The Influence of the Foodstuffs upon the Susceptibility of the Liver to Injury by Chloroform and the Probable Mechanism of Their Action. *J. Clin. Investigation*, **18**: 277, 1939.
- 16 Harris, F. J., and S. A. Marcus: Common Duct Stone Relieved by Injections of Nupercaine Solution into T-Tube. *J.A.M.A.*, **131**: 39, 1946.
- 17 Hicken, N. F., A. J. Mc Allister and E. Crowder: Technique Indications and Value of Postoperative Cholangiography. *Arch. Surg.*, **60**: 1102, 1950.
- 18 Hicken, N. F., A. J. McAllister and O. W. Call: Residual Choledochal Stones, Etiology and Complications in One Hundred Ten Cases. *Arch. Surg.*, **68**: 643, 1954.
- 19 Johnston, E. V., J. M. Waugh and C. A. Good: Residual Stones in the Common Bile Duct; the Question of Operative Cholangiograms. *Ann. Surg.*, **139**: 293, 1954.

- ²⁰ Kelly, J. F., A. J. Callaghan and S. H. Kline: Complication Arising from the Attempted Dissolution of a Common Duct Stone. *Surgery*, **36**: 294, 1954.
- ²¹ Lichtman, S. S.: *Diseases of the Liver, Gallbladder, and Bile Ducts*. p. 1226, Philadelphia, 1953, Lea and Febiger.
- ²² Mixter, C. G., L. Hermanson and A. L. Segel: Operative Cholangiography; Evaluation of 40 Cases. *Ann. Surg.*, **134**: 346, 1951.
- ²³ Narat, J. K., and A. F. Cipolla: Fragmentation and Dissolution of Gallstones by Chloroform. *Arch. Surg.*, **51**: 51, 1945.
- ²⁴ Norman, O.: Studies on Hepatic Ducts in Cholangiography. *Acta Radiol. suppl.*, **84**: 1, 1951.
- ²⁵ Payne, J. R., and C. N. Firme: The Problem of the Overlooked Common Duct Stone. *The American Surgeon*, **20**: 1171, 1954.
- ²⁶ Pribram, B. O. C.: The Method for Dissolution of Stones Remaining after Operation. *Surgery*, **22**: 806, 1947.
- ²⁷ Probst, J. G., and C. T. Eckert: The Injection of Ether into the Biliary Tract as Treatment for Choledocholithiasis. *Arch. Surg.*, **35**: 258, 1937.
- ²⁸ Strickler, J. H., J. J. Muller, C. O. Rice and J. D. Baronofsky: The Non-operative Management of Retained Postoperative Common Duct Stones. *Ann. Surg.*, **133**: 174, 1951.
- ²⁹ Strohl, E. L.: Symptoms of Common Duct Stones. *Arch. Surg.*, **64**: 788, 1952.
- ³⁰ Sullens, W. E., and G. A. Sexton: Indications for Operative Cholangiography. *Ann. Surg.*, **141**: 499, 1955.
- ³¹ Walls, W. S.: The Common Duct Stone Problem. *N. Y. State J. Med.*, **53**: 2971, 1953.
- ³² Walters, W., and A. M. Snell: *Diseases of the Gallbladder and Bile Ducts*. Philadelphia, 1940, W. B. Saunders Co.
- ³³ Whipple, G. H., and H. P. Smith: Bile Salt Metabolism. *J. Biol. Chem.*, **89**: 727, 1930.

DISCUSSION.—DR. I. S. RAVDIN, Philadelphia, Pa.: There is no problem more difficult than that of the overlooked common duct stone. I have overlooked a number of them. I have not been able to get rid of the majority of these overlooked stones by any method except by operation. I am reminded of what Dr. John B. Dever used to say in this regard; when we talked about using something to dissolve an overlooked stone—he would say—"Don't send a boy to do a man's job."

The thing that more surgeons ought to do is operative cholangiography. Perhaps it should be done on nearly every patient having a cholecystectomy. I am firmly convinced that the surgeon often cannot palpate a stone in the common duct. It always amuses me to see a surgeon put his hand in the abdomen, feel the common duct and then proclaim that no stones are present. Operative cholangiography has been suggested for many years and we, in this country, have been rather loathe to adopt it. One will find that many stones, not only in the lower reaches of the common duct but in the hepatic ducts, can be visualized by utilizing this technic.

The time to remove a common duct stone is at the original operation. Faceted stones rarely if ever form in the common bile duct; olivary stones form in the common duct. When a surgeon goes back for a second or third or even a fourth operation, as is not too unusual, and removes a faceted stone, he merely is removing something that has been overlooked by himself, or by some other surgeon at previous operations.

I was reminded in looking at the last slide shown by Dr. Kaplan, where I think he said the stone passed, that the picture is identical with that we have had in several instances in which we have not been able to find a stone. When we opened the duodenum we found the lesion which Dr. Cattell

has described, an adenoma of the papilla of Vater. It may not be possible to tell the difference between these two lesions by operative cholangiogram.

DR. H. W. MAYO, JR., Charleston, S. C.: I should like to discuss a very simple piece of experimental work which will be reported in detail elsewhere. While we were working on experimental dogs, in which obstructive jaundice had been created by ligation of the distal end of the common bile duct, one of our residents, Dr. J. D. Ashmore, conceived the idea that this was a very appropriate occasion to investigate the efficacy of cholangiographic methods, using various dilutions of various dyes, such as sodium iodide and neo-iopax. Stones of measured size and known chemical constituents were placed in the obstructed ducts and cholangiograms were carried out by a variety of roentgenogram technics. We were tremendously surprised to find that using any solution of any dye with any roentgenogram technic, stones measuring 5 to 7 mm in diameter did not show up at all. You can imagine, if these are the results in a dog with a thin abdominal wall, how they might be magnified in a very obese woman. I do not mean to indicate that operative cholangiography or postoperative cholangiography is not valuable, but I do think that negative or normal results should be regarded with some misgivings.

DR. RICHARD B. CATTELL, Boston, Mass.: I am sure we will all agree, no matter what means are used to determine the presence or absence of common duct stones at operation, that some are missed and we later must remove them. I would agree with Dr. Ravdin that faceted stones do not form in the common duct itself but represent those formed in the gallbladder; but certainly stones will reform in the common duct and that is the point I would like particularly to make now. If we have