

## Trichobezoar \*

### Report of a Case of Gastric Trichobezoar Complicated by Multiple Polyps with Malignant Degeneration of One of the Polyps

HERMAN CHARACHE, M.D., SILIK H. POLAYES, M.D., IRVING S. BEHR, M.D.,  
MARY Y. MURATA, M.D., ANDREAS D. DIMETRIADES, M.D.

*From the Service of Dr. John J. Gainey, Director of Surgery, Dr. Saul F. Livingston,  
Visiting Surgeon, Cumberland Hospital, Brooklyn, N. Y.*

TRICHOBEZOAR may be defined as a foreign body composed of hair found in the stomach, and more rarely in the intestines, of men and lower animals. The history of animal bezoars dates back to the 12th century B.C., when bezoar stones from goats' stomachs were used as remedies against poisons, pestilence and plague. The animal bezoars were so venerated that they were kept in golden caskets adorned with precious stones. The first case of human trichobezoar was reported by Baudamant<sup>1</sup> in 1779. In 1915 Matas<sup>6</sup> had collected 73 cases from the literature and added a case of his own. In 1938 DeBakey and Ochsner<sup>2</sup> found 171 cases and added another of their own. Up to this writing 35 additional cases have been reported, making a total of 207 cases. In none of these cases was the trichobezoar associated with multiple polyps of the stomach, benign or malignant.

More than 90 per cent of human trichobezoars occurred in young females who had a perverted appetite for hair swallowing, chewing on the ends of their braids or curls, and pulling their hair through their teeth. In the majority of cases the habit had persisted from early childhood. In Matas's case it had existed for 14 years. He quotes two other cases that persisted for 17 and 22 years. The youngest patient on record was two and one-half years<sup>8</sup> and the oldest 52.<sup>5</sup>

Some trichobezoars are of occupational

origin, in wool spinners, workers with human or animal hair, and brush makers. As bits of hair reach the stomach, they are caught in the mucous folds and form the "anlage" of a future trichobezoar. As additional hair is swallowed, it attaches itself to the primary nucleus, forming a hair ball. Eventually the hair ball fills the entire stomach, forming a perfect hair cast of the stomach similar to a plaster of Paris cast.

Some of the hair may pass on through the duodenum and be excreted in the stool, while other may form a trichobezoar in the small intestines and result in intestinal obstruction. There is only one case reported where the trichobezoar extended into the esophagus (Matas). The same author reports a case of trichobezoar associated with hookworm disease, and quotes two similar cases from the literature. Peak<sup>7</sup> reports a similar case in which in addition to a trichobezoar and hookworm disease, the patient also had a penetrating gastric ulcer. Seven cases of perforated gastric ulcer secondary to trichobezoar were reported. In our own case the trichobezoar was associated with multiple gastric polyps and malignant degeneration of one of the polyps.

One of the largest trichobezoars reported weighed six and one-half pounds<sup>4</sup> immediately after its removal but it weighed much less after desiccation. In the case reported by de Hauteville,<sup>3</sup> the trichobezoar weighed six pounds, but 19 days later, after

\* Submitted for publication September 10, 1956.

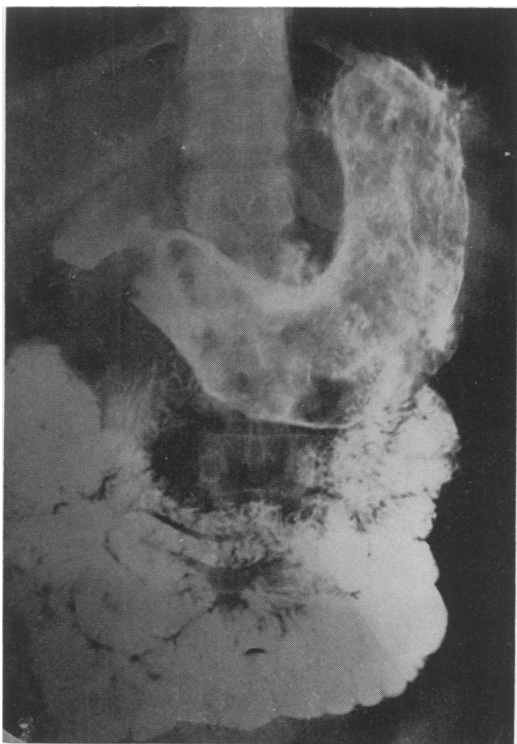


FIG. 1. X-ray of trichobezoar before operation.

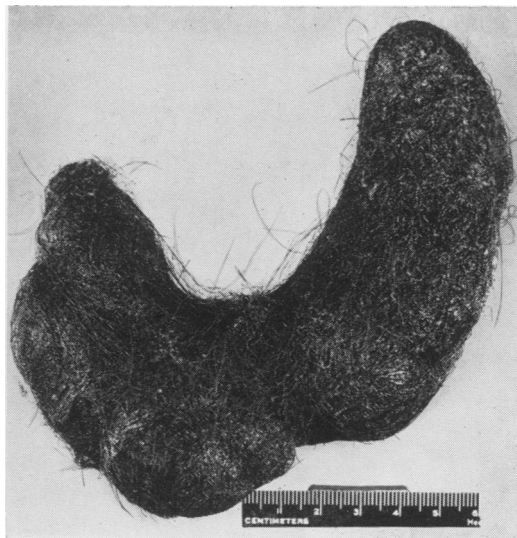


FIG. 2. Trichobezoar removed from the stomach at operation and composed of coils of hair and mucoid matter forming a cast of the lumen of the stomach.

the specimen had dried, it weighed only two and one-half pounds.

Immediately after operation the surface of the trichobezoar is covered with a slimy mucoid substance. Its interior is made up of hair intermingled with particles of all kinds of food, especially undigested fat, emitting a foul odor resulting from long-standing fermentation and decomposition. This foul odor may be present for a long time; in the case reported by DeBakey and Ochsner it had diminished very little three years after operation.

The color of the trichobezoar varies from green to black or brown, regardless of the color of the patient's hair. This may be the result of the chemical action of the gastric juice.

The clinical diagnosis of trichobezoar is very seldom entertained in a differential diagnosis of a "questionable gastric tumor." The subject is not even mentioned in most textbooks, but is scattered in the form of

single case reports in different journals. Matas states in his very informative paper, "The mere presentation and exhibition of these cases (trichobezoar) in medical societies is profitable, as the description of an actual occurrence and the exhibition of such a striking specimen will be of benefit in reminding a puzzled diagnostician of one of the possibilities he might have overlooked in the analysis of a doubtful and problematic case." He further reports that of 47 cases that came to operation in only ten was the correct diagnosis made. As DeBakey and Ochsner point out in their equally informative paper on bezoars, "If for no other reason than as a reminder their occasional presentation is thoroughly justified. Once the condition is suspected, the establishment of a correct diagnosis should be relatively simple."

To establish a correct preoperative diagnosis, the following factors should be considered. The patients are young females who may have a history of hair-swallowing. They are frail, anemic, undernourished, with a foul breath, alternate diarrhea and constipation. They may complain of a dull

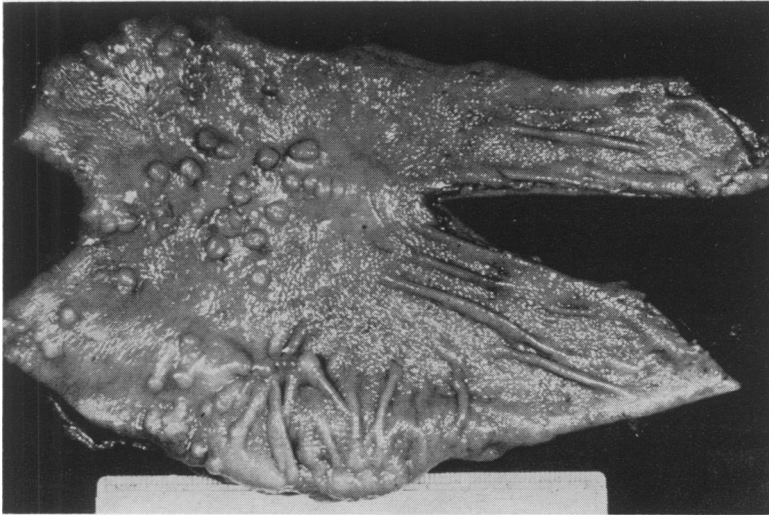


FIG. 3. Stomach opened, showing multiple polyps in the distal half, mainly along the lesser curvature. The mucosa elsewhere is hypertrophic and the wall thickened. One of these polyps shows an incipient malignant change. (See Fig. 4.)

epigastric pain and occasional nausea and vomiting. Examination will reveal a palpable epigastric tumor freely movable and not tender on palpation. "The greater curvature of the stomach may be palpable during peristalsis when the trichobezoar is gripped by the muscular contraction and is not palpable when the stomach is relaxed and does not grip the foreign body" (Matas). In addition the laboratory work will reveal a slight secondary anemia and a mild leucocytosis. Gastric lavage may disclose hair from the trichobezoar; so will stool examination or the vomitus, if present. A gastro-intestinal x-ray series will reveal an atonic stomach, marked pylorospasm, mottled appearance, some residue after six and 24 hours, a mass in the stomach, and the "Magenblase" will be entirely absent. If there is still doubt, gastroscopic examination will complete the diagnosis.

The treatment of choice in trichobezoar is exploratory laparotomy and gastrotomy. An incision is made along the anterior surface of the stomach long enough to enable the surgeon to remove easily the trichobezoar without contaminating the peritoneal cavity with the drippings of the

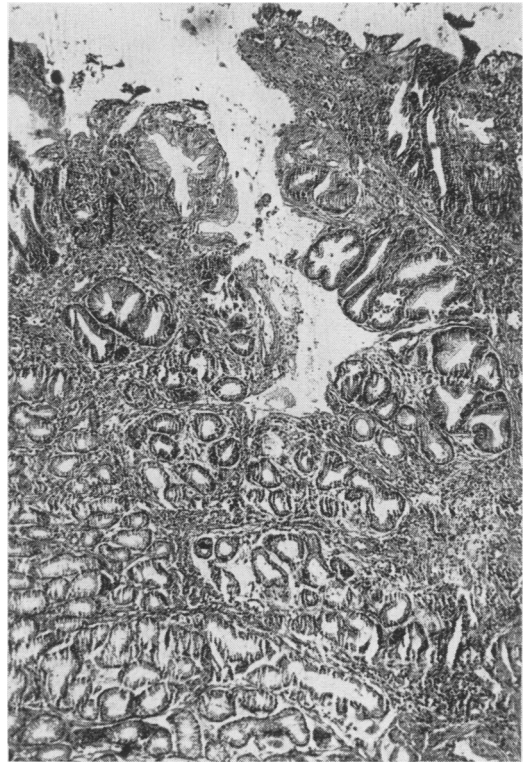


FIG. 4. Low power magnification (50 $\times$ ) of one of the gastric polyps (see Fig. 3), showing the adenomatous change in the mucosal glands. Arrow points to an area in which there is evidence of incipient malignant transformation of the glandular epithelium. (See Fig. 5.)

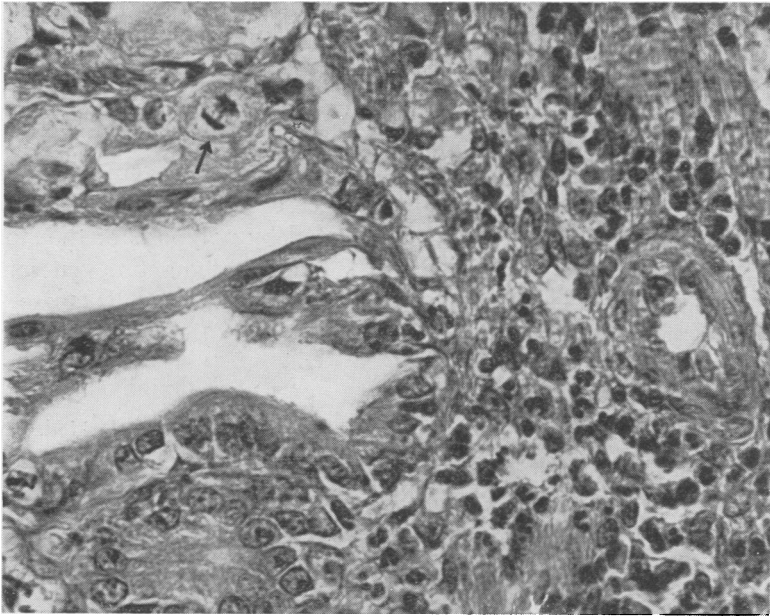


FIG. 5. High power magnification of area shown by arrow in Figure 4. Note the cellular atypism and invasion of stroma by the malignant epithelium including mitotic figures (arrow).

putrid material that continuously bathes the trichobezoar. Should the trichobezoar be complicated by ulceration or neoplastic disease requiring more extensive surgical removal, it may be necessary to postpone such procedure for a future date. This will enable the surgeon to rid the stomach of the putrid material that may contain virulent pathogenic organisms which, according to DeBakey and Ochsner, account for the death of the five patients with perforated trichobezoar ulcers.

The prognosis of uncomplicated trichobezoar is very favorable, provided treatment is instituted without delay. Immediate laparotomy, when a diagnosis of trichobezoar is made or suspected or misdiagnosed as a "tumor," will save many lives.

#### CASE REPORT

J. A., a 25-year-old Porto Rican woman, was admitted to the Surgical Service of Cumberland Hospital on March 22nd, 1956, complaining of epigastric pain most marked after meals and at night. She also complained of a mass "moving around in her stomach."

Her past history was uneventful. In July 1955 during her routine post partum examination a left upper quadrant mass was discovered. A gastro-intestinal x-ray series revealed a "gastric tumor." She refused advice to be admitted to the Surgical Service for operation until abdominal pain developed.

Physical examination revealed a well-developed, slender, anemic young woman, weighing 129 pounds, not acutely ill, temperature 36.9° C. (98.4° F.), pulse 80, respiration 22, blood pressure 140/80. The abdomen was soft and flat. A hard, non-tender, freely movable mass was felt in the left upper quadrant, extending subcostally along the sweep of the stomach toward the umbilicus. The greater curvature of the stomach appeared "scalloped" or "nodular." The rest of the physical examination was essentially negative.

The red blood cell count was 3,740,000 with hemoglobin of 52 per cent. The white blood cell count was 17,200 with 80 per cent segmental cells and 20 per cent lymphocytes, a marked anisocytosis and hypochromia. The blood chemical determinations and urinary examination were within normal limits. So was the x-ray of the chest with the exception of a slight cardiac enlargement. A repeat gastro-intestinal series was suggestive of a foreign body or a malignant tumor of the stomach. Roentgenological bone survey was reported negative for pathologic change. Gastric analysis and stool examination were not diagnostic.

On March 27th, 1956 the patient was explored. An anterior gastrotomy was performed. The findings were a trichobezoar and multiple gastric polyps. After removing the gastric trichobezoar, one of the polyps was excised for histologic study. The stomach and abdomen were closed in the usual manner. The patient made an uneventful recovery.

The pathologic report of the trichobezoar was as follows: "A club-shaped mass of coiled black hair about 18 cm. in length by 8 cm. in width weighing 220 Gm. The coils are adherent to each other by a grey mucoid material." The excised polyp showed incipient malignant degeneration.

On April 10th, 1956 the patient was again taken to the operating room and a subtotal gastrectomy was performed. The pathologic report was as follows: "Stomach measures 16 × 6 cm. The surface is congested. The wall is 1 cm. in thickness. The mucosa is hypertrophic with scattered multiple grey, firm polyps. The largest is 1 cm. in greatest diameter located in the distal two-thirds of the stomach and many at the lesser curvature. Diagnosis: Polyposis of the stomach, chronic hypertrophic gastritis." The remaining polyps did not show any evidence of malignancy.

The patient made an uneventful recovery and was discharged to the clinic on April 19th, 1956. She has never admitted to being a hair swallower, even when confronted with the evidence of the trichobezoar.

#### SUMMARY

Trichobezoars are foreign bodies composed of hair found in the stomach and to a lesser degree in the small intestines of young females who have a perverted ap-

petite for hair swallowing. Up to the present writing 207 cases of trichobezoar have been reported in the literature. Complications of trichobezoars are ulceration and perforation of the stomach, and intestinal obstruction. Diagnostic aids are described. A case of trichobezoar is reported complicated by polyposis of the stomach with incipient malignant degeneration of one of the polyps. A similar case has not been reported in the literature.

#### BIBLIOGRAPHY

1. Baudamant, M.: *J. de Med. Paris*, 2: 931, 1779 (quoted by Matas).
2. DeBakey, M. and A. Ochsner: *Bezoars and Concretions, a Comprehensive Review of the Literature with an Analysis of 303 Collected Cases and a Presentation of 8 Additional Cases. Surgery*, 4: 934-963, Dec. 1938, 5: 132-160, Jan. 1939.
3. D'Hauteville, M.: *J. Gener. Med. et Chir. et Pharm., Paris*, 48: 147, 1813 (quoted by DeBakey and Ochsner).
4. Davies, I. J.: *Hair Balls or Hair Casts of Stomach and Gastrointestinal Tract. Lancet*, 2: 791, 1921.
5. Koogken: *Ztschr. f. Klin. Med.*, 14: 203, 1888 (quoted by Matas).
6. Matas, R.: *Hair Balls or Hair Casts of the Stomach and Gastrointestinal Tract. Surg., Gyn. and Obst.*, 21: 594-608, Nov. 1915.
7. Peak, J. D.: *Trichobezoar or Hair Ball. Radiology*, 51: 816 1948.
8. Schwartzman, J. J.: *Trichobezoar. J. Pediatrics*, 11: 691, June 1937.