

# Temporary Extracorporeal Circulation in the Surgical Treatment of Cardiac and Aortic Disease

## Report of 98 Cases \*

DENTON A. COOLEY, M.D., BENJAMIN A. BELMONTE, M.D.,  
MICHAEL E. DE BAKEY, M.D., JOSEPH R. LATSON, M.D.\*\*

THE NEED for an efficient and safe method of extracorporeal circulation in surgical treatment of intracardiac lesions has long been recognized, but not until 1939 when Gibbon<sup>9</sup> reported his pioneering experimental efforts with total body perfusion during cardiopulmonary bypass did the procedure appear to be within reach for clinical application. Since that time extensive experimental investigations concerned mostly with development of an ideal pump oxygenator and control of certain complicating factors inherent in artificial perfusion of blood have been undertaken in many instances with discouraging results. Indeed, until very recently it appeared that widespread clinical use of extracorporeal circulation would not be possible for some years. Thus, the recent demonstration of the efficacy of artificial extracorporeal circulation has finally broken a major barrier in the further advancement of cardiovascular surgery and stands as a brilliant achievement in surgical progress. The fact that Gibbon,<sup>10</sup> in 1953, accomplished the first successful clinical application of this method in repairing an atrial septal defect in an 18-year-old girl was indeed an appropriate

event and provides high tribute to his thoughtful investigations and devoted efforts in this field of endeavor.

A highly significant contribution in this field was made by Lillehei and his associates<sup>13</sup> who in 1954 employed controlled cross circulation between a living human donor and patient to perform open cardiotomy. Using this method 32 patients were operated upon for congenital cardiac lesions including ventricular septal defects and tetralogy of Fallot with impressive results, thus providing a powerful stimulus in this field. In general the reduced flow principle based upon the so-called "azygos-factor" as first described by Andreason and Watson<sup>2,3</sup> was used by Lillehei with a flow rate through the donor circuit of 25–35 cubic centimeters per kilogram body weight of the patient, which is much less than normal calculated basal cardiac output of 100–160 cubic centimeters per minute. Kirklin and his associates<sup>11,12</sup> meanwhile constructed a Gibbon-type vertical screen oxygenator and pump system and subsequently demonstrated in a series of 40 operations that open cardiotomy could be accomplished in man using a completely mechanical extracorporeal circuit. Moreover, by this method, flow rates approximating normal resting cardiac output could be maintained eliminating the need for a donor to provide oxygenated blood and thus maintaining the patient in a normal physiologic state for prolonged periods. Although it may appear that use of a pump oxygenator which provides large flow rate is preferable to a low flow system, from a practical stand-

---

\* Presented before the Southern Surgical Association, Boca Raton, Florida, December 4–6, 1956.

\*\* From the Cora and Webb Mading Department of Surgery, Baylor University College of Medicine, Houston, Texas, and the Surgical Services of the Texas Children's, Methodist, Jefferson Davis, and Veterans Administration Hospitals, Houston, Texas.

Aided by a grant from the Houston Heart Association.

point it has been established by clinical experience that lower rates of flow can be maintained more simply and with less complicated and cumbersome equipment and with approximately equal safety for the patient. Moreover, lower rates of flow have the advantage of minimizing the risk of air embolism and hemolysis and of permitting low systemic pressures during cardiotomy thus reducing blood loss from the cardiotomy and the need for blood replacement.

In 1955, DeWall and Lillehei<sup>8</sup> developed a simple expendable artificial oxygenator for cardiopulmonary bypass based upon the bubble diffusion principle for maximum mixing of oxygen with blood. When this oxygenator was incorporated in the circuit, originally employed by Lillehei for cardiac bypass, the biologic donor oxygenator was no longer needed and the major objections to their original method of controlled cross circulation was eliminated. Using this relatively simple oxygenator with low flow rates between 35 and 50 cubic centimeters per kilogram body weight per minute, open cardiac surgery at last became clinically practical.

This report is concerned with our own experience with use of temporary extracorporeal circulation in 98 cases of cardiovascular disease during the past 11 months. Temporary controlled extracorporeal circulation of two types has been used, one being total cardiopulmonary bypass and the other simple unilateral bypass shunting blood from venous to venous or arterial to arterial regions. The choice of method employed in the individual case depended upon the location and nature of the lesion.

#### CARDIOPULMONARY BYPASS

*Method.* Cardiopulmonary bypass provided the means of operating upon the heart or upon the great cardiac vessels diverting the blood stream through the pump oxygenator system to maintain a constant perfusion of the body and at the same time permit operation inside of the heart in a

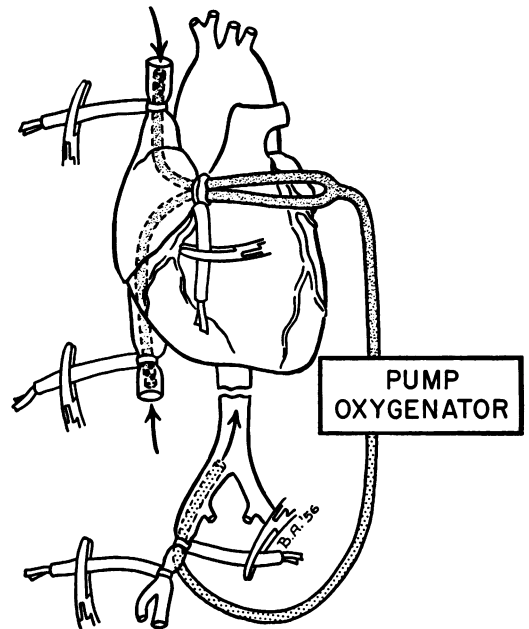


FIG. 1. Diagram showing method of total cardiopulmonary bypass. Venous blood was withdrawn through cannulas in the superior and inferior vena cavae, passed through the pump oxygenator, and the oxygenated blood was returned to the abdominal aorta through a femoral arterial catheter.

relatively bloodless operative field (Fig. 1). In all cases vascular cannulations in the patient were done using plastic catheters or tubing. Venous outflow from the superior and inferior vena cavae was obtained by cannulation with plastic tubing of appropriate size through the tip of the right auricular appendage. Tapes were passed about the vena cavae to be tightened around the cannulae for complete inflow occlusion. In our earlier cases the left and occasionally the right subclavian artery was cannulated for return of oxygenated blood to the arterial system, but at present in all cases including infants the common femoral artery is used for arterial inflow, threading a plastic catheter into the common iliac artery or abdominal aorta from a femoral arteriotomy. When perfusion was completed, the femoral arteriotomy was repaired with arterial sutures, and no complications occurred in the extremity.




FIG. 2. Photograph of stainless steel oxygen diffuser used in oxygenating blood column showing multiple perforations (0.021 inch diameter) in the diffusion plate. Venous blood entered through the plastic catheter A and oxygen entered base of diffuser through steel tubing B.

The pump oxygenator system used was a modification of the DeWall-Lillehei system.<sup>8</sup> Oxygen was diffused through a special stainless steel plug with a diffusion plate perforated with multiple openings 0.021 inch in diameter (Fig. 2). The diffuser was inserted into the lower end of a plastic polyvinyl tube 90 centimeters (3 feet) long which served as the oxygenator or diffusion column (Fig. 3a). For flow rates less than 1,500 centimeters per minute tubing with 1 inch internal diameter was used for the diffusion column, but for larger flow tubing with a 1½ inch internal diameter with a correspondingly larger plate was used. Oxygen flow through the diffusion plate was at a rate of approximately 10 times the flow rate of blood; e.g., 5 liters of oxygen per minute for 500 cubic centimeters per minute blood flow. Blood at the apex of the column which was in a foamed state was directed into a disposable polyethylene plastic half-gallon bottle for elimination of oxygen bubbles (Fig. 3b). A stainless steel sponge coated with "Dow-Corning Antifoam A" was placed in the bottle, and upon contact of the blood with the steel mesh the bubbles burst due to reduction in surface tension, and the blood

was converted to a liquid state. The blood then flowed by gravity into a coiled polyvinyl tube 270 centimeters (9 feet) long which assisted further in eliminating oxygen bubbles and served as an arterial blood reservoir (Fig. 3c). The coiled tube ("Helix") was immersed in a tank of water maintained at 106° Fahrenheit to prevent excessive heat loss in an effort to maintain the normal body temperature of the patient. The oxygenated blood was pumped from the reservoir directly to the patient. No blood filters were employed in the circuit thus eliminating another source of possible obstruction and trauma to the blood in the extracorporeal system. To date no complications due to thrombi or particulate matter in the blood stream have occurred.

A double Sigmamotor pump was used and proved to be very satisfactory (Fig. 3). Rate of flow was based upon body weight of the patient so that for patients less than two years of age 50 cubic centimeters per kilogram body weight was circulated through the pump oxygenator and in patients more than two years old 35 cubic centimeters per kilogram was used. The smallest flow used was 175 cubic centimeters per minute in a 13-week-old infant weighing 3.5 kilograms and the maximum rate of flow was 2,800 cubic centimeters per minute in an 80 kilogram adult. Two pump heads were used, one to remove blood from the venae cavae and pump it through the oxygenator and the other to remove blood from the oxygenated reservoir and pump it into the femoral cannula (Fig. 3). With each case the pump heads were calibrated to the desired rate of flow using sterile normal saline solution and then equilibrated against each other so that blood volume in the patient remained essentially constant.

Blood for use in the pump oxygenator was drawn from donors on the morning of operation into 500 cubic centimeter containers, either siliconized glass bottles or plastic bags containing 15 milligrams heparin and 30 cubic centimeters of 5 per cent




FIG. 3. Photograph of pump oxygenator system used in 88 cases of cardiopulmonary bypass. Venous blood pumped into the system was oxygenated in the bubble type oxygenator and diffusion column A. Defoaming of the blood was accomplished in polyethylene bottle B which contained "Dow-Corning Antifoam A" applied to a stainless steel sponge. Oxygenated blood was collected in the coiled helix which was immersed in a warm water bath at 106 degrees Fahrenheit (C). The double Sigmamotor pump and oxygen source completed the system.

glucose in normal saline. The blood was maintained at body temperature in a thermostatically controlled water bath until ready for use. The pump oxygenator was filled or "primed" with about 1,000 cubic centimeters of blood eliminating all bubbles from the tubes containing the oxygenated blood to prevent air embolism. Before the cannulations were performed, heparin 1.0 to 1.5 milligrams per kilogram was administered intravenously, and at the completion of the perfusion the heparin effect was counteracted by a similar quantity of protamine sulfate diluted in about 50 cubic centimeters of 5 per cent glucose. Also, immediately after perfusion, a transfusion of freshly drawn citrated blood was started to restore essential clotting factors.

Surgical exposure for cardiopulmonary

bypass was obtained by transverse bilateral thoracotomy usually entering the fourth intercostal space anteriorly. The sternum was transected and the internal mammary vessels were ligated. The pericardium was incised transversely to expose the base of the heart and venae cavae. The superior mediastinum was carefully examined for the presence of a persistent left superior vena cava or a patent ductus arteriosus since either of these structures interfere greatly with the perfusion. At the completion of operation the pericardium was closed loosely and the thoracotomy was repaired instituting bilateral intrapleural underwater drainage with gentle suction.

*Potassium Induced Cardiac Arrest.* As an adjunct to extracorporeal circulation induced cardiac arrest was used to produce a

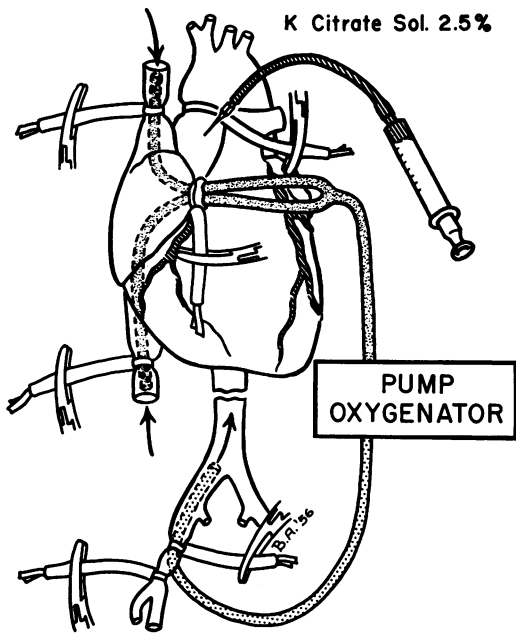


FIG. 4. Diagram showing method of inducing cardiac arrest during cardiopulmonary bypass using dilute potassium citrate solution. With cardiac inflow occluded, the ascending aorta was occluded and potassium citrate was injected slowly until asystole occurred.

completely quiet and bloodless field. Extracorporeal circulation was started with inflow occlusion for a period of about one minute to permit emptying of the heart following which the ascending aorta was occluded and an injection of dilute 2 to 5 per cent solution of potassium citrate was made into the proximal aortic segment (Fig. 4). The solution consisted of 2.0–5.0 cubic centimeters of freshly prepared 20 per cent potassium citrate solution diluted with 18 or 15 cubic centimeters of oxygenated heparinized blood to give the desired strength. Cardiac arrest was produced gradually under electrocardiographic control by slow injection until visible myocardial contractions and electrical activity of the heart were eliminated. Aortic occlusion and coronary stasis was maintained until the repair of the cardiomy was started. Shortly after the occluding clamp on the ascending aorta was released and coronary perfusion was restored, cardiac activity resumed. In most

cases stimulating drugs were unnecessary, but occasionally a dilute 2.5 per cent solution of calcium chloride was injected slowly into the femoral arterial cannula to strengthen the myocardial contraction. However, this was done cautiously under constant electrocardiographic control since excessive calcium ion may produce ventricular fibrillation under these circumstances. In only one instance was cardiac massage used to assist cardiac emptying after potassium induced cardiac arrest. The longest period of induced cardiac arrest by this method was 42 minutes with complete recovery. Air embolism may be a significant danger where potassium arrest is used since trapping of air within the flaccid heart occurs readily. This complicating feature was relatively easy to control by washing out the air with warm saline solution or by opening the venae cavae to fill the heart with blood before the cardiomy was closed. From a practical standpoint small amounts of trapped intracardiac air cause no appreciable disturbance where coronary perfusion can be maintained with extracorporeal circulation since the air may be forced through the coronary circulation without significant effect.

Once the feasibility of cardiopulmonary bypass was demonstrated, the importance of certain technical problems concerned with rapid recognition and expeditious repair of intracardiac lesions was apparent. This was particularly true of ventricular septal defects which vary widely in location, number, and size. The technical difficulties encountered were largely overcome when potassium arrest was employed, and this has become routine in the more recent patients. Preliminary intracardiac palpation through the right auricular appendage was done in all patients where the appendage was large enough to admit the exploring finger. Final localization of the defect was thus permitted and the technic of repair was planned. Exposure of ventricular defects was obtained through a ventriculot-

omy incision made in the direction of the outflow tract of the right ventricle (Fig. 5). Frequently sizable pre-ventricular branches of the right and left coronary arteries were suture-ligated and divided where this was necessary to obtain adequate exposure. For large defects polyvinyl sponge (Ivalon) patches were used to tamponade the closure using 2-0 and 3-0 black silk sutures to hold the sponge in place (Fig. 5a). Small ventricular septal defects were closed with multiple interrupted silk sutures using one row of mattress sutures and a second row of simple interrupted sutures (Fig. 5b). From the time potassium arrest was adopted for routine use, almost all defects were repaired without polyvinyl sponge because complete relaxation of the myocardium facilitated approximation of the edges of the defect and prevented the sutures from tearing out. Sutures were inserted carefully in defects of the membranous septum because of the proximity of the A-V conduction bundle to the posterior border of the defect. Complete A-V dissociation occurred in the only one patient where a deep suture was used in this critical area of the defect and this type of repair was not used again (Fig. 5c). Location of the ventricular septal defects varied greatly and were classified according to anatomic position (Fig. 6). Among 45 ventricular septal defects 34 were in the membranous septum (Type II) and frequently satisfactory exposure and repair required division of the septal insertion of the tricuspid papillary muscle of the septal leaflet. After repair of the defect the papillary muscle was reattached to the septum with multiple sutures. Defects in four patients were located in the posterior superior position of the muscular ventricular septum (Type III) and were exposed by dividing papillary muscles to the posterior tricuspid leaflet. Defects in the outflow tract of the right ventricle were demonstrated low in the muscular septum in four patients (Type IV) and in three patients the defect was above the crista supra-

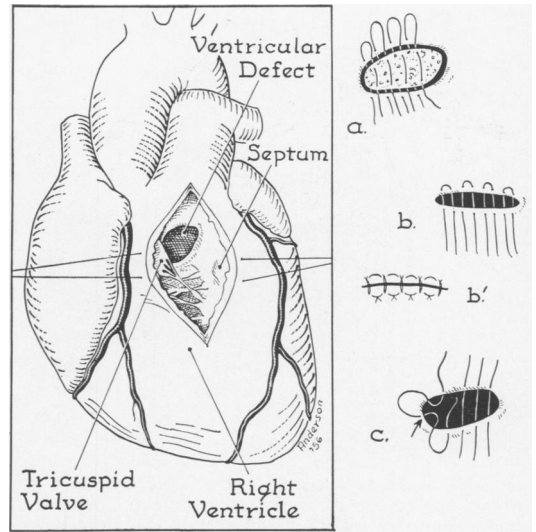


FIG. 5. Drawing showing usual method of repair for ventricular septal defects showing exposure of defect in membranous septum and position of septal leaflet of tricuspid valve. Closure of ventricular defects was done with polyvinyl sponge (a) or by direct sutures (b and c). Repair of posterior angle (indicated by arrow) may injure A-V conduction bundle and A-V dissociation followed in one patient after repair by method c.

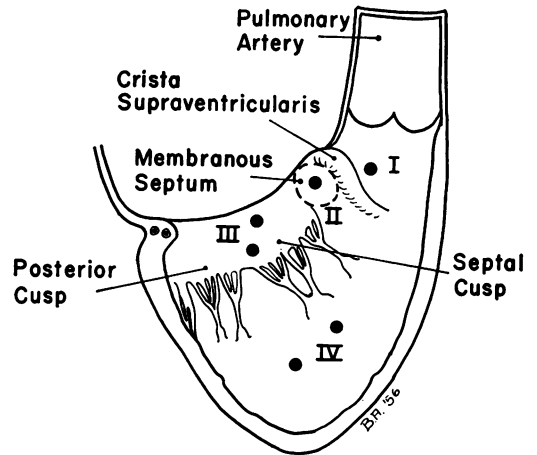


FIG. 6. Drawing showing anatomic position of ventricular septal defects in 45 patients. Defects in membranous septum (Type II) were most common (34 cases). Type I, III and IV defects occurred in three, four and four cases, respectively, and in five patients defects were multiple.

tricularis (Type I). Search was made in each case for additional defects and more than one ventricular defect was discovered and repaired in five patients. In three patients the left to right intracardiac vascular

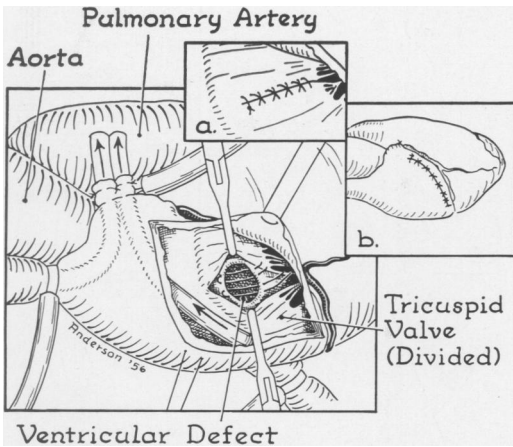


FIG. 7. Drawing demonstrating transatrial approach to repair of ventricular defects located in membranous septum. Exposure of the defect was obtained by atriotomy incision parallel to A-V sulcus and by division of the tricuspid leaflet. After repair of the defect was completed, the tricuspid valve and atriotomy were repaired (Inset *a* and *b*).

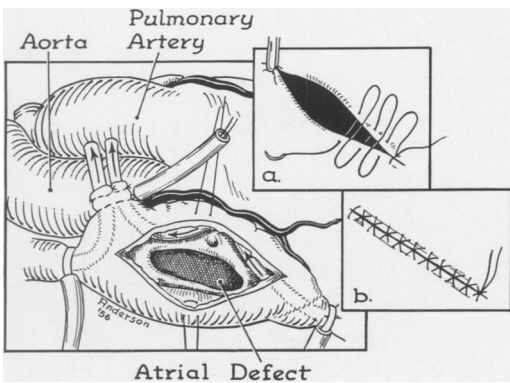


FIG. 8. Drawing showing method of repair of atrial septal defects. The upper margin of the defect was grasped with a hemostat (Inset *a*) and closure was done with a double row of continuous black silk (Inset *b*).

shunt occurred between the left ventricle and right atrium, and in all these there was a deformity, usually a cleft, in the septal leaflet of the tricuspid valve. Repair of the defect and of the cleft tricuspid valve was easily performed through an atriotomy incision directed parallel to the atrioventricular sulcus. Recently this same transatrial approach was used in four patients in repair of typical interventricular defects of the membranous type (Fig. 7). A small incision

in the septal leaflet of the tricuspid valve gave excellent exposure of the defect for repair, and the valve was subsequently reapproximated with a continuous suture (Fig. 7a). Patients appeared to tolerate the atriotomy better than the ventriculotomy approach and this method is preferred whenever the defect may be readily palpated through the right auricular appendage.

Repair of atrial septal defects was performed using a similar but considerably smaller thoracotomy incision than used for ventricular septal defects. Preliminary palpation of the defect was done through the right auricular appendage to localize the defect and detect other anomalies such as anomalous location of pulmonary venous drainage and defects of the tricuspid or mitral valves. Inflow occlusion was established, an atriotomy incision was made, and after blood was aspirated from the right atrium the upper angle of the defect was grasped with a hemostat (Fig. 8). Repair of the defect was accomplished with a running suture of 3-0 black silk which was continued up and down the defect to give a double row of sutures (Fig. 8a and b). Polyvinyl sponge was not used in repair of simple atrial defects. In one case of atrioventricularis communis after the mitral and tricuspid valvular anomalies were repaired, the residual atrial defect was patched with a wafer of polyvinyl sponge, and in another both ventriculotomy and atriotomy incisions were used in repair of the complicated defect which consisted of both interventricular and interatrial defects with anomalous A-V valves.

Repair of the ventricular septal defect in patients with tetralogy of Fallot was similar to the method just described for isolated ventricular defects, but in these cases care was exercised to avoid including a leaflet of the aortic valve in the sutures because of the dextraposed aorta over-riding the ventricular septum. In most instances the obstruction to the outflow tract of the right ventricle was produced by a com-



bined infundibular and valvular pulmonic stenosis. In some instances the ventriculotomy incision was extended upward through the annulus of the pulmonary valve into the pulmonary artery. After the infundibulectomy was completed, plastic repair of the pulmonary valvular annulus was done increasing the diameter of the annulus by suturing the incision transversely in the pulmonary artery and adjacent ventricle and the remainder of the ventriculotomy was repaired longitudinally producing a "T" shaped closure of the incision.

Technics of repair which were used for less common defects have already been or will soon be described elsewhere.<sup>4-7</sup>

#### UNILATERAL BYPASS

A method for bypassing only a portion of the cardiovascular system was used without an oxygenator when only veno-venous or arterio-arterial shunting was necessary. For example, in one patient, a 14-year-old boy with combined infundibular and valvular pulmonic stenosis with intact ventricular septum and roentgenographic evidence of right ventricular hypertrophy (Fig. 9a), cardiac inflow occlusion was produced and caval blood was pumped into the pulmonary artery at a rate of 1,500 cubic centimeters per minute (Fig. 9b). Right ventriculotomy was used for complete infundibular resection and pulmonary valvulotomy under direct vision. The method was successful in this patient but appeared to produce excessive blood loss and total cardiopulmonary bypass is probably more satisfactory for this purpose.

Unilateral bypass was used in by-passing the descending thoracic aorta in order to prevent spinal cord ischemia distal to the occluding clamps resulting in paraplegia during resection and grafting of the aorta for fusiform aneurysm.<sup>12</sup> Thus, for aneurysms of the descending thoracic aorta and thoraco-abdominal aorta oxygenated blood was removed through a plastic cannula placed in the left auricular appendage and

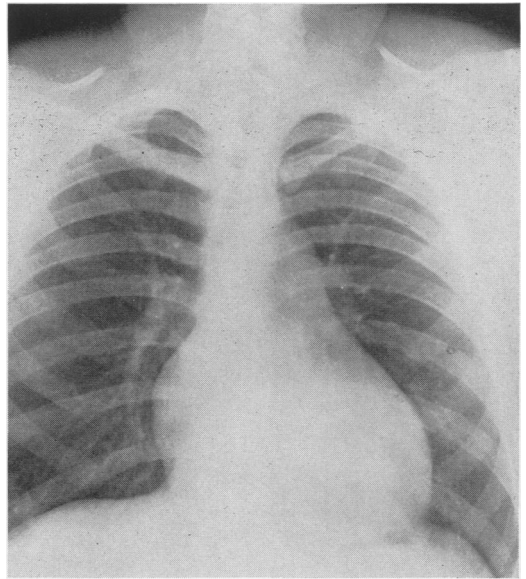


FIG. 9A.

FIG. 9. Roentgenogram of chest in 14-year-old patient with combined infundibular and valvular pulmonary stenosis showing right ventricular hypertrophy and absence of a dilated pulmonary artery (a). Method of bypassing right ventricle and pulmonary valve is demonstrated in (b).

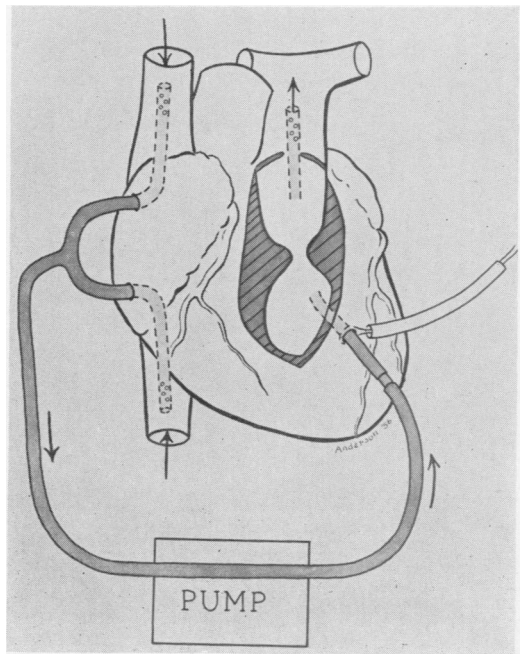


FIG. 9B.



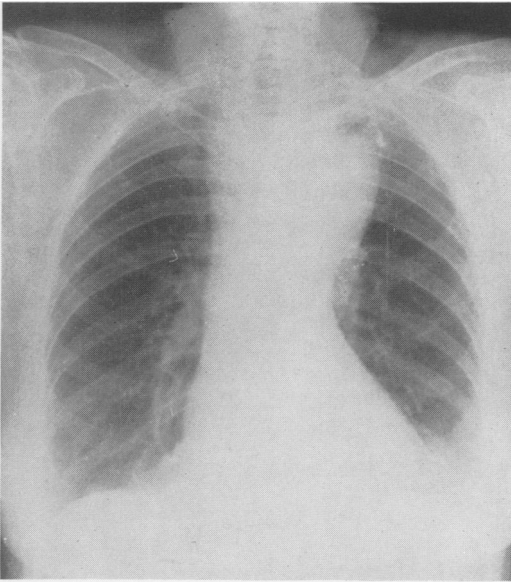


FIG. 10A.

FIG. 10. Roentgenogram of chest in 72-year-old patient with acute dissecting aneurysm of distal portion of aortic arch (*a*) and diagram showing method of unilateral bypass used in resecting and grafting aorta (*b*).

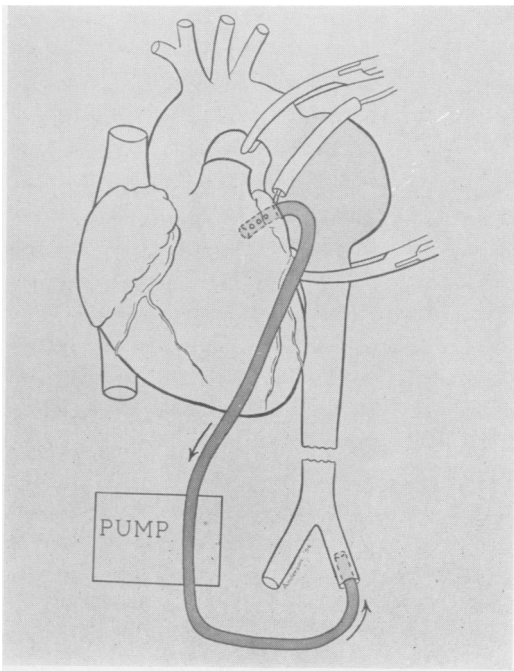


FIG. 10B.

pumped into the abdominal aorta through a catheter threaded up a femoral artery (Fig. 10a and b). In general a flow rate of approximately 500 to 750 cubic centimeters per minute was used to produce the desired protective effect upon the spinal cord. Upon completion of the grafting procedure which usually required 35 to 60 minutes, the cannulae were removed and the appendage and femoral artery were repaired. In cases of unilateral bypass heparin was administered in dosage 1.0 milligrams per kilogram body weight and, if perfusion exceeded 30 minutes, additional small doses of heparin were administered.

#### RESULTS

Since January 1956 temporary extracorporeal circulation was used in 98 operations for cardiovascular disease (Table I). In 88 instances total cardiopulmonary bypass was employed and 10 operations were performed with unilateral bypass alone. Among the patients with cardiopulmonary bypass there were 23 early deaths occurring within the first 2 weeks after operation usually in the first 24 hours and 3 late deaths occurring as much as two months after operation giving a total mortality in this group of 29.5 per cent (Fig. 13). Three deaths occurred in patients in whom unilateral bypass was employed and all of these were in patients with massive aortic aneurysms and advanced arteriosclerosis associated with renal insufficiency. Indeed the total mortality can only be evaluated properly after full consideration of the complicating features of the disease which existed in most patients. Many of the patients, for example, were in advanced stages of chronic cardiac failure at the time of operation, and the surgical attempt was made as a final resort. Moreover, in several patients surgically intractable anomalies such as endocardial fibro-elastosis and extremely complicated septal defects of the atrio-ventricularis communis type were encountered at thoracotomy. The fact that no patients were refused operation in whom

the possibility seemed to exist that surgical correction of the lesion was possible unquestionably accounted to a major extent for the apparent high operative risk.

A meaningful impression of the results of operation with extracorporeal circulation may be obtained by close scrutiny of the results in the various categories. Cardiopulmonary bypass was used in 45 patients with ventricular septal defect, of which 38 survived providing a mortality rate of 15.5 per cent. The youngest patient in this group was 11 weeks old and the oldest was 40 years old. Sixteen patients were less than two years of age, and in most instances these patients were serious surgical risks at the time of operation as evidenced by the fact that 5 of the 7 deaths in this group occurred in patients less than two years old. Associated anomalies were present in more than half of the patients with ventricular septal defect, in most instances increasing the cardiac disability and adding to the technical problem at operation. Five patients had concomitant tricuspid insufficiency of severe degree requiring valvuloplasty, and in one a ruptured papillary muscle was repaired successfully. Two patients also had aortic regurgitation of severe degree. In one extremely ill three-year-old patient a ventriculo-atrial shunt with tricuspid insufficiency was complicated by severe subaortic stenosis, yet successful repair of all three defects was accomplished using a right atriotomy and ascending aortotomy. In another patient a large ventricular defect was corrected in the presence of a corrected transposition or malrotation of the heart. Recurrence of the ventricular septal defect occurred in an 11-year-old girl who had a large defect measuring 3 centimeters in diameter closed with polyvinyl sponge at the first operation. In order to expose the defect it was necessary to divide the papillary muscle of the medial leaflet but this was repaired after the defect was closed. Pulmonary arterial pressure which had been equal to aortic pressure before

TABLE I. *Cardiovascular Lesions Operated upon Using Extracorporeal Circulation*

Lesion	No. Cases
A. Cardio-pulmonary bypass	
Ventricular septal defect	45
Atrial septal defect	12
Tetralogy of Fallot	7
Atrio-ventricularis communis	5
Aneurysm ascending aorta	4
Pulmonic stenosis	4
Transposition great vessels	2
Aortico-pulmonary septal defect	2
Ruptured ventricular septum (coronary)	1
Ruptured tricuspid valve (trauma)	1
Calcific aortic stenosis	1
Ruptured aneurysm sinus Valsalva	1
Single ventricle	1
Aortic regurgitation (congenital)	1
Endocardial fibroelastosis	1
Aorto-ventricular fistula (traumatic)	1
Subtotal	88
B. Unilateral bypass	
Aneurysm descending aorta	9
Infundibular pulmonic stenosis	1
Subtotal	10
Total	98

closure of the defect showed a 50 per cent reduction. After an uneventful early post-operative course while she was at home chest pain suddenly occurred and congestive failure ensued. Six weeks later when the patient was in severe failure, cardiopulmonary bypass was used again. A recurrence of the defect 1.5 centimeters in diameter was discovered at the posterior angle, but the principle cause for the failure and extreme hepatomegaly was tricuspid insufficiency due to disruption of the papillary muscle. Under potassium induced cardiac arrest the septal defect and septal leaflet of the tricuspid valve were repaired, and the patient recovered. This case illustrated the importance of induced cardiac arrest in repair of ventricular defects since at the original operation done without induced arrest, sutures must have partially torn out due to the vigorous myocardial contractions. With the ventricle completely relaxed

TABLE II. *Mortality in Operations Performed with Extracorporeal Circulation*

		Early	Mortality Late	Total	Per Cent
A. Cardiopulmonary bypass					
Ventricular septal defect	45	7	0	7	15.5
Atrial septal defect	12	2	0	2	16.6
Tetralogy of Fallot	7	3	0	3	
Aneurysm ascending aorta	4	2	1	3	
Pulmonic stenosis	4	0	0	0	
Atrio-ventricularis communis	5	3	0	3	
Miscellaneous	11	6	2	8	
Total	88	23	3	26	29.5
B. Unilateral bypass					
Aneurysm descending aorta	9	2	1	3	
Infundibular pulmonic stenosis	1	0	0	0	
Total	10	2	1	3	30

firm repair was greatly facilitated at the second operation.

Of particular importance in evaluation of results of operation for ventricular septal defect is a consideration of pulmonary arterial pressure since it is known that alterations in pulmonary vascular resistance in this condition are of vital prognostic significance. Sixteen patients in this series had moderate to severe pulmonary hypertension with pressures at cardiac catheterization in excess of 70 millimeters of mercury. In several patients the pulmonary arterial pressure was more than 90 per cent of systemic arterial pressure and in one patient the pressures in pulmonary and systemic beds were roughly equal. Indeed mild arterial oxygen unsaturation was evident in some patients where the peripheral arterial blood was 85 to 95 per cent saturated indicating a tendency to reversal of the vascular shunt. No frankly cyanotic patients or patients with Eisenmenger's syndrome were operated upon. Nevertheless, the response of pulmonary arterial pressure to surgical repair of the ventricular defect was extremely gratifying, the maximum benefit in this respect occurring in patients where the pulmonary pressure was greatest (Table II). The studies were made by direct measure-

ment of intracardiac and arterial pressures at the time of operation, and the cases were classified according to severity on the basis of comparison of pulmonary to systemic arterial pressure expressed as percentage. It is noteworthy that in the patients with severe pulmonary arterial hypertension where pulmonary pressure was greater than 70 per cent of systemic pressure, a 51.7 decrease in this ratio occurred immediately after repair of the defect. In the moderate and mild cases there was a 43 per cent and 27.2 per cent decrease, respectively. Subsequent follow up on these patients reveals convincing clinical evidence of progressive decrease in pulmonary pressure with roentgenographic evidence of decrease in pulmonary vascularity and reduction in cardiac size (Fig. 11a & b). Confirmation of this response will be obtained subsequently by cardiac catheterization.

In 12 patients where surgical repair of large atrial septal defects was performed, 11 of which were of the septum secundum type and one an ostium primum defect, there were two deaths yielding a mortality of 16.6 per cent. One of the fatalities occurred in a 50-year-old woman who had been virtually bedridden for years with intractable congestive heart failure and

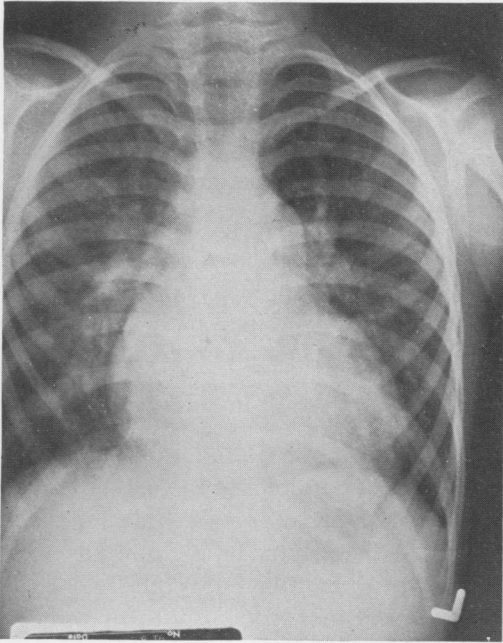


FIG. 11A.

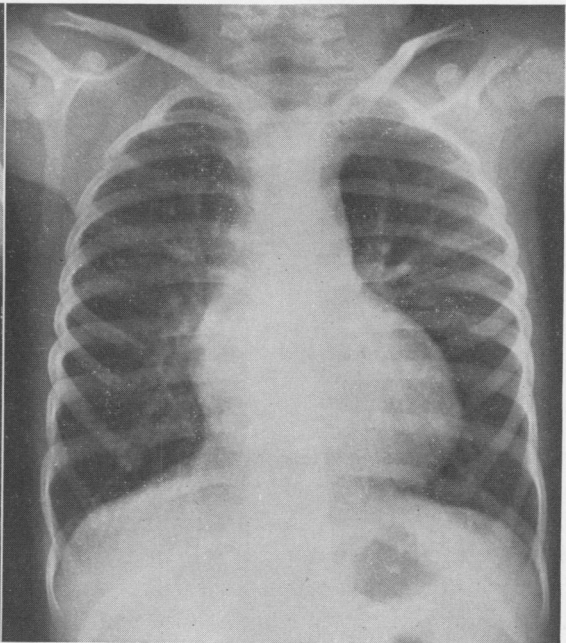


FIG. 11B.

FIG. 11. Roentgenograms of chest made before and five months after repair of a large ventricular septal defect in a 5-year-old patient with severe pulmonary hypertension showing decrease in cardiac size and vascularity of lung fields.

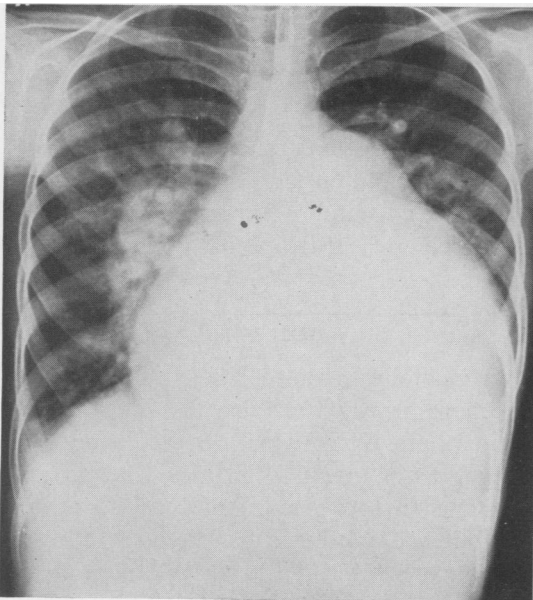


FIG. 12A.

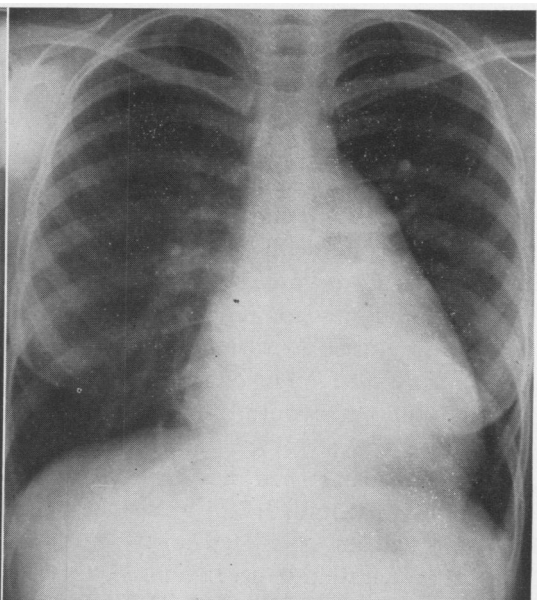


FIG. 12B.

FIG. 2. Roentgenograms of chest in 12-year-old patient with large atrial defect, rheumatic myocarditis, and congestive failure made before and eight months after repair of the defect showing striking decrease in cardiac size and pulmonary vascularity.

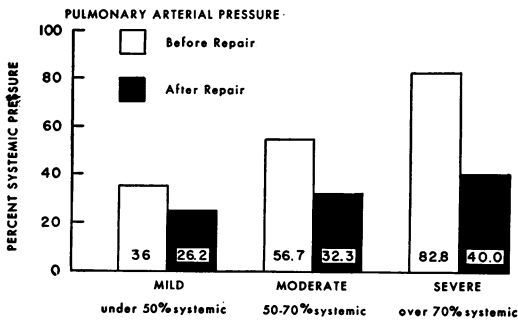


FIG. 13. Alteration in pulmonary arterial pressure at operation before and after repair of ventricular septal defect with pulmonary pressure expressed as per cent of systemic arterial pressure.

auricular flutter. When cardiopulmonary bypass was begun and cardiotomy performed, the cardiac rhythm reverted to sinus for the first time in more than a year and repair of the massive septal defect was well tolerated. Unfortunately, on the fourth day after operation she died suddenly, presumably from acute heart block. The other fatality occurred following potassium induced cardiac arrest in a 40-year-old woman where massive coronary air embolism caused ventricular fibrillation. Although cardiac resuscitation was possible in this patient, she died 12 hours later from cerebral complications. In all of the survivors a careful and complete closure of the defects was obtained and the operation was extremely well tolerated. After operation striking improvement and in some complete relief of symptoms with reduction in heart size has already occurred (Fig. 12).

Open cardiotomy for repair of tetralogy of Fallot was done in seven patients none of whom were severely cyanotic. In fact, most of these cases were of the "atypical" type where the shunt at the ventricular level was either balanced or a moderate left to right shunt existed. In this group of patients one had an associated aortic insufficiency of moderate degree. In another there was pulmonary hypertension. One three-year-old patient had an anatomical tetralogy of Fallot complicated by a large aortico-pulmonary septal window, and this patient

survived total correction of the combination of anomalies. Three deaths occurred among the patients with tetralogy of Fallot, all three presumably due to congestive cardiac failure during the first 24 hours after operation.

Open cardiotomy for pulmonary stenosis was performed in five patients without a death. In four patients a severe infundibular obstruction was present and in three of these there was combined infundibular and valvular stenosis. One patient in this group was cyanotic and angiocardiography revealed the presence of a small ventricular septal defect and infundibular stenosis (Fig. 14). At cardiotomy the septal defect was repaired and complete infundibulectomy was done reducing right ventricular pressure at operation from 160/0 to 65/3 millimeters of mercury.

Impressive results were obtained in several patients with unusual cardiac conditions. For example, in one 14-year-old patient with severe pulmonary hypertension a large aortico-pulmonary septal window measuring 4.0 centimeters in diameter was successfully divided.<sup>7</sup> In another patient in congestive failure an intracardiac fistula between the ascending aorta and right ventricle produced by a stab wound was repaired. These and other gratifying results compensate in large measure for the operative risk encountered in many other operations where extracorporeal circulation was used.

#### DISCUSSION

Hematologic complications following operations in which extracorporeal circulation and pump oxygenator are employed may occur from many mechanical factors and trauma to the blood. Yet in spite of the turbulence produced in the gas diffusion type oxygenator and in the pumping mechanism, surprisingly little hemolysis was produced in our patients. All tubing and connectors in the circuit were made of plastic, stainless steel, or gum rubber reducing the

tendency to destruction of blood cells and platelets. Samples of blood removed from the arterial cannulae at the conclusion of perfusion consistently revealed a plasma hemoglobin value less than 50 milligrams per cent and in none of the cases studied has it reached a dangerous or nephrotoxic level. Renal function studies which were conducted in eight patients in his series indicate that the procedure was well tolerated by the kidney producing only a transient depression of renal function during the perfusion.<sup>1</sup> Hematologic studies including coagulation time and platelet counts on these same samples revealed only a moderate depression in thrombocytes, but 2 earlier patients had uncontrolled hemorrhagic manifestations after operation for unknown reasons. In the majority of patients the slight hematologic changes were within the limits of safety for the patient after the brief periods of time, usually less than twenty minutes, of temporary extracorporeal circulation which were employed.

Induced cardiac arrest proved to be an invaluable adjunct to surgical repair of certain defects. Potassium citrate solution as recommended by Melrose and Dreyer<sup>14</sup> was used routinely for this purpose and in general was highly satisfactory. Certain disadvantages to use of potassium exist, however, particularly concerned with disturbance in electrolyte balance produced by large quantities of potassium ion. In one five-year-old patient, for example, 35 milliequivalents of potassium was necessary to produce asystole, and in another 12-year-old patient more than 100 milliequivalents was used. After operation, because of the possibility of hyperkalemia, calcium chloride was administered by constant slow drip. Although not as potent as potassium, acetyl choline may be used similarly to induce cardiac arrest without producing a disturbance in electrolyte pattern. Its effect is reversible by use of small quantities of atropine,<sup>15, 16</sup> and because of these advan-

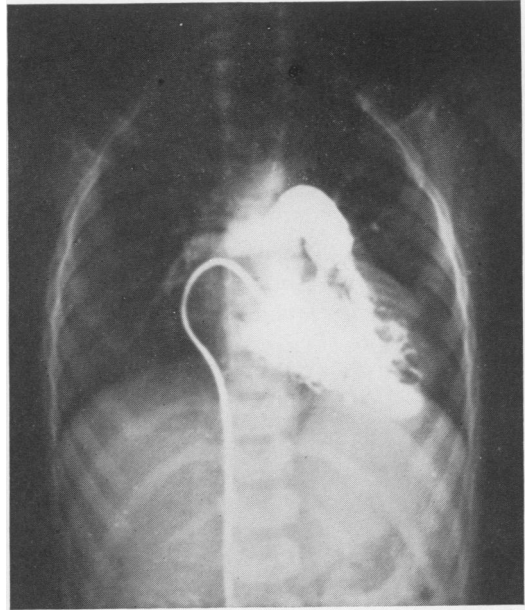


FIG. 14. Selective angiogram made in 5-year-old cyanotic patient showing infundibular pulmonary stenosis and small ventricular septal defect producing early opacification of the aorta by the contrast medium.

tages, it may subsequently be used as a substitute for potassium.

#### SUMMARY

During the past few years temporary extracorporeal circulation has been developed for clinical application in surgical treatment of cardiovascular diseases. Two methods have been employed, total cardiopulmonary bypass with pump oxygenator and unilateral bypass without oxygenator. Ninety-eight operations using temporary cardiopulmonary bypass are reported, 88 being total cardiopulmonary bypass and 10 unilateral bypass.

The oxygenator system was a bubble diffusion type which produced consistently good oxygenation without serious hematologic changes.

Ventricular septal defects were repaired in 45 patients. Decrease in pulmonary pressure occurred at operation in all patients, and clinical improvement resulted in the 38 survivors.

Repair of atrial septal defects was usually well tolerated under cardiopulmonary bypass and is considered to be the method of choice for these defects. Among 12 patients operated upon 10 recovered and are apparently cured.

Complete correction of tetralogy of Fallot was attempted in seven patients with four survivors, and in four patients with isolated pulmonary stenosis there were no deaths.

Unilateral bypass was used successfully in one patient with combined infundibular and pulmonary valvular stenosis. For aneurysms of the descending thoracic aorta bypass around the lesion proved effective in preventing ischemic damage to the spinal cord during temporary aortic occlusion.

#### ADDENDUM

Since this paper was presented, 52 cases of cardiopulmonary by-pass and 12 cases of unilateral aortic by-pass for aneurysm of the descending aorta have been operated upon. The total cardiopulmonary by-pass experience numbers 150 cases and unilateral by-pass 22 cases. A stainless steel oxygenator has recently been used which is superior in many respects to the disposable plastic oxygenator described herein.

#### REFERENCES

1. Beall, A. C., D. A. Cooley, G. C. Morris, Jr. and J. H. Moyer: Effect of Total Cardiac Bypass on Renal Hemodynamics and Water and Electrolyte Excretion in Man. *Ann. Surg.* To be published.
2. Andreasen, A. T. and F. Watson: Experimental Cardiovascular Surgery. *Brit. J. Surg.*, **39**: 548, 1952.
3. Andreasen, A. T. and F. Watson: Experimental Cardiovascular Surgery: Discussion of results so far obtained and report on experiments concerning a donor circulation. *Brit. J. Surg.*, **41**: 195, 1953.
4. Cooley, D. A., B. A. Belmonte, L. B. Zeis and S. Schnur: Surgical Repair of Ruptured Interventricular Septum Following Acute Myocardial Infarction. *Surgery*. In press.
5. Cooley, D. A. and M. E. De Bakey: Resection of Entire Ascending Aorta for Fusiform Aneurysm Using Temporary Cardiac Bypass. *J. A. M. A.*, **162**: 1158, 1956.
6. Cooley, D. A. and M. E. De Bakey and G. C. Morris, Jr.: Controlled Extracorporeal Circulation in Surgical Treatment of Aortic Aneurysm. *Trans. Am. Surg. Assn.* 1957.
7. Cooley, D. A., D. G. McNamara and J. R. Latson: Aortico-Pulmonary Septal Defect: Diagnosis and Surgical Treatment. *Surgery*. (In Press.)
8. DeWall, R. A., H. E. Warden, R. C. Read, V. L. Gott, N. Ziegler, R. L. Varco and C. W. Lillehei: A Simple Expendable Artificial Oxygenator for Open Heart Surgery. *Surg. Clin. North America*, **36**: 1025, 1956.
9. Gibbon, J. H., Jr.: The Maintenance of Life During Experimental Occlusion of the Pulmonary Artery Followed by Survival. *Surg., Gynec. & Obst.*, **69**: 602, 1939.
10. Gibbon, J. H., Jr.: Application of a Mechanical Heart and Lung Apparatus to Cardiac Surgery. *Minnesota Med.*, **37**: 171, 1954.
11. Kirklin, J. W., J. W. DuShane, R. T. Patrick, D. E. Donald, P. S. Hetzel, H. G. Harshbarger and E. H. Wood: Intracardiac Surgery with the Aid of a Mechanical Pump Oxygenator System (Gibbon Type); Report of 8 Cases. *Proc. Mayo Clin.*, **30**: 201, 1955.
12. Kirklin, J. W., D. E. Donald, H. G. Harshbarger, P. S. Hetzel, R. T. Patrick, H. J. C. Swan and E. H. Wood: Studies in Extracorporeal Circulation. I. Applicability of Gibbon-type Oxygenator to Human Intracardiac Surgery: 40 Cases. *Ann. Surg.*, **144**: 2, 1956.
13. Lillehei, C. W., M. Cohen, H. E. Warden and R. L. Varco: The Direct-Vision Intracardiac Correction of Congenital Anomalies by Controlled Cross Circulation. *Surgery*, **38**: 11, 1955.
14. Melrose, D. B., B. Dreyer, H. H. Bentall and J. B. E. Baker: Elective Cardiac Arrest. *Lancet*, **2**: 21, 1955.
15. Moulder, P. V., R. G. Thompson, C. A. Smith, B. L. Siegel and W. E. Adams: Cardiac Surgery with Hypothermia and Acetylcholine Arrest. *J. Thoracic Surg.*, **32**: 360, 1956.
16. Sergeant, C. K., T. Geoghan and C. R. Lam: Further Studies in Induced Cardiac Arrest Using the Agent Acetylcholine. *Surg. Forum*, American College of Surgeons, Oct. 1956. To be published.