

# Healing of the Intestine in Experimental Bowel Infarction \*

DONALD J. GLOTZER, M.D.,\*\* ALEJANDRO H. VILLEGAS, M.D.,  
SUDHAWIT ANEKAMAYA, M.D., ROBERT S. SHAW, M.D.

*From the Department of Surgery and the James Homer Wright Pathology Laboratories of the Massachusetts General Hospital and the Department of Surgery of the Harvard Medical School*

SURGEONS are familiar with ischemic bowel injury largely because of experience with strangulation obstruction. Extensive investigations have been carried out to determine criteria of viability of a compromised segment of bowel. If serious doubt remains in such cases, the problem is readily resolved by resection. In massive bowel infarction from superior mesenteric artery obstruction, resection may not be reasonable because of the amount of bowel involved, and arterial reconstruction may be the only hope for salvage. Recovery may depend, in this instance, not only upon the ability to restore circulation but the healing potential of very severely damaged bowel.

Clinical experience has shown that recovery from a severe ischemic injury of the entire small bowel is possible,<sup>1,4</sup> and also that healing may be associated with a prolonged period of functional disability.<sup>15</sup> These studies were undertaken to document the nature of the ischemic damage to bowel, to relate the pathologic lesion to duration of ischemia, and to examine the potential and sequences of healing.

## Methods and Materials

Preparations were constructed in anesthetized mongrel dogs with sterile technic as follows. At a first stage, a one-foot segment of jejunum beginning approximately two feet from the ligament of Treitz was isolated and continuity restored in the remaining intestine by end-to-end anastomosis. The blood supply to the isolated segment usually included four straight vessels and narrowed to a single pedicle including artery and vein at the base of the mesentery. The proximal end of the isolated loop was turned in and sutured to the abdominal wall to avoid intussusception. The distal end of the loop was led through a circular wound on the left side of the abdomen and the mucosa of the bowel sutured to the skin. The laparotomy wound was closed and the dogs allowed to recover.

After healing took place it was possible to biopsy the mucosa of the jejunal loop without anesthesia with a specially constructed flexible biopsy tube on the principle of a Shiner tube.<sup>2</sup> Such a biopsy to be satisfactory had to have a small bit of muscularis mucosae attached to it. The biopsy was fixed immediately in 10 per cent formalin, and sectioned at a later time. It was important to cut and imbed the tissue at right angles to the plane of the lumen for proper orientation. The tissue was proc-

\* Submitted for publication June 7, 1961.

\*\* Current address: Department of Surgery, Tufts University School of Medicine, New England Center Hospital, Boston, Massachusetts.

Supported by the Medical Foundation and U.S.P.H. Grant H-633 (C11).

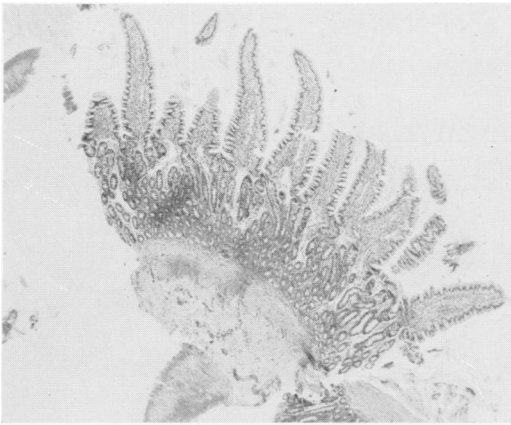


FIG. 1. Biopsy of normal dog jejunum obtained through cutaneous stoma showing normal villi, crypts and muscularis mucosae.

essed automatically, imbedded in paraffin and stained with hematoxylin and eosin. Such a biopsy is shown in Figure 1.

After control studies of the loop were performed, the dogs were again anesthetized and a second laparotomy performed through the previous incision. Circulation in the loop was totally arrested by occluding the mesenteric vascular pedicle and the stomal attachment with atraumatic clamps after separating all other attachments which might provide a portal for circulation. Following the desired period of circulatory arrest, the clamps were released, the proximal end of the loop reattached to the abdominal wall and the wound closed.

Biopsies were taken at the time of operation before and after release of the occluding clamps, and at intervals in the post-operative days and weeks, until the mucosa was healed. Following healing the dogs were sacrificed with an overdose of a barbiturate and the isolated bowel segment removed along with a comparable segment of normal bowel. Both were immediately fixed in 10 per cent formalin and processed in the same manner as the biopsies.

In a number of dogs an attempt was made to assess function in the bowel loops before and after injury. Fluid in the volume of

15 cc. would be instilled into the loop through the cutaneous stoma, retained in the loop by means of a balloon inflated just within the stoma, and completely aspirated and re-instilled at intervals to allow sampling and measurement of volume. Five per cent dextrose and water was instilled in these initial experiments, and total volume and dextrose concentration measured at five-minute intervals for one-half hour.

## Results

The bowel was able to recover from periods of total ischemia as long as seven and one-quarter hours. All animals subjected to eight hours or more of ischemia to these loops died with gangrene of the segment with or without perforation. The injury started at the tips of the villi and extended deeper into the crypts with increasing amounts of ischemia. Further desquamation of epithelial cells, edema and extravasation usually occurred immediately after release of the occluding clamps. In the longer ischemic periods further loss of mucosal elements occurred subsequently. The time necessary for complete healing depended on the amount of the original injury.

The ability of the mucosa to regenerate following nearly complete destruction was

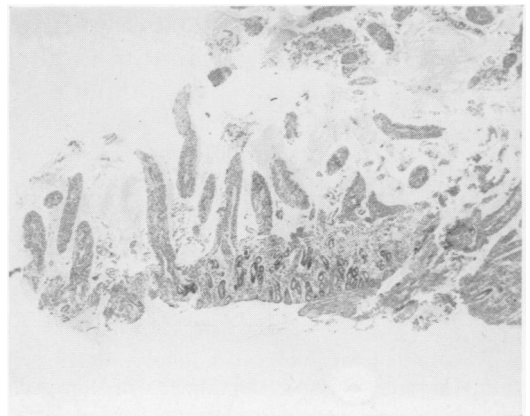


FIG. 2. Usual injury at 2 hours. Note sloughing of villus epithelium and a portion of the crypts with preservation of the connective tissue elements of the mucosa.

impressive. Although in most instances the regenerated mucosa was recognizably abnormal, it had very well differentiated villi and crypts. Particularly remarkable was the regrowth of smooth muscle in the villi even when the villi had previously sloughed off completely.

**Gross Observations.** Upon application of occluding clamps the bowel immediately became blue-white and pulseless. There was overactive peristalsis and accordion-like contraction of the musculature. Frequently with longer periods of ischemia the bowel became more cyanotic and developed focal ecchymoses. Following release of the clamps the pulses in the vessels adjacent to the bowel returned rapidly and the serosa became pink. There was subsequent rapid edema formation and the segment became thickened and turgid. The loops doomed by eight-hour ischemic periods could not be sharply differentiated from the ones destined to survive. Frequently, there was a serosanguineous discharge from the stoma after injury and during the healing period. Occasionally, this became frankly purulent. When the animals were sacrificed, there were usually a fair number of adhesions in the abdomen and especially about the loop. Although there was a considerable individual varia-

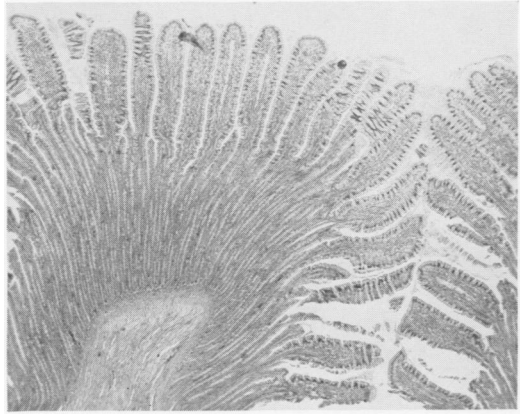


FIG. 4. Control autopsy specimen.

tion, the most striking reactions were in the loops subjected to the severest injury. The diameter of the isolated loop was usually significantly less than the adjacent jejunum, probably largely due to the de-functioned state. In the severer injuries there was loss of or diminution in prominence of the valves of Kerckring with flattening and thinning of the mucosa.

**Microscopic Observations.** *Two-hour occlusions (three animals)*—At the end of the ischemic period there was sloughing of a good portion of the villus epithelium leaving the connective tissue portion of the villus intact. Except for one animal there was, in addition, some damage to the upper layers of the crypts in the form of pyknotic nuclei and the pulling away of the cells from one another and the basement membrane. Figure 2 shows the usual injury at two hours. In two animals the bowel returned to normal within 24 hours. In the third there was as rapid re-epithelialization but there was persistent shortening and distortion of the villi, which did not return to normal during the period of observation. At autopsy the animal showed villi that were noticeably shorter, wider and more irregular than those of the bowel from which the segment was removed. In a second animal the villi were virtually normal except for acute and chronic inflammation. The third animal was not autopsied. Figure 3

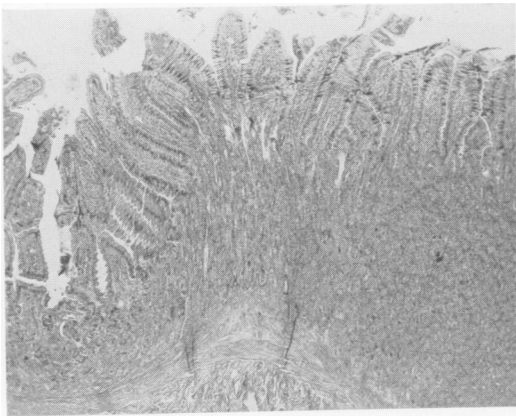


FIG. 3. Autopsy specimen of mucosa subjected to 2 hours ischemia and then allowed to heal. (Same animal as Fig. 2). Note regeneration to near normal mucosa.

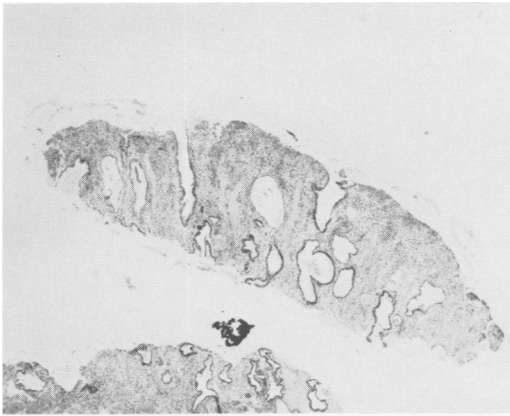


FIG. 5. Mucosa 6 days after 4 hours ischemia showing granulation tissue in which a few glands with cuboidal, nondifferentiated epithelial cells are present.

shows healing of mucosa subjected to two hours ischemia. Figure 4 shows a normal autopsy specimen.

*Four Hour Occlusions (three animals)*—Immediately after release of the occluding clamps there was virtually total degeneration of the epithelial covering of the villi and injury to the upper one-fourth to three-fourths of the crypt depth. The connective tissue stroma was left intact initially, but subsequently there was further injury with hemorrhage, acute inflammation, and sloughing of the villus tips. Granulation tissue with a few scattered glands with cuboidal epithelium replaced the mucosa, although one animal showed epithelial covering of the surface and some villus formation in 24 hours and healing by day six. The mucosa of a second animal healed in about two weeks, but the third in this group showed gradual slow healing over two months' time. Autopsies on all three animals in this group showed abnormal mucosae with shortened, irregular, thickened, sometimes branching villi. Figure 5 shows a mucosa six days after four hours of ischemia. Figure 6 shows the same animal at autopsy 102 days after injury.

*Five-hour occlusions (three animals)*—Two animals in the group promptly died of peritonitis, one due to perforation of the

loop probably due to a technical error and the other from contamination, as no perforation or intestinal leakage was found at autopsy. In all animals, there was evidence of epithelial degeneration from villus tip to the depths of the crypts.

The surviving animal initially had almost total destruction of the epithelium of villi and crypts, and in the ensuing days there was replacement of the mucosa by a granulation tissue. There was slow re-epithelialization with scattered gland formation. This animal was sacrificed prematurely at 45 days and at autopsy the mucosa showed only a few scattered glands and focal epithelialization of the surface, illustrating that healing of such damaged mucosa takes place from scattered epithelial cells in the base of the crypts and from the intact mucosa at the stoma. In addition there was loss of a portion of the muscularis of the bowel wall (Fig. 7).

*Six-hour occlusions (two animals)*—One of the two animals in the group showed fair preservation of the crypts immediately after the injury. Healing over the surface took place within two days and by five days the mucosa had completely regenerated. This animal was sacrificed at three and one-half months and at this time the mucosa appeared almost normal.

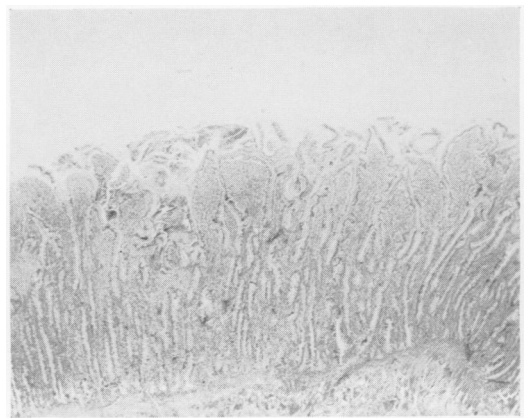


FIG. 6. Autopsy specimen 102 days after 4-hour injury. (Same animal as Fig. 5). Note the shortened, widened, irregular villi.

The mucosa in the other animal showed virtually full thickness damage initially, and on the day after the ischemic period replacement by granulation tissue with a few scattered glands was noted. Spotty re-epithelialization of the surface took place by three days, but fairly good villi did not appear in all areas until 29 days. At autopsy 57 days after injury the villi were shortened, widened and irregular.

*Seven-hour occlusions (three animals)*—The immediate initial injury varied from partial to almost full thickness of mucosa. In all three animals there was further histological damage in the ensuing days resulting in a lumen lined by granulation tissue with a few scattered glands.

In one animal the mucosa healed gradually over an 86-day period. At autopsy at 200 days, mucosa with shortened distorted villi was present, but considering the original injury, they were surprisingly normal (Fig. 8). There was some loss of smooth muscle in the bowel wall in this animal.

The mucosa in another animal had healed focally by 23 days, but even after 106 days there were still areas of granulation tissue.

The third animal was extremely sick for a few days following the injury and appeared to be dying. A biopsy at two days showed what appeared to be serosal fat. The animal was sacrificed in two and one-



FIG. 8. Autopsy specimen of final healing after 7-hours ischemia. Recognizably abnormal mucosa, but with all the normal elements including smooth muscle in the villi. Note destruction of smooth muscle in the wall of the bowel.

half months and the loop found replaced by a fibrotic cord with a few scattered intestinal glands.

*Eight-hour occlusions (three animals)*—All three animals died because of gangrene of the loop. Initial biopsies indicated an injury no more severe than that seen in the seven-hour dogs (Fig. 9). Subsequent sections in most areas showed a preservation of the connective tissue framework without invasion by inflammatory cells or extravasation of red cells and the mucosa did not slough away (Fig. 10). When autopsied there was, in addition, evidence of muscle necrosis in the wall of the bowel. There was no clue to the obvious failure of the circulation to bring inflammatory cells to the area in the form of thrombosis of the mesenteric or submucosal vessels.

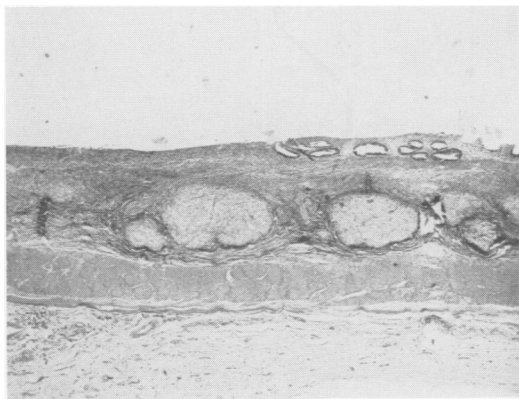


FIG. 7. Autopsy specimen of bowel subjected to 5-hours ischemia sacrificed before healing. Note loss of smooth muscle, ulceration, few scattered glands and prominent lymph follicles.

## Discussion

The lethal dose of ischemia from experimental mesenteric artery occlusion in animals is about four hours.<sup>11, 12</sup> This implied time limit, if applied to superior mesenteric artery occlusion in man, would leave little practical opportunity for mesenteric arterial embolectomy with recovery. We attempted to study the bowel injury itself, eliminating secondary general effects on the organism

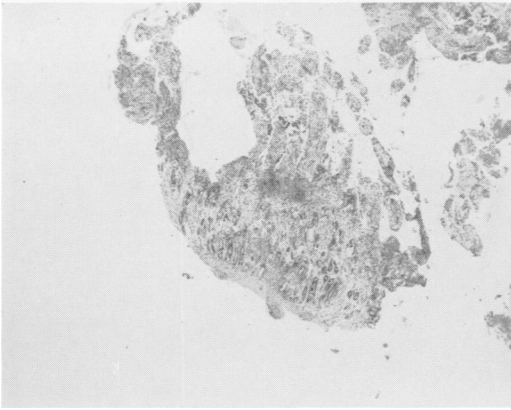


FIG. 9. Injury at 7 hours showing apparently viable cells at base of crypts.

by observing the changes in a short isolated segment of bowel. Here nearly twice this period of ischemia was required to produce injury which would not heal. Injury beyond the capacity for healing may be the principle limiting factor in recovery, rather than the largely manageable effects of exudative losses, bacterial infection and temporary interference with nutrition.

The severity of ischemic injury to bowel will be a function not only of duration of ischemia but also of degree of ischemia. The maximum duration of ischemia consistent with recovery defined in the described experiments would almost certainly be extended by making the circulatory arrest less complete. Thus, the little trickle of collateral circulation in the human patient with mesenteric infarction explains recovery after reconstructive vascular surgery when the duration of ischemia has been well beyond eight hours, and also makes such surgical treatment of this disorder a hopeful, practical, and reasonable thing.

The duration of ischemia compatible with survival of bowel in such experiments as these could undoubtedly be improved by control of intestinal bacteria since there is increasing evidence that bacteria are synergistic with ischemia in producing further damage to the gut. Several investigators have shown a protective action of antibi-

otics with experimental mesenteric obstructions as well as in strangulation obstructions.<sup>3, 5-7, 12, 13</sup> Cohn<sup>5, 6</sup> showed not only longer survival in ischemic bowel by treatment with intestinal and systemic antibiotics, but remarkable preservation of mucosa which otherwise would have been completely destroyed.

Further breakdown of the mucosa following the ischemic period is probably a function of bacterial action. This factor probably comes into play only with severer injuries. In lesser injuries the tremendous repair potential of the intestinal mucosa predominates. The normal rate of turnover of intestinal mucosal cells is truly remarkable, the entire mucosa being replenished in 36 hours in rat and man<sup>1, 8, 9</sup> and in 54 hours in cats.<sup>10</sup>

The present experiments as well as those of Cameron and Khurma<sup>4</sup> show that even brief ischemic periods, though compatible with survival, produce injury to the intestinal mucosa. The injury of a brief ischemic period heals quickly as shown by Cameron and Khurma and in the two-hour ischemic injuries in these experiments.

On the other hand, re-organization and repair in severely injured mucosa took weeks in some cases. This is consistent with

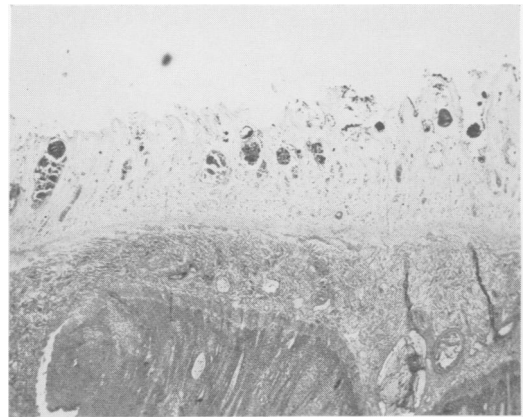


FIG. 10. Autopsy following 8-hour ischemia. Preservation of connective tissue framework with inflammatory cells. Dark areas in mucosa are bacteria. Underlying muscle is necrotic.

the prolonged period of malabsorption observed after mesenteric embolectomy in Rutledge's patient.<sup>14</sup>

Information from animal work is only transferable to the patient in a qualitative manner. The better supportive therapy possible with patients will improve their chance of recovery. The presence of collateral circulation will slow down the progression of ischemic injury during occlusion of the major artery. Potential survival cannot be estimated from the duration of ischemia as judged from the clinical history or even the appearance at the time of exploration. Viability can be better ascertained after restoration of circulation, but in doubtful cases the decision should be delayed to a second operation 12 to 24 hours after restoration of flow.

In many respects the bowel injury due to temporary interruption of the arterial blood supply resembles a thermal burn with the source of heat within the bowel lumen. A relatively brief ischemia "burn" of one to two hours merely singes the tips of the villi. The depth of the "burn" increases with the duration of ischemia until between seven and eight hours the injury is "full thickness" with necrosis of the muscularis and perforation. Whether the latter phenomenon is due to complete breakdown of the mucosal barrier, irreversible blood vessel damage, or some other factor is not yet known.

As in a skin burn the extent may not be determinable initially, a deep second degree burn may be extremely difficult to tell from a third degree one. As in epidermis, a functional organ may regrow from just a few viable elements. The amount of supportive therapy necessary to effect recovery may be comparable to that required in an extensive skin burn.

Finally, the poor salvage rate presently expected from reconstructive vascular surgery in massive intestinal infarction is considerably better than the 100 per cent fatality expected with no treatment. Poor sal-

vage has not discouraged vigorous treatment of extensive burns and both an increase in clinically applicable knowledge and survival rate has resulted. The same can be expected from the vigorous pursuit of therapy in the case of the extensive ischemic "burn" of bowel.

### Summary

1. The recovery potential of small bowel subjected to complete ischemia is great and is a function of the duration of ischemia. Ischemic periods of as long as seven hours are tolerated by isolated small bowel loops without the use of antibiotics.

2. Recovery may be quite prolonged, taking several weeks in some instances, but may proceed from only a few viable epithelial cells to a well organized, near normal mucosa.

3. Important considerations in transferring this information to the treatment of the patient with superior mesenteric ischemia are discussed.

### Bibliography

1. Bertalauff, F. D. and K. Nagy: The Mitotic Activity and Renewal Rate of Duodenal Epithelium. *Anat. Rec. (Proc.)*, **130**:271, 1958.
2. Bolt, R. J., H. M. Pollard and L. Standaert: Transoral Small Bowel Biopsy as an Aid in the Diagnosis of Malabsorption States. *N. Eng. J. Med.*, **259**:32, 1958.
3. Burnett, W. O.: Experimental Strangulated Intestinal Obstruction. A Review. *Gastroenterology*, **39**:32, 1960.
4. Cameron, G. R. and S. D. Khanna: Regeneration of the Intestinal Villi After Extensive Mucosal Infarction. *J. Path. and Bact.*, **77**: 505, 1959.
5. Cohn, I., M. Atik and J. C. Werner: Strangulation Obstruction Combined Arterial and Venous Strangulation. *Surgery*, **48**:1006, 1960.
6. —, and M. Atik: Strangulation Obstruction—Closed Loop Studies. *Ann. Surg.*, **153**:94, 1961.
7. Laufman, H.: Experimental Evidence of Factors Concerned in the Eventual Recovery of Strangulated Intestine. Effects of Massive Penicillin Therapy. *Surgery*, **28**:509, 1950.

8. LeBlond, C. P. and C. E. Stevens: The Constant Renewal of the Intestinal Epithelium of the Albino Rat. *Anat. Rec.*, **100**:357, 1948.
9. —, and B. E. Walker: Renewal of Cell Populations. *Phys. Rev.*, **36**:255, 1956.
10. McMinn, R. M. H.: The Rate of Renewal of Intestinal Epithelium in the Cat. *J. Anatomy*, **88**:527, 1954.
11. Medins, G. and H. Laufman: Hypothermia in Mesenteric Arterial and Venous Occlusions. *Ann. Surg.*, **148**:747, 1958.
12. Nelson, L. E. and A. J. Kremen: Experimental Occlusion of the Superior Mesenteric Vessels with Special Reference to the Role of Intravascular Thrombosis and its Prevention by Heparin. *Surg.*, **28**:819, 1950.
13. Rabinovicci, N. and J. Fine: The Effect of Aureomycin on the Intestine Subject to Vascular Injury. *Ann. Surg.*, **135**:344, 1952.
14. Shaw, R. S. and R. H. Rutledge: Superior Mesenteric Artery Embolectomy in the Treatment of Massive Mesenteric Infarction. *N. Eng. J. Med.*, **257**:595, 1957.
15. —, and E. P. Maynard: Acute and Chronic Thrombosis of the Mesenteric Arteries Associated with Malabsorption. *N. Eng. J. Med.*, **258**:874, 1958.