

Hydrometrocolpos: *

Report of Three Cases and Review of the Literature

ROWENA SPENCER, M.D., DONALD M. LEVY, M.D.**

*From the Department of Surgery, Louisiana State University School of Medicine
and Charity Hospital of Louisiana at New Orleans*

HYDROMETROCOLPOS is a condition in which the uterus and vagina are distended by retained fluid other than blood. This abnormality, which always occurs before the menarche, is associated with atresia of the vagina or imperforate hymen. Vaginal obstruction alone, however, will not produce hydrometrocolpos; there must also be sufficient estrogenic stimulation to provoke secretion from the glands in the reproductive tract. Thus, the condition occurs at the extremes of childhood—in infancy, when there is a high level of maternal hormones, and in early puberty, when the patient herself begins to elaborate estrogenic hormones.

Congenital vaginal obstruction alone is usually not diagnosed until puberty when hematocolpos results from retained menses. Whereas hematocolpos is a relatively common condition, only 59 well-documented cases of hydrometrocolpos have been reported since 1900. The infrequency of this abnormality and the tragic results following errors in diagnosis have prompted the report of three additional cases and a review of the literature.

Case Reports

Case 1. C. H., T 58-284210, a three-month-old colored girl, was admitted to the L.S.U. Pediatric Surgery service of Charity Hospital on May 20, 1958 because of respiratory infection and abdominal distention of ten days' duration. The infant had vomited little but had been anorexic and ir-

ritable. The day before admission the patient had become febrile and urination scanty and infrequent.

The only abnormality of gestation and delivery was polyhydramnios. The infant had been noted to have a distended abdomen shortly after birth (at Charity Hospital).

On admission the infant was acutely ill, dehydrated, and obviously uncomfortable, with a moderately severe respiratory infection and a distended abdomen. Temperature 39.5° C., pulse 160, respirations 30. Numerous coarse rhonchi were heard throughout the chest. A firm smooth mass occupied the entire lower abdomen and extended almost to the costal margin. It could be palpated through a small umbilical hernia and per rectum. Examination of the perineum revealed normal labia but upward retraction of the area of the urethral and vaginal orifices. By using an otoscope as a speculum, the urethral meatus was found to be normal. There was no hymen, and the atretic vagina was represented by a deep dimple. Catheterization of the bladder yielded a small amount of cloudy urine.

Hgb. 8.0 Gm., WBC 29,400 with 80 per cent neutrophils. Urine contained many red and white blood cells and bacteria. Excretory urogram showed bilateral hydronephrosis and hydroureter due to compression of the ureters at the pelvic brim, and displacement of the small intestine into the epigastrium by a rounded homogenous mass filling most of the abdomen (Fig. 1). On cystogram the bladder was seen to be displaced anteriorly and superiorly, with a long narrow urachal tract overlapping through the umbilical hernia (Fig. 2).

The patient was given antibiotics, intravenous fluids, and whole blood. Since it was impossible safely to approach the tiny, inaccessible, atretic lower vagina from below, laparotomy was performed (Fig. 3). The bladder was separated from the vagina anteriorly, and the tremendously distended upper vagina opened and emptied of 800 cc. of foul, faintly green, thin mucoid fluid. After deflation, the vagina could be brought into the

* Submitted for publication August 21, 1961.

** Now at Mayo Clinic, Rochester, Minnesota.

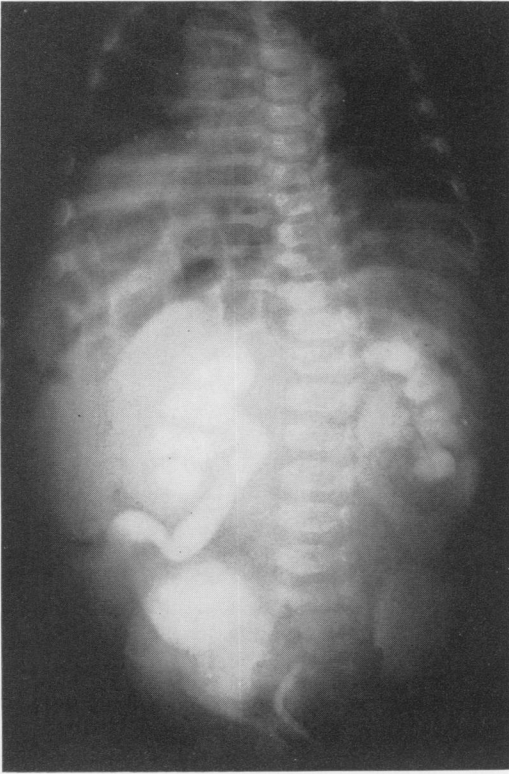


FIG. 1. (Case 1.) Excretory urogram on admission demonstrates hydronephrosis and hydroureter.

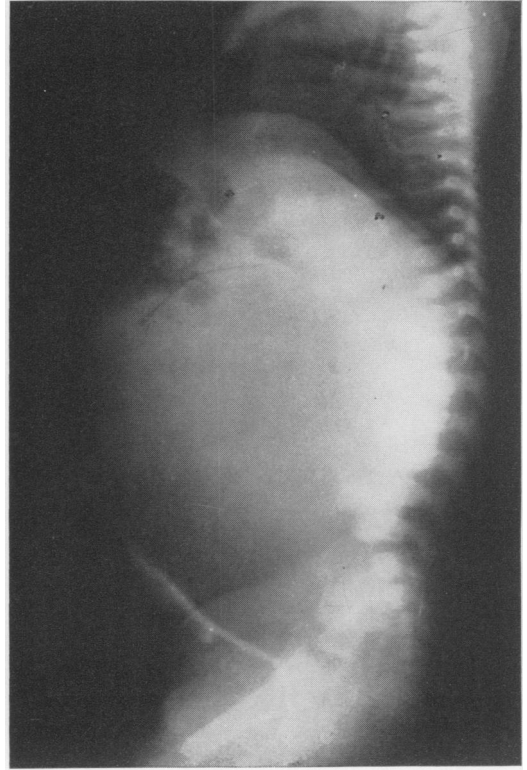


FIG. 2. (Case 1.) Cystogram on admission shows anterior displacement of the bladder by a homogenous lower abdominal mass.

wound and examined. The Fallopian tubes and ovaries were normal, but the uterus was enlarged, measuring 2.0×5.0 cm.

Attention was then turned to the perineum. With a catheter in the urethra, the finger of an assistant in the rectum, and the finger of the surgeon in the lowermost portion of the distended vagina, a probe was forced through the area of

atresia from below upward (Fig. 4). A No. 8 Foley catheter was threaded over the probe, pulled through the new opening, and inflated. The incisions in the vagina and in the abdomen were closed. Culture of the vaginal fluid later revealed *Escherichia* and *paracolon* bacilli.

The vaginal catheter was irrigated daily and changed occasionally, gradually increasing the size

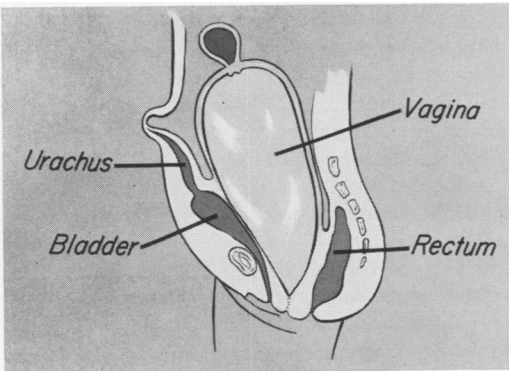


FIG. 3. (Case 1.) The pathologic changes are shown diagrammatically.

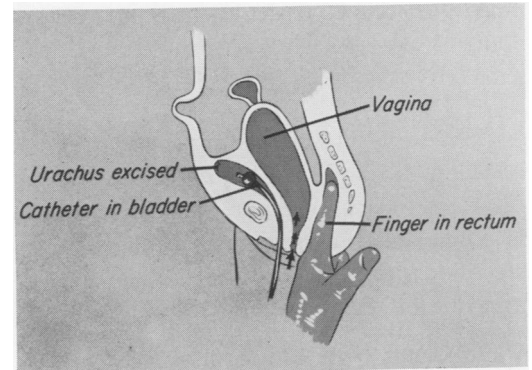


FIG. 4. (Case 1.) Artist's conception of the method of operative approach.

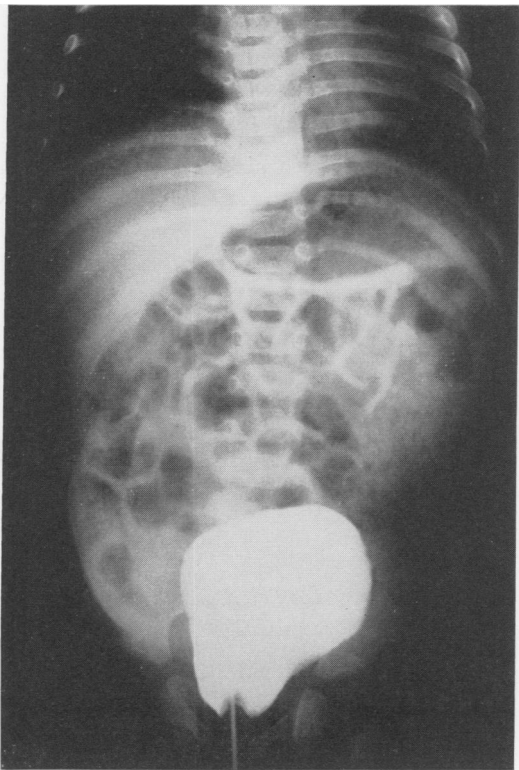


FIG. 5. (Case 1). Vaginogram three weeks after operation shows decrease in the size of the vagina.

to No. 20 French. Excretory urogram two weeks after operation showed improvement in the hydronephrosis, and vaginogram a week later revealed decrease in the size of the vagina (Fig. 5). The patient was discharged two months after operation.

On 9-12-58 the patient was readmitted for repair of an incisional hernia. The vaginal orifice appeared normal and tolerated a No. 18 catheter. Vaginogram showed further decrease in the size of the vagina (Fig. 6). On 4-28-60, nearly two years after operation, the vaginal orifice still appeared normal.

Comment. The preceding case prompted a review of the Charity Hospital records for other similar cases. Since hydrometrocolpos is not listed as a specific diagnosis, all obstructions and cysts of the hymen and vagina in children were reviewed. Two additional cases were found, one with a definite atresia of the vagina and the other with only a pin-point opening in the hymen.

Case 2. J. G., T 59-314602, a five-month-old colored girl, was admitted 1-23-59 with a diagnosis of congestive heart failure. Five days before admission the infant began drawing up her legs and straining as if to expel flatus. The day before admission she was noted to be febrile and dyspneic. The urine had a foul odor and the infant cried when she voided.

On admission temperature 39.8° C., pulse 200, respirations 62, B.P. 95/60. Diffuse rales were heard throughout the chest. Because of a rapid heart rate, no murmur was heard. The liver was four centimeters below the costal margin, but no other organs or masses were felt. The genitalia were described as normal, as was the digital rectal examination, but the urine was noted to be malodorous.

Hgb. 8.0 Gm. WBC 12,300 with 66 per cent neutrophils. Urine was loaded with pus cells and bacteria. The patient was given oxygen, digitalis, and antibiotics. When the heart rate slowed, a systolic murmur was heard over the pulmonic area.

After at least two unsuccessful attempts to find the urethra, a catheterized urine specimen was obtained three days after admission. Excretory urogram showed bilateral hydronephrosis and hydro-ureter, and cystography revealed a normal bladder. The urology consultant noted at cystoscopy that "the bladder is pushed forward for some reason," and on digital examination found a cystic mass anterior to the rectum. Two days later a mass was felt in the lower abdomen.

A gynecology consultant found fullness anterior to the rectum and was unable to locate the vaginal aperture. On 2-16-59 the abdomen was noted to be distended and the urine again offensive.

The abdomen was explored by a surgical consultant on February 20, 1959. In the operative note was described a 5.0-cm. mass between the uterus and rectum extending to the pelvic peritoneum. After 20 cc. of foul cloudy fluid was aspirated, the cyst was opened and the 5.0-mm., fibrous wall was noted to have a smooth lining. The uterus and bladder were intimately adherent to the mass, and both ovaries were enlarged and cystic. The cyst wall was biopsied and the abdomen closed. The presumptive diagnosis was cystic degeneration of an inoperable malignancy.

The cyst fluid was later reported as mucoid, containing many red and white blood cells, cornified epithelial cells, and Doederlein's bacilli but no malignant cells. Culture yielded enterococci and paracolon bacilli. The pathologist reported "stratified squamous and glandular epithelium overlying dense fibromuscular tissue containing a chronic inflammatory infiltrate. This probably represents some developmental anomaly."

Digitals was discontinued on 3-1-59. The following day the infant was febrile and the lower abdominal mass was larger and apparently about to drain spontaneously through the perineum. Repeat excretory urogram showed no change in the hydronephrosis.

On March 3, 1959, a gynecology consultant drained 90 to 120 cc. of pus from the cystic pelvic mass through a stab wound in the area normally occupied by the vaginal orifice. A rubber drain was left in the incision. After drainage, the uterus was easily palpable on rectal examination. During the subsequent four or five weeks, the perineal wound was dilated and the cyst aspirated frequently. Excretory urogram showed continuing hydronephrosis, and hysterectomy was considered.

Finally the dilator was successfully passed into the cyst cavity, following which aspiration of the cyst was no longer necessary. Urogram on 5-3-59 revealed decrease in the dilatation of the pelvis and ureters, and the patient was discharged from the hospital. At the time of discharge, there was serious doubt that she had congenital heart disease. Her condition was still satisfactory on 3-18-60 when she was last seen in the out-patient clinic.

Comment. The final diagnosis in this case was "atresia of the vagina and inflammatory cyst of the lower uterine segment" but gross and microscopic descriptions of the cyst and the subsequent course of the patient leaves little doubt that this is a case of atresia of the lower portion of the vagina with hydrometrocolpos.

Case 3. P. D., T 56-205555, was a two-day-old white infant admitted January 5, 1960 with a "congenital cyst of the hymen." On examination the labia and urethra were normal, but immediately beneath the urethra was a "large (2.0 x 3.0 cm. when full) thin-walled sac with a pin-point opening at its most posterior portion, from which urine drains or can be expressed." No vaginal orifice was present. Excretory urogram was unsatisfactory but a cystogram was normal. A gynecology consultant thought the lesion was a hymeneal cyst and felt that no treatment was indicated. The patient was lost to follow up after one clinic visit at the age of two months.

This case probably represents extreme stenosis of the hymen with accumulation of secretion which slowly escaped from the opening.

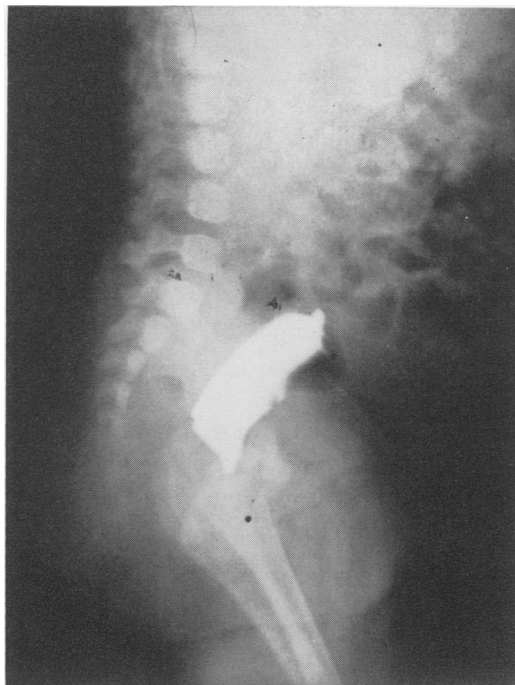


FIG. 6. (Case 1.) Vaginogram four months after operation shows the vagina still larger than normal.

History

Vaginal obstruction due to imperforate hymen with resultant hematocolpos is mentioned in the writings of Hippocrates and Celsus,⁴⁹ but hydrometrocolpos, the comparable condition occurring before the menarche, was apparently not recognized prior to 1856. Godefroy,²⁶ in that year, contributed a clear and concise report of a two-month-old infant with a teaspoonful of viscid mucoid fluid imprisoned behind a 2.0 mm. thick, vascular hymen. Unfamiliar as he was with this abnormality, Godefroy recognized the need for early treatment to avoid the complication of hematocolpos after puberty.

In 1865, Bryck⁹ reported hydrometra with complete absence of the vagina in an 18-year-old girl who died five days after perineal dissection up to the uterus. Hirschsprung,³¹ in 1877, described two cases of imperforate hymen in infants five and 16

months old. Strangely, these patients had only 5.0 and 15 cc. of retained fluid, but von Winckel,⁷² in 1899, found at autopsy in a stillborn infant an atretic vagina containing 180 cc. of fluid.

Textbooks published before 1900^{6, 33, 67} contained discussions of retention of non-menstrual fluid in the genital canal, usually without citing specific instances. Because of the difficulty in obtaining the original articles of cases reported before 1900, no further search of the older literature was made.

In some more recent reports,^{27, 39, 56} details were not recorded. In some instances, hydrometrocolpos was associated with such gross abnormalities of the urogenital system and hindgut that the specimens were considered to be embryologic curiosities without real clinical significance.^{24, 32, 40, 45, 47, 69} None of the above cases are included in the present series.

Embryology

During the second month of fetal life, the Müllerian ducts develop as tubular invaginations of the coelomic mesothelium parallel to the mesonephric ducts.³⁶ The cephalic ends of the invaginations are later modified to become the abdominal ostia of the Fallopian tubes, while the caudal ends (which form the uterus and vagina) fuse in the midline and make contact with the urogenital sinus. The distal portion of the fused Müllerian ducts, temporarily completely occluded by a solid cord of cells, is the Müllerian tubercle, the caudal end of which becomes the hymen.⁵⁰

Failure of degeneration of the epithelial plate in the Müllerian tubercle results in imperforate hymen, and persistence of a portion of the solid cord of cells in the fused Müllerian ducts above this level results in atresia of the vagina. Presumably a transverse septum of the vagina would result from incomplete coalescence of the vacuoles which develop as the epithelial cord begins to degenerate.

Pathologic Physiology

The maternal hormones profoundly affect the reproductive tract of the female infant both in utero and during the early neonatal period.²⁰ The newborn female infant, in addition to having enlargement of the breasts, usually displays swollen vulva and a slight mucoid leukorrhea with a low pH and many Doederlein's bacilli. The vagina has thick stratified squamous epithelium consisting of an active basal layer and 20 to 30 layers of large vacuolated cells containing abundant glycogen. These features are characteristic of the adult vagina.

By the age of a month, however, the breast enlargement has disappeared, and the vaginal secretion has become scanty and alkaline. The epithelium is thin, the individual cells small and devoid of glycogen, and the basal layer comparatively inactive.¹⁹

The retained fluid in hydrometrocolpos is usually acid and serous or mucoid with large numbers of desquamated epithelial cells and leukocytes. Rarely, hydrohematocolpos will develop in the newborn infant with estrogen-withdrawal bleeding from the uterus. Secondary infection of the vaginal fluid, usually with colonic organisms, is not uncommon.

Both estrogenic stimulation and vaginal obstruction must coexist before hydrometrocolpos will develop. If the fetal reproductive tract is sufficiently stimulated by maternal hormones, the newborn infant with vaginal obstruction will develop hydrometrocolpos. If there is a low level of maternal hormones, however, the obstruction will usually remain unnoticed until puberty when the hormones of the patient will produce secretion of the cervical and/or uterine glands. It is probably that in most patients, hydrometrocolpos is not symptomatic until hematocolpos is superimposed at the time of the menarche.

Of the 62 patients in the collected series, there were 48 infants aged three months or

less (two of whom had hydrohematocolpos), one infant of five months, and one of seven months who was admitted *in extremis* and died before operation could be undertaken. The prepubertal group includes eight patients aged 12 to 15 years and one girl of ten years. Of the three *middle-aged* children, only one (aged seven years) was uncomplicated. The others were a two-year-old girl who required excision of a previously incised hymen, and a six-year-old girl with leukorrhea who was found to have a pin-point opening in the hymen.

Pathologic Anatomy

Most cases of hydrometrocolpos are associated with an imperforate hymen, which forms a thin translucent membrane bulging between the labia (Fig. 7A). Occasionally the hymen is abnormally thickened and scarred, and rarely other abnormalities are noted (i.e., mucosal bridge across the hymen, or adhesions of the labia to the hymen). In the collected series of 62 patients, 40 had imperforate hymen—31 with a bulging membrane and nine without a description of the perineum. A pin-point opening in the hymen was found in a newborn in the present report and in one patient (aged six years) who had previously had episodes of profuse leukorrhea. (An additional patient with a history of leukorrhea is presumed to have sealed a small opening in the hymen.)

A bulging membrane protruding through the vulva is not always an imperforate hymen, however. In some cases a transverse septum higher in the vagina (Fig. 7B) will be seen to protrude through a normally perforated hymen, apparently representing a congenital diaphragm similar to those seen in the gastro-intestinal tract. Obstruction may be caused by atresia of the vagina (Fig. 7C, D), usually in the lower portion but occasionally extensive, involving most or all of the vagina. Thirteen of the 62 patients had atresia of the vagina, in the lower half or third in 11 and a few milli-

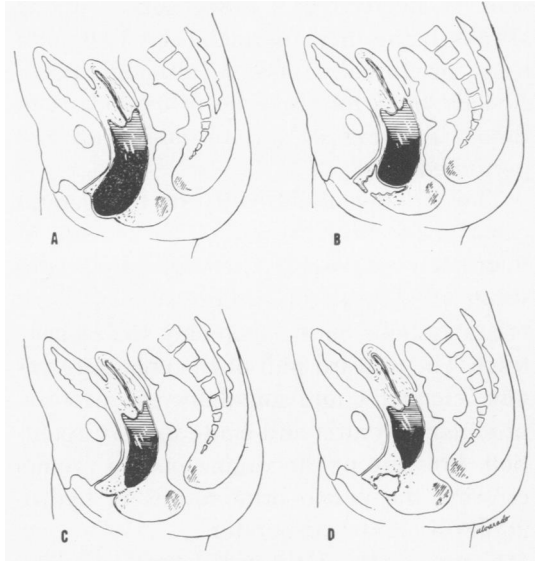


FIG. 7A. Imperforate hymen. B. Transverse septum of the vagina. C and D. Low and high atresia of the vagina.

meters to a centimeter behind a normal hymen in two. Transverse septum occurred in seven patients, in two of whom the membrane bulged through a normal hymen. It is possible that other patients with a protruding membrane were incorrectly assumed to have an imperforate hymen.

In atresia of the vagina, the appearance of the external genitalia differs markedly from that seen with imperforate hymen. Instead of a bulging membrane protruding from the labia, with unusual prominence of the vulva and perineum, the area normally occupied by the vaginal orifice may be retracted upward into the pelvis—the result of the enlarging upper vagina escaping from the small pelvis into the more roomy abdominal cavity above. In these cases, the abnormality will not be detected without a careful examination of the genitalia.

Regardless of the variable anatomy of the vaginal outlet, the changes in the upper vagina and uterus are distinctive. The upper vagina becomes enormously distended, usually producing a palpable abdominal mass arising from the pelvis. The uterus, with its less distensible, thick muscular

wall, is involved to a lesser degree but is always larger than normal. The Fallopian tubes are usually normal, although occasionally they, too, may be distended, even rarely allowing escape of fluid into the peritoneum.

The striking abnormality of the genital canal is the primary pathologic change in hydrometrocolpos, but complications develop as a result of compression of other organ systems, most commonly the urinary tract. The upward pull of the enlarging vagina elongates and angulates the urethra, producing dysuria and acute urinary retention. Pressure of the vagina on the ureters crossing the pelvic brim results in hydronephrosis and hydroureter.

Compression of the vena cava and iliac vessels will cause cyanosis, edema, and ecchymosis of the perineum, lower extremities, and abdominal wall. The rectum is less commonly involved, but constipation, ribbon stools, and actual intestinal obstruction may complicate hydrometrocolpos. Occasionally respiratory embarrassment will accompany the severe abdominal distention resulting from the enlargement of the vagina, urinary retention, and/or intestinal obstruction.

As would be expected, other anomalies are occasionally seen with hydrometrocolpos. In the present series, four patients had imperforate anus, one also with atresia of the esophagus and duodenum, and two also with bicornate uterus and double vagina. An additional patient had duplication of the uterus and vagina, making a total of three with this anomaly. Each of the following abnormalities occurred once: bifid clitoris, congenital urethral membrane, double ureter, and ureteral stenosis.

Signs and Symptoms

Uncomplicated hydrometrocolpos is probably asymptomatic, the diagnosis being made only after accidental discovery of a bulging membrane. The early symptoms attributed to this condition are nonspecific

indications of discomfort followed by urinary, venous, or intestinal obstruction, respiratory distress, or superimposed infection of the urinary tract or of the fluid retained in the vagina. Examination of the abdomen reveals a tensely cystic, rounded mass arising from the pelvis and occasionally reaching as high as the costal margin. The tumor may seem lobulated because of the distended bladder anteriorly and the moderately enlarged uterus surmounting the vagina. Rectal examination reveals the pelvic component of the mass.

On inspection of the genitalia, the translucent bulge of an imperforate hymen will be seen to increase in size when the infant cries or when pressure is exerted on the abdominal mass. In vaginal atresia, the upward pull of the enlarging vagina rising out of the pelvis may retract the atretic lower portion of the vagina up into the pelvis and make examination difficult. If a major portion of the vagina is absent, the external genitalia may seem quite normal, and the diagnosis will be missed unless the vaginal orifice is deliberately sought.

In this series of 62 patients, obstruction occurred in the urinary tract alone in 21, in the urinary tract and venous system in seven, and in the urinary and intestinal tracts in five. Urinary, venous, and intestinal obstruction occurred in two patients, and one infant had respiratory distress associated with urinary and venous obstruction. It is interesting that all 36 patients with evidence of compression had involvement of the urinary tract, either alone or in the combination with other organ systems. Abdominal distention was reported in 23 patients, but 33 were noted to have an abdominal mass and five, a mass on rectal examination.

Diagnosis and Treatment

The diagnosis of hydrometrocolpos usually can be made by physical examination alone and confirmed by roentgenologic studies. Plain films will show the small

intestine displaced into the epigastrium by a rounded homogenous mass in the lower abdomen. Urogram will demonstrate anterior and superior displacement of the bladder and, possibly, hydronephrosis and hydroureter. When a bulging membrane can be visualized clearly, aspiration of some of the contained fluid and injection of a water-soluble radio-opaque material will outline the distended vagina and uterus.

The presence of a lower abdominal mass in a female infant or child should always arouse suspicion of hydrometrocolpos and indicate careful examination of the genitalia. In the absence of clearly demonstrable patency of the vagina, the mass should be considered to be vagina until proven otherwise.

If the diagnosis is not made before laparotomy is undertaken, identification of the uterus and Fallopian tubes surmounting the cystic mass will make the diagnosis certain. No resection should be attempted, because of a presumptive diagnosis of congenital, inflammatory, or neoplastic cyst, until the patency of the genital canal has been demonstrated with certainty.

Therapy is directed toward permanent relief of the obstruction of the vaginal outlet. A bulging membrane in an infant with imperforate hymen or transverse septum of the vagina may be incised without anesthesia, but if the hymen is thickened, the obstruction recurrent, or the patient an adolescent, excision is probably preferable. If the atretic lower portion of the vagina has been retracted up into the pelvis, it may be desirable to open the vagina through a laparotomy incision to avoid damage to the urethra, bladder, and rectum. In all cases, it is desirable to maintain patency of the opening by use of a drain and/or repeated dilatation.

In discussing treatment in the collected series, the patients can conveniently be divided into three groups, depending on whether the diagnosis and treatment were

accomplished with or without laparotomy or the condition discovered at autopsy.

Group 1. Diagnosis and/or treatment without laparotomy. Of the 30 patients with imperforate hymen and three with a transverse septum of the vagina, 24 were less than three months old, the remainder being two, seven, and ten to 15 years old. In 29 of these patients, the obstruction was successfully relieved by a single linear or cruciate incision or excision, occasionally following preliminary aspiration. In two patients, the hymen was ruptured spontaneously or with a catheter. A second incision was required in one infant, and excision was needed in a two-year-old girl whose imperforate hymen had previously been incised twice.

Even though a bulging imperforate hymen was noted at the time of the initial examination in four newborn infants, definitive therapy was delayed three weeks to three months, usually until urinary and venous obstruction developed. A newborn infant in the present report received no treatment for retention of fluid behind a hymen with only a pin-point opening.

Group 2. Diagnosis and/or treatment by laparotomy. This group includes three older girls with imperforate hymen (6, 12 and 14 years old) and 15 infants (two days to five months old), ten of whom had atresia of the vagina. Four of the infants died.

Five infants were subjected to panhysterectomy. Three of these patients had atresia of vagina, but two had a bulging imperforate hymen, one of which was noted before laparotomy. In this last patient, 300 cc. of sterile fluid was aspirated from the vagina at the time of laparotomy at the age of seven days, and fluid which accumulated later was removed by abdominal paracentesis. Sixteen days after operation, dyspnea, cyanosis, and urinary retention recurred, and a hysterectomy was done, removing a vagina containing 500 cc. of *nauseating* fluid.

TABLE 1

Case	Author, Year	Age	Volume Fluid, cc.	Infect.	Site of Obst.	Mass	Treatment	Other Obstruc.	Other Anomaly	Comment
1.	Vitrac 1900	NB	195		Hymen	Yes	None	Urinary Venous		Died urinary infection age 33 days.
2.	Bunzel 1900	1 da.	?		Hymen		None			Ruptured spontaneously.
3.	Bulius 1901	NB	30		Septum Vagina		Incision	Urinary Intestinal		Hydrohematocolpos.
4.	Budin 1903	Infant	?		Hymen		Incision			
5.	Otto 1903	NB	?		Hymen		Incision			Hymen 1 millimeter thick.
6.	Commandeur 1904	1 da.	100		Hymen		Incision			Mucosal bridge from hymen to fourchette.
7.	Cranwell 1905	1 mo.	400		Septum Vagina	Yes	Para-anal incision	Urinary Venous Intestinal		Died. Vaginal septum few millimeters above hymen.
8.	Haase 1911	6 wk.	20		Hymen		Excision			
9.	Bjerrum 1915	7 wk.	800	Yes	Hymen		Incision			
10.	Spencer, H. 1916	11 wk.	4		Hymen		Excision			
11.	Wiener 1917	12 yr.	900		Hymen	Yes	Excision	Urinary		
12.	Henrich 1920	2 wk.	150		Hymen		Incision	Urinary Intestinal		
13.	Tierny* 1927	3 mo.	600	Yes	Septum Vagina	Yes	Hysterectomy	Urinary		Marsupialization lower vagina. Septum vagina 1 cm. above hymen. Vulva normal.
14.	Dahl 1927	12 yr.	300		Hymen	Yes	Incision	Urinary		No menses 3 mo. later.
15.	Rocher 1932	2 da.	60	Yes	Hymen		Incision X2			Wineglassful of infected pus and gas under pressure.
16.	Sousa 1934	25 da.	"Huge"		Hymen		Incision	Urinary		
17.	Melodia 1935	7 yr.	300	Yes	Hymen		Incision	Urinary		Pelvic mass per rectum.
18.	Superbi 1935	1 da.	"egg"		Hymen		None			Died. Neonatal death. Meconium peritonitis.
19.	Guilleminet 1938	6 yr.	4 X6 cm.	Yes	Hymen		Laparotomy Dilated	Urinary Intestinal		Pin-point opening in hymen, leucorrhea. Dx. after laparotomy
20.	Kereszturi 1940	8 wk.	60		Hymen		Laparotomy Incision	Urinary Intestinal		Dx. at laparotomy. Pelvic mass per rectum.
21.	Mahoney 1940	1 wk.	"Ozs."		Septum Vagina	Yes	Incision			Bulging mass 1 cm. above hymen.
22.	Mahoney 1940	3 wk.	"Large"		Hymen	Yes	Hysterectomy	Urinary		Panhysterectomy, later incision hymen.
23.	Mahoney 1940	NB	30		Septum Vagina		None		Atresia duod., esoph., anus	Died p.o. duod. & anal atresia. Autopsy dx. vagina.
24.	Althoff 1941	14 yr.	2,250		Hymen	Yes	Laparotomy Excision			Dx. at laparotomy. Amenorrheic post-op.
25.	Bowen 1941	12 yr.	2,000		Hymen	Yes	Incision			Menarche 5 mo. post-op. Normal twin.
26.	Doyie 1942	10 yr.	"Much"		Hymen		Excision	Urinary		Pelvic mass per rectum.
27.	Doyle 1942	2 yr.	?		Hymen		Excision		Urethral membrane	Previous incision X2.
28.	Richardson 1942	2 mo.	1,350	Yes	Atresia Vagina	Yes	Abd. paracentesis	Urinary Venous		Died peritonitis after abd. paracentesis of vagina.

* Also reported by Brunet.

TABLE 1—(Continued)

Case	Author, Year	Age	Volume Fluid, cc.	Infect.	Site of Obst.	Mass	Treatment	Other Obstruc.	Other Anomaly	Comment
29.	Rosenblatt 1943	17 da.	210		Hymen	Yes	Incision	Urinary		
30.	Morris 1945	7 wk.	5 cm.		Hymen		Laparotomy Incision	Urinary Venous Intestinal		Dx. at laparotomy. Died 34 da. post-op.
31.	Leopold 1947	12 da.	100		Hymen		Laparotomy Incision	Urinary Venous		Pelvic mass per rectum. Dx. at laparotomy. Died p.o. 5.
32.	Maliphant 1948	14 yr.	850		Septum Vagina		Excision	Urinary		Menarche 5 mo. post-op. Retrohymeneal membrane.
33.	Schell 1948	NB	400		Hymen	Yes	Incision	Urinary		Hymen 2 mm. thick.
34.	Ruiz 1949	13 yr.	200		Hymen		Incision			Menarche 15 da. p.o. Previous leucorrhea.
35.	Sen 1949	4 da.	32		Hymen	Yes	Incision	Urinary	Imperforate anus	Bulging hymen noted at 4 da., incised at 24 da.
36.	Davis 1950	NB	400		Atresia Vagina	Yes	Hysterectomy		Double uterus and vagina Imperforate anus	Colostomy and hysterectomy.
37.	Campbell 1951	1 da.	18		Hymen		Incision			Premature, 3 lb., 9 oz.
38.	Campbell 1951	8 wk.	90	Yes	Hymen	Yes	Incision	Urinary		
39.	Antell 1952	11 da.	150		Hymen		Incision	Urinary Venous		
40.	Klostermyer 1952	2 mo.	90	Yes	Hymen	Yes	Incision	Urinary		
41.	Lide 1952	NB	7 X 8		Septum Vagina	Yes	None	Urinary	Double uterus	Stillborn, dx. at autopsy.
42.	Burger 1954	7 da.	500	Yes	Hymen	Yes	Hysterectomy	Urinary Venous Respiratory		Bulging hymen noted pre-op. Laparotomy at 7 da., no dx. Paracentesis at 19 da. Hysterectomy at 23 da.
43.	Silva 1954	NB	200		Hymen	Yes	None	Urinary		Stillborn, dx. at autopsy.
44.	Fèvre 1956	12 yr.	2,000	Yes	Hymen	Yes	Laparotomy Incision	Urinary		Laparotomy infancy "malignancy" Laparotomy 9 yr. "normal" Laparotomy 12 yr., dx. made. Menarche few months later.
45.	Stojimirovic 1956	1 da.	150		Atresia Vagina		Puncture	Urinary	Imperforate anus, double uterus & vag.	Died p.o. 5, ano-plasty and puncture vagina.
46.	Stojimirovic 1956	2 da.	?		Atresia Vagina	Yes	Hysterectomy		Ureteral stenosis	Died. Fetal peritonitis.
47.	Valledor 1956	7 mo.	500		Atresia Vagina	Yes	None	Urinary Intestinal	Double ureter	Died before operation.
48.	Valledor 1956	NB	?		Hymen	Yes	Ruptured			Bulging hymen ruptured with catheter.
49.	Whittlesey 1956	NB	400		Atresia Vagina	Yes	Laparotomy Incision	Urinary		Dx. pre-op. Laparotomy for repair.
50.	Whittlesey 1956	NB	400		Atresia Vagina	Yes	Laparotomy Incision			Dx. pre-op. Laparotomy for repair.
51.	Brews 1957	15 yr.	40		Hymen		Incision	Urinary		Menarche 5 mo. post-op.
52.	Fèvre 1957	7 da.	little		Hymen		Incision			Incision at 27 days.
53.	Fèvre 1957	1 da.	"Much"	Yes	Hymen		Incision		Bifid clitoris	
54.	Genevet 1957	6 da.	"Orange"		Hymen	Yes	Incision			

TABLE 1—(Continued)

Case	Author, Year	Age	Volume Fluid, cc.	Infect.	Site of Obst.	Mass	Treatment	Other Obstruc.	Other Anomaly	Comment
55.	Rea 1957	5 da.	100		Atresia Vagina	Yes	Laparotomy Ruptured			Dx. at laparotomy, atresia 1 cm. above hymen ruptured with catheter. Died p.o. 2 mo.
56.	Beyer 1959	NB	180		Atresia Vagina	Yes	Laparotomy Incision	Urinary Venous		Laparotomy at 1 da., no dx. Abdomino-perineal repair at 4 mo.
57.	Marion 1959	NB	150	Yes	Hymen	Yes	Incision	Urinary Venous		Bulging hymen noted at birth, incised at 3 mo.
58.	Notter 1959	11 da.	350	Yes	Atresia Vagina	Yes	Laparotomy Incision	Urinary Venous	Malrotation	Dx. at laparotomy. Hydrohematocolpos.
59.	Shinbein 1959	NB	240		Atresia Vagina	Yes	None	Venous		Died. Neonatal death, respiratory. Dx. at autopsy.
60.	Spencer 1962	3 mo.	800	Yes	Atresia Vagina	Yes	Laparotomy Incision	Urinary		Dx. pre-op. laparotomy for repair.
61.	Spencer 1962	5 mo.	100	Yes	Atresia Vagina	Yes	Laparotomy Incision	Urinary	Heart?	No dx. at laparotomy at 6 mo. Perineal puncture at 7 mo.
62.	Spencer 1962	2 da.	?		Hymen		None			Pin-point opening hymen, not treated.

In addition to the five infants who had hysterectomy, two other infants were not diagnosed correctly at laparotomy. In these patients, the cystic vagina was only aspirated at laparotomy. When the abdominal tumor recurred in one patient, the mother refused operation, but four months later gave permission to repair the atretic vagina by an abdomino-perineal approach. In the other infant, hysterectomy was being considered because of continued severe hydronephrosis when, fortunately, the infected vaginal fluid began to bulge the perineum. Incision of the vaginal atresia, repeated aspiration and dilatation were finally successful in relieving the pressure on the ureters in the pelvis.

The two older girls were relieved of symptoms following excision of a bulging hymen after hydrometrocolpos was diagnosed at laparotomy. In one of these patients, abdominal exploration in early infancy had revealed an abdominal tumor presumed to be malignant. When an incisional hernia was repaired nine years later, the uterus, tubes, and ovaries were said to be normal. At 12 years, urinary retention and an abdominal tumor indicated a third

laparotomy, following which a bulging hymen was incised and two liters of pus evacuated. In a six-year-old girl who had abdominal pain, urinary retention and leucorrhea, laparotomy yielded no diagnosis. When the leucorrhea persisted, perineal examination revealed a pin-point opening in the hymen and a pelvic mass. All symptoms disappeared when the opening was dilated.

Group 3. Diagnosis at autopsy.

These ten patients include four stillborn and neonatal deaths and two additional patients who probably died of other anomalies—one who had been operated upon for duodenal atresia and imperforate anus, and another in whom the dilated vagina was accidentally punctured during operation for imperforate anus.

The remaining four patients in this group are presumed to have died of untreated or improperly treated hydrometrocolpos. One infant, who was noted shortly after birth to have a bulging hymen and an abdominal mass, died at the age of a month after only daily catheterization for urinary retention with hydronephrosis. In a two-month-old infant with a huge cystic abdominal mass,

abdominal paracentesis yielded 45 ounces of infected fluid and resulted in death due to peritonitis. Autopsy revealed atresia of the vagina and bilateral hydronephrosis.

The third patient, one month old, died with urinary and intestinal obstruction after a para-anal incision into a vagina occluded by a transverse septum a few millimeters above the hymen. The fourth patient was a seven-months-old girl who died with hydronephrosis and an abdominal tumor before operation could be accomplished. At autopsy 500 cc. of sterile fluid was found in a vagina obstructed by atresia of the lower portion.

Summary and Conclusions

The mortality of hydrometrocolpos in 44 infants (one day to seven months old) was 18 per cent. (This excludes four stillborn and neonatal deaths and two deaths presumed to be due to multiple anomalies.) The eight deaths in these 44 infants followed laparotomy (four), neglect (three) or inadequate treatment (one). Simple incision or excision of an obstructing membrane resulted in no deaths, no complications, and only two easily treated recurrences. There were no deaths in 12 older girls aged two to 15 years.

It should be emphasized that laparotomy is indicated in an occasional case of hydrometrocolpos. Some patients with atresia or transverse septum of the vagina require treatment by an abdomino-perineal approach to avoid injury to the urethra, bladder, and rectum, and the relative infrequency of this condition makes it inevitable that a bulging hymen will occasionally escape detection or proper evaluation before operation. However, panhysterectomy for a simple benign vaginal obstruction in an infant is a tragic and avoidable error.

Acknowledgment

The authors wish to acknowledge indebtedness to Mrs. Dorthy Liptak for her untiring and successful search for the original articles for the entire bibliography, to Miss Marjorie Le Doux for

translating the French, and to Mrs. Margot Dyess for translating the German.

References

1. Althoff, F.: Ein Ungewöhnlicher Fall von Serokolpos und Serometra bei Atresia hymenalis. *Zentralbl. f. Gynak.*, **65**:1398, 1941.
2. Antell, L.: Hydrocolpos in Infancy and Childhood. *Pediatrics*, **10**:306, 1952.
3. Beyer, P., G. Apprill and M. L. Klein: Hydroméetrocolpos Chez un Nouveau-né. *Arch. Franç. Péd.*, **16**:1274, 1959.
4. Bjerrum, S.: Atresia hymenalis og Pyokolpos hos Pattebarn. *Ugesk. f. Laeger.*, **77**:407, 1915.
5. Bowen, F. H., Imperforate Hymen before the Menarche with Mucocolpos and Mucometrium. *Am. J. Obst. & Gynec.*, **42**:144, 1941.
6. Briesky: Die Krankheiten der Vagina. In Billroth, T., *Handbuch der Frauenkrankheiten*. Ferdinand Enke, Stuttgart, 1877-1880, p. 18.
7. Brews, R. A.: Some Clinical Aspects of Developmental Anomalies of the Female Genitourinary Tract. *Proc. Roy. Soc. Med.*, **50**:199, 1957.
8. Brunet, A.: Contribution à l'Etude des Cloisons Congénitales du Vagin par Diaphragme Transversal et leur Traitement Chirurgical. Thèse pour le Doctorat en Médecine Paris, 1930.
9. Bryck, A.: Zur Diagnose der Atresien weiblicher Geschlechtsorgane. *Med. Wschr.*, p. 209-213, 261-264, 279-283, 295-299, Feb. 15, 1865.
10. Budin, M. P.: Imperforation de l'Hymen. *Bull. Soc. d'Obstét. et Gynec. Paris*, **6**:12, 1903.
11. Bulius: Über Atresia vaginalis congenita. *Verhandl. d. deutsch gesellsch. f. gynäk.*, Leipzig, **9**:501, 1901.
12. Bunzel, R.: Atresia hymenalis mit Schleimretention bei einem Neugeborenen. *Prag. Med. Wschr.*, **25**:349, 1900.
13. Burger, P., P. Buck, M. Carloz and B. Winisdoerffer: Hydrocolpos Congénital. *Soc. Gynec. et D'Obstét. Strasbourg*, **6**:113, 1954.
14. Campbell, M.: *Clinical Pediatric Urology*, Philadelphia, W. B. Saunders Company, 1951, p. 342.
15. Commandeur, M.: Imperforation de l'Hymen avec Hydrocolpos; Incision. Évacuation de 100 gr. de Liquide d'Aspect Laiteux; Guérison. *Bull. Soc. D'Obstét. et Gynec. Paris*, **7**:54, 1904.
16. Cranwell, D. J.: Hydrocolpos Congénital. *Rev. Gynec. et Chir. Abd.*, **9**:635, 1905.

17. vom Dahl, P.: Ein Fall von Pyocolpos infolge Atresia hymenalis. *Zentralbl. f. Gynäk.*, **51**: 433, 1927.
18. Davis, C., Jr. and E. H. Fell: Double Hydrometrocolpos and Imperforate Anus in a Newborn Infant. *A. M. A. Am. J. Dis. Child.*, **80**:79, 1950.
19. Davis, M. E. and S. A. Pearl: Biology of the Human Vagina in Pregnancy. *Am. J. Obst. & Gynec.*, **35**:77, 1938.
20. Dobszay, L.: Hormonal Reactions of Pregnancy. *A. M. A. Am. J. Dis. Child.*, **56**:1280, 1938.
21. Doyle, J. C.: Imperforate Hymen with and without Hematocolpos. *California & West. Med.*, **56**:242, 1942.
22. Fèvre, M.: L'Hydrocolpos et L'hydro-pyocolpos. Ses Accidents Néonataux et Prépubertaires. *Arch. Franç. Péd.*, **13**:569, 1956.
23. Fèvre, M.: L'Hydrocolpos et ses Accidents. *Bull. Acad. Nat. de Méd. Paris*, **141**:619, 1957.
24. Fromme: Ein weiterer Beitrag zur Lehre von dem Gynatresien. *Ztschr. f. Geburtsh. u. Gynäk.*, **54**:482, 1905.
25. Genevet, L., A. Marzet and M. Lagrange: À Propos d'un Cas d'Hydrocolpos du Nouveau-né. *Pédiatrie*, **12**:816, 1957.
26. Godefroy, M.: Imperforation de la Membrane Hymen. *Lancette Franc., Gaz. d. Hop.*, **29**: 567, 1856.
27. Gross, R. E.: *The Surgery of Infancy and Childhood*. Philadelphia, W. B. Saunders Company, 1953, p. 494.
28. Guilleminet and R. Gayet: Pyocolpos chez une Enfant de 6 Ans, Révélé par une Rétenion d'urin; Guérison par Dilatation de l'Hymen. *Lyon Méd.*, **161**:561, 1938.
29. Haase: Atresia hymenalis beim Neugeborenen (Case presentation). *Zentralbl. f. Gynäk.*, **35**:455, 1911.
30. Henrich, O.: Beitrag zur Gynatresia hymenalis congenita. *Zentralbl. f. Gynäk.*, **2**:1283, 1920.
31. Hirschsprung, H.: Nogle Tilfaelde af medfødt Atresia hymenalis, iagttagne hos Børn. *Gynaek. og Obst. Medd. Kjobenh.* part 3, **1**:42, 1877.
32. Ihl, O.: Eine seltene Missbildung des Urogenitalsystem eines totgeborenen Mädchens. *Ztschr. f. Geburtsh. u. Gynäk.*, **55**:373, 1905.
33. Kelly, H. A.: *Operative Gynecology*. New York, D. Appleton & Co., 1900, Vol. 1, p. 236.
34. Kereszturi, C.: Imperforate Hymen Causing Hydrocolpos, Hydroureter, Hydronephrosis, and Pyuria; Its Occurrence in an Infant. *A. M. A. Am. J. Dis. Child.*, **59**:1290, 1940.
35. Klostermyer, L. L. and J. J. Thompson: Radiographic Diagnosis of Hydrocolpos in Infants. *Radiology*, **58**:100, 1952.
36. Koff, A. K.: Development of the Vagina in the Human Fetus. In *Carnegie Institute of Washington, Contributions to Embryology* No. 140, **24**:61, 1933.
37. Leopold, J. S.: Imperforate Hymen Resulting in Hydrometrocolpos and Hematocolpos. *J. Mt. Sinai Hosp.*, **14**:467, 1947-48.
38. Lide, T. N. and W. G. Coker: Congenital Hydrometrocolpos, Review of the Literature and Report of a Case with Uterus Duplex and Incomplete Septate Vagina. *Am. J. Obst. & Gynec.*, **64**:1275, 1952.
39. Longino, L. A. and L. W. Martin: Abdominal Masses in the Newborn Infant. *Pediatrics*, **21**:596, 1958.
40. Lüer, K.: Ueber einen Fall von congenitaler Scheidenatresia mit Cystokolposbildung bei völligem Mangel der Urethra und Blase, sowie der Portio, Cervix, und des Corpus uteri. *Inaugural-Dissertation, Kgl. Hof. -u. Universitäts-Buchdruckerei von Dr. C. Wolf & Sohn, München*, 1903.
41. Mahoney, P. J. and J. W. Chamberlain: Hydrometrocolpos in Infancy; Congenital Atresia of the Vagina with Abnormally Abundant Cervical Secretions. *J. Pediat.*, **17**:772, 1940.
42. Maliphant, R. G.: Gynatresia; Report of three Uncommon Clinical Types. *Brit. M. J.*, **2**:555, 1948.
43. Marion, J., P. Monnet, J. Dubois and Thevenson: À Propos d'un Cas d'Hydrocolpos du Nouveau-né. *Pédiatrie*, **14**:72, 1959; also *Lyon Chir.*, **56**:130, 1960, and *Arch. Franç. Péd.*, **16**:384, 1959.
44. Melodia, G.: Piocolpo in una Bambina di 7 Anni con Imene Imperforato. *Méd. Infant., Roma*, **6**:132, 1935.
45. Moore, T. C. and E. A. Lawrence: Congenital Malformations of the Rectum and Anus. *Surg., Gynec. & Obst.*, **95**:281, 1952.
46. Morris, Paul, Hydrometrocolpos in Infancy—a Cause of Urinary Retention, Intestinal Obstruction and Edema of the Lower Extremities. *Am. J. M. Sc.*, **210**:751, 1945.
47. Nordenfelt, O.: Two Cases of Cloacal Formation with Congenital Hydrometra and Hydrocolpos. *Acta Obst. et Gynec. Scandinav.*, **5**:1, 1926.
48. Notter, A. and J. Chabal: L'Hydrohématocolpos du Nouveau-né Problème de la Menstruation du Foetus in Utero. *Gynec. et Obstet.*, **58**:538, 1959.

49. Otto, H.: Ein Fall von Atresia hymenalis congenita, Inaugural-dissertation. Berlin, Gustav Schade, 1903.
50. Patten, B. M.: Human Embryology. Philadelphia, The Blakiston Company, 1946.
51. Rea, E. and H. F. Theron: Hydrometrocolpos, South African M. J., 31:1013, 1957.
52. Richardson, G. O. and G. A. Smart: Hydrocolpos in an Infant. Arch. Dis. Childhood, 17:56, 1942.
53. Rocher, H. L. and Balard: Pyocolpos Gazeux à Coli-bacille chez un Nouveau-né. Bull. Soc. Pédiat. de Paris, 30:208, 1932.
54. Rosenblatt, M. S. and P. V. Woolley, Jr.: Hydrometrocolpos in Infancy. Ann. Surg., 117:635, 1943.
55. Ruiz, V. and G. DiPaola: Hidrocolpos. Obst. y Ginec. Latino-Am., 7:144, 1949.
56. Schauffler, G. C.: Pediatric Gynecology. Chicago, The Yearbook Publishers Inc., 1953, p. 66-67.
57. Schell, F. R.: Report of a Case of Hydrometrocolpos—a Congenital Dilatation of the Female Genital Tract. Radiology, 51:252, 1948.
58. Sen, N. C.: Hydrocolpos. Lancet, 2:991, 1949.
59. Shinbein, A. and E. H. Albano: Hydrometrocolpos; Report of a Case. Obst. & Gynec., 14:242, 1959.
60. da Silva, L. M.: Hidrocolpos em Nati-morto. Rev. Gynec. e d'Obstet., 2:436, 1954.
61. de Sousa, C. S.: Manifestations Rares d'une Imperforation de l'Hymen. Arch. Méd. Enfants, 37:721, 1934.
62. Spencer, H. R.: Imperforate Hymen in a Baby. Lancet, 1:823, 1916.
63. Stojimirovic, I.: Hidrometrokolpos novorodencita. Acta Chir. Iugoslavica, 3:175, 1956.
64. Superbi, C.: Di un Caso di Peritonite Fetale Associata a Idocolpo. Clin. Obstet., 37:332, 1935.
65. Tierny, A.: Volumineux Pyocolpos chez un Bébé de Trois Mois. Soc. de Chir. Bull. et Mem., 53:1420, 1927.
66. Valledor, T., C. Salanowsky, R. M. Cuétara, L. Barbolla, E. Torroella and A. G. Palacio: Hidrocolpos en la infancia. Rev. Cubana Pediat., 28:707, 1956.
67. Viet, J.: Erkrankungen der Vagina. In Handbuch der Gynäkologie, J. F. Bergman, Weisbaden, 1897, vol. 1., p. 287.
68. Vitrac, Jr.: Hydroméetrocolpos Congénital par Imperforation de l'Hymen. Rev. Mens. de Gynéc. Bordeaux, 2:110, 1900.
69. Wagner, V. G. A.: Präparat einer Missbildung (Case Presentation). Zentralbl. f. Gynäk., 34:793, 1910.
70. Whittlesey, R. H., M. Atik and J. C. Jones: Atresia of the Vagina in Infancy. Pediatrics, 18:260, 1956.
71. Weiner, S.: Imperforate Hymen; Large Sero-colpos in a Child. Am. J. Obst. & Dis. Women and Children, 75:398, 1917.
72. von Winckel, F.: Über die Eintheilung, Entstehung, und Benennung der Bildungshemmungen der weiblichen Sexualorgane. Samml. Klin. Vortr., 251/252:1523, 1899.