

Treatment of Post-Catheterization Arterial Injuries: *

Use of Survey Plethysmography

JOHN W. BELL, M.D.**

From the Surgical Service, Veterans Administration Hospital and the Department of Surgery, University of Washington School of Medicine, Seattle, Washington

THROMBOSIS of a peripheral artery following simple needle puncture or catheterization fortunately is an uncommon problem. Such injury may result from intimal trauma or be associated with a perivascular hematoma. Conservative treatment of post-catheterization arterial trauma is based upon demonstrated viability of the limb. Progressive signs and symptoms of circulatory insufficiency as with other types of arterial damage indicate the need for operative intervention.¹⁸

We have recently had the occasion to treat three patients with femoro-iliac thrombosis following retrograde catheterization. Two additional patients have been observed with brachial and combined radial-ulnar artery thrombosis after catheterization in which nonoperative management was possible.

Our purpose is to review the diagnostic features of this type of arterial injury and to describe the use of the mercury strain gauge plethysmograph in evaluating the development of collateral circulation and success of reparative surgery.^{12, 15}

Material

During the two years (1959-60), 49 patients were studied by retrograde arterial catheterization on the cardiovascular and neurosurgical services of the Seattle Veterans Administration Hospital.

* Submitted for publication August 8, 1961.

** Chief, Surgical Service, Veterans Administration Hospital; Associate Professor of Surgery, University of Washington School of Medicine, Seattle, Washington.

Each of the upper extremity procedures was performed by open arteriotomy of the brachial or radial and ulnar arteries, usually under local anesthesia. Attempts were made to repair the brachial artery in each instance unless a small muscular branch had been used for catheterization. In six patients the right radial artery was ligated and in five, repair of the arteriotomy was performed. In one patient the ulnar artery was ligated after temporary occlusion had indicated satisfactory radial collateral.

In 21 patients, percutaneous retrograde catheterization of the femoral artery was performed with the Seldinger catheter. Fifteen patients had successful completion of the procedure with no apparent complication. In three, failure of catheter advancement led to termination of the procedure. In the remaining three, major vascular injury occurred consisting of acute common femoral thrombosis in one, delayed femoral thrombosis in the second and external iliac perforation and thrombosis in the third.

No major complications resulted from retrograde upper extremity arterial catheterization in any of the 28 patients receiving diagnostic cardiac or neurosurgical studies. Of those patients in whom the brachial arteriotomy was repaired, three exhibited absent radial pulses in the post-operative period. Although the hand was cool, capillary filling was prompt. The patients occasionally complained of slight claudication and vague paresthesia but these symptoms were usually transient. Similarly, ligation of the radial artery caused minimal to no subjective complaints and a pulse often reappeared several weeks

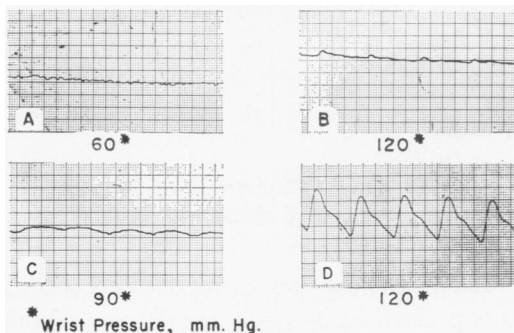


FIG. 1. Finger plethysmogram with brachial artery thrombosis. A. Rt. index with obstructive pulse of low amplitude. B. Rt. index, first postop. day with increase in pressure and volume pulse. C. Left index, normal pulse with vasoconstriction. D. Left index, normal digit pulse.

after discharge. Appearance of a radial pulse after ligation or suture repair was in most patients thought to result from collateral circulation rather than a patent vessel.

The following cases illustrate a variety of injuries in both upper and lower extremity arteries.

Case Reports

Brachial Artery Thrombosis

Case 1 (E. F.). A 39-year-old white man was admitted to the neuropsychiatry service for a cerebral angiogram. Under general anesthesia the right brachial artery was exposed in the antecubital fossa. A No. 9 cardiac catheter was advanced to the innominate artery. Under Arfonad hypotension to 70 to 80 mm. Hg systolic, four injections of 20 cc. of 50 per cent sodium diatrizoate † were made for a series of exposures. The catheter was withdrawn and a bulldog clamp placed on the arteriotomy site. The clamp became dislodged and mild bleeding occurred. After hemostasis and heparin irrigation the arteriotomy was closed with a single silk suture. No pulsations were apparent in the repaired area. Papaverine hydrochloride (2.5%) was injected into the arterial wall without any improvement.

Plethysmographic study of the fingers revealed adequate collateral circulation in the hand (Fig. 1) with a wrist pressure of 60 mm. Hg. A stellate block was advised. An increase in digit pulse volume resulted but the arm remained cool and no radial pulse was palpable. The patient complained of a cold hand with paresthesia and mild claudica-

tion. On the first postoperative day, examination revealed slow capillary filling with an increase in wrist pressure to 90 mm. Hg. On the third day the radial pulse was still absent but no motor or sensory deficit was demonstrated. By the eighth day the arm and hand were warm and the patient had no specific complaints. The radial pulse reappeared after three months.

Comment: The period of hypotension, the repeated injections of contrast media and, finally the local trauma with the bulldog clamp could have been factors in this arterial thrombosis. Collateral circulation, at first critical, improved with time and possibly benefited from stellate block.

Ulnar Artery Ligation and Thrombosis of Radial Artery

Case 2 (W. M.). A 42-year-old white man was admitted for study of severe rheumatic valvular disease. On February 12, 1960 a retrograde catheterization of the left heart was performed under local anesthesia. A No. 9 side-hole Lehman cardiac catheter was introduced via the ulnar artery. The catheter was in place for three hours during the completion of the cardiac studies. Following catheter withdrawal, the ulnar artery was ligated just below the bifurcation of the brachial artery. Within a few hours the patient complained of a cold, painful hand. No pulses were palpable below the brachial. Plethysmography revealed absent digit pulses. The impression at this time was that the radial artery had thrombosed subsequent to ligation of the ulnar. A stellate block was performed that evening and again the following day. The patient was symptomatically improved but the hand remained cool, pale and somewhat

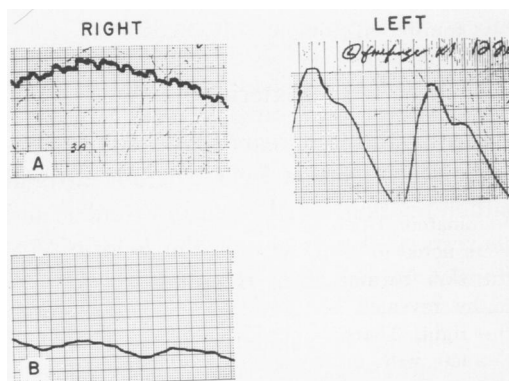


FIG. 2. Finger plethysmogram with obstruction of radial and ulnar artery. A. Rt. index, showing volume pulse compared to normal left index. B. 2nd postop. day following stellate block, slight improvement in digit volume pulse.

† Hypaque, Winthrop.

numb. Plethysmographic study on the first post-operative day revealed a slight pulsatile flow but of low volume and obstructive in character (Fig. 2). Subsequently, the arm and hand remained cool but capillary flow improved. The patient complained of paresthesia and moderate claudication. At follow up examination two months later the radial pulse was again palpable and the hand was essentially asymptomatic.

Comment: The long period of inlying catheterization (three hours) necessary for the completion of the cardiac studies plus ligation of the ulnar artery at the bifurcation may have contributed to the radial artery thrombosis.

Femoral Thrombosis

Case 3 (R. L.). A 41-year-old white man was admitted for evaluation of hematuria and question of a right renal mass. A lumbar percutaneous aortogram was unsuccessful. The patient was referred to the cardiovascular service. On November 11, 1960, a right retrograde femoral (Seldinger catheter) aortogram was performed. Following removal of the catheter the patient was observed to have a cold, pulseless leg. The physical findings were confirmed by plethysmographic study (Fig. 3) of absent digital pulsation and absent ankle pressure compared to 130 mm. Hg in the opposite ankle. Following removal of a 2.0 to 3.0 cm. segmental thrombus in the common femoral artery, the peripheral pulses returned. The patient was ambulatory the following day and convalesced uneventfully. Two weeks later the patient had a right nephrectomy for a hypernephroma.

Perforation and Thrombosis of the External Iliac Artery

Case 4 (M. L.). A 53-year-old white man was transferred from another hospital for study of idiopathic cardiomegaly. On December 8, 1960, under local anesthesia, right retrograde (Seldinger) catheterization of the femoral artery was performed. Obstruction to passage of the catheter was apparent upon several trials. Because of abdominal and pelvic pain, the procedure was terminated. Upon catheter withdrawal the pulses were noted to be absent in the entire right leg and the skin became cool and mottled. Plethysmography revealed no detectable ankle pressure on the right. There was marked vasoconstriction on the left with an ankle pressure of 90 mm. Hg; the arm pressure was 150 mm. Hg systolic (Fig. 4).

The right femoro-iliac area was explored under continuous epidural anesthesia two hours after the catheterization. The proximal common femoral

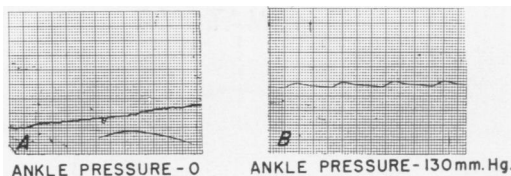


FIG. 3. Toe plethysmogram with right femoral thrombosis. A. Absent rt. digit pulse before thrombectomy. B. Left toe with vasoconstrictive pulse of low amplitude.

and external iliac arteries were moderately atherosclerotic and were completely thrombosed. There was a large retroperitoneal hematoma which had originated from arterial puncture by the catheter on the lateral wall of the iliac just opposite the origin of the hypogastric (Fig. 5). The latter vessel was also obstructed by the intraluminal thrombus. There was extensive mural dissection by the hematoma, chiefly under the adventitia of the external iliac artery. Subsequent longitudinal arteriotomy showed this segment so damaged that thrombectomy was not feasible (Fig. 6).

As the common iliac was pulsatile and the common femoral near the origin of the profunda was satisfactory, a Teflon graft was placed end-to-end and end-to-side. The damaged arterial segment was excised. Upon removal of the arterial clamp there was a transient drop of central pressure. After this was corrected, right ankle pressure was 65 mm. Hg but no pulses were noted. Shortly thereafter, the posterior tibial pulse appeared and at wound closure the ankle pressure had increased to 130 mm. Hg.

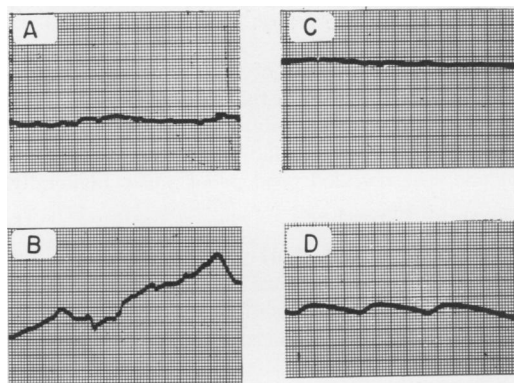


FIG. 4. Plethysmogram with right iliac perforation and obstruction. A. Preop. rt. 2nd toe, absent pulse and ankle pressure, left ankle pressure 110 mm. Hg. B. During surgery, showing digit volume increase after declamping. Ankle pressure 125 mm. Hg. C. 5th postop. day, rt. toe with marked vasoconstriction obliterating pulsatile flow, ankle pressure 120 mm. Hg. D. Same with pulsatile flow appearing after reactive hyperemia test to release vasoconstriction.

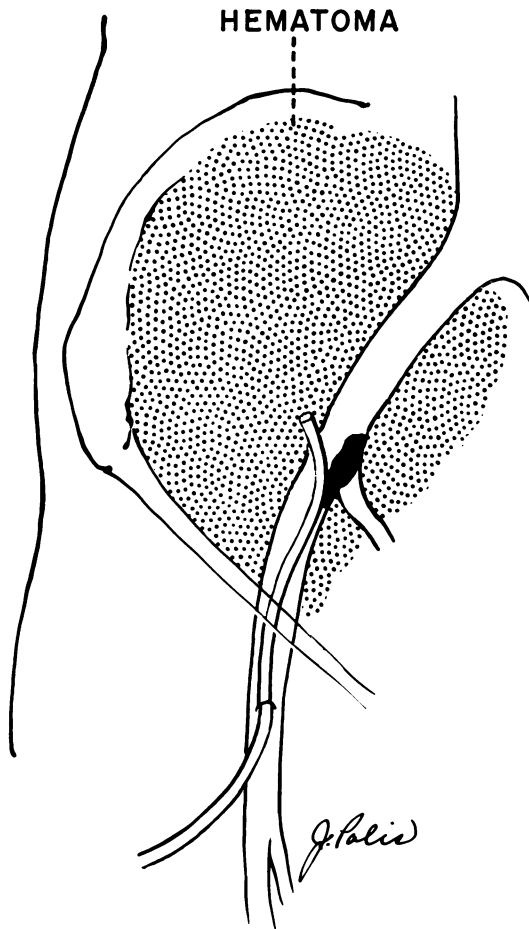


FIG. 5. Diagram of probable mechanism of catheter deflection from plaque to perforate opposite wall of iliac artery.

A moderate degree of peripheral vasoconstriction was apparent up to the fifth postoperative day by plethysmographic study. The patient convalesced well and had no specific complaints. Follow up at one year revealed good pedal pulses bilaterally.

Femoral Thrombosis

Case 5 (D. S.). A 41-year-old white man was admitted for neurological study. A month prior to admission he had suffered a cerebrovascular accident. A carotid angiogram had revealed normal findings. He also was found to be pre-diabetic with mild hyperglycemia and glycosuria. Blood pressure was normal. He was readmitted for retrograde vertebral angiography. On April 12, 1960, a percutaneous (Seldinger) catheterization of the right common femoral artery was performed. The procedure was believed to be without incident. However, the patient returned one week later with weakness and pain in the right leg. He had noted one-block claudication and cramps in the

right calf at rest. Examination revealed a cool right leg with totally absent pulses.

Plethysmography revealed absent digital pulses with low pressure through the entire right leg. The pressure gradients were normal, however, indicating a patent distal bed (Fig. 7).

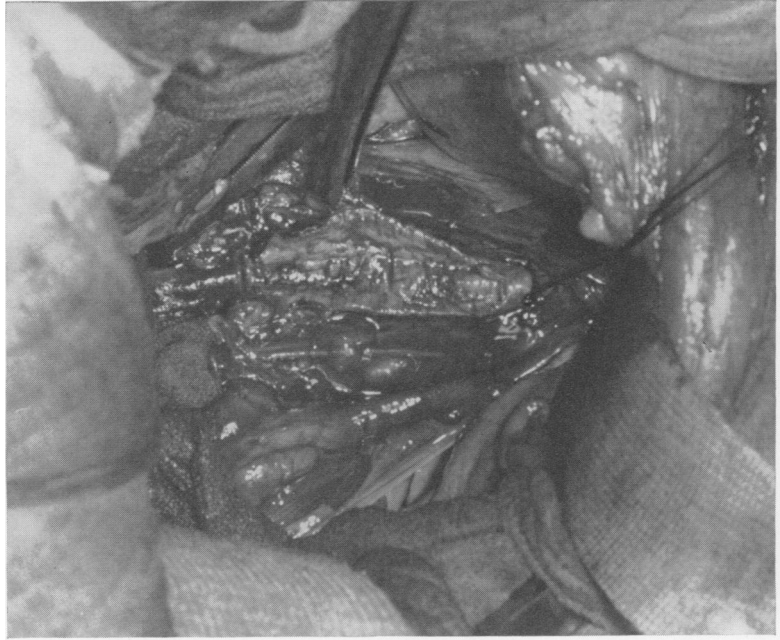At operation the common femoral artery was thrombosed to the origin of the profunda. There was a recent adventitial hematoma and a 3.0 mm. sealed laceration in the vessel wall. Diffuse atherosclerotic plaquing of the vessel was palpated. Thrombectomy was accomplished with good immediate results. Plethysmographic check in the recovery room two hours later revealed a rethrombosis of the involved segment. The patient was returned to the operating room and the artery re-explored. It was believed that previous arterial damage (post-catheterization) had so altered the arterial wall that a thrombogenic focus was present. Accordingly, the damaged segment was excised and a Teflon end-on graft inserted.

The patient had excellent results for nine months, when calf claudication reappeared and plethysmographic and clinical examination confirmed a new thrombosis in the prosthetic graft. On December 23, 1960, the femoro-iliac area was re-explored. The right external iliac artery was found to be markedly atherosclerotic and was occluded by thrombus from the origin of the hypogastric. The graft replacement of the common femoral was also clotted down to the profunda. A Dacron graft was placed end-to-side from common iliac to the superficial femoral artery. A concomitant sympathectomy was performed. The preoperative ankle pressure was 65 mm. Hg, which increased to 105 mm. Hg at the end of the operation. The patient did well for two months but at present has evidence of graft failure and a further procedure may be necessary.

Discussion

In contemplating retrograde cannulation through an upper extremity artery, consideration must be given to potential collateral circulation. Whether catheterization is performed by percutaneous or open arteriotomy, the opportunity for vascular obstruction is always present. Abundant collateral circulation permitting survival of the arm following ligation of the subclavian, brachial, radial or ulnar arteries in most instances makes the upper arm vessels more suitable than leg arteries for retrograde procedures. Other factors such as the ease of exposure and control of the brachial or

FIG. 6. Operative photograph of opened external iliac artery revealing thrombus and mural damage.



radial-ulnar arteries, the infrequent occurrence of occult atherosclerosis and the shorter distance to the proximal aorta or heart reduce the risk of sequelae from arterial injury in the upper extremity.

In the patient with post-catheterization thrombosis of the brachial artery (Case 1), the wrist blood pressure of 60 mm. Hg and the obstructive but adequate digit volume as measured with the mercury loop plethysmograph indicated satisfactory collateral

circulation. Conservative treatment was recommended and within 24 hours the wrist pressure had increased to 90 mm. Hg and the digit pulse was of slightly greater amplitude. The usually generous collateral pathways at the elbow between the radial and ulnar collateral and ascending recurrent arteries suggest that this site is a rather benign point for obstruction (Fig. 8).

The second patient (Case 2) in whom there was ligation of the ulnar artery would

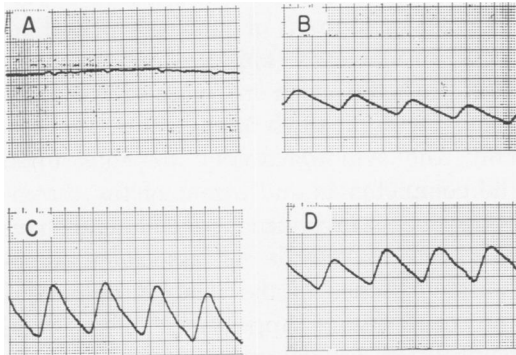


FIG. 7. Plethysmogram with right common femoral thrombosis. A. Rt. 2nd toe preoperation, absent pulse, ankle pressure 60 mm. Hg. B. Left 2nd toe preoperative, essentially normal digit pulse, ankle pressure 120 mm. Hg. C. Rt. toe, 3rd day after teflon graft with near normal digit pulse, ankle pressure 128 mm. Hg. D. Left toe, 3rd day, ankle pressure 120 mm. Hg.

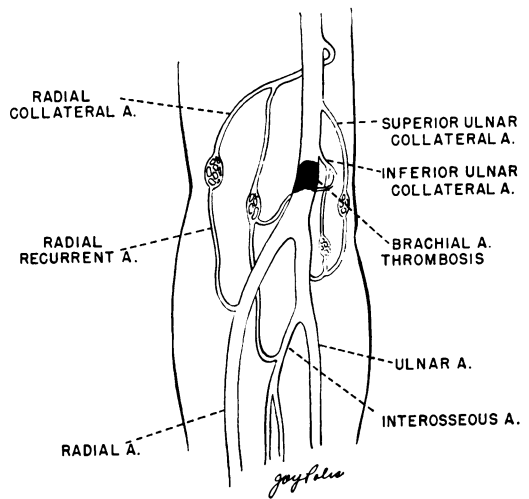


FIG. 8. Available collateral pathways with brachial obstruction.

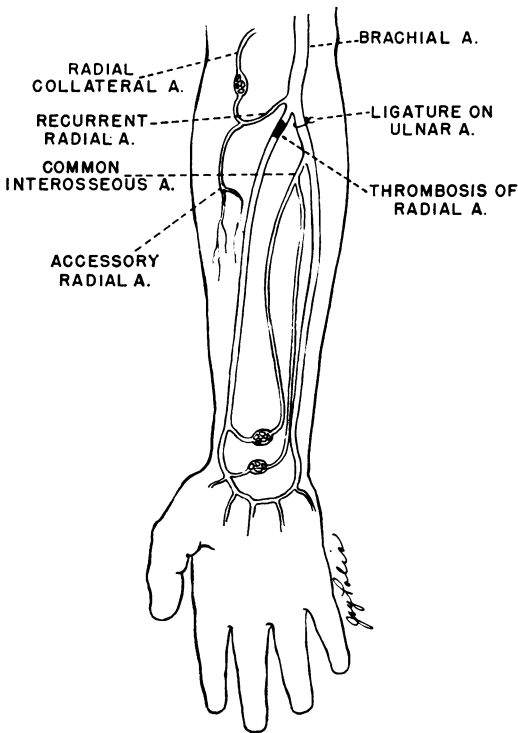


FIG. 9. Collateral circulation with ligation of ulnar and thrombosis of radial artery.

probably have had no sequela if the radial artery had remained patent. The presence of the catheter in the ulnar artery for prolonged periods may have been a precipitating factor for the retrograde radial thrombosis. Following two stellate blocks, there was marked improvement in objective findings. Again the decision was reached to continue nonoperative measures. Collateral circulation with both ulnar and radial arteries occluded near their origin is more critical than with uniarterial or higher obstruction (Fig. 9). Possible collateral pathways are the descending vessels from the brachial anastomosing with the interosseous and accessory radial or ulnar recurrent arteries below the obstructed point. If the ulnar artery is occluded below the origin of the interosseous, the latter artery should assure circulation to the hand.¹¹

Apparently, post-catheterization arterial injuries from either the percutaneous or

open approach are quite uncommon in the arm. Collins and co-workers³ modified the original Gould technic⁶ for retrograde brachial vertebral angiography and reported no complications in 17 patients. They stated that although the radial pulse was commonly absent after single suture repair of the arteriotomy, it usually reappeared within 48 hours. Kuhn,⁹ using the open brachial approach for cerebral angiography, has described a large experience without morbidity or mortality in over 200 children and adults.

In 1948, Radner¹³ reported a technic for retrograde thoracic aortography involving the exposure and post-catheterization ligation of the radial artery in the upper third of the forearm. Although this preliminary communication did not mention any complications, subsequent reports from the Swedish investigators¹ have established the utility and safety of retrograde catheterization by various routes on several thousand patients.

Damage to the femoral or iliac arteries poses a much more serious problem than with the counterpart vessels in the arm. Although it is well known that chronic occlusion of these vessels is surprisingly well tolerated, acute obstruction results in distal necrosis in a high percentage of patients.⁸

In the three patients herein reported, signs and symptoms of acute peripheral arterial insufficiency appeared immediately after catheterization in two and were delayed for eight days in the third. Presumably, the symptomatology depends upon the completeness and extent of the thrombotic process, involvement of collateral channels and magnitude of associated vasospasm. Absence of the femoral pulse and the concomitant appearance of a cool, painful leg following withdrawal of the catheter indicate thrombosis of the common femoral or iliac vessels.

In Case 4 the presence of severe low back and abdominal pain plus difficulty in

advancing the catheter led to a suspicion of iliac injury. The mechanism of this dissection was thought to be similar to that reported by Templeton¹⁷ in which the catheter tip was thought to have penetrated an atherosclerotic ulcer of the intima and caused a dissecting aneurysm of the thoracic aorta. In the present case, the catheter tip apparently deflected by a plaque perforated the iliac artery opposite the origin of the hypogastric (Fig. 5).

In 1945, Farinas⁴ presented a method of retrograde femoral catheterization for study of the abdominal aorta. However, it remained for Seldinger,¹⁴ in 1953, to describe a technic of percutaneous arteriography which could be utilized for studying the left heart and thoracic aorta. This method was later modified by Odman¹⁰ to include a flexible metal guide which aided in the passage and manipulation of the catheter. The Seldinger technic has received wide acceptance among American radiologists and cardiologists interested in retrograde studies of the heart and large vessels.

Figley and associates⁵ have reported the results of this technic in the contrast study of left heart valves and coronary arteries. In 140 catheterizations, they experienced failure to pass the catheter through the pelvic arteries in 17 (12%). In the older patients, tortuosity of the pelvic vessels increased the failure rate to 20 per cent. Post-catheterization femoral thrombosis occurred in two patients, both of whom had low output heart failure.

Bernens and co-workers² have published an experience with more than 150 gynecologic cases in which abdominal aortography was performed by the percutaneous femoral route. Other than angiospasm and hematoma, they had no serious complications. They recommended that femoral puncture should be avoided in ambulant patients, especially elderly ones.

Our three patients suffering post-catheterization femoro-iliac thrombosis were

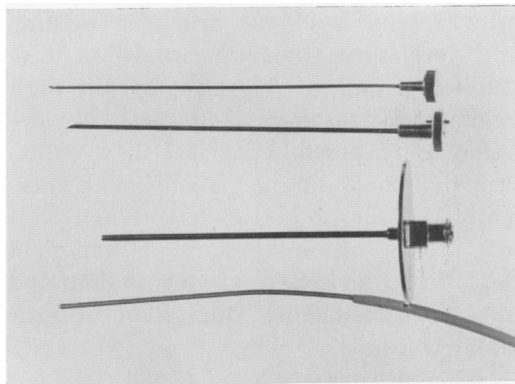


FIG. 10. Seldinger catheter assembly with flexible spring wire stylet (bottom).

scarcely elderly (ages 39, 42, 41), which raises the question of occult atherosclerosis in the middle aged man. One patient had clinical evidence of a cardiac lesion and one had suffered a cerebrovascular accident.

When the flexible, metallic guide wire of the Seldinger catheter is advanced through vessels which are the site of arteriosclerotic plaquing, it is readily seen that the tip may dissect under a plaque or be deflected to perforate the opposite wall (Fig. 10). It would appear that such complications are perhaps unavoidable when using the femoral artery which is the site of occult atherosclerosis.⁷ Possibly the incidence of postcatheterization thrombosis could be reduced by performing open arteriotomy and selecting a soft area of vessel wall rather than the blind percutaneous puncture.

In selecting patients for retrograde arterial studies, it would seem desirable to avoid the femoral artery in diabetic, hypertensive or elderly individuals in whom there is clinical evidence of systemic arteriosclerotic disease.

Previous experience with the use of the mercury strain gauge plethysmograph for the operative monitor of digit volume and ankle pressures during reconstructive surgery led to its application in these patients with acute arterial injury.^{12, 15, 16} In major

arterial injuries of the arm, the existing and developing collateral circulation were manifest from the improvement in digit volume and rise in wrist pressure. The decision as to possible surgical intervention was simplified. In the patients with traumatic thrombosis of the femoro-iliac vessels, use of the plethysmograph confirmed the clinical evidence of obstruction and indicated satisfactory restoration of flow after corrective surgery.*

Summary

1. Three cases of injury to the femoro-iliac arteries are described following retrograde catheterization. Each patient required surgical treatment for relief of symptoms and restoration of circulation.

2. Two patients had post-catheterization occlusion of upper extremity arteries following either cardiac or neurosurgical study. Surgical intervention was strongly considered but subsequent observation proved the reversibility of symptoms with the development of adequate collateral circulation.

3. Use of a simple mercury loop strain gauge plethysmograph is described as a technic to supplement the clinical diagnosis, monitor the surgical procedure and evaluate the late results of treatment.

References

1. Bagger, M., and 33 other investigators: On Methods and Complications in Catheterization of Heart and Large Vessels, with and without Contrast Injection. *Amer. Heart J.*, **54**:766, 1957.
2. Bernens, B., A. Carlsten, A. Holmgren and S. I. Seldinger: Percutaneous Catheterization of Peripheral Arteries as a Method for Blood Sampling. *Scand. J. Clin. Lab. Invest.*, **6**: 217, 1954.

3. Collins, W. F., Jr., H. W. Slade and W. G. Lockhart: Brachial Vertebral Angiography in Adults. *J. Neurosurg.*, **14**:466, 1957.
4. Farinas, P. L.: Retrograde Arteriography in the Study of the Abdominal Aorta and Iliac Arteries. *Surgery*, **18**:244, 1945.
5. Figley, M. M., L. A. Phillips, R. A. Bruce and L. A. Cobb: Radiologic Examination of the Left Heart Valves and Coronary Arteries. Personal communication.
6. Gould, P. L., W. T. Peyton and L. A. French: Vertebral Angiography by Retrograde Injection of the Brachial Artery. *J. Neurosurg.*, **12**:369, 1955.
7. Jones, T. W., R. R. Vetto, L. C. Winterscheid, D. H. Dillard and K. A. Merendino: Arterial Complications Incident to Cannulation with Special Reference to the Femoral Artery. *Ann. Surg.*, **152**:969, 1960.
8. Kagiyaama: Quoted in Morris' *Human Anatomy*, p. 688, 10th Ed. Philadelphia, The Blakiston Co., 1942.
9. Kuhn, R. A.: Brachial Cerebral Angiography. *J. Neurosurg.*, **17**:955, 1960.
10. Odman, Per and J. Philipson: Aortic Valvular Disease Studied by Percutaneous Thoracic Aortography. *Acta Radiol. Suppl.*, **172**, 1958.
11. Quiring, D. P.: Collateral Circulation. Philadelphia, Lea and Febiger, 1949.
12. Radke, H. M., J. W. Bell, D. E. Strandness, Jr. and J. E. Jesseph: Monitor of Digit Volume Changes in Angioplasty Surgery: Use of Strain Gauge Plethysmography. *Ann. Surg.*, **154**:818, 1961.
13. Radner, S.: Thoracic Aortography by Catheterization from the Radial Artery. *Acta Radiol.*, **29**:179, 1948.
14. Seldinger, S. I.: Catheter Replacement of the Needle in Percutaneous Arteriography. *Acta Radiol.*, **39**:368, 1953.
15. Strandness, D. E., Jr., H. M. Radke and J. W. Bell: Use of a new Simplified Plethysmograph in the Clinical Evaluation of Patients with Arteriosclerosis Obliterans. *Surg., Gynec. & Obst.*, **112**:751, 1961.
16. Strandness, D. E., Jr., G. E. Gibbons and J. W. Bell: Acquired Arteriovenous Fistula: Evaluation and Prognosis with Mercury Loop Plethysmograph. (In press), *A.M.A. Arch. Surg.*, 1962.
17. Templeton, J. Y., R. G. Johnson and J. R. Griffith: Dissecting Aneurysm of the Thoracic Aorta as a Complication of Catheter Aortography. Successful Surgical Treatment. *J. Thor. Cardio. Surg.*, **40**:209, 1960.
18. Warren, R.: *Procedures in Vascular Surgery*. Boston, Little Brown, 1960.

* The author is indebted to resident surgeons D. E. Strandness, Jr., H. M. Radke and G. E. Gibbons for assistance in plethysmographic study and to Dr. Harold T. Dodge, Chief Cardiovascular Service and W. A. Kelly, Dept. of Neurosurgery for review of the manuscript.