

# Prepancreatic Portal Vein: \*

## Case Report

DANIEL S. RENNER, M.D., CHARLES G. CHILD, III, M.D.

*From the Department of Surgery, University of Michigan, Ann Arbor, Michigan*

CONGENITAL ANOMALIES of the portal vein are rare. Of these anomalies the variations of the mesenteric and splenic tributaries are most frequent, but there may also be duplications, cavernous transformation, and positional changes of the portal vein. Prepancreatic portal vein is extremely rare. There are only 16 cases reported in the world literature (Fig. 1). Eight cases are found in the American literature, seven in German and one in Spanish. This paper presents another case of prepancreatic portal vein associated with biliary atresia.

### Case Report

G. K. was a seven-week-old white male infant who had been jaundiced since the third day of life. His jaundice progressed and was associated with light stools and dark urine. He was admitted to another hospital where a diagnosis of biliary atresia was made. He was transferred to the University of Michigan Medical Center on October 24, 1961. The infant weighed 9 pounds 4 ounces on admission, having gained normally from 7 pounds 2 ounces at birth. The child was in good health except for icterus and a palpable liver. His hemoglobin was 9.8 Gm. per 100 ml., total bilirubin 15.2 mg.%, with a one-minute direct of 13.7 mg.%, alkaline phosphatase 19.7 King-Armstrong units, and a 72-hour stool excretion of radioactive rose bengal was 3.8 per cent, indicative of biliary atresia. On October 31, 1961, an operation was performed disjoining an anomalous portal vein anterior to the pancreas and first portion of the duodenum and posterior to the third portion of the duodenum (Fig. 2, 3). Complete biliary atresia was also present as expected. To correct this, a Sterling prosthesis<sup>14</sup> was inserted into the liver and connected Roux-en-Y to the jejunum. No other abnormalities were found.

Six weeks after operation a splenoportogram was performed (Fig. 4). Liver function studies at that time were essentially unchanged, except

for the 72-hour stool excretion of radioactive rose bengal which was 16.3 per cent.

### Discussion

The first case of prepancreatic portal vein was reported by Harry O. Knight<sup>6</sup> in 1921 and was found in dissection of a cadaver. Since that time 15 other cases have been reported. The other American cases were reported by Snavely,<sup>12</sup> in 1954, Bernard,<sup>1</sup> in 1959, Block and Zikria,<sup>2</sup> in 1961 and four cases by Boles,<sup>3</sup> in 1961. The case reported by Snavely had a double portal vein with the smaller branch going to the gallbladder and right lobe of the liver. The splenic and coronary veins merged and joined the portal vein superior to the duodenum so that the mesenteric tributaries were the only parts to lie anterior to the pancreas and duodenum (Fig. 1). There was also a congenital stenosis of the abnormal portal vein ventral to the duodenum, which caused portal hypertension and death from bleeding esophageal varices. The cases of Bernard and Block

Figure 1.  
PRE-PANCREATIC PORTAL VEIN








STOMACH & DUODENUM	NORMAL	SITUS INVERSUS	PARTIAL SITUS INVERSUS & ABNORMAL MESENTERY	
TOTAL CASES 16 1921-1961	 KNIGHT BERNARD STENDEL (2) PERNKOPF LEWIS & BOLES (CASES I & IV)	 SNAVELY	 PERNKOPF (CASE II)	 SNITZLER
	 RENNER-CHILD (THIS CASE)	 PERNKOPF (CASE IV)	 BLOCK BOLES (CASE III) KOVERALTA	

FIG. 1. Schematic review of cases of prepancreatic portal vein reported in the world literature.

\* Submitted for publication June 5, 1962.

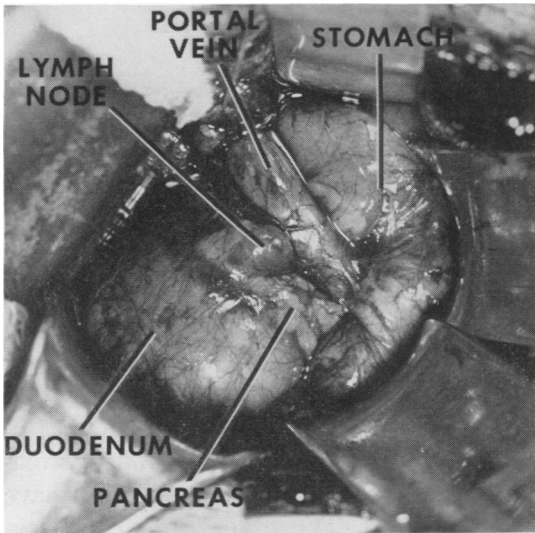


FIG. 2. Photograph taken at operation, showing portal vein crossing anterior to pancreas and first portion of duodenum, and going posterior to third portion of duodenum.

were found during operation to have obstruction of the first part of the duodenum. Bernard's case also had a duodenal ulcer penetrating the portal vein causing massive gastro-intestinal bleeding. Boles reports four cases in infants. All had associated congenital anomalies, but did not have clinical symptoms directly related to the abnormal portal vein.

In the German literature, Stengel<sup>13</sup> reported two cases in 1934. The cases were incidental findings at autopsy, both having the same configuration with the portal vein lying anterior to the third portion of the duodenum. It is of interest that these two cases were found in the same week, in the same hospital, and because of this Stengel stated that this anomaly must not be too infrequent. A review of the world literature now does not verify this view. Schnitzler,<sup>11</sup> in 1926, reported an operative case with prepancreatic portal vein and partial situs inversus of the stomach and duodenum. In this particular case the portal vein crossed anterior to the mid-portion of the stomach as well as the pancreas. This represents a pregastric portal vein whereas the

other cases represented preduodenal portal veins. In 1932, Pernkopf<sup>9</sup> reported two cases: one he found in dissection of a cadaver and the other was reported to him by Lehman. The latter was an operative case in which the portal vein was obstructing the duodenum. A gastrectomy and gastrojejunostomy were done to bypass the obstruction. Two other cases reported by Pernkopf<sup>8</sup> had partial situs inversus of the upper abdominal viscera. In his "Case number II," the portal vein is anterior to the first portion of the duodenum and pancreas and posterior to the third portion of the duodenum. Except for the situs inversus, this is similar to our case. Both cases represent two separate anomalies since situs inversus normally is not associated with a prepancreatic portal vein. Despite the malrotation of the intestinal tract, the portal vein would be expected to form the same way and lie behind the duodenum and pancreas.

In 1958, Roveralta<sup>10</sup> reported in the Spanish literature a case which presented as duodenal obstruction in a newborn. During operation a prepancreatic portal vein was found with other congenital anomalies, including a partial malrotation of the small bowel and colon.

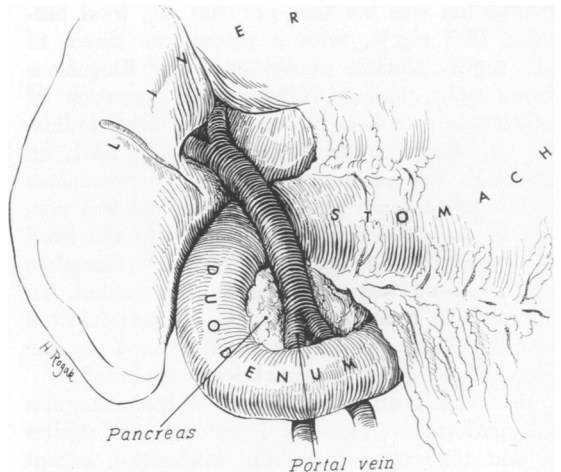
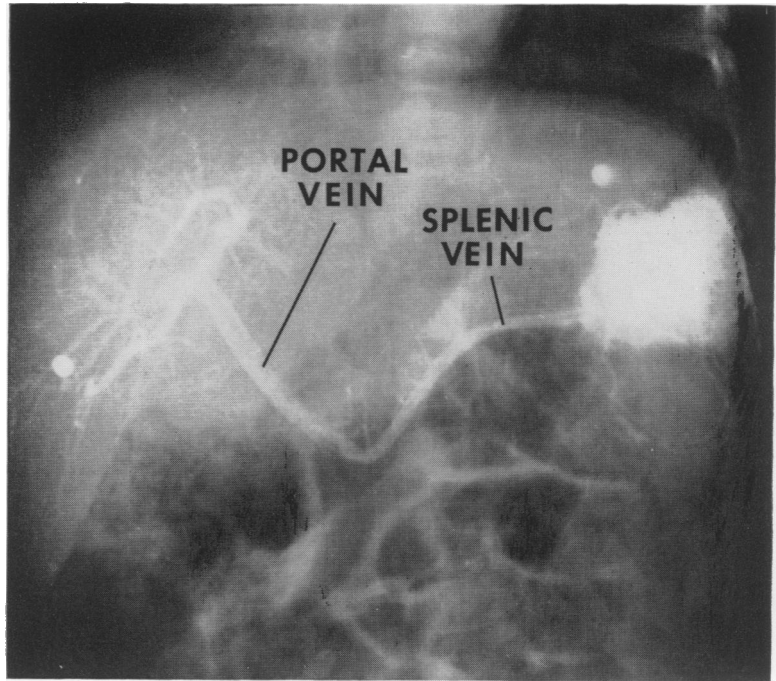


FIG. 3. Artist's sketch enlarging on photograph in Figure 2.

FIG. 4. Splenoportogram taken six weeks after operation using 4.0 cc. of 50 per cent Hypaque. This is interpreted as a normal splenoportogram. Tip of Sterling prosthesis is seen in right lobe of liver.



The etiology of this anomaly can best be understood by reviewing the normal embryology.<sup>7</sup> The portal vein is formed from the right and left omphalomesenteric (vitelline) veins. These veins have three anastomoses. The most cephalic eventually lies within the liver, making up the transverse part of the portal sinus, and ultimately becomes the left main intrahepatic division of the portal vein (pars transversa of the left portal vein). The middle anastomosis lies posterior (dorsal) to the primitive gut and the most caudal anastomosis lies anterior (ventral) to the gut. As the gut rotates, the middle anastomosis lies posterior to the first portion of the duodenum while the caudal anastomosis lies anterior to the third portion of the duodenum. Parts of the right and left omphalomesenteric veins drop out. This would leave a tortuous vein around the duodenum, except that at the same time the gut rotates so that the extrahepatic portal vein runs in a direct line from bowel mesentery to porta hepatis.

In the anomaly reported in this paper,

the direct line of the portal vein is still present, indicating that although the portions of the omphalomesenteric veins have dropped out normally, the middle anastomosis which should have developed posterior to the gut has in this case developed anterior to it. The caudal anastomosis has developed normally anterior to the third portion of the duodenum in all other reported cases, except Pernkopf's "Case number II" and ours. In these two cases the caudal anastomosis also was abnormal in position, in that it developed on the dorsal side of the duodenum. Since Pernkopf's case is associated with situs inversus, our case is unique; no other case has been reported with this particular arrangement.

Eight of the reported cases and ours have two or more congenital anomalies existing together. To the best of our knowledge each is independent of the other. Three cases have situs inversus associated with this anomaly and three have partial situs inversus of the stomach and duodenum. Another case is associated with pneu-

matosis cystoides intestinalis. Our case and one reported by Boles are associated with biliary atresia. Because of the integrated development of the liver and biliary tree with the portal vein, it is conceivable that these two anomalies might be related. However, in view of our present inadequate understanding of the inter-relation between the development of the liver, the rotation of the gut and the development of the venous anastomoses, we have no reason to assume a causal relationship between the biliary atresia and the abnormal portal vein.

Four of the reported cases have been of clinical significance. Two have been operated upon for duodenal obstruction at the site where the portal vein crossed the first portion of the duodenum. One had obstruction and a duodenal ulcer at this area with bleeding from the ulcer which eroded the portal vein. Another case had stenosis and cavernous transformation of the portal vein with portal hypertension resulting in death from bleeding esophageal varices.

It is easy to imagine other problems that may arise from this anomaly, such as unexpected discovery in porto-caval anastomoses for portal hypertension. Operations on the pancreas would also be difficult with this anomaly. A routine gastrectomy could be exceedingly difficult since the portal vein would overlie the duodenal stump. Boles reports two cases operated upon for intestinal obstruction not directly related to the portal vein in which the abnormal portal vein made the operation technically difficult. Because of the importance of accidental division of the portal vein,<sup>4</sup> the possibility of this anomaly must be kept in mind during operations in this area, especially in the presence of other anomalies.

### Summary

1. A case of the portal vein lying anterior to the pancreas and first portion of the duodenum is reported.

2. The 16 cases of prepancreatic portal vein in world literature are reviewed.

3. The embryology of this anomaly is presented.

4. The clinical importance of this anomaly is discussed.

### References

1. Bernard, L. J., F. A. Perry and M. Walker: Preduodenal Portal Vein Causing Duodenal Obstruction with Bleeding Duodenal Ulcer. A Case Report. *Ann. Surg.*, 150:909, 1959.
2. Block, M. and E. A. Zikria: Preduodenal Portal Vein Causing Duodenal Obstruction Associated with Pneumatosis Cystoids Intestinalis. *Ann. Surg.*, 153:407, 1961.
3. Boles, E. T. and B. Smith: Preduodenal Portal Vein. *Pediatrics*, 28:805, 196.
4. Child, C. G. 3rd.: *The Hepatic Circulation and Portal Hypertension*. Philadelphia and London, Saunders, 1954, p. 323.
5. Gilfillan, R. S.: Anatomic Study of the Portal Vein with its Main Branches. *Arch. Surg.*, 61:449, 1950.
6. Knight, H. O.: An Anomalous Portal Vein with its Surgical Dangers. *Ann. Surg.*, 74:697, 1921.
7. Patten, B. M.: *Human Embryology*. New York and Toronto, The Blakiston Company, Inc. 1953, p. 642-646.
8. Pernkopf, E.: Der Partielle Situs Inversus der Eingeweide Beim Menschen. *Ztschr. Anat.*, 79:577, 1926.
9. Pernkopf, E.: Eine Seltene Anomalie im Verlaufe des Pfortaderstammes Zugleich ein Beitrag zur Entwicklungsgeschichte der Pfortader Beim Menschen. *Ztschr. Anat.*, 97:293, 1932.
10. Roviralta, E.: Vena Porta Preduodenal y Otras Malformaciones. *Rev. Espan. Pediat.*, 14:487, 1958.
11. Schnitzler, J.: Ueber Eine Cigentumliche Missbildung mit Stenosierung des Magenausgangs. *Med. Klin.*, 22:723, 1926.
12. Snavely, J. G. and E. S. Breakell: Fatal Hemorrhage from Esophageal Varices Due to Malformations and Congenital Stenoses in the Portal Venous System. *Am. J. Med.*, 16:459, 1954.
13. Stengel, F.: Über Zwei Falle von Praduodenal Verlauf der Pfortader bei Normaler Lage von Magen und Duodenum. *Ztschr. Anat.*, 102:661, 1934.
14. Sterling, J. A.: An Artificial Biliary Tree for Use in Biliary Agenesis. *J. Albert Einstein Med. Ctr.* 8:218, 1960.