

Rhabdomyosarcoma: *

A Study of 35 Cases

JORGE ALBORES-SAAVEDRA, M.D., RICHARD G. MARTIN, M.D.
J. LESLIE SMITH, JR., M.D.

*Departments of Pathology and Surgery, The University of Texas M. D. Anderson
Hospital and Tumor Institute, Houston, Texas*

IN VIEW of the wide variation in the clinical and pathological features of rhabdomyosarcoma, the pathologist who is unfamiliar with its different microscopic patterns frequently confuses it with other neoplasms. Further, the alveolar variant has only recently been recognized,¹¹ having previously been regarded as reticulum cell sarcoma, adenocarcinoma, melanoma, or some other tumor. For these reasons, the exact incidence of rhabdomyosarcoma and the survival rate of the patients are unknown.

Horn and Enterline⁵ divided rhabdomyosarcomas into four groups, according to their clinical and pathological features: pleomorphic, alveolar, embryonal, and botryoid. This division has been employed in a study of 35 patients ** who were treated or observed in consultation at the M. D. Anderson Hospital and Tumor Institute from January 1, 1950, to January 1, 1961.

Materials and Methods

The review covered all the tumors diagnosed as rhabdomyosarcoma and unclassified sarcoma. Thirty-five tumors which were regarded as rhabdomyosarcomas were found, although we were unable to support this diagnosis in three of the 35.

Three tumors labeled as unclassified sarcomas fulfilled our criteria for rhabdomyosarcoma, one being alveolar and two embryonal. Botryoid sarcomas of the female genital tract were not included; since heterologous elements other than muscle can be demonstrated in these lesions, they are considered mixed mesodermal tumors.⁸

Slides from all the specimens were stained with hematoxylin and eosin, phosphotungstic acid hematoxylin, Masson, and reticulum stains, individually. The clinical charts and, if available, autopsy protocols were also studied.

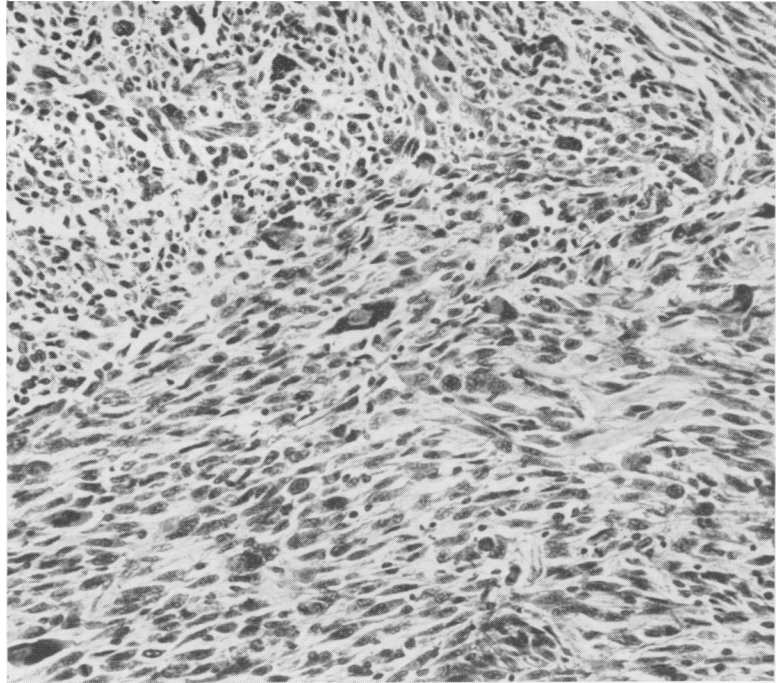
Pleomorphic Rhabdomyosarcoma

Pathologic Features. Grossly, the pleomorphic tumors were nodular or ill-defined, gray-white, and contained areas of hemorrhage and necrosis. Hemorrhage was so extensive in one tumor that it was confused with a hematoma. Basically, the tumors of this type were composed of spindle cells mixed with varying quantities of multinucleated giant cells (Fig. 1). Some of the latter contained cytoplasmic vacuoles, the cytoplasm being abundant and eosinophilic. Strap-shaped and racquet cells were present in all the tumors (Fig. 2). The stroma was well vascularized and contained a considerable number of collagen fibers; in general, the metastases contained more collagen fibers than the primary tumors. Numerous mitoses were observed. Longitudinal myofibrils and cross striations were demonstrated in four tumors.

* Submitted for publication April 3, 1962.

** Case 19 of the embryonal group was included through the courtesy of Dr. Harvey S. Rosenberg, at the Texas Children's Hospital in Houston, Texas.

FIG. 1. Pleomorphic rhabdomyosarcoma. Spindle cells mixed with multinucleated giant cells. H and E stain, $\times 180$.



Clinical Features. Nine of the 35 patients had tumors of this type (Table 1). Five of the nine were men. Their ages

ranged from 36 to 70 years, the average age being 57 years.

Seven patients had tumors arising in the

FIG. 2. Pleomorphic rhabdomyosarcoma. Strap-shaped cells. Ill-defined cross striations in one cell. Masson stain, $\times 720$.

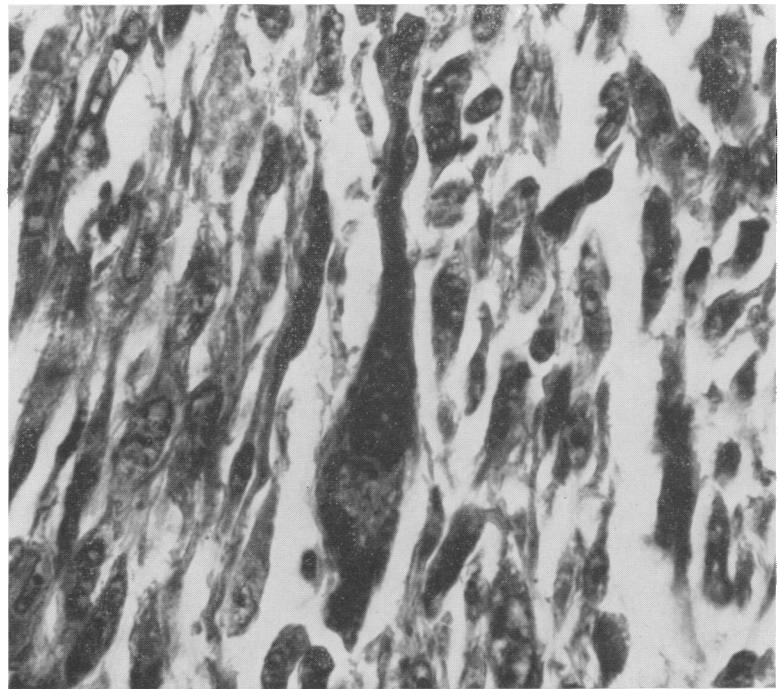


TABLE 1. *Clinical and Pathological Features of Pleomorphic Rhabdomyosarcoma*

Case	Age Sex	Location	Treatment	Local Recurrence	Metastases	Results
1	66 M	Thigh	Hemipelvectomy	No	Lungs	Patient died 8 yrs. postoperatively
2	36 F	Leg	Local excision	No	No	Patient is well 9 yrs. postoperatively
3	68 F	Buttock	Local excision	No	No	Patient is well 4 yrs. postoperatively
4	70 F	Leg	Above knee amputation; Actinomycin P-2, Thio-TEPA	No	Lungs & skull	Patient died 2 yrs. postoperatively
5	57 M	Chest wall	Local excision, Cytosaxan	Yes	Lungs & pericardium	Patient died 14 mos. postoperatively
6	56 F	Thigh	Disarticulation hip	No	No	Patient is well 3 yrs. postoperatively
7	49 M	Arm	Disarticulation shoulder	No	Lungs	Patient died 18 mos. postoperatively
8	57 M	Thigh	Local excision	No	Lungs	Patient died one yr postoperatively
9	55 M	Posterior aspect of neck	Local excision, radiotherapy	Yes	Lungs & heart	Patient died 3 yrs. postoperatively

extremities, one on the posterior chest wall, and one on the posterior aspect of the neck. Five were treated by local excision, two of whom also received chemotherapy and one radiotherapy. Two patients had a disarticulation, one an amputation, and one a hemipelvectomy.

Six patients died with evidence of distant metastasis, from 14 months to eight years following the diagnosis of rhabdomyosarcoma. The most common sites of metastases were the lungs, the skeletal system, and the heart, in decreasing order. The remaining three patients are still alive, three to nine years postoperatively, all of whom had tumors on the extremities. Two of these three were treated by local excision and the third had a disarticulation. A lesion on the posterior wall of the chest of one patient and on the posterior aspect of the neck of another recurred locally following excision.

Chemotherapy with the use of Cytosaxan, Actinomycin P-2, and Thio-TEPA failed to

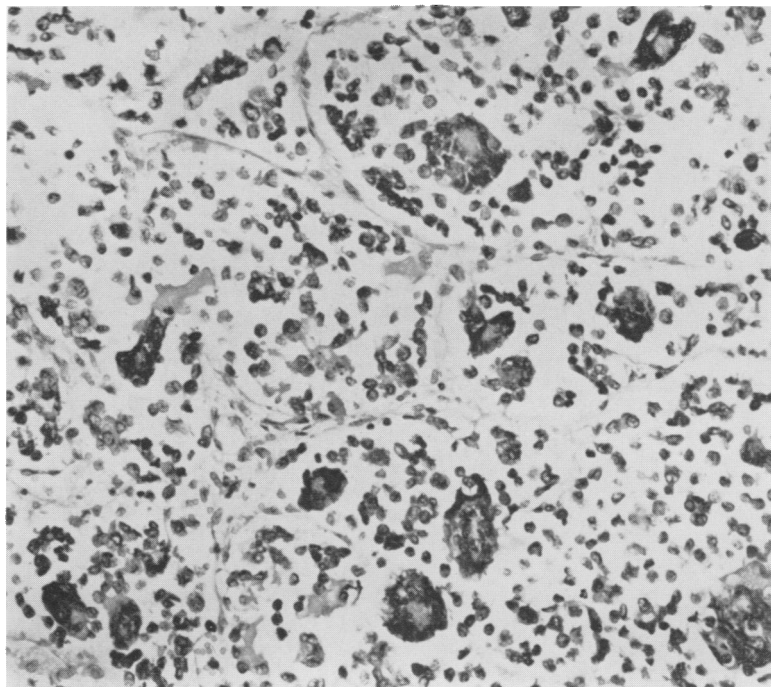
produce a good objective response in these tumors. Radiotherapy was also ineffective.

Alveolar Rhabdomyosarcoma

Pathologic Features. Grossly, the alveolar rhabdomyosarcomas were similar to the pleomorphic variety. With one exception, all of this type were situated between and partially replaced the muscles. None penetrated the overlying skin.

These neoplasms were composed of small round cells with scant cytoplasm and round vesicular or hyperchromatic nuclei. Frequently, the round cells were mixed with multinucleated giant cells (Fig. 3). Portions containing diffuse round cells which obliterated the alveolar pattern could easily have been confused with malignant lymphoma, undifferentiated carcinoma, neuroblastoma and other tumors. In most of the tumors, however, cells with eccentric nuclei and abundant eosinophilic cytoplasm could be found. In others, or in different areas of the same tumor, the cells

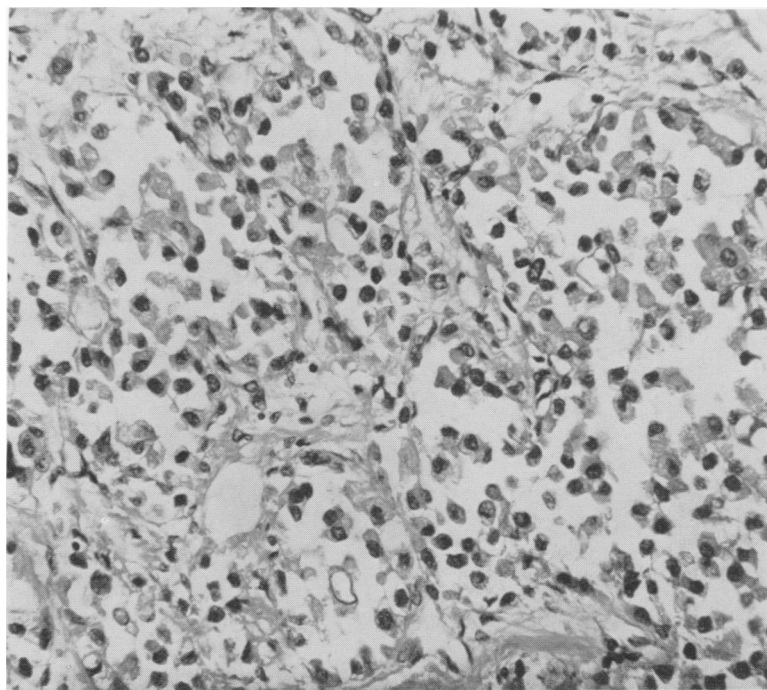
FIG. 3. Alveolar rhabdomyosarcoma. Round and multinucleated giant cells divided into compartments by connective tissue septa, producing an alveolar pattern. H and E stain, $\times 200$.



were larger, with eccentric and abundant eosinophilic cytoplasm; they tended to line connective tissue septa, producing the char-

acteristic alveolar pattern (Fig. 4). Other cells of this type were lying free in the lumina of the alveoli. Occasionally, struc-

FIG. 4. Alveolar rhabdomyosarcoma. Most of the cells have eccentric nuclei and abundant eosinophilic cytoplasm. Some cells are lying in the lumina of the alveoli, while others are lining connective tissue septa. H and E stain, $\times 250$.



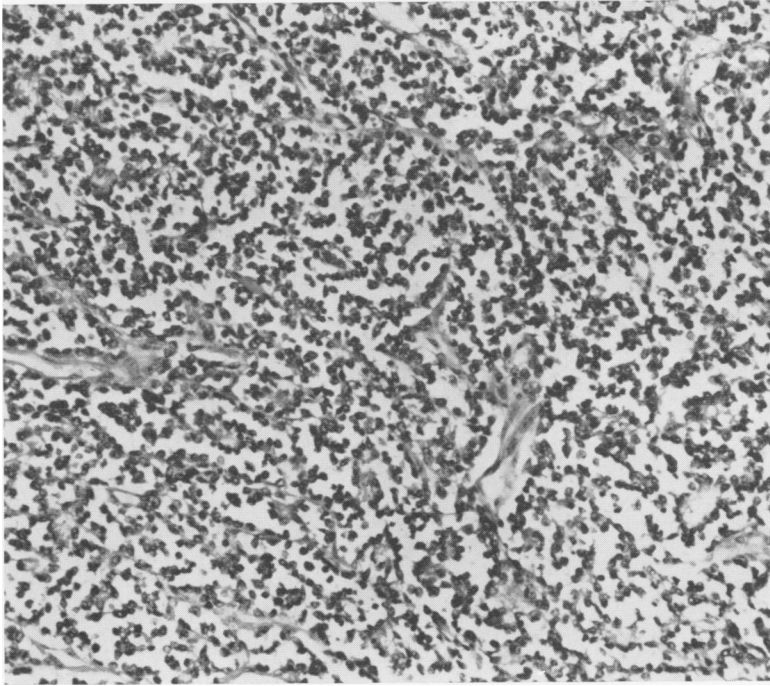


FIG. 5. Alveolar rhabdomyosarcoma resembling a vascular tumor. H and E stain, $\times 150$.

tures resembling connective tissue septa could be identified as giant multinucleated neoplastic muscle cells, the nuclei being

attached laterally to the sarcoplasm (Fig. 5, 6). Strap-shaped cells were observed in all the tumors. Mitotic figures were few.

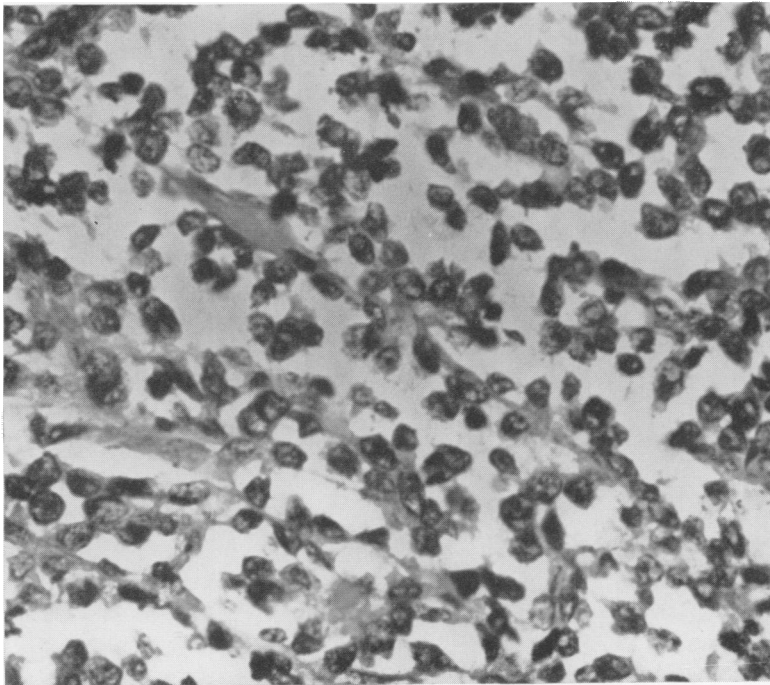


FIG. 6. Higher magnification of Figure 5, demonstrating neoplastic muscle cells with the nuclei attached laterally to the sarcoplasm, resembling connective tissue septa. H and E stain, $\times 720$.

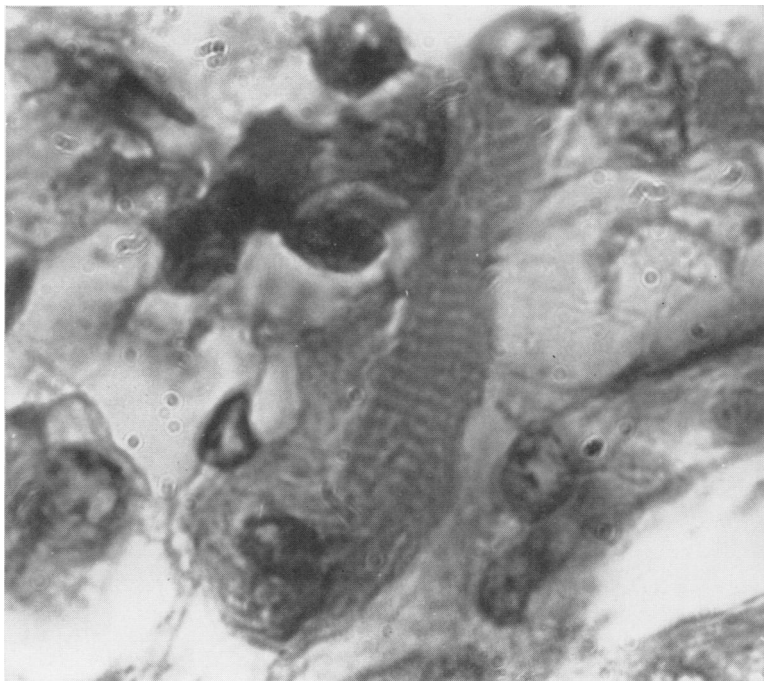


FIG. 7. Cross striations in alveolar rhabdomyosarcoma. H and E stain, $\times 1,700$.

In five tumors longitudinal myofibrils and cross striations were easily demonstrable (Fig. 7).

Clinical Features. The tumors of seven patients were alveolar rhabdomyosarcomas (Table 2). Four of the seven patients were women. The youngest was 15 and the oldest 53 years, the average age being 30. Four had lesions on the extremities; two, on the head and neck; and one, in the scapular region. One tumor in the thigh and another in the scapular region invaded the femur and scapula, respectively, producing osteolytic lesions. In both, the soft tissue mass contained calcified spots, as observed in chondrosarcoma and synovial sarcoma.

Three patients were treated by radical surgery, namely, disarticulation of the hip, interscapulothoracic amputation, and hemipelvectomy. One had an amputation of the fifth finger and fifth metacarpal bone and axillary node dissection. The treatment of another consisted of local excision of the lesion, followed by radiotherapy, 5-fluo-

ouracil, uracil mustard, Actinomycin P-2, Cytosan, and, finally palliative hemipelvectomy. Still another received only radiotherapy followed by Cytosan. The seventh patient had a biopsy and an intra-arterial injection of Methotrexate through the external carotid artery.

Metastasis is known to have developed in five patients; three of these have died, the fourth is still living with metastasis six months after treatment, and the fifth is apparently well 30 months postoperatively. The most common sites of metastases were the regional lymph nodes and the bones, especially the vertebrae. Two patients had paraplegia incident to vertebral collapse and consequent compression of the spinal cord. Another, who had no metastasis, was without evidence of disease six months postoperatively. Still another died elsewhere of the tumor. Two patients had local recurrences.

Irradiation brought about a temporary response of the tumor of one patient. The pulmonary metastasis of another disap-

TABLE 2. *Clinical and Pathological Features of Alveolar Rhabdomyosarcoma*

Case	Age Sex	Location	Treatment	Local Recurrence	Metastases	Results
1	24 M	Thigh	Disarticulation hip	Yes	?	Patient died one yr. postoperatively
2	15 F	Thigh	Local excision followed by radiotherapy to mediast. 5-fluorouracil, Actinomycin P-2, Cytoxan, uracil mustard & hemipelvectomy	Yes	Lungs, bones & epidural space	Patient died 2 yrs. after first operation
3	20 F	Orbit	Radiotherapy & Cytoxan		Cervical & axillary nodes, breasts & several vertebral bodies	Patient died one yr. following treatment with tumor extension to base of skull
4	42 F	Thigh	Hemipelvectomy	No	No	Patient living and free of tumor 6 mos. postoperatively
5	38 M	Hypothecar region	Amputation of 5th digit & 5th metacarpal bone; axillary node dissection	No	Axillary lymph nodes	Patient is well 2½ yrs. postoperatively
6	24 M	Right scapular region	Interscapulo-thoracic amputation & Actinomycin P-2	No	Lymph nodes heart, lungs & bone	Patient died 4 mos. postoperatively
7	53 F	Maxillary sinus	Intra-arterial injection of Methotrexate		Cervical & supraclavicular nodes & vertebral bodies	Patient living 6 mos. postoperatively with evidence of metastasis

peared for several weeks after therapy with 5-fluorouracil combined with radiation to the lungs. The tumor of the patient who received Methotrexate intra-arterially also regressed temporarily.

Embryonal Rhabdomyosarcoma

Pathologic Features. Grossly, the embryonal tumors were gray-white, gelatinous in texture, and infiltrated adjacent structures. The group included no polypoid forms,^{4, 7} and thus none could be classified as botryoid.

The tumors were composed of interlacing bundles of long spindle cells, usually with a single oval, a centrally placed nu-

cleus and brightly eosinophilic granular cytoplasm (Fig. 8). Round cells with eccentric nuclei were a prominent feature of three tumors. Avascular myxoid areas were also observed, and occasionally, multinucleated giant cells. Mitotic figures were fairly numerous.

Cross striations (Fig. 9) were apparent in many neoplastic cells of two tumors, and in seven others striations were found after a prolonged search. The stroma contained a small number of collagen fibers and a few blood vessels. The pattern of three tumors was mixed with foci of alveolar arrangement.

Clinical Features. Nineteen of the 35 patients had embryonal rhabdomyosarcoma

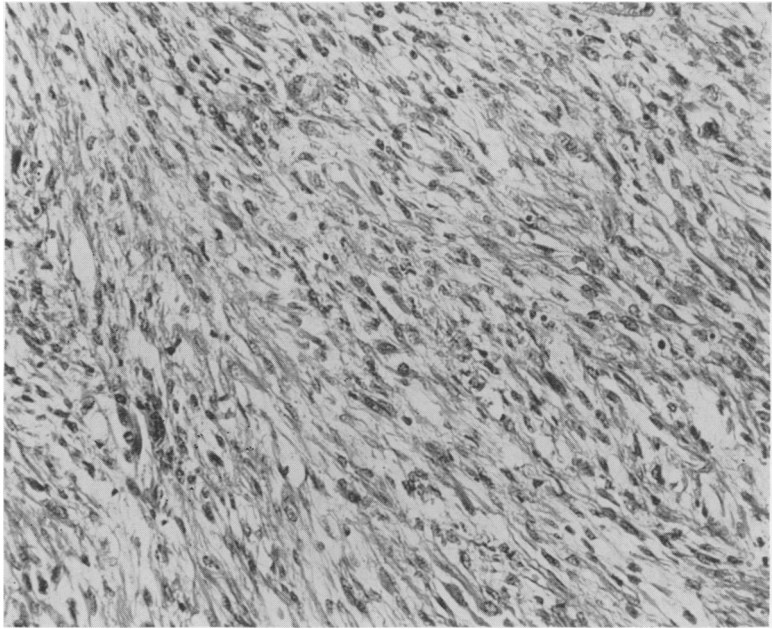


FIG. 8. Embryonal rhabdomyosarcoma. Long spindle cells with centrally placed nuclei and eosinophilic cytoplasm. H and E stain, $\times 180$.

(Table 3), 10 of whom were female. The youngest was 12 months old and the oldest 59 years, the average age being 12 years. Thirteen had tumors in the head and neck

areas; three, in the extremities; two, in the chest wall; and one, in the tunica vaginalis testis and spermatic cord.

These patients were treated by different

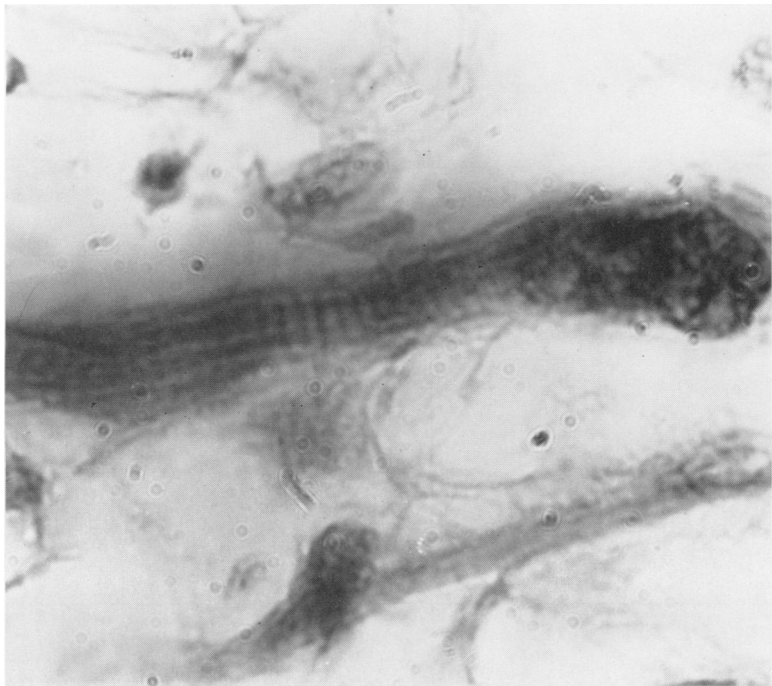


FIG. 9. Cross striations in embryonal rhabdomyosarcoma. H and E stain, $\times 1,700$.

TABLE 3. *Clinical and Pathological Features of Embryonal Rhabdomyosarcoma*

Case	Age Sex	Location	Treatment	Local Recurrence	Metastases	Results
1	10 M	Maxillary & sphenoid sinuses	Maxillary resection	Yes	No	Patient died one yr. postoperatively with tumor extension into base of skull
2	1 F	Posterior chest wall	Local excision	Yes	?	Patient died 4 mos. following excision; no autopsy
3	1½ F	Arm	Interscapulo-thoracic amputation	No	No	Patient is well and alive 6 yrs. post-operatively
4	19 M	Thigh	Disarticulation hip	No	No	Patient is well and alive 5 yrs. post-operatively
5	13 F	Temple	Local excision & radiotherapy	Yes	Breasts, left pleura, pericardium, pancreas, bones, peritoneum, & subcutaneous tissue	Patient died 3 yrs. following excision
6	9 M	Nasal pharynx	Local excision, Actinomycin D & radiotherapy	Yes	Lungs	Patient died 9 mos. following excision, with tumor extension into the base of the skull
7	59 F	Maxillary antrum	Intra-arterial injection of nitrogen mustard, radiotherapy		Heart, pancreas & bones	Patient died 5 mos. following treatment, with tumor extension into the base of the skull
8	1½ F	Posterior chest wall	Local excision, Actinomycin D, radiotherapy to to lungs	No	Right lung & subcutaneous tissue of face	Patient is living with metastases 2 yrs. following excision
9	3 M	Nasal pharynx	Local excision followed by Actinomycin D, radiotherapy & Cytosan	Yes	Cervical nodes & lungs	Patient died 10 yrs. postoperatively
10	8 M	Maxillary sinus & nasal pharynx	Radiotherapy, Thio-TEPA & Cytosan		Cervical nodes	Patient died 13 mos. following diagnosis of the tumor
11	1 M	Left cheek	Actinomycin D & radiotherapy		Cervical nodes & lungs	Patient is living with tumor 6 mos. after treatment
12	56 M	Tunica vaginalis & spermatic cord	Orchiectomy; excision of spermatic cord	No	No	Patient is living and tumor-free 6 mos. following treatment

TABLE 3.—(Continued)

Case	Age Sex	Location	Treatment	Local Recurrence	Metastases	Results
13	11 F	Orbit	Local excision followed by orbital exenteration	Yes	Cervical nodes & lungs	Patient died 2½ yrs. following original treatment with tumor extension into base of skull
14	18 F	Leg	Local excision & triethylene melamine & amethopterin	Yes	Regional nodes, lungs & bones	Patient died 2 yrs. following original excision
15	3 F	Orbit	Local excision (3 times) followed by radiotherapy & orbital exenteration	Yes	No	Patient is living, tumor-free, 16 mos. following original excision
16	3½ M	Hard palate	Local excision, Actinomycin D, nitrogen mustard & radiotherapy	Yes	Subcutaneous tissue of abdominal wall & bones	Patient died 1 yr., 7 mos., postoperatively
17	11 M	Hard palate	Maxillary resection & orbital exenteration, radiotherapy	Yes	No	Patient died 18 mos. postoperatively with tumor extension to base of skull
18	16 F	Nasal pharynx	Radiotherapy		?	Patient died 3 yrs., 2 mos. following treatment
19	3 F	Larynx	Laryngectomy	No	No	Patient is well, free of tumor, 3 yrs. postoperatively

methods. The majority received a combination of surgical treatment, radiotherapy and chemotherapy.

Twelve died from the effects of the tumor, while two are living with evidence of metastases. Five are apparently free of tumor one and one-half to six years following treatment. Three of these had tumors outside the head and neck. One had a tumor in the tunica vaginalis testis and spermatic cord, and was treated by orchiectomy with removal of the cord. The second patient had three local excisions, radiotherapy and, finally, orbital exenteration. The third had a total laryngectomy. The remaining two who exhibited no evidence of the disease had tumors in the extremities, for which an amputation and a disarticulation were performed.

Ten tumors are known to have metastasized, the lungs having been most often invaded and thereafter the regional lymph nodes and bones. Ten also recurred locally.

With three exceptions, the tumors which were irradiated responded temporarily. A combination of chemotherapy and irradiation brought about temporary regression of six tumors. The metastasis of one patient responded favorably to triethylene melamine and amethopterin.

Discussion

The higher incidence of pleomorphic rhabdomyosarcoma in the extremities of older patients in this series is consistent with that reported by other observers.⁵ Because of its location and the fact that this type occasionally remains localized for

a long time,^{13,14} it offers a more favorable prospect of surgical cure than the other variants of rhabdomyosarcoma. In some cases, metastases may appear from several to many years following excision of the primary tumor, as in our Patients 1 and 9.

Of the seven alveolar rhabdomyosarcomas in this group, four were situated on the extremities. Four of the patients, also, were young adults. This tumor has been considered highly malignant,^{2, 10, 11} all of the cases reported having been fatal. The number is too small, however, to permit an estimate of the average period of survival. Compression of the spinal cord, incident to metastasis to the vertebral bodies, is associated fairly often. The tendency of the tumor to metastasize to the regional lymph nodes must be considered in the treatment of the patient.

Three factors have contributed to the confusion of alveolar rhabdomyosarcoma with malignant lymphoma: 1) the tumor is strongly prone to metastasize to the regional lymph nodes; 2) it may be radiosensitive; and 3) microscopically, it usually contains extensive areas of round cells, closely resembling reticulum cell sarcoma or a lymphoblastic type of malignant lymphoma. Enterline and Horn² have emphasized the chief morphologic differences between this tumor and the alveolar soft part sarcoma.

The high incidence of local recurrence of embryonal rhabdomyosarcoma is related to the fact that this tumor arises chiefly in the head and neck^{6, 12} and is seldom amenable to surgical eradication. Thus, the location is of important prognostic significance. Of the five patients in our series who are living and apparently well, two had a tumor in an extremity and one a tumor in the tunica vaginalis and spermatic cord.

While embryonal rhabdomyosarcoma has a tendency to metastasize to the lungs, lymph nodes, and bones, it may also remain localized for a considerable time. It is usually radiosensitive,¹ and may also re-

spond to chemotherapy, particularly Actinomycin D.³

Of the 35 patients in this group, 22 have died as a result of the tumor. Three are living with metastasis, and 10 (28%) are apparently free of tumor six months to nine years following treatment. Of the 65 patients in the series of Pack and Ebert,⁹ 22 (33.8%) survived more than five years after treatment. None of the 65 had alveolar rhabdomyosarcoma, probably the most aggressive of these tumors.

Whatever the type of rhabdomyosarcoma, the treatment of choice is complete excision. The sooner this is carried out after the tumor is discovered, the more favorable the prospect of cure.

Summary

Thirty-five cases of rhabdomyosarcoma are reported. The tumors were subclassified into three groups: pleomorphic, alveolar, and embryonal. None of the embryonal tumors was polypoid and thus none could be designated as botryoid. Each type of rhabdomyosarcoma has special pathological and clinical features. The pleomorphic variant develops chiefly in the extremities of patients in the older age groups. It is resistant to chemotherapy and radiotherapy. The alveolar variant usually arises in the extremities or the head and neck of young adults. This tumor may be radiosensitive and strongly tends to metastasize to the regional nodes—two factors which have contributed to its confusion with malignant lymphoma. The majority of embryonal rhabdomyosarcomas are observed in children and are located in the head and neck. They are radiosensitive and respond consistently to Actinomycin D.

Of the 35 patients, 22 have died as a result of the tumor, three are living with evidence of metastases, and 10 survivors (28%) are living and free of tumor six months to nine years following treatment.

The most effective treatment for any

type of rhabdomyosarcoma is complete surgical excision.

Addendum

Since this article was submitted for publication, the three patients who were living with clinical evidence of metastasis have died. The remaining 10 of the 13 survivors are apparently free of disease, now 16 months to 10 years postoperatively.

References

1. D'Angio, G. J., S. Farber and C. L. Maddock: Potentiation of X-Ray Effects by Actinomycin D. *Radiology*, **73**:175, 1959.
2. Enterline, H. T. and R. C. Horn, Jr.: Alveolar Rhabdomyosarcoma: A Distinctive Tumor Type. *Am. J. Clin. Path.*, **29**:356, 1958.
3. Farber, S., R. Toch, E. M. Sears and D. Pinkel: Advances in Chemotherapy of Cancer in Man. *Advances in Cancer Research*, New York, Academic Press, Inc., **4**:1-71, 1956.
4. Farinocci, C. J., J. P. Fairchild, M. H. Sula and G. W. Gilpatrick: Sarcoma Botryoides (Form of Embryonal Rhabdomyosarcoma) of Common Bile Duct; Report of Two Cases. *Cancer* **9**:408, 1956.
5. Horn, R. C., Jr. and H. F. Enterline: Rhabdomyosarcoma: A Clinicopathological Study and Classification of 39 Cases. *Cancer*, **11**:181, 1958.
6. Moore, O. and C. Grossi: Embryonal Rhabdomyosarcoma of the Head and Neck. *Cancer*, **12**:69, 1959.
7. Mostofi, F. K. and W. H. Morse: Polypoid Rhabdomyosarcoma (Sarcoma Botryoides) of Bladder in Children. *J. Urol.*, **67**:681, 1952.
8. Ober, W. B. and J. H. Edgcomb: Sarcoma Botryoides in Female Urogenital Tract. *Cancer*, **7**:75, 1954.
9. Pack, G. T. and W. F. Eberhart: Rhabdomyosarcoma of Skeletal Muscle: Report of 100 Cases. *Surgery*, **32**:1023, 1952.
10. Potenza, D. A. and D. J. Winslow: Rhabdomyosarcoma of the Hand. *J. Bone and Joint Surg.*, **43-A**:700, 1961.
11. Riopelle, J. S. and J. P. Theriault: Sur une Forme Meconnue de Sarcome des Parties Molles, le Rhabdomyosarcoma Alviolaire. *Ann. de Anat. Path.*, **1**:88, 1956.
12. Stobbe, G. D. and H. W. Dargeon: Embryonal Rhabdomyosarcoma of Head and Neck in Children and Adolescents. *Cancer*, **3**:826, 1950.
13. Stout, A. P.: Tumors of the Soft Tissues. *Atlas of Tumor Pathology*, Sec. D., Fasc. 5, Washington, D. C., Armed Forces Institute of Pathology.
14. Stout, A. P.: Rhabdomyosarcoma of Skeletal Muscles. *Ann. Surg.*, **123**:447, 1946.

Additional Reference

- Porterfield, J. F. and Zimmerman, L. E.: Rhabdomyosarcoma of the Orbit. A Clinicopathologic Study of 55 Cases. *Virchovs Arch. path. Anat.*, **335**:329, 1962.