

Surgical Management of Congenital Lesions of the Coronary Circulation *

DAVID C. SABISTON, JR., M.D., RICHARD S. ROSS, M.D., J. MICHAEL CRILEY, M.D.,
ROBERT A. GAERTNER, M.D., CATHERINE A. NEILL, M.D., HELEN B. TAUSSIG, M.D.

*From the Departments of Surgery, Medicine, and Pediatrics, The Johns Hopkins
University School of Medicine and Hospital, Baltimore, Maryland*

WITHIN the recent past increased attention has been directed toward the diagnosis and surgical management of both congenital and acquired lesions of the coronary circulation. This represents an advance which has been possible due in large part to the introduction of precise and objective diagnostic methods as well as to improvements in surgical technic. One of the most important developments in this field has been the introduction of coronary arteriography. Contributions by various workers have led to the safe and reliable use of this method in a large number of patients with abnormalities of the coronary vessels. Constantly improving technics relating to direct surgical procedures on small arteries together with improved postoperative management have each been additional factors in the successful correction of several specific lesions of the coronary circulation. In this communication our experience in the diagnosis and surgical management of coronary arteriovenous fistula and congenital origin of the left coronary artery from the pulmonary artery will be presented.

Coronary Arteriography

The coronary arteries were first visualized in the intact experimental animal by Rousthoi in 1933.²⁴ He published convinc-

ing photographs demonstrating good filling of the coronary vessels following the injection of radio-opaque medium into the proximal aorta. The introduction of angiocardiology by introduction of dye into the venous system aroused further interest in this subject. The coronary arteries are occasionally demonstrated by this method, but only rarely does the filling provide sufficient detail for diagnostic accuracy. The use of retrograde aortography constituted another advance, and in 1952, DiGuglielmo and Guttadauro¹¹ published a monograph recording their observations employing this method. Dye was injected through a catheter in the proximal aorta, and this produced successful demonstration of the coronary arteries in a number of patients. Since then various workers have introduced several modifications such as direct needle puncture of the aorta, the use of acetylcholine to induce cardiac arrest during injection of dye, and employment of a catheter with a loop-end tip in an effort to improve visualization and to increase the safety of the technic.^{21, 33} We reviewed the results of 41 patients undergoing coronary arteriography in the Johns Hopkins Hospital in which dye injection in the proximal aorta was used.²⁰ The results were highly satisfactory and there was no mortality or significant morbidity.

The most recent significant advance in this field was the introduction by Sones²⁹ of a direct and selective method for coronary arteriography. With considerable ingenuity he developed the technic of direct

* Presented before the Southern Surgical Association, Boca Raton, Florida, December 4-6, 1962.

This work supported by Grants H-2864 and H-5584 from the National Heart Institute and Clinical Center Grant OG-11, Division of General Medical Sciences, National Institutes of Health, USPHS, Bethesda, Maryland.

placement under fluoroscopic control of a catheter into the coronary ostium followed by the injection of a *small* amount (3.0–4.0 ml.) of contrast medium. With the use of this method, excellent visualization of the coronary arteries and their branches may be consistently obtained. The immediate filling is observed on a screen intensifier, and a permanent record is obtained with ciné-angiography. In the experience of the Wellcome Laboratory of The Johns Hopkins Hospital, this method has been employed in more than 50 patients with gratifying results. This technic not only localizes anatomic and pathologic defects but also permits a dynamic evaluation of the site and magnitude of collateral circulation. The exposures are taken at a speed of sixty frames per second, permitting an accurate analysis of the changes which occur.

Coronary Arteriovenous Fistula

The first coronary arteriovenous fistula was described by Krause,¹⁸ in 1865, and since that time more than 80 examples have been recorded in the literature. Until the recent past this condition was of little more than academic interest since surgical closure had not been undertaken. With modern investigative methods the diagnosis can now be established with confidence, and furthermore a precise anatomical localization of the defect may be made. Arteriovenous fistulae of the coronary vessels are often small and asymptomatic, but in every case they represent a potential source of serious complications. These include sequelae which may accompany an arteriovenous fistula at any site such as the development of an aneurysm, formation of mural thrombi with occlusion or distal embolization, the production of cardiac enlargement secondary to a high cardiac output, bacterial endocarditis, anemia, glomerulonephritis, and cardiac failure. For these reasons serious consideration should be given surgical correction in every instance.

Anatomical Features. Coronary arteriovenous fistulae have been described in a variety of anatomical patterns. Communications between the coronary arteries may directly enter the 1) right atrium; 2) right ventricle; 3) left atrium; 4) left ventricle; 5) pulmonary artery; 6) coronary sinus; or 7) great coronary vein; and each of these types has been reported. Furthermore, aberrant coronaries may arise anomalously from the aorta which may also similarly communicate with the various cardiac chambers. In a collected review of 61 coronary arteriovenous fistulas in which complete anatomical descriptions were available, the right coronary artery was involved in 30 cases and the left in 20 cases with 11 additional fistulas from *anomalous* coronary arteries arising from the aorta.^{1, 2, 4, 13, 14, 28, 30, 32} The most common site of the fistulous entry is into the right ventricle and this was noted in approximately half the cases (28 of 61).

Clinical Manifestations and Diagnosis. At the time of discovery, the majority of coronary arteriovenous fistulas are asymptomatic. In most instances the lesion is first detected by the presence of a continuous precordial murmur, often thought initially to represent a patent ductus arteriosus. Other conditions which must be differentiated include aortico-pulmonary window, sinus of Valsalva fistula, ventricular septal defect with aortic insufficiency, arteriovenous fistulas of the lung, and fistulas of the subclavian or internal mammary vessels. This is usually possible with present diagnostic methods. The murmur of a coronary arteriovenous fistula is often lower in the chest and is usually more toward the right than found with a patent ductus arteriosus. Furthermore, when the fistula empties into the right ventricle, the intensity of the murmur may be decreased during systole. Frequently, more objective laboratory procedures are required for definitive diagnosis, and cardiac catheterization is

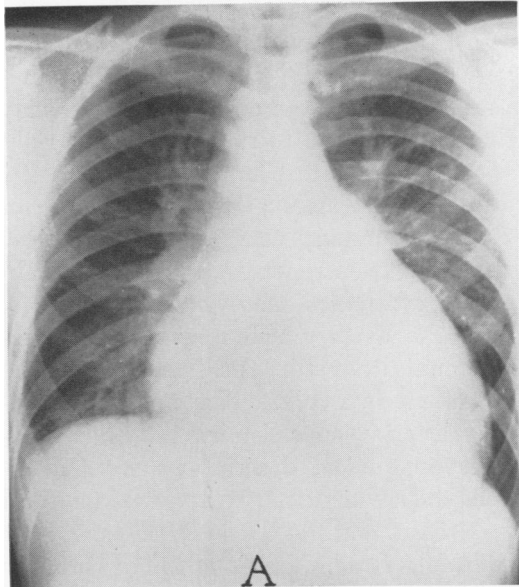


FIG. 1. Films of a 17-year-old boy with a large coronary arteriovenous fistula between the right coronary artery and the right ventricle. A. Chest film showing marked cardiac enlargement.

often helpful. With fistulas which drain into the right heart an increase in oxygen saturation is found at the site of entry. Although many of the shunts are small and some are not detectable by the usual catheterization technics, tremendous flows may occur and shunts exceeding 6.0 l./min. have been recorded.²

Cardiac failure may develop in the presence of large shunts, and death from this cause has been reported on several occasions. One of the most valuable methods of diagnosis is coronary arteriography. The site of the fistula may be demonstrated and additional information is provided concerning the other coronary arteries. If the fistula is a large one, the coronary artery involved is frequently massively dilated and tortuous.

Surgical Management. In 1947, Bjork and Crafoord were the first to record successful closure of a coronary arteriovenous fistula.⁴ This was encountered in a patient thought preoperatively to have a patent ductus arteriosus. An anomalous coronary

artery arising from the aorta was discovered and after a tortuous course was found to enter the pulmonary artery. The vessel was ligated with obliteration of the fistula. Since their report, more than 30 patients have been managed successfully by surgical means.^{2, 13, 14, 28} In most instances operation was performed to correct a continuous precordial murmur, and the most frequent procedure employed has been ligation of the communication at the site of the fistula. Only one operative death has been reported and that in a child with severe associated pulmonary hypertension and patent ductus arteriosus.

We have observed three patients with congenital coronary arteriovenous fistulas in the past several years. One of these is of particular interest in that the condition was associated with virtually *all* the classic manifestations observed in this disorder. This patient is reported in detail.

Case Reports

Case 1. This 17-year-old boy was known to have a heart murmur since birth but was essentially asymptomatic until several months before admission in November 1961. Cardiac catheterization was performed in 1952 and an oxygen stepup in the right ventricle discovered. He was admitted in 1957 for angiocardiology at which time a dilated right coronary artery was demonstrated and a diagnosis of coronary arteriovenous fistula made. In October 1961, the patient noted dyspnea on exertion and shortly thereafter fever and petechiae appeared. He again entered the hospital and was acutely and chronically ill. The positive findings included a temperature, 37.2 C., pulse, 100, and blood pressure, 122/68. Numerous petechiae were present. Examination of the chest showed a right ventricular lift with an apex beat in the fifth interspace outside the midclavicular line. A thrill was palpable in the fourth and fifth left interspaces near the sternal border. A loud continuous murmur was present in the same area, with the systolic component being louder than the diastolic. The second pulmonary sound was accentuated. Positive laboratory findings included a hematocrit of 21, urinalysis positive for albumin and many red cells, carbon dioxide of 15 mEq./l., serum urea nitrogen 43 mEq./l. Several blood cultures were positive for a micro-

aerophilic streptococcus. The chest film showed massive cardiac enlargement (Fig. 1A). A diagnosis of coronary arteriovenous fistula complicated by bacterial endocarditis, glomerulonephritis, anemia, and cardiac enlargement and failure was made. The electrocardiogram showed an axis of +90 with R/S ratio in V-1 of 5/8 and in V-5 12/1. The QRS-complexes were notched. A 2.0 mm. Q-wave was present in Lead III. The T-waves were deeply and symmetrically inverted in Lead III and diphasic in V-4-6. The interpretation was an abnormal record with evidence of right ventricular enlargement and myocardial ischemia.

The patient was treated for six weeks with penicillin during which time he became afebrile and the blood cultures sterile. The anemia and renal insufficiency persisted for a longer period but ultimately the hematocrit rose to 42, the serum urea nitrogen fell to 19 mEq./l., and the carbon dioxide was 20 mEq./l. At this time cardiac catheterization was performed with the following pressures (mm. Hg): right atrium 1.5 (mean), right ventricle 18/-4/0, main pulmonary artery 17/7 (11 mean), left ventricle 81/3, and right coronary artery 81/58. The oxygen saturation in the right atrium was 72 per cent, in the right ventricle 78 to 83 per cent, and in the pulmonary artery 81 per cent. The cardiac output by the Fick method was calculated to be 6.88 L./min. with a cardiac index of 4.15 L./min./M²) and a shunt of 1.98 L./min. passing through the coronary arteriovenous fistula.

Coronary arteriograms were obtained and demonstrated a large flow through the right coronary artery. Rapid injection of a large amount of radioopaque contrast medium was necessary in order

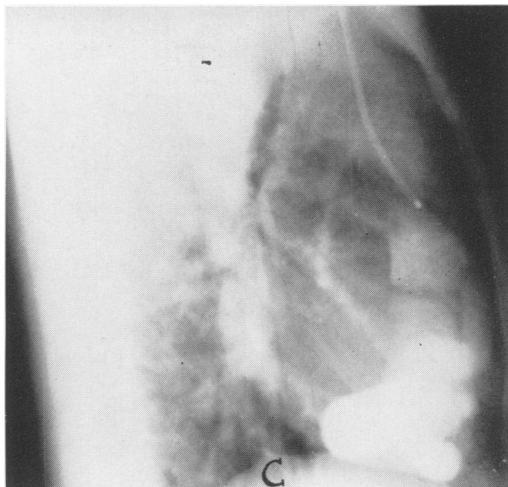


FIG. 1C. Lateral view of Figure 1B.

to visualize the vessel. The right coronary was massively dilated and tortuous and terminated in a large oval chamber emptying into the posterior right ventricle immediately below the tricuspid valve (Fig. 1B, C).³¹ The impression was right coronary artery-right ventricular fistula.

On March 12, 1962 a left anterior thoracotomy was performed with division of the sternum in the fourth intercostal space. The pericardium was opened and the heart found to be greatly enlarged (Fig. 2). The right coronary artery arose normally from the aorta and measured 17 mm. in diameter. It was thin-walled and quite tense. A continuous thrill was palpable in the right ventricle and could be obliterated by compression of the right coronary artery. Palpation with the finger at the termination of the right coronary artery revealed a one centimeter defect entering the right ventricle. It was interesting that the heart could be lifted upward almost at a right angle with little change in the arterial blood pressure making extracorporeal circulation unnecessary. A tape was loosely placed around the right coronary at its origin and a purse-string suture inserted in the right atrial appendage. With the finger inserted through an opening in the atrial appendage and passed through the right atrium, the defect could be palpated just below the tricuspid valve on the posterior ventricular wall. A jet of blood could be felt with the finger following each systolic contraction. Occlusion of the opening with the finger obliterated the thrill. An arterial clamp was then placed on the right coronary at its origin in order to reduce the pressure and to produce a partial collapse of the vessel. The fistula was then closed with five suture-ligatures of silk passed through its margins (Fig.

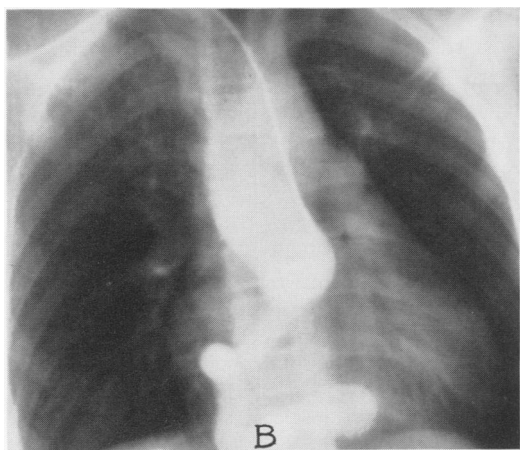


FIG. 1B. Coronary arteriogram showing dilated, tortuous, and aneurysmal right coronary artery with fistula entering the right ventricle.

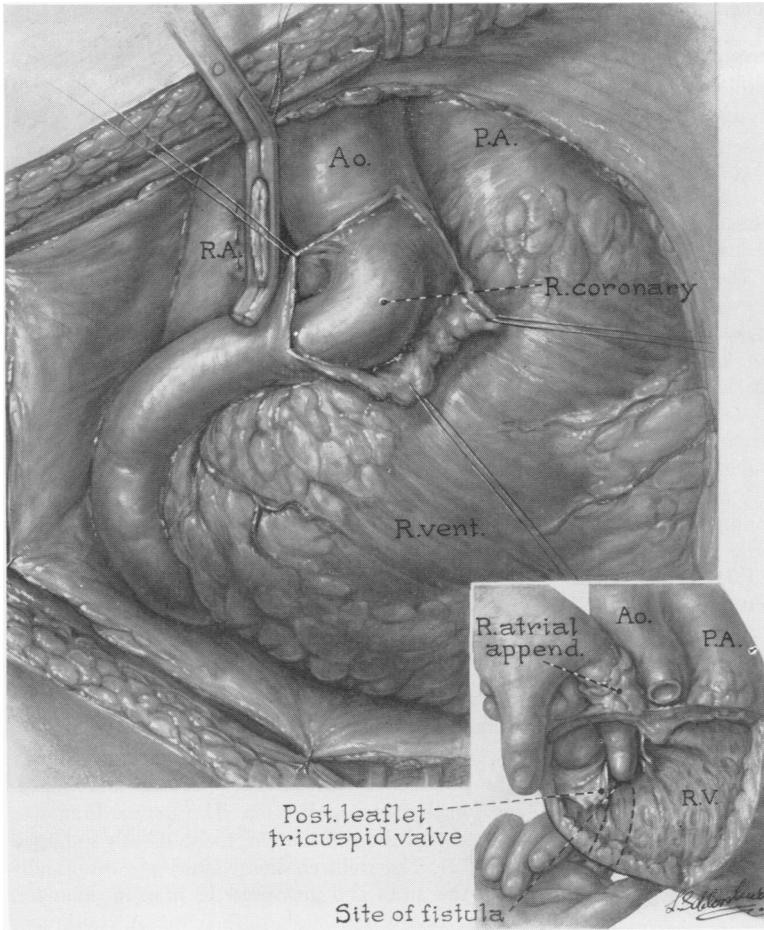


FIG. 2. Coronary arteriovenous fistula as seen at operation showing marked dilatation of the right coronary artery. A finger is introduced through the right atrial appendage and passed into the right ventricle with palpation of the defect (insert). The right coronary artery at its termination communicated with the right ventricle through a fistula 1.0 cm. in diameter.

3). The area was assessed with a finger inside the ventricle and found to be tightly closed. The patient tolerated the procedure quite well and the postoperative course was uneventful. He has been examined on several occasions since with normal physical findings. Chest films reveal continuing diminution in the heart size and the patient seems quite well.

Comment: This patient is an example of a large coronary arteriovenous fistula present for 17 years with the ultimate development of each of the classic complications of this lesion. The complications included cardiac enlargement, bacterial endocarditis, glomerulonephritis, anemia, and high output cardiac failure. These are the findings which are known to occur clinically in severe cases and consistently fol-

low the creation of large experimental arteriovenous fistulas.^{23, 27} In this patient each was reversible following closure of the fistula. The case is illustrative of the complications which may follow an uncorrected arteriovenous fistula and demonstrates the effectiveness of surgical closure.

Case 2. A ten-year-old girl was first admitted at the age of four with a history of having had a heart murmur since the age of two. There was a history of mild exertional dyspnea noted on extreme exercise. The physical examination revealed a loud, Grade III continuous murmur over the entire right chest with maximal intensity in the third and fourth intercostal spaces to the *right* of the sternum. The heart rate was 100 with a regular rhythm and the blood pressure 120/70. The remainder of the physical examination was not remarkable. The electrocardiogram showed a

normal sinus rhythm with a focal bundle branch block in V-1 and inverted T waves in V-1 and V3L, with evidence of right axis deviation and left ventricular preponderance. Chest fluoroscopy and films showed a slightly enlarged heart. An angiocardigram revealed re-opacification of the right atrium at the time the main bolus of dye reached the aorta. At cardiac catheterization an oxygen step-up of 6.0 per cent was present in the right atrium. Operation was performed and a fistula between the right coronary artery and the atrium was identified and closed without difficulty leaving the right coronary artery intact. The child recovered rapidly and remains well.

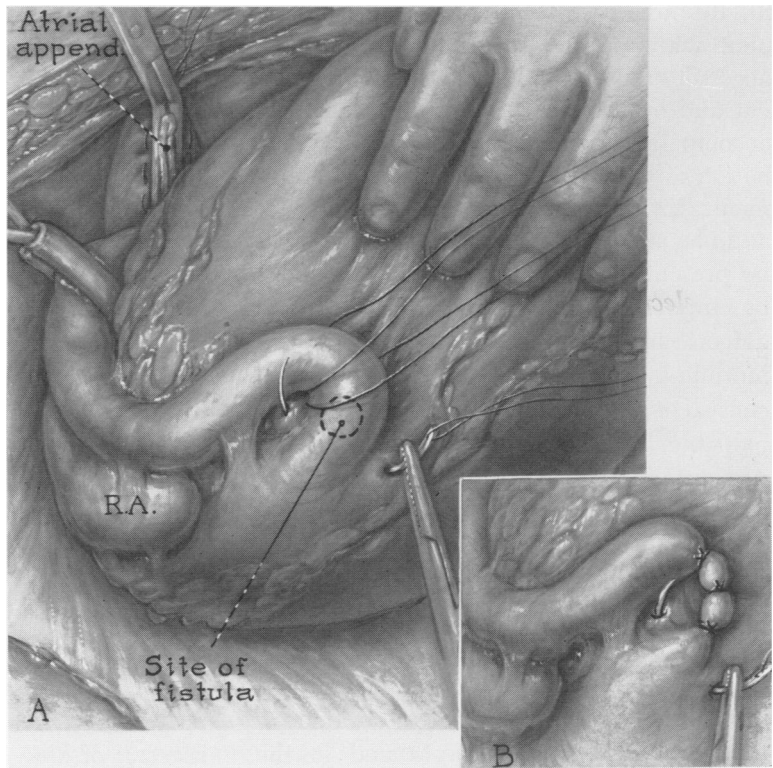
Case 3. A 25-year-old man was examined in the out-patient department for an upper respiratory infection and was found to have a cardiac murmur. The past history was unremarkable and the patient had not had any symptoms referable to the heart. Physical examination revealed a tall, thin, Negro male. The heart was not enlarged on percussion and the PMI was in the sixth interspace 3.0 cm. within the mid-clavicular line. The rhythm was regular. A high pitched, whirring murmur was heard along the left sternal border, most prominent during diastole, and was essen-

tially continuous. The blood pressure was 110/80. The electrocardiogram was interpreted as being within normal limits. The chest film was normal except for a slight increase in the transverse diameter of the heart. A retrograde aortogram was performed with injection of dye into the aorta just above the aortic valve. The right coronary artery was enlarged and tortuous and appeared to branch and form a large arteriovenous malformation at the anterior inferior surface of the right ventricle. The final impression was right coronary artery-right ventricular fistula. Surgical correction has been recommended to the patient.

Congenital Origin of the Left Coronary Artery from the Pulmonary Artery

In 1933, Bland, White and Garland⁵ first described the clinical manifestations and electrocardiographic characteristics of congenital origin of the left coronary artery from the pulmonary artery. For the first time a means was provided for the diagnosis of this condition during life, and there are now nearly a hundred cases reported in the literature.^{3, 6, 8, 15, 17, 26} In the recent

FIG. 3. Coronary arteriovenous fistula. The right coronary artery is temporarily occluded at its origin to render the vessel more flaccid during closure of the opening into right ventricle. Multiple transfixion sutures of silk are employed to close the defect (insert).



past significant advances have been made in clinical diagnosis and surgical management of this malformation and increased attention is being given its management.

Our experience with this condition in infancy has been recently reported.^{26, 31} In most instances the physical examination indicated that the patient is essentially normal at birth and the child continues without evidence of a serious malformation for the first several weeks. Nevertheless, symptoms may appear at birth in a small number and progress rapidly. Among 12 *infants*, two were symptomatic at birth and all were ill by the age of three months.

Symptoms. In infants the first abnormality which is usually noted is rapid and difficult respiration. It has also been observed that some show evidence of *anginal* pain, particularly during and after feeding. Vomiting frequently occurs and attacks of sweating, pallor, and dyspnea are characteristic. On physical examination the infant may appear both acutely and chronically ill. Respiratory difficulty is usually prominent with a rapid rate and with use of accessory muscles. Moist rales may be present and cyanosis of the lips and nail beds accompany the more severe cases. Examination of the heart reveals marked enlargement. In some instances no murmur is audible, although a systolic murmur may be present over the precordium. It should be emphasized that associated intracardiac defects are not uncommon and produce murmurs. Enlargement of the liver is a consistent finding and the spleen is often palpable. In a small group of patients the presenting picture may be that of shock associated with the findings of acute myocardial infarction. Marked tachycardia, hypotension, and peripheral vascular collapse characterize this form of the condition.

The *electrocardiogram* is often characteristic, and the changes closely simulate those associated with myocardial infarction in the adult. The rate is rapid and in the

standard leads, T₁ and T₂ are usually inverted and the S-T segment in Lead I is slightly raised. The T-waves in the precordial leads V₅ and V₆ are usually inverted and deep Q-waves are often present. Additional changes may occur and these findings are critically discussed in a recent review by Keith.¹⁷ On fluoroscopy the heart is massively enlarged, the left atrium and left ventricle being primarily involved. The left cardiac border frequently extends to the lateral rib margin and the pulsations of the left ventricle are markedly diminished. The pulmonary vascular markings are often increased.

Angiocardiography. Injection of radioopaque dye into the right heart demonstrates a normal right atrium and right ventricle. The pulmonary vascularity may be slightly increased, but the striking feature is massive enlargement of the left atrium and left ventricle. The latter is usually markedly dilated and has a very thin wall. The contrast medium may linger for a prolonged period in the left heart, indicating a sluggish circulation secondary to a failing left ventricle. It is rare for the anomalous left coronary artery to be well-filled from the pulmonary artery during angiocardiography. The injection of dye directly into the aorta with filling of the proximal aorta usually demonstrates a normal right coronary artery. This vessel is often larger than normal and communications by collateral vessels with the left coronary artery may at times be clearly demonstrated.

Cardiac Catheterization. The positive findings include a low mixed venous saturation in the right heart and possible elevation of the pulmonary arterial and pulmonary wedge pressures. These changes essentially represent left ventricular failure. Of particular significance is an increase in oxygen saturation in the proximal pulmonary artery and when present indicates a *reversal* of flow in the anomalous coronary

artery.⁹ Our experience with this condition is comprised of observations on 13 patients and their findings and clinical course is summarized in Table 1.

For a number of years it was generally agreed that the left ventricular myocardial infarction which often accompanies this disorder was the result of poor perfusion of the left ventricle by an artery arising from the pulmonary artery with a low pressure and with blood of low oxygen saturation. Edwards¹² suggested the possibility that collateral vessels might connect the normal right coronary with the left coronary and thus permit blood to flow retrograde into the pulmonary artery. This concept was originally proposed by Brooks, in 1886,⁷ and has since been supported by others.^{3, 8, 25}

In a previous communication,²⁵ it was shown that blood in the anomalous left coronary artery is fully saturated with oxygen indicating that it originates from a systemic source rather than from the pulmonary artery.²⁵ Furthermore, by direct measurement at operation the pressure in the left coronary artery *rises* when it is occluded at its origin, indicating that the source of pressure is through collateral communications with the right coronary artery.²⁵ These observations led us to conclude that the flow in the left coronary is *retrograde* and that improvement should follow ligation of the vessel at its origin,²⁵ a procedure which has been performed by others.^{8, 10, 16} It is probable, however, that *retrograde* flow may not occur in the presence of significant pulmonary hypertension, but co-existence of this complication with an anomalous coronary would appear to be uncommon.

Although most of the untreated infants with this malformation die by the age of two years,¹⁷ there is a small group who survive to adult life. George and Knowlan¹⁵ collected 14 adults with congenital origin of the left coronary artery from the pulmonary artery. The mean age of death was

35 years (range of 16–60 years) and 11 in this group died suddenly. Six had an enlarged heart at autopsy and in at least three thinning or fibrosis of the left ventricle was described. The right coronary artery was characteristically enlarged and thin-walled, and the left coronary was also larger than normal. Liebman and associates²¹ report three children (ages 3–14) with this condition, one of whom had congestive failure which was relieved by ligation of the left coronary artery at its origin. An additional patient aged 16 has also been recently reported and in this instance the diagnosis was established by aortography demonstrating the coronary arteries with retrograde flow into the pulmonary artery.¹⁹ Cumming and Ferguson⁹ describe an asymptomatic seven-year-old child with a continuous precordial murmur and a 20 per cent left-to-right shunt in the pulmonary artery. Retrograde aortography demonstrated a large right coronary artery which filled the left coronary artery via collaterals and emptied into the pulmonary artery. She was treated by ligation of the left coronary at its origin with a good recovery.

We recently have observed a fascinating 12-year-old child with a continuous precordial murmur and an enlarged heart. This patient is of sufficient interest to be described in detail:

Case Report

A 12-year-old girl was admitted in September 1961 with the history of a heart murmur since the age of seven months. She remained asymptomatic but at the age of nine the attending pediatrician thought the murmur intensity had increased significantly. Cardiac catheterization was performed elsewhere and showed an equivocal step-up in the right ventricle near the pulmonary valve. On admission the patient was a normally appearing well-developed but slender girl of 12. The blood pressure was 110/65 and the peripheral pulses had a collapsing quality. A soft continuous murmur was present along the lower left sternum, and toward the apex a harsh Grade III systolic murmur was also audible.

TABLE 1. Congenital Origin of the Left Coronary Artery from the Pulmonary Artery Summary of 13 Cases Observed at the Johns Hopkins Hospital

No.	Age at Diagnosis	Symptoms		Signs				Operation	Course	Postmortem Examination			
		Dyspnea	Angina	Cyanosis	Enlarged Heart	Enlarged Liver	Murmurs				Shock	Cardiac Failure	Ischemia on EKG
1	1 day	+		+	+	+	+	+	+	Not done	None	Death at 1 day of cardiac failure	Ventricular septal defect Angioma of mitral valve
2	1 week	+		+	+	+	+	+	+	+	None	Death at 9 days of cardiac failure	Fresh left ventricular focal infarctus Patent ductus arteriosus Ascites
3	2 mos.	+		+	+	+	+	+	+	+	None	Death at 3 mos. of cardiac failure	Left ventricular infarction and calcification
4	3 mos.	+		+	+	+	+	+	+	+	None	Death at 3 mos. of cardiac failure	Left ventricular infarction
5	2 mos.	+		+	+	+	+	+	+	+	None	Death at 4 mos. of cardiac failure	Left ventricular infarction Atrial septal defect
6	10 mos.	+		+	+	+	+	+	+	+	None	Death of v. fibrill. during cardiac catheterization	Infarction of left ventricle with calcification
7	3 mos.	+	+	+	+	+	+	+	+	+	Pulmonary-aortic anastomosis	Death 1 hr. after operation	Infarction of left ventricle & interventricular septum
8	2 mos.	+		+	+	+	+	+	+	+	In refractory shock; attempt to improve by ligation of LCA	Death during operation	Left ventricular infarction
9	3 mos.	+		+	+	+	+	+	+	+	Thoracotomy	Death at beginning of thoracotomy	Left ventricular infarction
10	3 mos.	+		+	+	+	+	+	+	+	De-epicardialization	Living and well 3 years after operation	
11	4 mos.	+		+	+	+	+	+	+	+	De-epicardialization	Living and well 5 years after operation	
12	2 mos.	+		+	+	+	+	+	+	+	Ligation of LCA and de-epicardialization	Living and well 3 years following operation	
13	12 yrs.	+		+	+	+	+	+	+	+	Ligation of LCA	Living and improved 6 mos. after operation	

The chest films and fluoroscopy demonstrated a slight cardiac enlargement. The electrocardiogram showed a sinus rhythm, an axis of -30° , RV-1 5.0 mm., SV-1 21 mm., RV-5 33 mm. with secondary ST-T depressions in the left precordial leads. The impression was left ventricular hypertrophy.

A ciné-angiogram was performed with injection of dye into the proximal aorta demonstrating a large and tortuous right coronary artery. The left coronary artery was thought to fill retrograde and to empty into the pulmonary artery (Fig. 4). Indicator dye dilution curves were obtained which precisely localized the site of the fistula to the pulmonary artery (Fig. 5). Cardiac catheterization data showed pressures (mm. Hg) and oxygen saturations as follows: right atrium: 2.5 (81%); right ventricle: 26/-2/0 (80-83%); pulmonary artery: 22/7 (85%); aorta 103/70 (99%). It was the clinical impression that a coronary arteriovenous fistula might be present emptying into the right ventricle, and accordingly operation was performed through a median sternotomy. The right coronary artery was massively dilated and

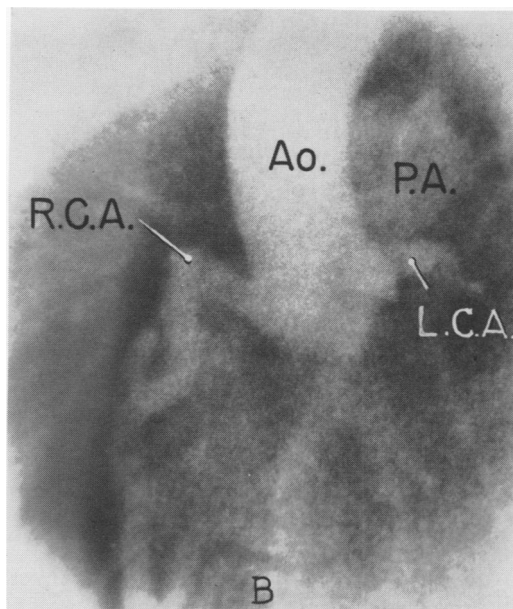


FIG. 4.B. Frame from ciné-arteriogram 1.4 seconds after injection of dye showing filling of the left coronary artery and opacification of the pulmonary artery. With interval frames the left coronary artery could be seen to fill by *retrograde* flow from the right coronary artery (LAO).

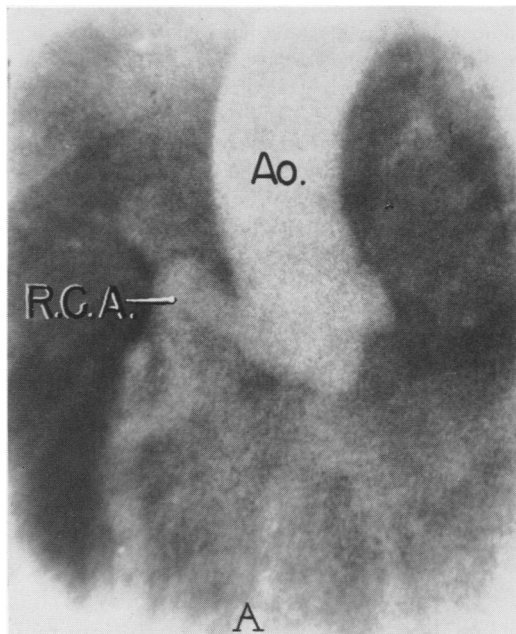


FIG. 4. Coronary arteriogram in 12-year-old patient with congenital origin of the left coronary artery from the pulmonary artery. A catheter was passed into the proximal aorta and 34 ml. of 75 per cent Hypaque® injected with a film speed of 60 frames per second. A. Frame from cine-arteriogram 0.8 seconds after injection showing good filling of a dilated right coronary artery. No dye is seen in the left coronary artery (LAO).

tortuous. A thrill was present at the termination of the right coronary artery and this area was occluded with a transfixion suture of silk. An attempt was made to dissect the left coronary artery and to identify its entrance into the aorta, but the exposure through a median sternotomy was inadequate and retraction of the heart and great vessels caused the cardiac action to become poor and it was not possible to determine this point. Post-operatively the patient was not improved and the heart remained enlarged. She continued to have a prominent murmur similar to that present pre-operatively and also developed a tachycardia with gallop rhythm requiring digitalis. It became apparent that something further was necessary and she was re-admitted and a second ciné-angiogram was obtained with selective injection of the right coronary artery. These films conclusively demonstrated origin of the left coronary artery from the pulmonary artery with retrograde flow. The right coronary could be seen to fill with passage of the dye through large collaterals into the left coronary artery with ultimate entry of the dye *retrograde* into the pulmonary artery. A pulmonary arteriogram showed slight reflux of dye into the proximal portion of the left coronary artery during the Valsalva maneuver, at which time the pulmo-

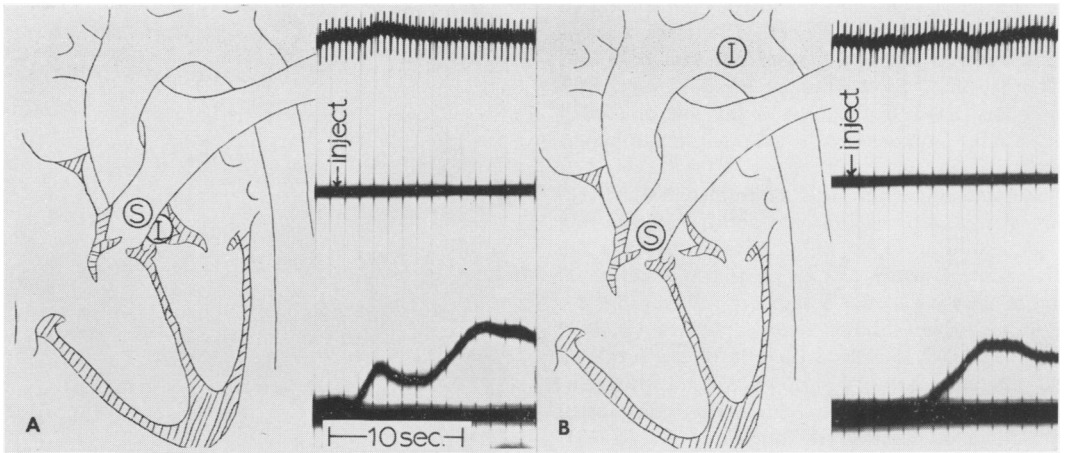


FIG. 5.* Indicator dilution curves for shunt detection and localization. A. Cardiogreen® dye injected in the aortic root (I) with sampling in the pulmonary artery (S) indicated an early appearance (shunt) curve at 1.5 seconds followed by a larger (systemic) curve at 6 seconds. B. An injection in the usual ductus area (I) with pulmonary artery sampling (S) revealed a single curve at 5 seconds representing systemic circulation only. The injection site was therefore downstream from the origin of the left-to-right shunt.

nary arterial pressure was increased with a concomitant decrease in aortic pressure. The dye was seen to reflux into the proximal left coronary artery in diastole. On the basis of these data all those attending the patient were convinced that the basic difficulty was an anomalous left coronary artery arising from the pulmonary artery.

Operation was performed through a left posterolateral thoracotomy, and an enlarged heart was

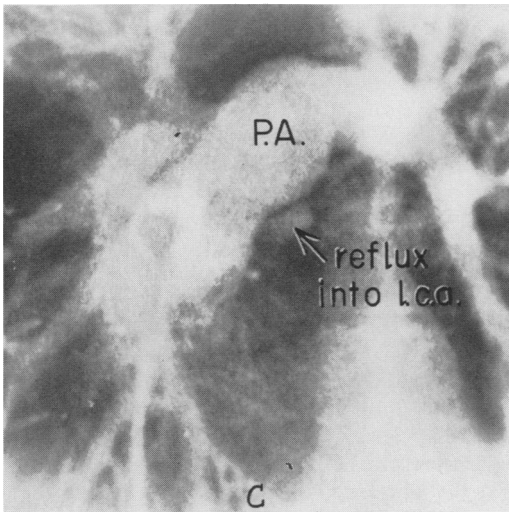


FIG. 4C. Pulmonary arteriogram showing "reflux" of dye into the portion of the left coronary artery in diastole and during the Valsalva maneuver. At this time the pulmonary arterial pressure was elevated and the aortic pressure decreased.

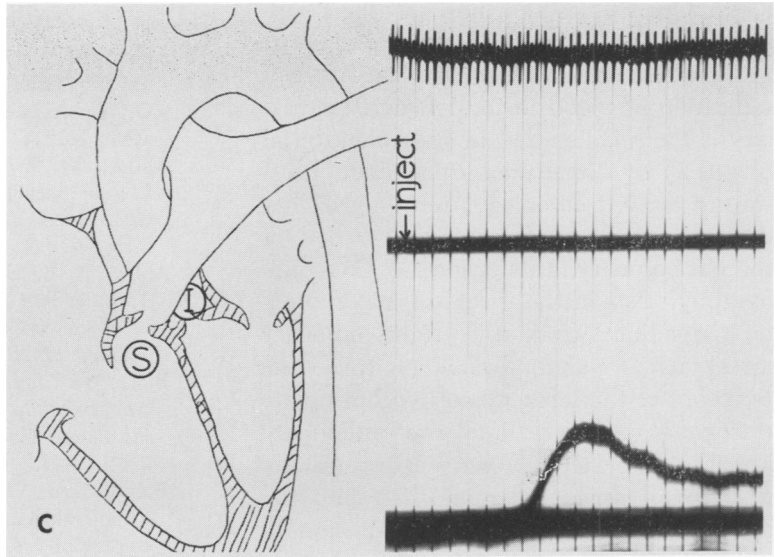
exposed. The left coronary artery was dissected and was found to enter the pulmonary artery (Fig. 6). A systolic thrill was palpable in the pulmonary artery which disappeared on compression of the left coronary artery. The left coronary artery was then triply ligated at its origin with sutures of silk. After ligation the pressure in the anterior descending coronary artery was 115/40 and the oxygen saturation of the blood within it was 95 per cent indicating excellent collateral circulation. Furthermore, the artery became larger and more tense *after* ligation, confirming that previously blood had been drained into the pulmonary artery. The child made an uneventful post-operative recovery and the heart has gradually become smaller. The gallop rhythm has disappeared and she is now considerably improved.

Discussion

Congenital origin of the left coronary from the pulmonary artery is being accurately diagnosed with increasing frequency during infancy, and more recently it has been recognized that the condition may

* Note. A factor of +4.5 seconds was used on all of the injection times on the above curves to correct for the 4.5 second delay imposed by the dead space in the catheter sampling system. The prolonged washout of the systemic curves may be due to the left-to-right shunt or distortion caused by the long sampling system.

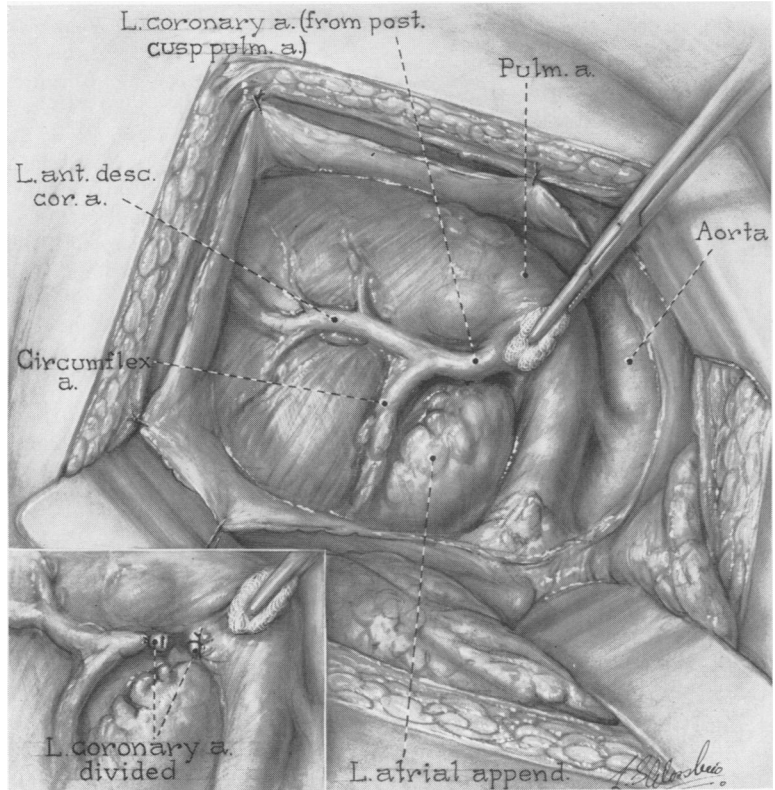
FIG. 5C. An injection in the aortic root (I) with sampling in the right ventricular outflow tract (S) revealed systemic circulation only (5.5 seconds). The sampling site was therefore upstream from the termination of the left-to-right shunt.



occur in older children and even in adults. The pathogenesis of the myocardial ischemia which frequently occurs under these circumstances has been a controversial sub-

ject, but there is increasing evidence that blood in the left coronary artery flows *retrograde* into the pulmonary artery thereby depriving the left ventricle of oxygenated

FIG. 6. Congenital origin of left coronary artery from pulmonary artery as seen through a left posterolateral thoracotomy. The origin of coronary from the pulmonary artery is clearly demonstrated as are the anterior descending and circumflex branches. The vessel is occluded at its origin with suture-ligatures.



blood. Our studies and those of others support this concept for the following reasons: 1) determinations showing that oxygen saturation of blood in the left coronary artery is the *same* as that in systemic arterial blood; 2) by direct measurement the pressure in the left coronary artery approaches the systemic level following *occlusion* of the left coronary at its origin; 3) ciné-angiography demonstrates passage of contrast medium from the right coronary artery across collateral channels to fill the branches of the left coronary with ultimate *retrograde* drainage into the pulmonary artery; 4) the left coronary artery usually *fails* to fill during dye injection into the pulmonary artery save for a small amount of diastolic *reflux* at the coronary ostium, especially during the Valsalva maneuver; and 5) *improvement* in the clinical course occurs following ligation of the vessel at its origin.

The *ideal* surgical management of this malformation is the anastomosis of the left coronary to a systemic artery. This has been attempted but without success.¹⁷ It is our present view that this disorder is best managed by ligation of the left coronary at its origin, a simple procedure which has produced gratifying results in our experience and in that of others.

Summary

The clinical manifestations of three patients with congenital arteriovenous fistula and 13 with congenital origin of the left coronary artery from the pulmonary artery are presented. Emphasis is placed upon the fact that with improved investigative methods, particularly coronary arteriography, a precise diagnosis and localization of these lesions may be made with accuracy. The complications which may occur in untreated patients is contrasted with the favorable course of those managed by surgical correction.

Bibliography

1. Abbott, M. E.: Anomalies of the Coronary Arteries in Osler's Modern Medicine, edited by O. W. McCrae. Philadelphia, Lea & Febiger, 1906, vol. IV, p. 420.
2. Abbott, O. A., C. H. Rivarola and R. B. Logue: Surgical Correction of Coronary Arteriovenous Fistula. *J. Thor. & Cardiovasc. Surg.*, 42:660, 1961.
3. Apley, J., R. E. Horton and M. G. Wilson: The Possible Role of Surgery in the Treatment of Anomalous Left Coronary Artery. *Thorax*, 12:28, 1957.
4. Bjork, G. and G. Crafoord: Arteriovenous Aneurysm on the Pulmonary Artery Simulating Patent Ductus Arteriosus Botalli. *Thorax*, 2:65, 1947.
5. Bland, E. F., P. D. White and J. Garland: Congenital Anomalies of Coronary Arteries: Report of an Unusual Case Associated with Cardiac Hypertrophy. *Am. Heart J.*, 8:787, 1933.
6. Boshier, L. H., V. Sverre, C. M. McCue and L. F. Belter: Congenital Coronary Arteriovenous Fistula Associated with Large Patent Ductus. *Circulation*, 20:254, 1959.
7. Brooks, H. St. J.: Two Cases of an Abnormal Coronary Artery of the Heart Arising from the Pulmonary Artery; with Some Remarks Upon the Effect of this Anomaly in Producing Cirroid Dilatation of the Vessels. *J. Anat. & Physiol.*, 20:26, 1886.
8. Case, R. B., A. G. Morrow, W. Stainsby and J. O. Nestor: Anomalous Origin of the Left Coronary Artery. The Physiologic Defect and Suggested Surgical Treatment. *Circulation*, 17:1062, 1958.
9. Cumming, G. R. and C. C. Ferguson: Anomalous Origin of the Left Coronary Artery from the Pulmonary Artery, Functioning as a Coronary Arteriovenous Fistula. *Am. Heart J.*, 65:690, 1962.
10. Davis, E. W.: Cited in Case *et al.*⁸
11. DiGuglielmo, L. and M. Guttadauro: A Roentgenologic Study of the Coronary Arteries in the Living. *Acta radiol. Suppl.*, 97, 1952.
12. Edwards, J. E.: Functional Pathology of Congenital Cardiac Disease. Philadelphia, W. B. Saunders Company, *Pediat. Clin. North America*, 1954, vol. 1, p. 13.
13. Fell, E. H., M. Weinberg, A. S. Gordon, B. M. Gasul and F. R. Johnson: Surgery for Congenital Coronary Artery Arteriovenous Fistula. *Arch. Surg.*, 77:331, 1958.
14. Gasul, B. M., R. A. Arcilla, E. H. Fell, J. Lynfield, P. Bicoff and L. L. Luan: Congenital

- Coronary Arteriovenous Fistula; Clinical, Phonocardiographic, Angiocardiographic, and Hemodynamic Studies in Five Patients. *Pediatrics*, 25:3, 1960.
15. George, J. M. and D. M. Knowlan: Anomalous Origin of the Left Coronary Artery from the Pulmonary Artery in an Adult. *N. Engl. J. Med.*, 261:993, 1959.
 16. Jahnke, E. J.: Cited in Case *et al.*⁸
 17. Keith, J. D.: The Anomalous Origin of the Left Coronary Artery from the Pulmonary Artery. *Brit. Heart J.*, 21:149, 1959.
 18. Krause, W.: *Ztschr. f. rat. Med.*, 24, 1865.
 19. Lampe, C. F. J. and A. P. M. Verheugt: Anomalous Left Coronary Artery. Adult Type. *Am. Heart J.*, 59:769, 1960.
 20. Lang, E. K. and D. C. Sabiston: Coronary Arteriography in the Selection of Patients for Surgery. *Radiology*, 76:32, 1961.
 21. Lemmon, W. M., J. S. Lehman and R. A. Boyer: Suprasternal Transaortic Coronary Arteriography. *Circulation*, 19:47, 1959.
 22. Liebman, J., J. Ankenen and H. K. Hellerstein: Anomalous Left Coronary Problem in Older Children. Abstract. *Circulation*, 22: Part II, 751, 1962.
 23. Lillehei, C. W., J. R. R. Robb and M. B. Visscher: The Occurrence of Endocarditis with Valvular Deformities in Dogs with Arteriovenous Fistulae. *Ann. Surg.*, 132:577, 1950.
 24. Rousthoi: Uber Angiokardiographie. Vorlaufige Mitteilung. *Acta radiol.*, 14:419, 1933.
 25. Sabiston, D. C., C. A. Neill and H. B. Taussig: The Direction of Blood Flow in Anomalous Left Coronary Artery Arising from the Pulmonary Artery. *Circulation*, 22:591, 1960.
 26. Sabiston, D. C., S. Pelargonio and H. B. Taussig: Myocardial Infarction in Infancy: the Surgical Management of a Complication of Congenital Origin of the Left Coronary Artery from the Pulmonary Artery. *J. Thor. & Cardiovasc. Surg.*, 40:321, 1960.
 27. Sabiston, D. C., E. O. Theilen and D. E. Gregg: Physiologic Studies in Experimental High Output Cardiac Failure Produced by Aortic-Caval Fistula. *Surgical Forum*, 6:223, 1955.
 28. Sanger, P. W., F. H. Taylor and F. Robicsek: The Diagnosis and Treatment of Coronary Arteriovenous Fistula. *Surgery*, 45:344, 1959.
 29. Sones, F. M. and E. K. Shirey: Cine Coronary Arteriography. *Modern Concepts of Cardiovascular Disease*, 31:735, 1962.
 30. Steinberg, I., J. S. Baldwin and C. T. Dotter: Coronary Arteriovenous Fistula. *Circulation*, 17:372, 1958.
 31. Taussig, H. B.: Congenital Malformations of the Heart. The Commonwealth Fund. Harvard University Press, Cambridge, Mass., 1960.
 32. Upshaw, C. B.: Congenital Coronary Arteriovenous Fistula: Report of a Case with an Analysis of 73 Reported Cases. *Am. Heart J.*, 63:399, 1962.
 33. Williams, J. A., *et al.*: Coronary Arteriography. II. Clinical Experiences with the Loop-End Catheter. *N. Engl. J. Med.*, 262:328, 1960.

DISCUSSION

DR. FRED TAYLOR (Charlotte): Our group in Charlotte has been interested in this operation for some time now. I think it is interesting from an historical standpoint that this procedure developed in widely separated areas independently. In 1950, Carlon, in Italy, first described this procedure as far as we can determine.

Shoemaker, in 1955, was the first to attempt this operation clinically. Unfortunately, he lost both of his patients, apparently because they had pulmonary hypertension. As Dr. Young pointed out, pulmonary hypertension is now known to be a contra-indication to the procedure. The first clinical success was in Russia in 1956 and then in 1958, Glenn and Rasmussen and our own group reported clinical successes (slide).

This is a four-year follow up of a patient who had transposition and pulmonary stenosis, showing that the shunt still works. The patient is

still clinically improved and doing well, attends school, can stand on his head, and put this anastomosis to a test (slide).

We, too, have used this operation in the desperately-ill cyanotic young children with tetralogy of Fallot as a palliative, temporizing procedure.

There is one technical difference we have compared with that of Dr. Young. We have preferred the end-to-end superior vena cava-pulmonary artery anastomosis, leaving the azygos vein open for decompression, while the vessels were clamped off. The azygos vein is ligated after the anastomosis is completed and the clamps removed.

It is very important that the azygos be ligated, as noted on the next slide. The azygos vein was left open in this case of tetralogy of Fallot. The child did not do as well as we had hoped. The cyanosis did not clear as much as we usually see, and she did not gain weight. This may be called an azygos steal syndrome, in which much of the blood is shunted into the inferior vena cava system.