

Encapsulated Ruffini-like endings in human lumbar facet joints

F. VANDENABEELE, J. CREEMERS, I. LAMBRICHTS, P. LIPPENS AND M. JANS

Department of Basic Medical Sciences, Limburgs Universitair Centrum, Diepenbeek, Belgium

(Accepted 29 July 1997)

ABSTRACT

The innervation of the human lumbar facet joint capsule was studied by light and electron microscopy. Small numbers of encapsulated corpuscular endings were identified in the dense fibrous layer. Clusters of 2 types of endings were found: small cylindrical corpuscles (type 1) and large fusiform corpuscles (type 2). The corpuscles were classified structurally as Ruffini-type endings. The 1st type was predominant and characterised by a compartmentalised receptor complex, a thin perineurial capsule and a narrow subcapsular space. The 2nd type was characterised by a thicker perineurial capsule, a 'spindle-like' receptive complex, and an extensive subcapsular space with capillaries and concentrically oriented fibroblast-like cells. Both types of endings were innervated mainly by thinly myelinated group III (A delta) and unmyelinated group IV (C) nerve fibres that branched and terminated in the receptor complex. Their sensory endings were intimately related to the collagen fibre bundles as multiple enlarged axonal segments ('beads') with ultrastructural features which were characteristic of receptive sites: an accumulation of mitochondria and vesicles, and 'bare' areas of axolemma lacking a Schwann cell investment but covered by a thin basal lamina. Some beads in the 2nd type of ending contained granular vesicles, 30–60 nm in diameter, resembling sympathetic nerve endings. Small diameter collagen fibrils situated within multilayered basal laminae were found among the multiple receptive sites in the receptive complex in both types of ending. Their possible functional significance in mechanoreception is discussed. Particular attention has been given to their apparent variable orientation to the mechanoreceptive site.

Key words: Spine; mechanoreceptors.

INTRODUCTION

The morphology and innervation of the facet joint has long been a subject of great interest in the orthopaedic and neurosurgical literature (Gilette et al. 1993; Mehta & Parry, 1994; Yamashita et al. 1996). Immunohistochemical investigations demonstrated the presence of an autonomic and sensory innervation (Giles & Harvey, 1987; El-Bohy et al. 1988; Cavanaugh et al. 1989; Gronblad et al. 1991; Ashton et al. 1992; Ahmed et al. 1993; Beamen et al. 1993). Recently, Vandenabeele et al. (1995) reported the ultrastructural characteristics of noncorpuscular nerve endings in the capsule of human lumbar facet joints. A variety of corpuscular endings have been

observed in the fibrous capsule of the facet joints (Ozaktay et al. 1991; McLain, 1994). Their typification was based on the morphofunctional classification of articular receptors introduced by Freeman & Wyke (1967). Ultrastructural data on mechanoreceptive endings in the facet joint are completely lacking. Electrophysiological studies identified mechanosensitive afferent units in the facet joint capsule (Cavanaugh et al. 1989; Yamashita et al. 1990; Avramov et al. 1992; Pickar & McLain, 1995). Pickar & McLain (1995) demonstrated that a majority of slowly adapting mechanosensitive units in the facet joint capsule of the human lumbar spine have a tonic discharge and are responsive to distraction and compression of the capsule in a graded fashion relative

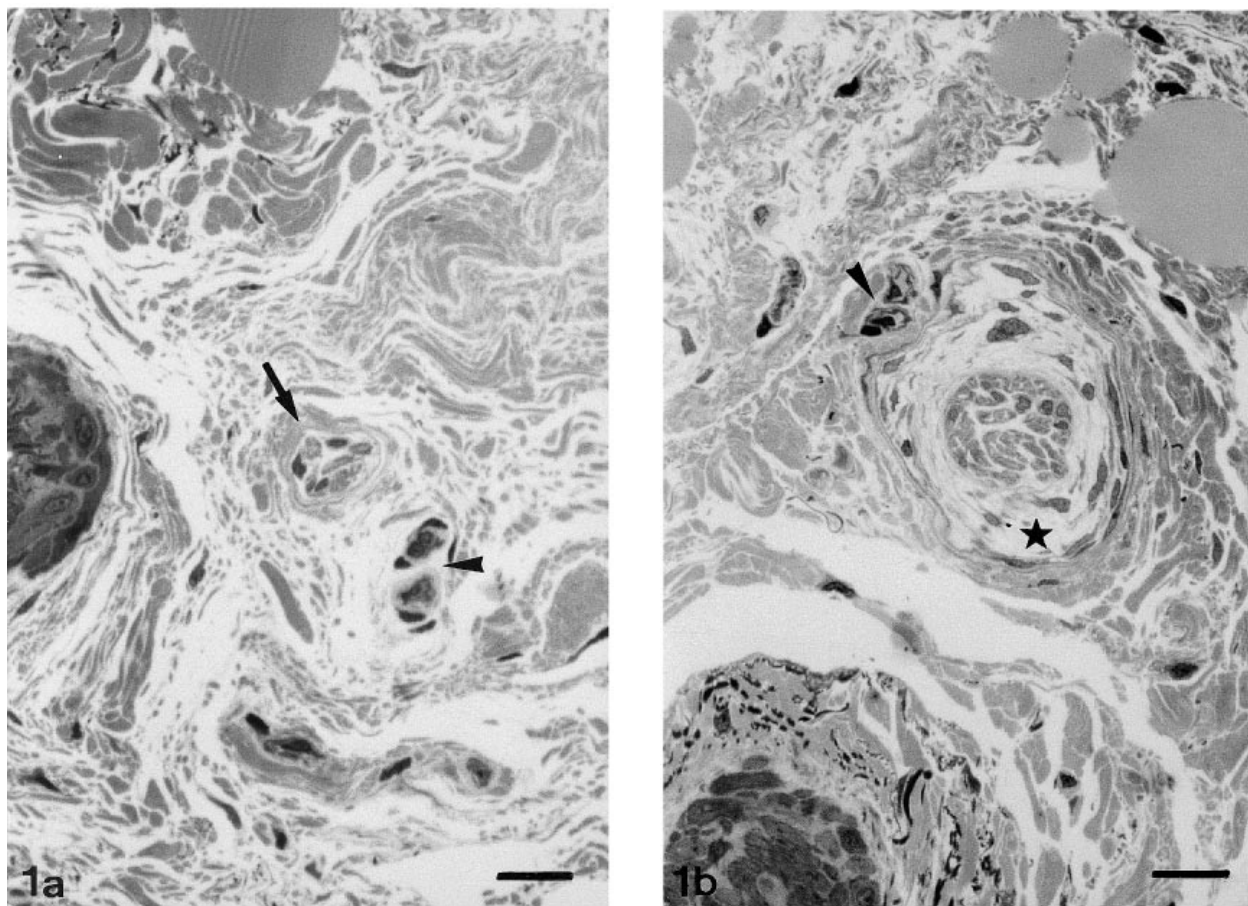


Fig. 1. Light micrographs of thionin–methylene blue-stained sections of the dense fibrous capsule. (a) Type 1 encapsulated nerve ending (arrow) adjacent to blood vessels (arrowhead). (b) Type 2 ending. Note the blood vessels (arrowhead) before entering the extensive subcapsular space (asterisk). Bar, 25 µm.

to the direction of force applied, and assumed that they probably represent a Ruffini-type ending. Functionally, the Ruffini ending is believed to act as a slowly adapting stretch receptor with tonic discharge (Chambers, 1969; Chambers et al. 1972) that mediates in protective muscle reflexes (Johansson et al. 1991; Schenk et al. 1996).

The facet joint capsule of the human lumbar spine appears to be richly supplied by Ruffini-type nerve endings (Ozaktay et al. 1991). They probably ensure postural stability and are well suited to function as spinal column proprioceptors (Pickar & McLain, 1995). We investigated the ultrastructure of the Ruffini-type nerve endings present in the human lumbar facet joint and sought to determine whether they display specific features that could explain their directional sensitivity to spinal loading. Special attention was thereby given to the structural specialisations at their mechanoreceptive sites. Possible mechanisms for mechanoelectric transduction are discussed.

MATERIAL AND METHODS

Biopsy specimens of the facet joint capsule at lumbosacral spinal levels were obtained from 12 patients with significant low back pain and sciatica, undergoing posterior fusion operations. The patients were healthy apart from their spinal pathology. Tissue specimens of the inferolateral area of macroscopically intact capsules were excised with a sharp scalpel and fine forceps from both facets within each operative field. A careful examination and orientation within each sampled level were carried out in order to avoid harvesting adjacent tissue, and to make sure of receiving comparable samples from each joint. Care was taken to avoid tissue trauma during surgery and sampling.

The fresh surgical specimens were dissected in 1 mm³ blocks and immediately immersed in a solution of 2% glutaraldehyde in 0.05 M cacodylate buffer (pH 7.3) for 24–48 h. Tissue was postfixed in 2% osmium tetroxide for 1 h, contrasted with 2% uranyl

acetate in 10% acetone for 20 min, and embedded in Araldite. Semithin sections (0.5 μm) were stained with a solution of thionin and methylene blue (0.1% aqueous solution) for light microscopic examination to identify neural structures.

Presumptive corpuscular endings were often difficult to identify in semithin sections by light microscopy. Many tissue specimens were harvested and sectioned to find the areas illustrated in the present report. Serial sectioning avoided misinterpretation of size. Verification of presumptive corpuscular nerve endings on serial semithin sections by light microscopy was based on one or more of following criteria: (1) corpuscular structure with varying degree of encapsulation, (2) structure identifiable on consecutive sections, (3) inner core with parent nerve fibres and varying degree of compartmentalisation. Final verification of the mechanoreceptor ending was made by electron microscopy.

RESULTS

Small numbers of corpuscular nerve endings, structurally classified as a Ruffini-type ending, were identified in the dense fibrous capsule of the facet joint. They were found in fibroadipose septa and usually accompanied blood vessels. Neural structures were not found in the synovial membrane.

Light microscopy

Two types of encapsulated Ruffini-like corpuscles were readily identified. A small diameter cylindrical Ruffini-type ending was predominant (type 1). Type 1 endings were regularly clustered and easily recognised by light microscopy as compartmentalised entities with a minute subcapsular space (Fig. 1*a*). Their diameter measured $\sim 20\text{--}25\ \mu\text{m}$. Additionally, a remarkably large encapsulated Ruffini-type corpuscle was found, up to 500 μm in total length (type 2). The latter were characterised by a distinct inner core and extensive subcapsular space (Figs 1*b*, 2*a*, *b*). Towards their polar region type 2 endings were fusiform in shape. Their main body measured 70 μm on average.

Electron microscopy

Ultrastructurally, attenuated cytoplasmic extensions of fibroblast-like 'septal cells' (Schoultz & Swett,

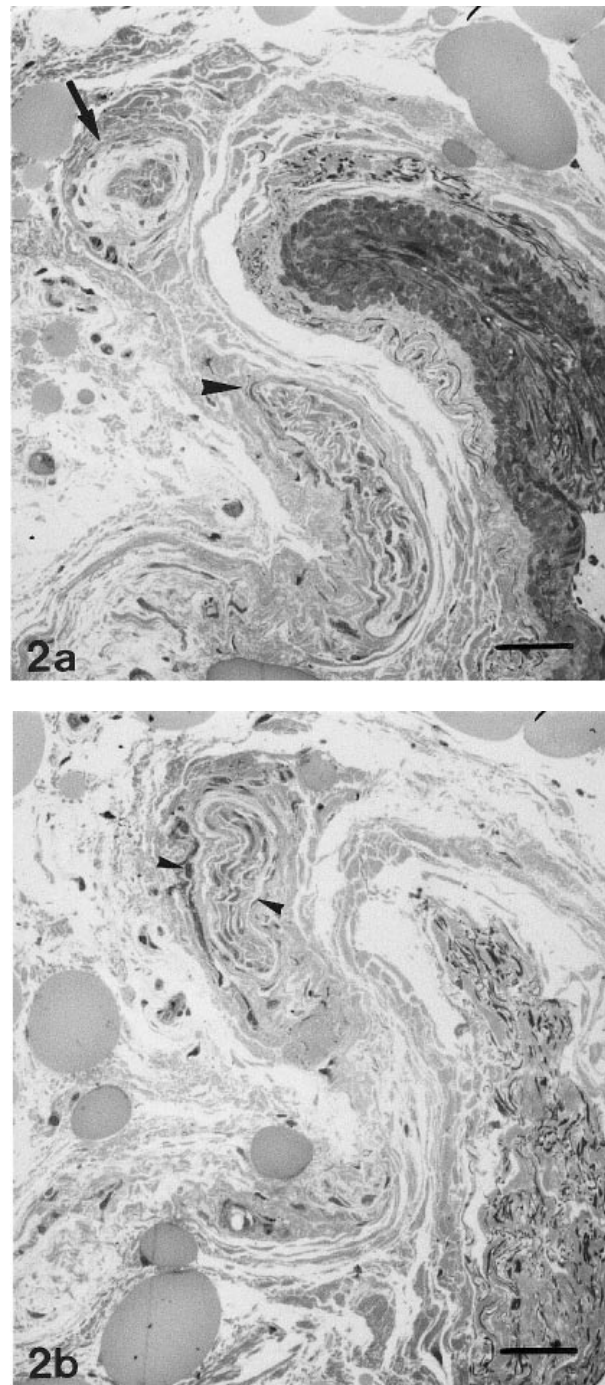


Fig. 2. Consecutive light micrographs of a type 2 ending in the dense fibrous capsule. (a) Afferent bundle (arrowhead) approaching the corpuscular ending (arrow). (b) After transition of the bundle and the ending (small arrowheads). Bar, 25 μm .

1972) compartmentalised the capsular space of the type 1 ending into 3–5 compartments (Fig. 3). The receptive complex was loosely arranged within these compartments.

The receptive complex of the type 2 ending was arranged as a 'spindle-like' inner core, about 40 μm in diameter. This core was separated from the perineurial

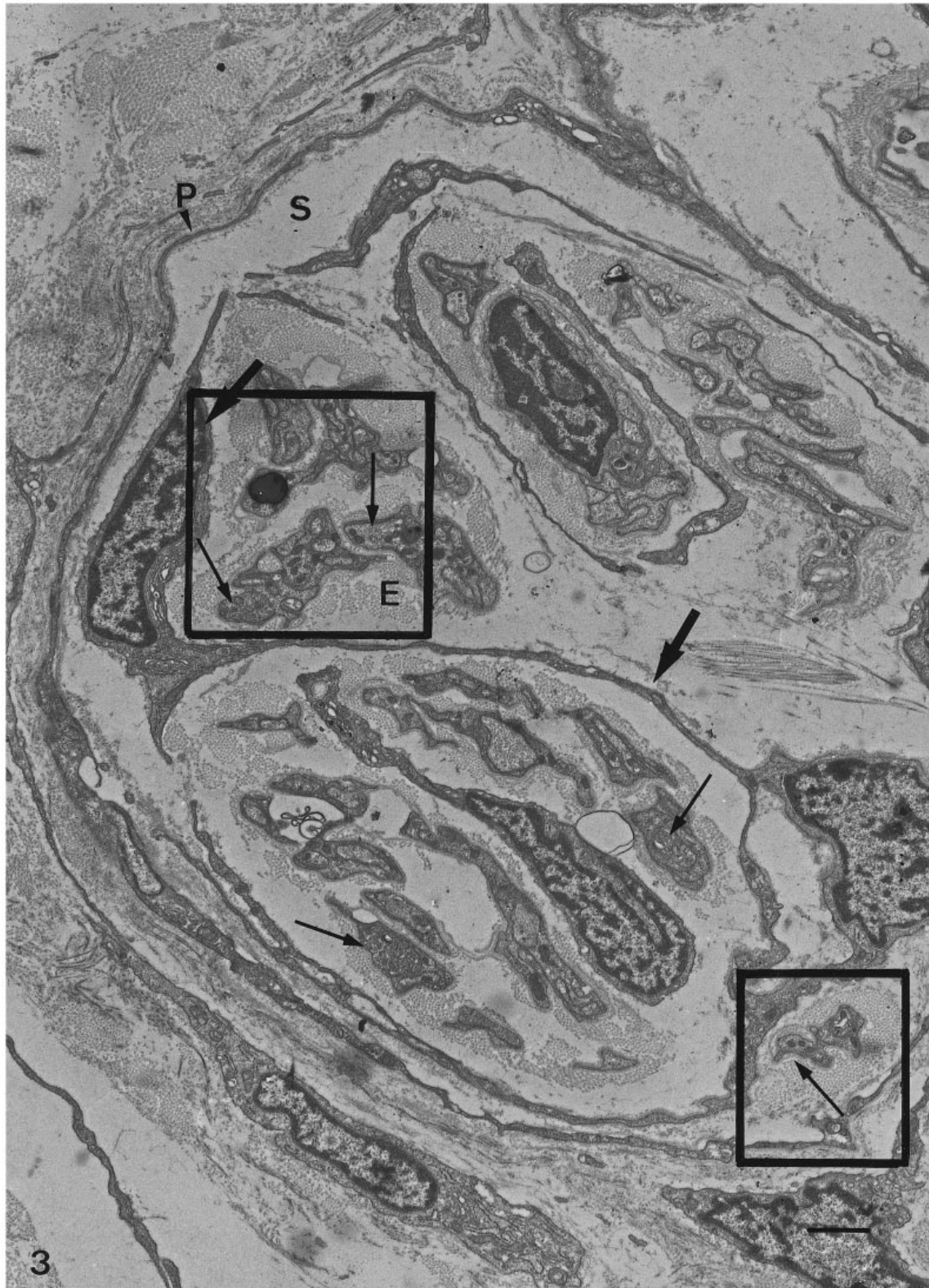

Fig. 3. Electron micrograph of a typical type 1 ending showing its dense fibrous capsule. The receptor complex is situated within several compartments of the capsular lumen, bounded by thin cytoplasmic processes of fibroblast-like septal cells (thick arrows). Note the small subcapsular space (S). Endoneurial connective tissue (E); nerve profiles (thin arrows); perineurial capsule (P). Bar, 1 μ m.

capsule by an extensive subcapsular space, measuring up to 25 μ m in width (Fig. 4). This subcapsular space was traversed by a web of delicate cell processes from

concentrically oriented fibroblast-like cells, referred to as inner capsular cells. These inner capsular cells were only locally lined by a basal lamina, on average 50 nm

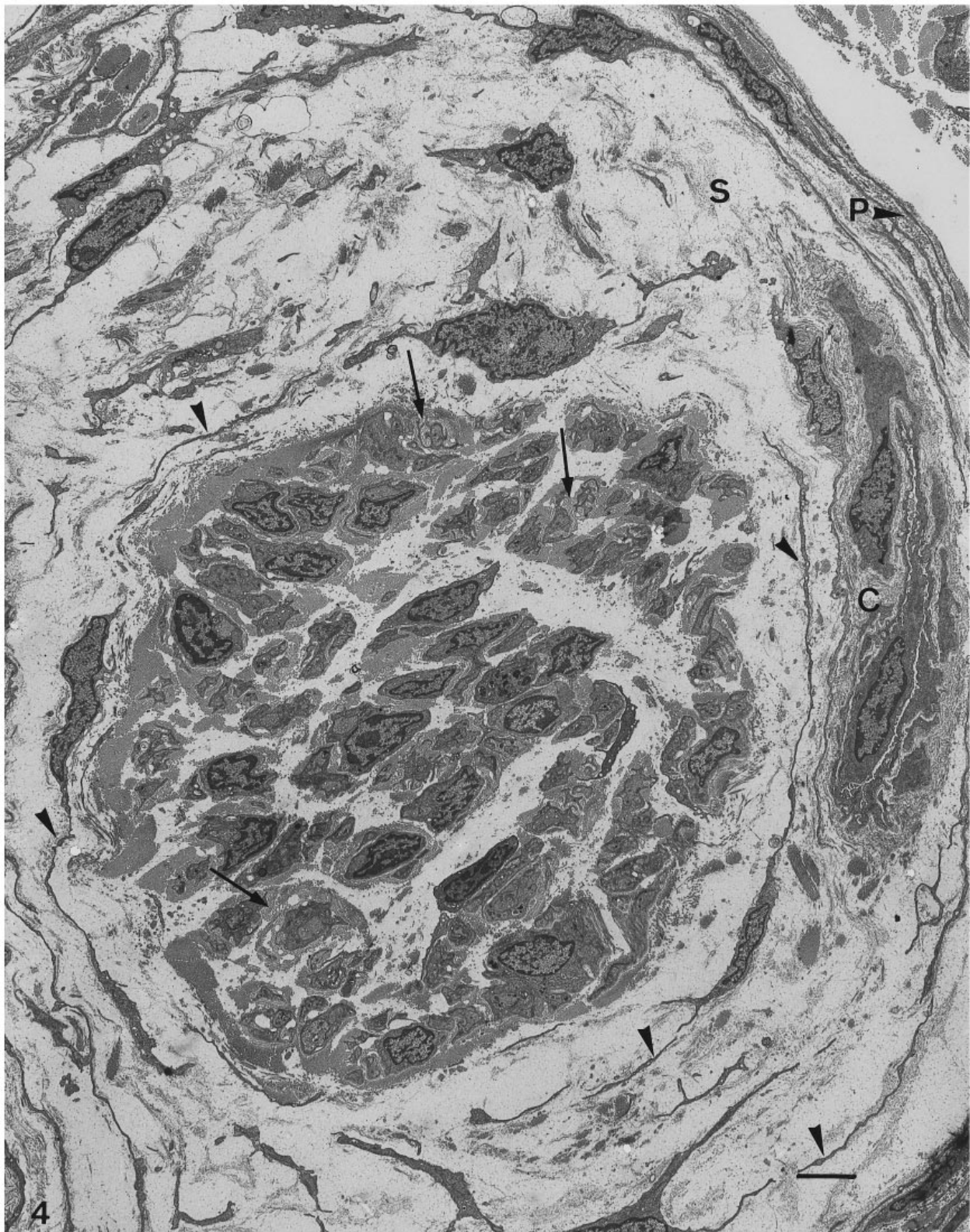


Fig. 4. Electron micrograph of a typical type 2 ending characterised by a dense fibrous capsule, an extensive subcapsular space (S), a 'spindle-like' receptive complex, and perineurial capillaries (C). Note that the subcapsular space is traversed by delicate cell processes (arrowheads) of concentrically arranged inner capsular cells. P, outer (perineurial) capsular cells; arrows, focally multilayered basal laminae within the receptor complex. Bar, 3 μ m.

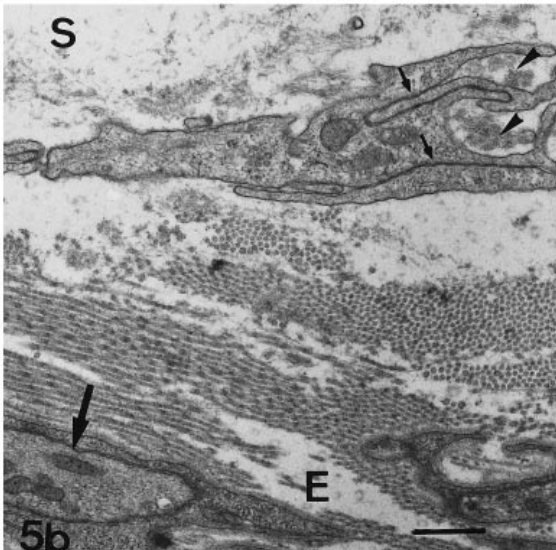
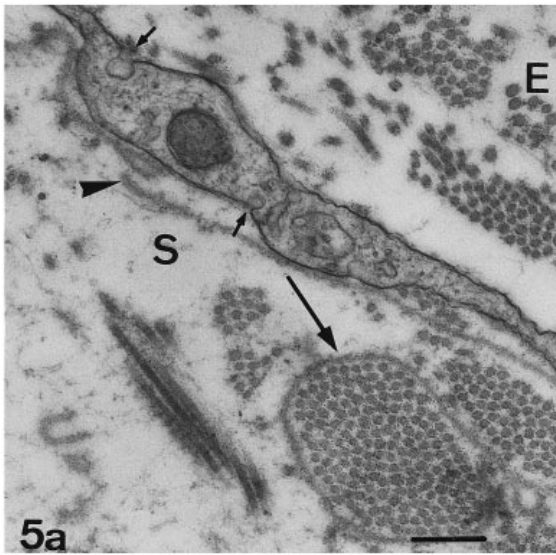


Fig. 5. Electron micrographs of inner capsular cells in the subcapsular space (S) of the 2nd type of ending. E, endoneurial connective tissue. (a) Cell process with detached basal lamina (arrowhead). Loops of basal lamina enclosing a collagen bundle (large arrow). Small arrows, micropinocytotic caveolae. Bar, 295 nm. (b) Specialised intercellular contacts recognised as sequences of tight junctions (small arrows). Arrowheads, groups of microfibrils; large arrow, group III axonal bead. Bar, 630 nm.

(Fig. 5a). The subcapsular space enclosed several collagen bundles. Some of these collagen bundles were ensheathed by loops of basal lamina, or by hook-like cell processes of inner capsular cells (Fig. 5a).

The capsule of both types of endings consisted of concentric layers of the flat perineurial cells (1–2 in type 1, 3–4 in type 2). Perineurial cells were lined on both sides by a continuous basal lamina and separated by narrow intercellular spaces. These intercellular spaces included collagen fibrils, a few scattered bundles of microfibrils, and some unmyelinated nerve fibres. The perineurial cells were referred to as outer

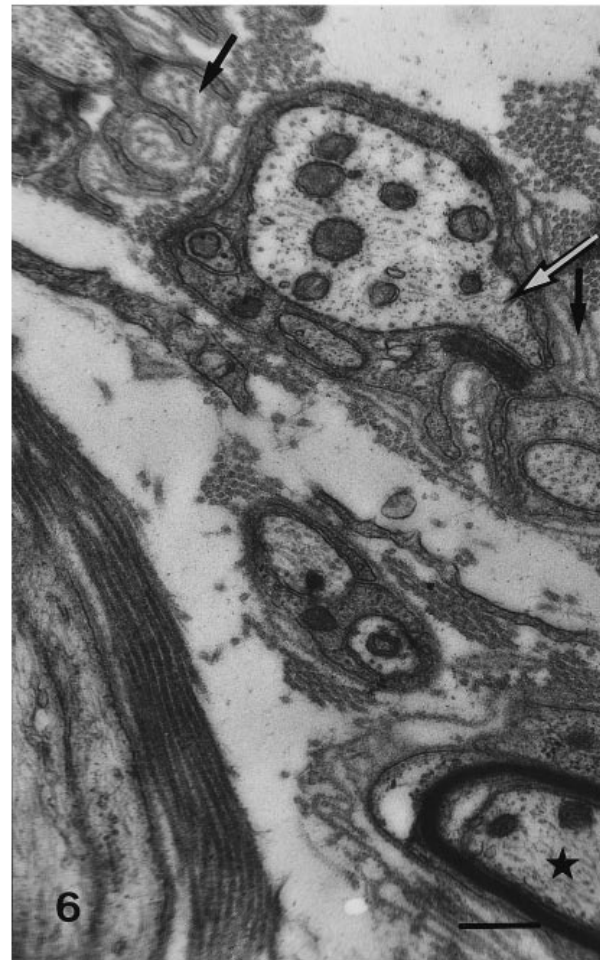


Fig. 6. Detail of the transition between the nerve bundle and a type 2 ending. Asterisk, thinly myelinated group III (A delta) nerve fibre; white arrow, axonal bead with 'finger-like' extension. Note multilayered basal laminae enclosing small diameter collagen fibrils (black arrows). Bar, 350 nm.

capsular cells in the type 2 Ruffini ending. The overall capsule thickness of the type 2 ending ranged from 0.8 to 2.5 μm .

Adjacent cell processes of perineurial cells interlocked and presented specialised intercellular contacts. Tight junctions were prominent. The attenuated cell processes of the inner capsular cells in the type 2 ending also closely apposed to each other, forming cell contacts identified as tight junctions and gap junctions (Fig. 5b).

A peculiar feature of the type 2 ending was the presence of capillaries with a continuous endothelium in the periphery of the subcapsular space (Fig. 4). The capillaries always carried a short extension of the perineurium with them, along their course in the subcapsular space.

Both types of corpuscular endings were supplied by a nerve bundle accompanying blood vessels. At the transition of this bundle and the corpuscle, the

perineurial sheath of the nerve bundle fused with the receptor capsule. Type 1 endings were commonly supplied by a small bundle of unmyelinated group IV (C) nerve fibres. In its preterminal course the bundle divided over several cylindrical type 1 corpuscles.

Type 2 endings are commonly supplied by a nerve bundle measuring on average 40 μm in diameter that comprised a mixed population of thinly myelinated group III (A delta) and unmyelinated group IV (C) nerve fibres (Fig. 6). Group III (A delta) nerve fibres measured on average 1–3 μm , whereas group IV (C) fibres measured on average 0.5–2 μm .

The receptive complex *sensu stricto* was composed of axon terminals and associated Schwann cell coverings, both intimately related to parallel bundles of collagen fibrils measuring ~ 30 –45 nm in diameter. The receptive complex of both types of Ruffini endings showed similar ultrastructural specialisations. Nerve fibres branched frequently within the receptive complex and exhibited focal axonal enlargements (varicosities or beads). Considerable variation in the vesicular content, the proportion of vesicles to mitochondria, and the mean axonal diameter was observed in these varicosities. Generally, the varicosities were only partly enveloped by associated Schwann cell processes (Fig. 7*a, b*). According to Heppelmann et al. (1990), the 'bare' area of axolemma lacking Schwann cell covering, was referred to as the 'receptive site'. The axolemma at the receptive site usually showed a varying degree of undulation. Collagen fibrils often closely approached this receptive site, but direct contact was seldom observed.

Large varicosities (measuring 1–1.5 μm), with 'neurofilament core' (Heppelmann et al. 1990), and a large number of peripheral and parallel mitochondria, were regularly found in the Type 2 ending (Fig. 8*a*). Other varicosities had no neurofilament core, but were filled with randomly oriented mitochondria (Fig. 8*a, b*). They also contained varying numbers of clear vesicles and some dense cored vesicles.

Vesicles were scattered between the mitochondria or clumped within a distinct 'receptor matrix' (Andres & von Düring, 1973; Andres et al. 1985). This matrix (Fig. 8*b*) was characterised by a filamentous substructure and lay under the bare axolemma at the receptive site. The receptor matrix was sometimes present in small axonal extensions known as axonal 'herniations' or 'fingers' (Byers, 1985), pointing to nearby endoneurial collagen fibrils (Fig. 9*a*). The larger varicosities were commonly accompanied by smaller varicosities (mean average diameter 0.2–0.5 μm) containing scarce mitochondria and a larger number of small agranular vesicles 30–60 nm in

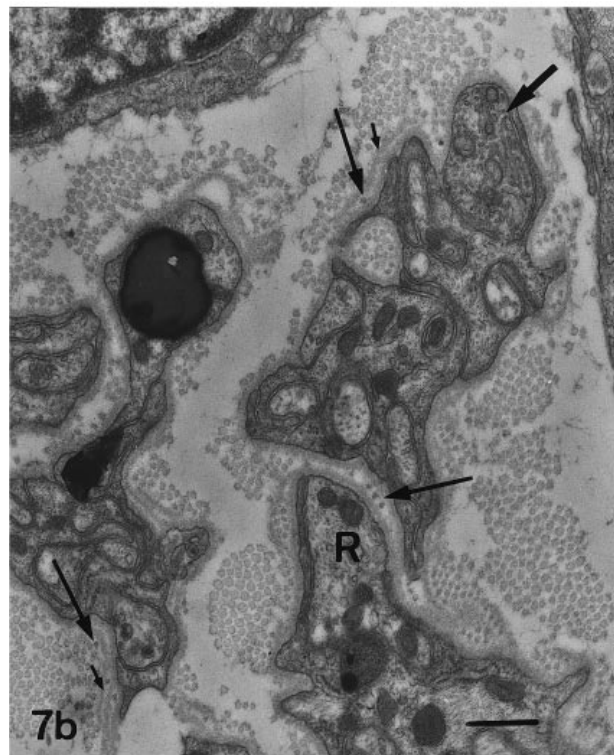
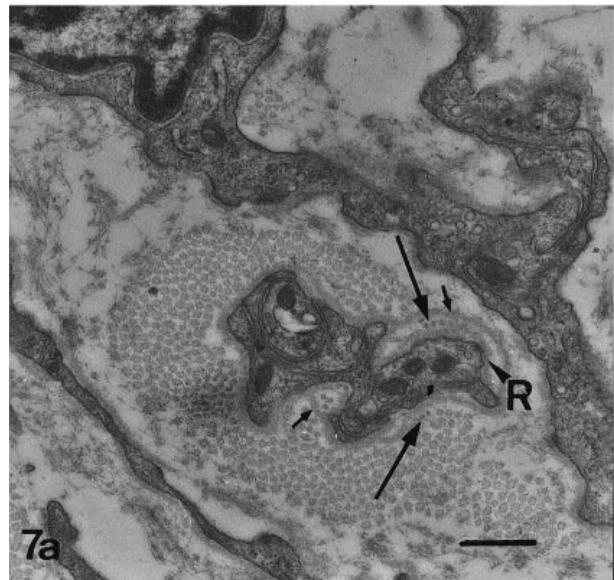


Fig. 7*a, b*. Higher magnification of the outlined areas within the receptive complex of the 1st type of ending shown in Figure 3, demonstrating axon terminals, partly or completely enveloped by Schwann cells. Small diameter collagen fibrils (thin arrows) are intimately related to the receptor site (R), and additional loops of basal lamina are present (small arrows). Note the undulating transducer membrane of high contrast and underlying 'receptor matrix' with filamentous substructure at the receptive site. Thick arrow, vesiculated nerve profile containing numerous round and flattened clear vesicles. Bar, 485 nm.

diameter (Fig. 8*b*). The smaller varicosities were most numerous in type 1 endings (Fig. 7*b*). Some of these smaller varicosities in the receptor complex of our type 2 ending contained a variable number of small

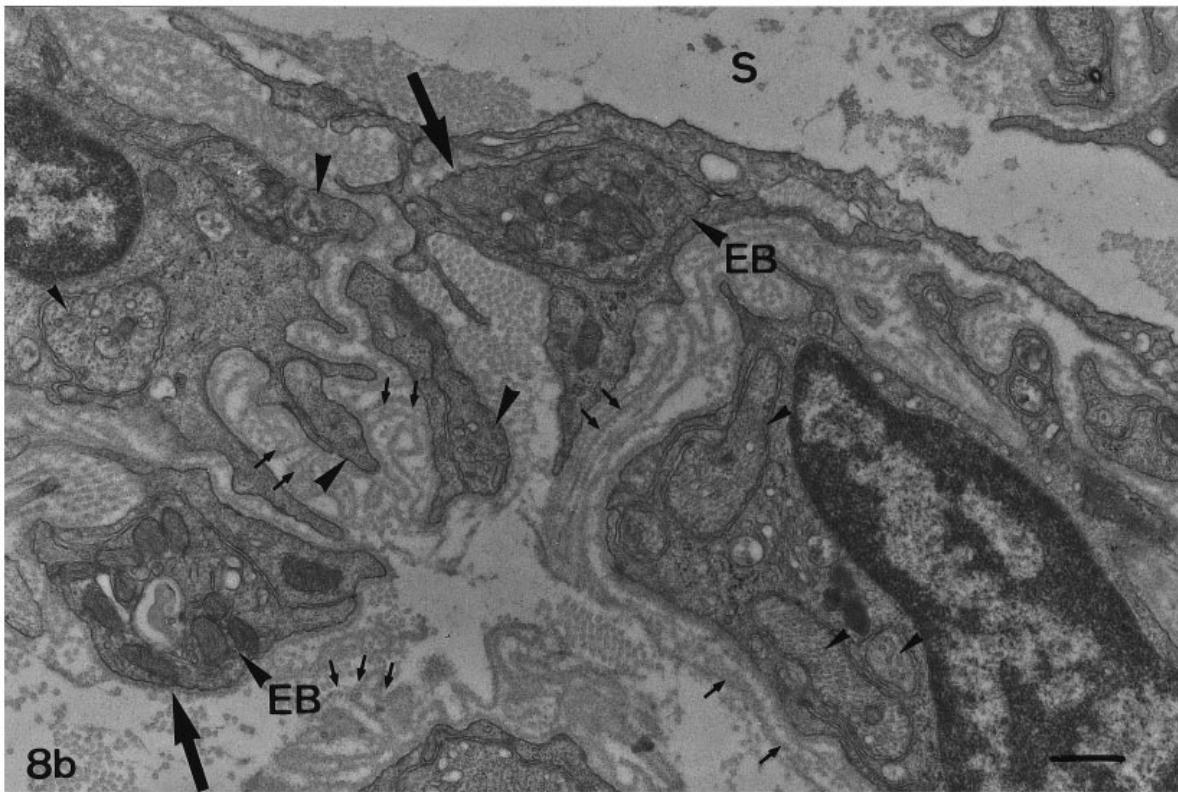
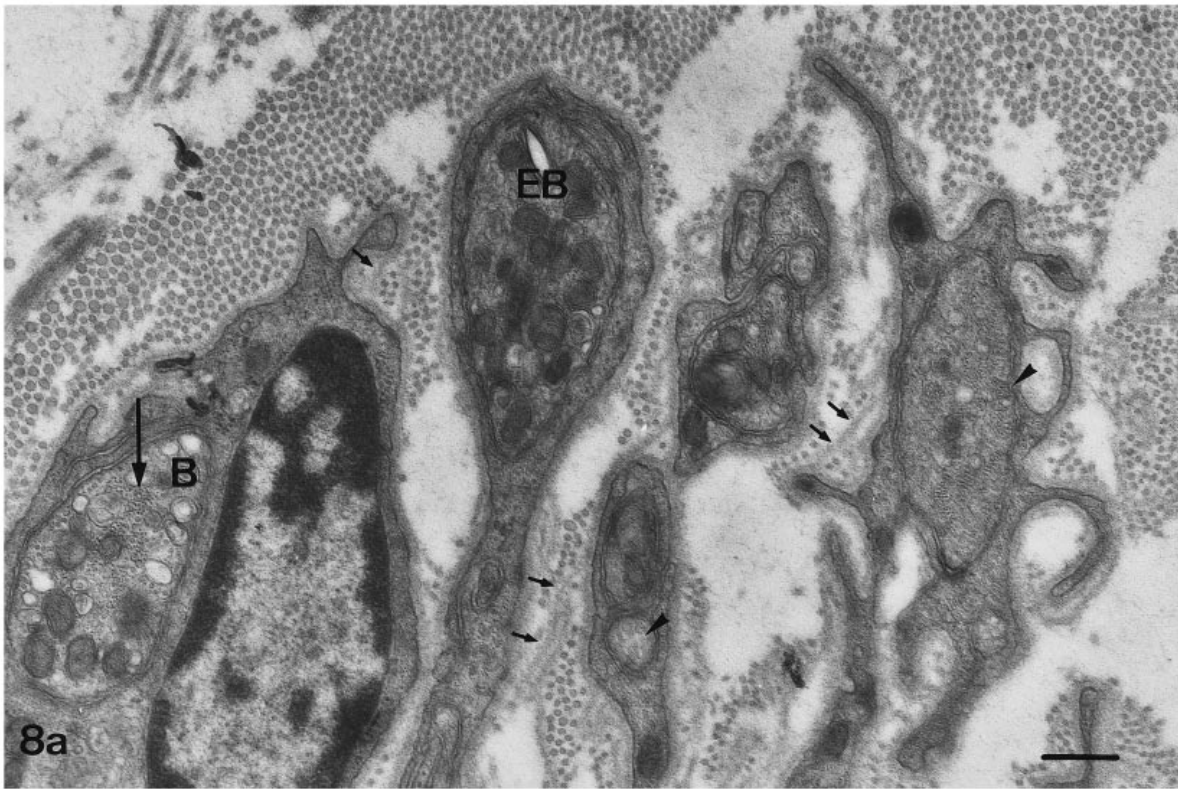


Fig. 8*a, b*. Electron micrographs of group III (A delta) afferent nerve fibres in the receptive complex of the 2nd type of ending showing axonal beads (B) with peripherally distributed mitochondria, a central 'neurofilament core' (thin arrow), few neurotubules and scarce cell organelles. Axonal end bulbs (EB) containing randomly oriented mitochondria and variable numbers of vesicles, but in contrast to beads no neurofilament core and scarce neurotubules. S, subcapsular space; small arrows, multilayered basal laminae; large arrowheads, vesiculated nerve profiles without mitochondria; small arrowheads; thin axonal segments with neurotubules and neurofilaments. Note the undulating transducer membranes of high contrast (large arrows) with underlying 'receptor matrix' and accumulated vesicles in (*b*). *a*, bar, 350 nm; *b*, bar, 455 nm.

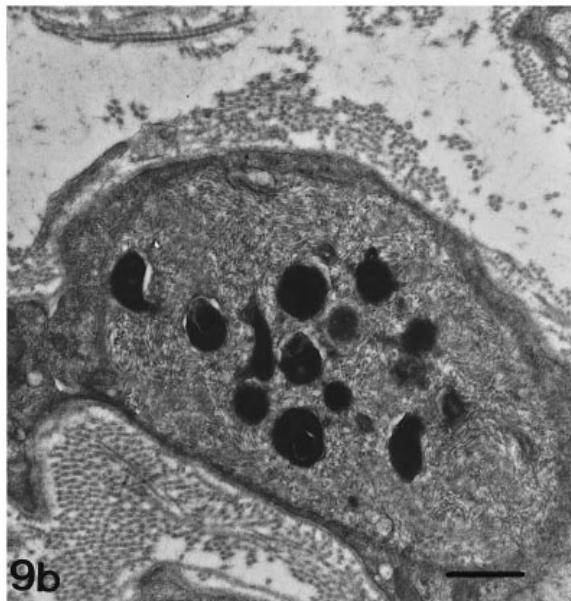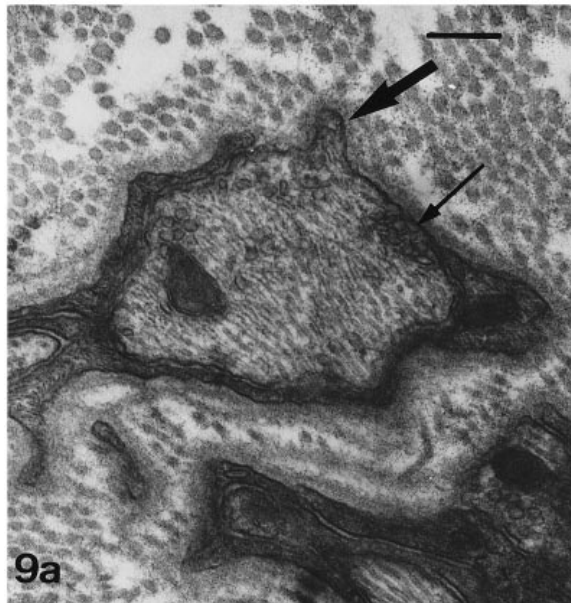


Fig. 9. Electron micrographs of axonal profiles in the receptive complex of the 2nd type of ending. (a) Fingerlike axonal herniation (thick arrow) in intimate relationship with the surrounding endoneurial connective tissue. Note the high contrast of the adjacent transducer membrane, and the underlying electron-dense axoplasm with accumulated small agranular vesicles (thin arrow). Bar, 225 nm. (b) Axonal profile with filamentous substructure containing multiple homogeneous densely osmiophilic bodies, recognised as end products of mitochondrial degeneration. Bar, 400 nm.

granular vesicles, 30–60 nm in diameter (Fig. 10). These varicosities were completely or only partly ensheathed by Schwann cells.

A striking structural specialisation of the corpuscles presently described was the presence of multilayered basal laminae around the axon terminals and associated Schwann cells (Figs 7a, b, 8a, b). Par-

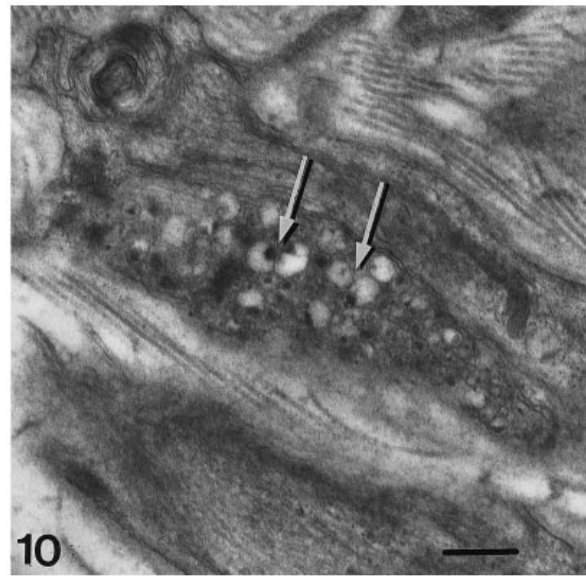


Fig. 10. Electron micrograph of a vesiculated nerve profile in the receptive complex of the 2nd type of ending, containing predominantly granular vesicles. Large granular vesicles with eccentric core and elaborate electron-lucent halo (arrows). Bar, 380 nm.

ticularly, the type 2 ending appeared focally well endowed with multilayered basal lamina (Fig. 4).

Both types of ending contained small diameter collagen fibrils (diameter on average 20 nm). These collagen fibrils were single or grouped and were commonly oriented tangential to the nerve terminals (Fig. 11). When sectioned transversely they were seen as electron-dense ‘dots’ around nerve terminals and associated Schwann cells. Comparable electron-dense dots were found along longitudinally sectioned nerve terminals and recognised as transversely sectioned small diameter collagen fibrils (Fig. 11). The small diameter collagen fibrils were always enclosed by one or several loops of multilayered basal laminae, and intimately related to the transducer membrane at the receptive sites (Figs 7a, b, 8a, b). They were regularly anchored in the basal laminae.

Schwann cells in both types of endings commonly exhibited long cytoplasmic extensions projecting far into the surrounding endoneurial connective tissue, embracing collagen bundles. In some instances axon terminals in the Ruffini-like endings described here contained very electron-dense bodies, vacuoles, lamellar formations and multivesicular bodies (Fig. 9b).

DISCUSSION

The morphofunctional classification of articular receptors as type I to IV, established by Freeman & Wyke (1967), has been widely used in the field of articular neurology, and includes Ruffini endings (type I), pacinian corpuscles (type II), Golgi endings

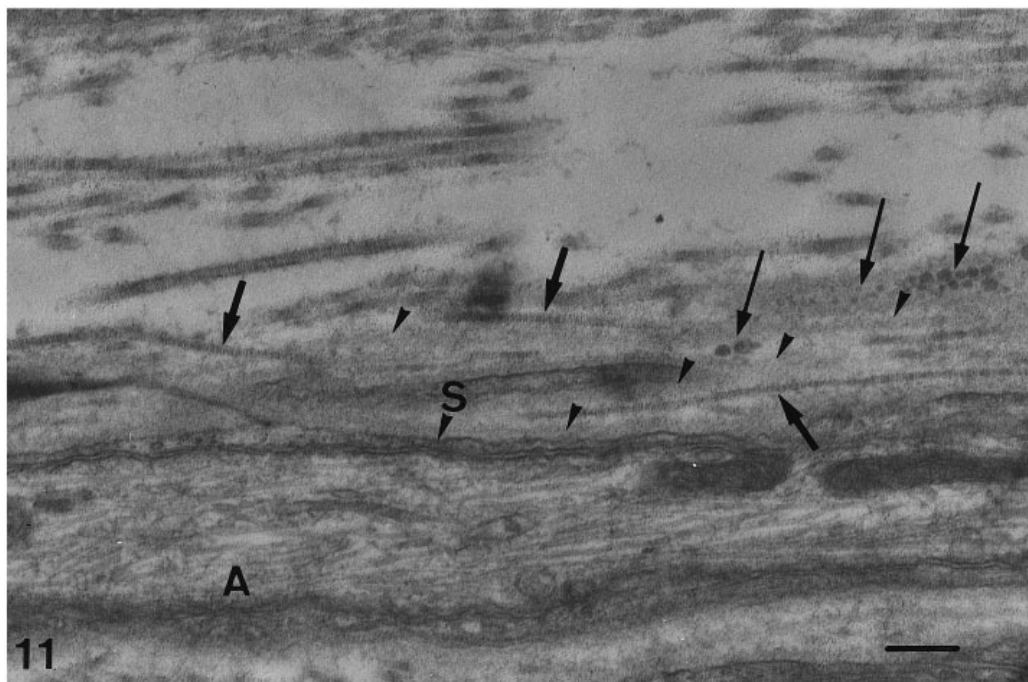


Fig. 11. Electron micrograph illustrating the intimate relationship between small diameter collagen fibrils and the axon terminal (A) with associated Schwann cell (S). Longitudinally sectioned axon terminal. Parallel small diameter collagen fibrils (thick arrows) enclosed within additional loops of basal lamina (arrowheads). Note multiple electron-dense spots (thin arrows) within successive layers of basal laminae recognized as transversely sectioned small diameter collagen fibrils. Bar, 245 nm.

(type II) and free nerve endings (type IV). Types I to III are corpuscular endings with mechanoreceptive properties, while noncorpuscular endings (type IV) mainly serve as nociceptors. Unfortunately the literature on the subject of nerve endings is confusing. It is often difficult to be certain with precision that different investigators are referring to the same ending. This may be due to a misinterpretation of nerve endings by the investigator, to a physiological variety of nerve endings in one individual, or to interspecies variation. Specific ultrastructural features of articular receptors may be important in order to speculate about their possibly physiological function and specific functional importance for a particular joint.

The observation of small numbers of mechanoreceptive endings in the facet joint capsule of the human lumbar spine agrees with the observations of McLain (1994) on cervical facets and suggests that each mechanoreceptor has a relatively large receptive field, which emphasises the clinical and neurosurgical importance of the facet joint. Structurally both types of corpuscular endings found in the facet joint capsule of the human lumbar spine are comparable to the 2 types of Ruffini corpuscles described by Halata et al. (1984) in the knee joint capsule of monkey.

Ruffini corpuscles with an extensive subcapsular space, comparable to our type 2 endings, have also been found in the hairy skin of cats (Chambers et al.

1972) and in the knee joint capsule of the dog (Schenk et al. 1996). The presence of a 'central core' (the receptive complex), situated within an extensive subcapsular space, has been implicated as an important criterion for the differentiation between large encapsulated Ruffini corpuscles and the well-defined Golgi tendon organ (Sklenska, 1972; Andres & von Düring, 1973; Andres, 1974). Golgi tendon organs and Ruffini endings are generally described as stretch receptors registering altered tension in the surrounding collagen, as collagen bundles pass through these corpuscles (Schoultz & Swett, 1972, 1974; Nitatori, 1988; Zimny, 1988; Backenköhler et al. 1996; Schenk et al. 1996).

Halata & Munger (1986) reported finding a specific corpuscle with a varying degree of encapsulation involved in the protopathic sensibility of the human glans penis. These corpuscles (referred to as 'genital end bulbs') were characterised by a central meshwork of densely arborising nerve terminals ultrastructurally identical in appearance to noncorpuscular nerve endings. In this respect the ultrastructural resemblance with our type 2 Ruffini-like endings is remarkable. Indeed, the afferent terminals in our Ruffini-type endings share comparable structural specialisations with noncorpuscular endings of fine afferent nerve terminals (Andres et al. 1985; Heppelmann et al. 1990; von Düring & Andres, 1990).

In agreement with recent electrophysiological studies demonstrating group III and group IV mechanosensitive units in the lumbar facet joint (see Introduction), we did find our corpuscular endings supplied by thinly myelinated nerve group III (A delta) and unmyelinated group IV (C) nerve fibres. Apparently the nerve supply of our Ruffini-like endings differs from the well-known corpuscular endings in tendons or other articular capsules. Indeed, as generally accepted corpuscular endings are generally supplied by a myelinated medium-sized axon measuring 2–4 μm in diameter classified as a group II fibre, dividing into several unmyelinated nerve fibres after entering the corpuscle (Halata, 1977; Halata & Munger, 1980, 1981; Halata et al. 1984, 1985; Strasmann et al. 1987; Zimny, 1988; Halata & Haus, 1989; Haus & Halata, 1990; Heppelmann et al. 1990; Backenköhler et al. 1996).

According to Heppelmann et al. (1990), the largest axonal profiles are afferent terminals from thinly myelinated group III (A delta) nerve fibres. The presence of a 'neurofilament core' within the terminal part of the group III afferent axon is known to be a conclusive criterion in the distinction between beads along the course and the end bulb or the last axonal bead at the tip of the sensory ending.

The smaller axonal profiles, lacking a neurofilament core and containing a variable number of vesicles, probably represent axonal beads and/or end bulbs of nerve terminals from unmyelinated group IV (C) afferent nerve fibres or autonomic efferent terminals. However, a conclusive morphofunctional classification of vesiculated nerve profiles using conventional EM is impossible. Vesiculated nerve profiles characterised by numerous granular vesicles, 30 to 60 nm in diameter, are accepted to be adrenergic in function and probably derived from vasomotor nerve fibres.

It is generally believed that the 'bare' areas of axolemma intimately related to the surrounding endoneurial connective tissue, are involved in mechanoelectric transduction. Stretching of the fibrous capsule is assumed to cause a physical distortion of the transducer membranes at the receptive sites (Schultz & Swett, 1972). To our knowledge, direct contacts with collagen fibrils have never been demonstrated. In addition, the literature concerning the significance of the finger-like axonal projections in mechanoreception is contradictory (Byers, 1985; Maeda et al. 1989; Sato et al. 1992). However, the presence of the small diameter collagen fibrils in intimate relation to multilayered basal laminae at the receptive sites, as described here, is suggestive. Comparable multilayered basal laminae

have been observed in periodontal Ruffini endings (Byers, 1985; Byers & Dong, 1989; Maeda et al., 1989, 1991; Kannari, 1990; Kannari et al. 1991). Multiple layering of basal laminae has been assumed to represent a morphological sign of axonal regeneration (Ide, 1983; Sandoz & Zenker, 1986; Sasamura, 1986). To our knowledge a possible functional significance for the multilayered basal laminae remains to be elucidated.

Kannari et al. (1991) also observed periaxonal small diameter collagen fibrils intimately related to multilayered basal laminae. They assumed that the multilayered basal lamina thereby acts as an 'adhesive device' or linkage between the afferent terminal and the small diameter collagen fibrils. Indeed, such structural specialisations at the receptive sites probably facilitate the perception of the mechanical stimulus. Stimulation of the receptive complex would narrow the extracellular spaces between successive layers of basal laminae, causing a deformation and displacement of small diameter collagen fibrils and a physical distortion of the transducer membrane. Small diameter collagen fibrils are thought to be highly elastic, recoil after deformation, and are resistant to stretch (Harkness, 1968; Schultz & Swett, 1972).

It may be noted that Pickar & McLain (1995) demonstrated electrophysiologically a directional sensitivity to spinal loading of slowly adapting Ruffini-type mechanosensitive afferents in the lumbar facet joint. In this context, the apparent variable orientation of periaxonal small diameter collagen fibrils in our encapsulated Ruffini-like endings on studying serial sections may be of interest and needs further investigation. It is tempting to suggest that the required mechanical stimulus of our type 2 endings is transferred to their receptive complex throughout the extensive fluid-filled spaces between successive inner capsular cells, thereby acting as a 'pressoreceptor'. It might be of interest to mention in this context the close resemblance between some of their afferent terminals and worn out pressoreceptor endings within the carotid sinus (Knoche et al. 1974; Abdel-Magied et al. 1982; Shin et al. 1987).

Tight junctions are known to provide specific permeability barrier characteristics. The intercellular features of the perineurial cells and inner capsular cells create a blood-nerve barrier that provides a constant microenvironment for the axon terminals within the receptive complex. The perineurial sleeve accompanying the capillaries in the periphery of the subcapsular space probably helps to maintain the integrity of the perineurial barrier. Our observations on the intercellular junctions between capsular cells in

the Ruffini corpuscles are in agreement with the results of Ovalle & Dow (1983). The gap junctions are involved in intercellular communication and cyto-functional synchronisation of inner capsular cells (Ovalle & Dow, 1983).

ACKNOWLEDGEMENTS

The authors gratefully acknowledge the help of Dr P. Donkersloot, Department of Neurosurgery, Virga Jesse Ziekenhuis, Hasselt (Belgium) in obtaining the capsular tissue.

REFERENCES

- ABDEL-MAGIED EM, TAHA AAM, KING AS (1982) An ultrastructural investigation of a baroreceptor zone in the common carotid artery of the domestic fowl. *Journal of Anatomy* **135**, 463–475.
- AHMED M, BJURHOLM AN, KREICBERGS A, SCHULTZBERG M (1993) Sensory and autonomic innervation of the facet joint in the rat lumbar spine. *Spine* **18**, 2121–2126.
- ANDRES KH (1974) Morphological criteria for the differentiation of mechanoreceptors in vertebrates. In *Symposium on Mechanoreception* (ed. Schwartzkopff J.), pp. 135–152. Opladen: Westdeutscher.
- ANDRES KH, VON DÜRING M (1973) Morphology of cutaneous receptors. In *Handbook of Sensory Physiology*, vol. II (ed. Iggo A), pp. 3–28. Berlin: Springer.
- ANDRES KH, VON DÜRING M, SCHMIDT RF (1985) Sensory innervation of the Achilles tendon by group III and IV afferent fibers. *Anatomy and Embryology* **172**, 145–156.
- ASHTON IK, ASHTON BA, GIBSON SJ, POLAK JM, JAFFRAY DC, EISENSTEIN SM (1992) Morphological basis for back pain: the demonstration of nerve fibers and neuropeptides in the lumbar facet joint capsule but not in ligamentum flavum. *Journal of Orthopaedic Research* **10**, 72–78.
- AVRAMOV AI, CAVANAUGH JM, OZAKTAY CA, GETCHELL TV, KING AI (1992) The effects of controlled mechanical loading on group II, III, and IV afferent units from the lumbar facet joint and surrounding tissue. *Journal of Bone and Joint Surgery* **74A**, 1464–1471.
- BACKENKÖHLER U, HALATA Z, STRASMANN TJ (1996) The sensory innervation of the shoulder joint of the mouse. *Annals of Anatomy* **178**, 173–181.
- BEAMEN DN, GRAZIANO GP, GLOVER RA, WOJTYŚ EM, CHANG V (1993) Substance P innervation of lumbar spine facet joints. *Spine* **18**, 1044–1049.
- BYERS MR (1985) Sensory innervation of periodontal ligament of rat molars consists of unencapsulated Ruffini-like mechanoreceptors and free nerve endings. *Journal of Comparative Neurology* **231**, 500–518.
- BYERS MR, DONG WK (1989) Comparison of trigeminal receptor location and structure in the periodontal ligament of different types of teeth from the rat, cat, and monkey. *Journal of Comparative Neurology* **279**, 117–127.
- CAVANAUGH JM, EL-BOHY A, HARDY WN, GETCHELL TV, GETCHELL ML, KING AI (1989) Sensory innervation of soft tissues of the lumbar spine in the rat. *Journal of Orthopaedic Research* **7**, 378–388.
- CHAMBERS MR (1969) *The properties of a slowly-adapting mechanoreceptor in the skin of the cat*. M.Sc. Thesis, University of Edinburgh.
- CHAMBERS MR, ANDRES KH, VON DÜRING M, IGGO A (1972) The structure and functions of the slowly adapting type II mechanoreceptor in hairy skin. *Quarterly Journal of Experimental Physiology* **57**, 417–445.
- EL-BOHY AA, CAVANAUGH JM, GETCHELL ML, BULAS T, GETCHELL TV, KING AI (1988) Localization of substance P and neurofilament immunoreactive fibers in the lumbar facet joint capsule and supraspinous ligament of the rabbit. *Brain Research* **460**, 379–382.
- FREEMAN MAR, WYKE B (1967) The innervation of the knee joint. An anatomical and histological study in the cat. *Journal of Anatomy* **101**, 505–532.
- GILETTE RG, KRAMIS RC, ROBERTS WJ (1993) Spinal projections of cat primary afferent fibers innervating lumbar facet joints and multifidus muscle. *Neuroscience Letters* **157**, 67–71.
- GILES LGF, HARVEY AR (1987) Immunohistochemical demonstration of nociceptors in the capsule and synovial folds of human zygapophyseal joints. *British Journal of Rheumatology* **26**, 362–364.
- GRÖNBLAD M, KORKALA O, KONTINEN YT, NEDERSTRÖM A, HUKKANEN M, TOLVANEN E et al. (1991) Silver impregnation and immunohistochemical study of nerves in lumbar facet joint plical tissue. *Spine* **16**, 34–43.
- HALATA Z (1977) The ultrastructure of the sensory nerve endings in the articular capsule of the knee joint of the domestic cat (Ruffini corpuscles and Pacinian corpuscles). *Journal of Anatomy* **124**, 717–729.
- HALATA Z, MUNGER BL (1980) The ultrastructure of Ruffini and Herbst corpuscles in the articular capsule of domestic pigeon. *Anatomical Record* **198**, 681–692.
- HALATA Z, MUNGER BL (1981) Identification of the Ruffini corpuscle in human hairy skin. *Cell and Tissue Research* **219**, 437–440.
- HALATA Z, BADALAMENTE MA, DEE R, PROPPER M (1984) Ultrastructure of sensory nerve endings in monkey (*Macaca fascicularis*) knee joint capsule. *Journal of Orthopaedic Research* **2**, 169–176.
- HALATA Z, RETTIG T, SCHULZE W (1985) The ultrastructure of sensory nerve endings in the human knee joint capsule. *Anatomy and Embryology* **172**, 265–275.
- HALATA Z, MUNGER BL (1986) The neuroanatomical basis for the protopathic sensibility of the human glans penis. *Brain Research* **371**, 205–230.
- HALATA Z, HAUS J (1989) The ultrastructure of sensory nerve endings in human anterior cruciate ligament. *Anatomy and Embryology* **179**, 415–421.
- HARKNESS RD (1968) Mechanical properties of collagenous tissues. In *Treatise on Collagen*, vol. 2 (ed. Gould BS), pp. 248–310. New York: Academic Press.
- HAUS J, HALATA Z (1990) Innervation of the anterior cruciate ligament. *International Orthopaedics* **14**, 293–296.
- HEPPELMANN B, MESSLINGER K, NEISS WF, SCHMIDT RF (1990) Ultrastructural three-dimensional reconstruction of group II and group IV sensory nerve endings ('free nerve endings') in the knee joint capsule of the cat: evidence for multiple receptive sites. *Journal of Comparative Neurology* **292**, 103–116.
- IDE C (1983) Nerve regeneration and Schwann cell basal lamina: observations of the long-term regeneration. *Archivum Histicologicum Japonicum* **46**, 243–257.
- JOHANSSON H, SJÖLANDER P, SOJKA P (1991) Receptors in the knee joint ligaments and their role in the biomechanics of the joint. *Biomedical Engineering* **18**, 341–368.
- KANNARI K (1990) Sensory receptors in the periodontal ligament of hamster incisors with special reference to the distribution, ultrastructure and three-dimensional reconstruction of Ruffini endings. *Archives of Histology and Cytology* **53**, 559–573.
- KANNARI K, SATO O, MAEDA T, IWANAGA T, FUJITA T (1991) A possible mechanism of mechanoreception in Ruffini endings in the periodontal ligament of hamster incisors. *Journal of Comparative Neurology* **313**, 368–376.

- KNOCHE H, ADDICKS K, SCHMITT G (1974) A contribution regarding our knowledge of pressoreceptor fields and the sinus nerve based on electron microscopic findings. In *Symposium on Mechanoreception* (ed. Schwartzkopf J), pp. 57–76. Opladen: Westdeutscher.
- MAEDA T, SATO O, KOBAYASHI S, IWANAGA T (1989) The ultrastructure of Ruffini endings in the periodontal ligament of rat incisors with special reference to the terminal Schwann cells (K-cells). *Anatomical Record* **223**, 95–103.
- MAEDA T, SATO O, KANNARI K, TAKAGI H, IWANAGA T (1991) Immunohistochemical localization of laminin in the periodontal Ruffini endings of rat incisors: a possible function of terminal Schwann cells. *Archives of Histology and Cytology* **54**, 339–348.
- MCLAIN RF (1994) Mechanoreceptor endings in human cervical facet joints. *Spine* **19**, 495–501.
- MEHTA M, PARRY CBW (1994) Mechanical back pain and the facet joint syndrome. *Disability and Rehabilitation* **16**, 2–12.
- NITATORI T (1988) The fine structure of human Golgi tendon organs as studied by three-dimensional reconstruction. *Journal of Neurocytology* **17**, 27–41.
- OVALLE WK, DOW PR (1983) Comparative ultrastructure of the inner capsule of the muscle spindle and the tendon organ. *American Journal of Anatomy* **166**, 343–357.
- ÖZAKTAY AC, YAMASHITA T, CAVANAUGH JM, KING AI (1991) Fine nerve fibers and endings in the fibrous capsule of the lumbar facet joint. *Transactions of the Orthopaedic Research Society* **16**, 353.
- PICKAR JG, MCLAIN RF (1995) Responses of mechanosensitive afferents to manipulation of the lumbar facet in the cat. *Spine* **20**, 2379–2385.
- SANDOZ PA, ZENKER W (1986) Unmyelinated axons in a muscle nerve. Electron microscopic morphometry of the sternomastoid nerve in normal and sympathectomized rats. *Anatomy and Embryology* **174**, 207–213.
- SASAMURA T (1986) Degeneration and regeneration of Ruffini corpuscles in the joint capsule. *Journal of the Japanese Orthopaedic Association* **60**, 1157–1166.
- SATO A, SWENSON RS (1984) Sympathetic nervous system response to mechanical stress of the spinal column in rats. *Journal of Manipulative and Physiological Therapeutics* **7**, 141–147.
- SCHENK I, SPAETHE A, HALATA Z (1996) The structure of sensory nerve endings in the knee joint capsule of the dog. *Annals of Anatomy* **178**, 515–521.
- SCHOULTZ TW, SWETT JE (1972) The fine structure of the Golgi tendon organ. *Journal of Neurocytology* **1**, 1–26.
- SCHOULTZ TW, SWETT JE (1974) Ultrastructural organization of the sensory fibres innervating the Golgi tendon organ. *Anatomical Record* **179**, 147–162.
- SHIN HS, HULBERT WC, BIGGS DF (1987) Observations on the fine structure of the baroreceptors and adrenergic innervation of the guinea-pig carotid sinus. *Journal of Morphology* **194**, 65–74.
- SKLENSKA A (1972) Contribution to the ultrastructure of the Golgi tendon organ. *Folia Morphologica* **200**, 195–198.
- STRASMANN T, HALATA Z, KIN LOO S (1987) Topography and ultrastructure of sensory nerve endings in the joint capsules of the Kowari (*Dasyuroides byrnei*), an Australian marsupial. *Anatomy and Embryology* **176**, 1–12.
- VANDENABEELE F, CREEMERS J, LAMBRICHTS I, ROBBERECHTS W (1995) Fine structure of vesiculated nerve profiles in the human lumbar facet joint. *Journal of Anatomy* **187**, 681–692.
- VON DÜRING M, ANDRES KH (1990) Topography and ultrastructure of group II and IV nerve terminals of the cat's gastrocnemius–soleus muscle. In *The Primary Afferent Neuron* (ed. Zenker W, Neuhuber WL), pp. 35–41. New York: Plenum Press.
- YAMASHITA T, CAVANAUGH JM, EL-BOHY AA, GETCHELL TV, KING AI (1990) Mechanosensitive afferent units in the lumbar facet joint. *Journal of Bone and Joint Surgery* **72A**, 865–870.
- YAMASHITA T, MINAKI Y, ÖZAKTAY C, CAVANAUGH JM, KING AI (1996) A morphological study of the fibrous capsule of the human lumbar facet joint. *Spine* **21**, 538–543.
- ZIMNY ML (1988) Mechanoreceptors in articular tissue. *American Journal of Anatomy* **182**, 16–32.