

The comparative anatomy of the pig middle ear cavity: a model for middle ear inflammation in the human?

J. P. PRACY¹, A. WHITE², Y. MUSTAFA¹, D. SMITH² AND M. E. PERRY¹

¹ Division of Anatomy and Cell Biology, United Medical and Dental Schools, Guy's Hospital, London, and ² Department of Immunology, Babraham Institute, Babraham, Cambridge, UK

(Accepted 20 January 1998)

ABSTRACT

This study was undertaken to develop a functional model of otitis media with effusion (OME) in the pig (*Sus scrofa*), with the purpose of investigating the origin of lymphocytes populating the middle ear during the course of an inflammatory process. The relevance of the model to the human condition of OME is to a large extent dependent on the anatomical and physiological similarities between the middle ear cavity and the pharyngeal lymphoid tissue of the pig and man. Anatomical specimens were collected from 7 young Large White pigs to determine the gross anatomy of the middle ear cavity and the histological characteristics of the middle ear mucosa. It was found that the anatomy of the 3 parts of the middle ear cavity in man and in the pig is broadly similar, although some minor differences were observed. The porcine eustachian tube was seen to be cartilaginous throughout its length in contrast to the part osseous, part cartilaginous structure found in man; the porcine ossicles were slightly different in shape to those of man and the air cell system was situated inferior to the tympanic cavity in the pig as opposed to posteriorly in man. This paper describes the structure and morphology of the pig middle ear cavity and compares and contrasts it with that of man. The minor differences observed are of anatomical importance but do not diminish the usefulness of the pig middle ear cleft as a potential model for human middle ear disorders.

Key words: Otitis media.

INTRODUCTION

The pig offers a number of advantages as a model for human pathological processes in that it is omnivorous and many elements of both its anatomy and physiology are similar to those of the human. A large number of monoclonal antibodies have been developed against a variety of pig antigens in recent years, and there is increasing interest in the development of the pig as a xenotransplantation donor for man. These factors taken together mean that the pig is potentially a good model in which to study the immunological processes involved in middle ear inflammation. More specifically, for the purposes of our future studies on lymphocyte homing it is of particular importance that the pig has a full complement of the pharyngeal lymphoid aggregates which constitute Waldeyer's ring in the human. Studies of lymphocyte homing into inflamed middle ear mucosa have been carried out in a number of laboratory

rodents, but have produced equivocal results at least in part due to the absence of true tonsillar structures in these animals (Ryan et al. 1988, 1990; Watanabe et al. 1992). Middle ear inflammation has been described in pigs but appears to be infrequent (Whitehair, 1964). It may be that the inflammation fails to result in a clinically significant event and so goes unnoticed or that the relatively long and tortuous external ear canal affords protection against perforation of the tympanic membrane and subsequent infection. As a clinically significant condition otitis media is most commonly seen in feeder pigs. The signs are initially head tilt which may be followed by circling or, in severe cases, ataxia (Wilcock, 1993). The lining of the tympanic cavity becomes hyperaemic, oedematous and has occasionally been reported as ulcerated (Wilcock, 1993).

The middle ear cavity in man consists of 3 main components: the eustachian tube, first described in 1562 by Bartholomaeus Eustachius; the tympanic

cavity; and the mastoid air cell system. The aim of this study was to assess the structure and morphology of the pig middle ear cavity using the methods of comparative anatomy, histology, and computerised tomographic (CT) scanning in order to validate the use of this animal as a model for otitis media with effusion (OME).

MATERIALS AND METHODS

Seven young (MHC homozygous SLAb/b, genetically inbred) Large White pigs (*Sus scrofa*), aged between 10 and 12 wk provided the material for this investigation. The pigs were anaesthetised using fluothane inhalational anaesthesia and killed by bleed out from the axillary artery. The heads were removed by cutting down to the vertebral column at the level of the 2nd cervical vertebra and separating the head and body by cutting through the intervertebral disc between the 1st and 2nd cervical vertebrae. The skin and subcutaneous tissue were removed to facilitate further dissection and the mandible was removed by sawing through the mandibular rami in order to gain improved access to the soft palate and postnasal space.

Soft tissue was removed from the surface of the temporal bone and the tympanic cavity was approached from the posterior aspect. Using a Wild Heerbrugg MS-C operating microscope and a nitrogen-driven dissecting drill with both cutting and polishing burrs, the temporal bone was drilled in order to provide access to the tympanic cavity. Photographs of this procedure were taken using an Olympus OM2 camera attached to the microscope using the Wild 350 mm SLR adapter. The middle ear ossicles were removed for further examination and the middle ear mucosa was stripped from the surface of the bone immediately inferior to the promontory. These fresh strips of mucosa tended to curl up on themselves during removal. To prevent curling during fixation, the strips of tissue were laid out on the adhesive surface of a gum adhesive label before being immersed in fixative.

The eustachian tube was cannulated using a blunt malleable probe and dissected from the nasopharyngeal end towards the tympanic cavity. In 2 cases the eustachian tubes were dissected bilaterally together with the adenoids. In one case the eustachian tube was dissected out uninterrupted along its full length. The temporal bone was then removed from the surrounding soft tissue by dissection and from the surrounding bone by separation along suture lines. In 3 cases the medial wall of the tympanic cavity was

removed for further photography, as was the air cell system of the tympanic bulla. Microphotography of the ossicles and the medial wall of the tympanic cavity was carried out in incident light using a specially modified system incorporating a Wild MPS 45 Photoautomat and Wild MPS 51S camera with a Wild M3Z stereomicroscope.

Tissue samples of middle ear mucosa, adenoid and eustachian tube were fixed in 7.5% formol saline solution for 24 h before being processed for histological examination. The tissues were dehydrated in graded alcohols and blocked in paraplast. Using a Leitz microtome 4–6 µm tissue sections were cut and subsequently stained with haematoxylin and eosin by applying modified techniques as described in Bancroft & Cook (1984). Photomicrographs were taken using a Leitz Orthoplan photomicrography system.

RESULTS

The gross anatomy of the middle ear cavity of the Large White pig (*Sus scrofa*) was very similar to that of the human (Fig. 1). The cavity was a paired structure in the form of a diverticulum with an opening in the nasopharyngeal mucosa just behind the posterior choana, which was identified as the pharyngeal orifice of the eustachian tube. From this point the tube ran posterosuperiorly to connect with the tympanic cavity, which in turn was connected to a system of air cells within the plexiform bone of the tympanic bulla. However, there were a number of minor differences in comparison to man which are of importance anatomically but do not diminish the usefulness of the pig middle ear cleft as a potential model for human middle ear disorders. The anatomical observations of the 3 topographic regions, which together constitute the middle ear cavity, were distinct from each other, but uniform in all the animals examined.

The eustachian tube

The tube was approximately 3 cm long and in contrast to the human was cartilaginous throughout its length although the upper third ran in a bony groove on the surface of the mastoid portion of the temporal bone. This groove was 'roofed in' by the skull base so that the cartilaginous tube was located in a bony channel. From its pharyngeal opening 1 cm behind the posterior choana, it passed posteriorly, superiorly and laterally to enter the tympanic cavity. The tube was oriented throughout its course at an angle of between

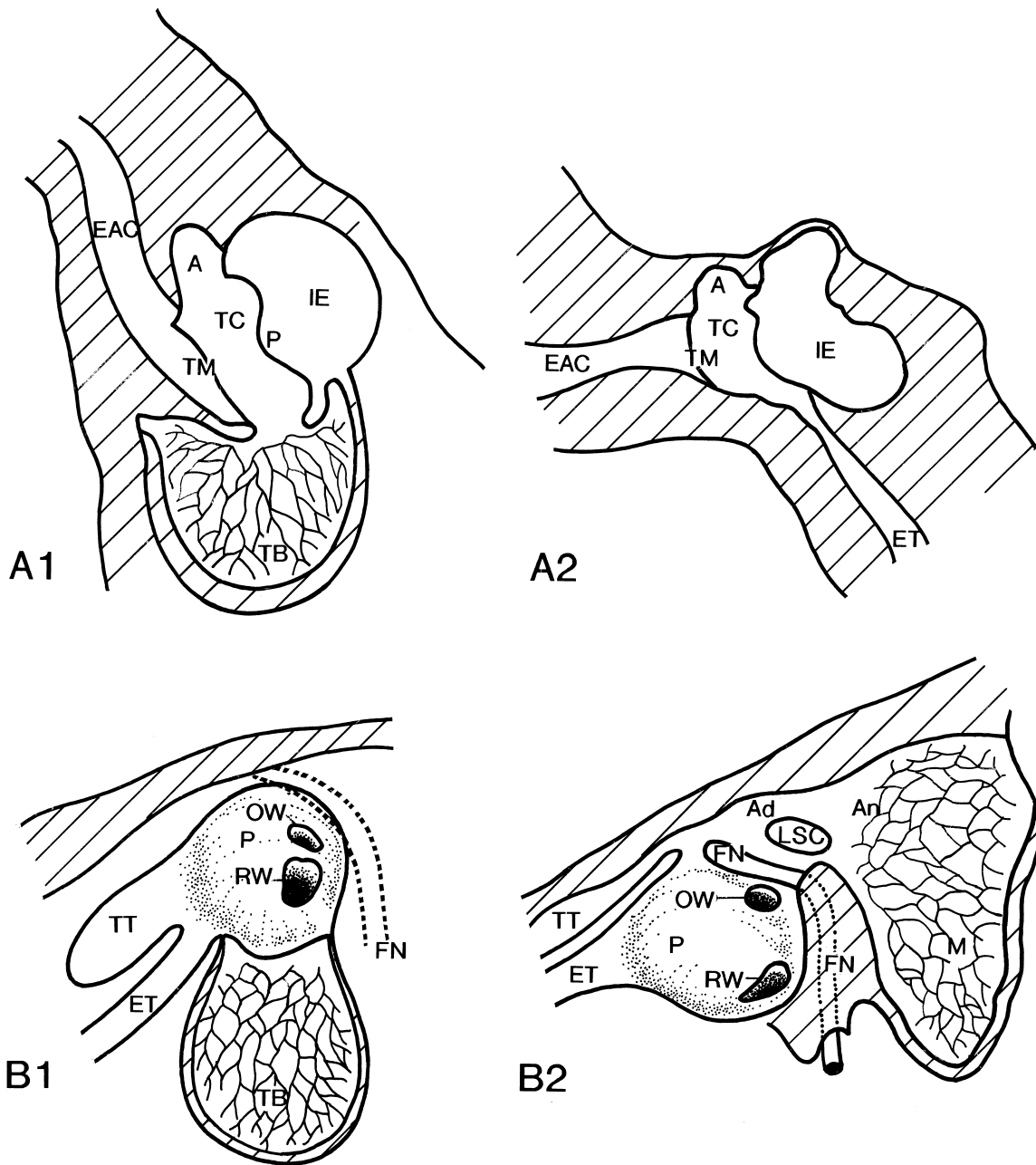


Fig. 1. Schematic representation of the middle ear cavity sectioned coronally (pig A1; human A2) and parasagittally (pig B1; human B2). EAC, external auditory canal; TC, tympanic cavity; TM, tympanic membrane; A, attic; ET, eustachian tube; IE, inner ear, P, promontory; TB, tympanic bulla; M, mastoid air cell system; TT, origin of tensor tympani; OW, oval window; RW, round window; FN, facial nerve; Ad, aditus; An, antrum.

25° and 30° to the horizontal plane and approximately 45° to the sagittal plane.

As in the human, the cartilage of the porcine tube was shaped like an inverted J and the 2 ends were joined by fibrous tissue. Some of the fibres of tensor veli palatini attached both to the fibrous membrane and to the cartilage in a manner similar to that found in the human. The tube narrowed as it ascended from its nasopharyngeal orifice, being narrowest at the point of entry into the bony channel. The tympanic

orifice measured 0.6 mm from medial to lateral and 3 mm from superior to inferior and was situated immediately below the origin of tensor tympani (Fig. 2).

Ciliated columnar epithelium lined the tube throughout its length in continuity with the epithelium of the nasopharynx and the area of the tympanic cavity adjacent to the tympanic end of the tube. The mucosa was thin at the tympanic end of the tube but became increasingly thickened by mucus glands

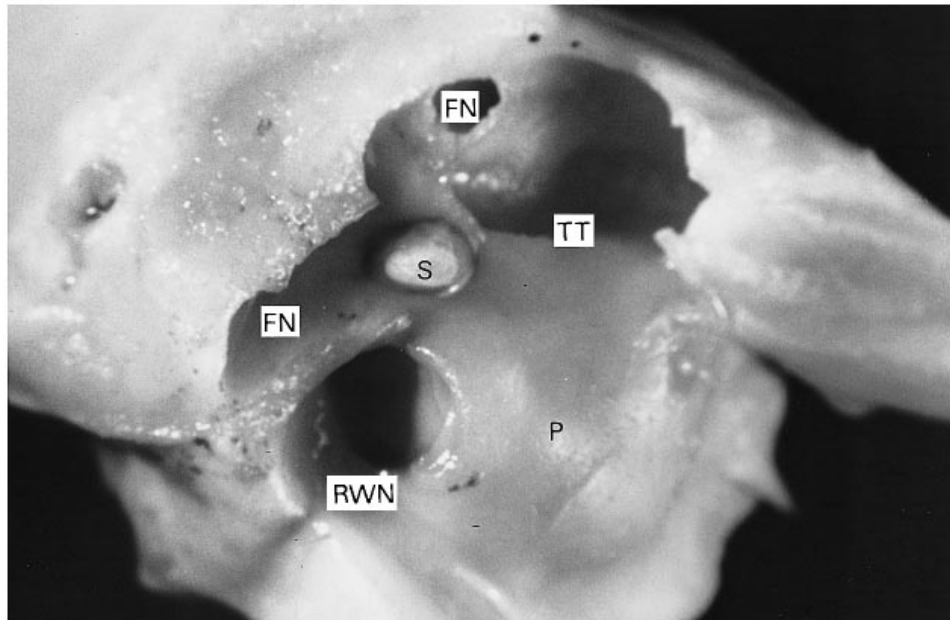


Fig. 2. Medial wall of the tympanic cavity. TT, origin of tensor tympani; P, promontory; RWN, round window niche; S, stapes; FN, facial nerve canal. $\times 10$.

towards the pharyngeal orifice. As the tube entered the tympanic cavity the cartilage divided into an anterior and posterior limb, forming a Y shape, which attached around the base of the promontory via a fascial thickening (Fig. 3).

In the region of the pharyngeal orifice a variable amount of lymphoid tissue aggregated into follicles was seen within the lamina propria, consistent with descriptions of the so-called tubal tonsil. This collection of lymphoid tissue appeared to be discrete and separated from the adenoid and so can truly be considered a tonsil in its own right (Fig. 4).

The tympanic cavity

The appearance of the tympanic cavity was similar to that seen in man (Fig. 1). Broadly speaking it was shaped like a biconcave lens and measured approximately 11 mm superoinferiorly and 11 mm anteroposteriorly. The greatest distance between the medial and lateral walls was 6 mm and the smallest 1 mm.

The roof was a relatively thin plate of bone separating the cavity from the middle cranial fossa. The anterior wall was divided into a lateral recess and a medial portion which contained the tympanic orifice of the eustachian tube. The posterior wall was composed of the bone of the fallopian canal, housing the facial nerve, as it passed from its second genu above the oval window inferiorly to exit the canal through the stylomastoid foramen situated between

the mastoid process anteriorly and the styloid process posteriorly. The floor of the cavity had a honey-combed appearance and led into a system of air cells within the cavities of the coarsely-celled plexiform bone of the tympanic bulla. In contrast to man no obvious aditus or antrum was identified (Fig. 1).

The lateral wall of the pig tympanic cavity was part bony and part membranous as in the human. The central portion of the lateral wall consisted of the tympanic membrane, a thin almost circular membrane, separating the tympanic cavity from the external auditory canal. As in the human the margins of the membrane were thickened to form the tympanic annulus which inserted into the tympanic sulcus, a groove in the tympanic bone. In common with man the tympanic sulcus was incomplete superiorly, and anterior and posterior malleolar folds ran from the superior limits of the annulus to the lateral process of the malleus. The pig tympanic membrane was inclined at an angle of 35–40° with the floor of the external ear canal. The membrane was divided, as in the human, into a pars flaccida superior to the level of the lateral process of the malleus and a pars tensa inferiorly. The pars flaccida was an extensive structure separating an elongated epitympanic recess from the external auditory canal. Laterally the pars flaccida was continuous with the linings of the external ear canal, however, medially the epithelium gradually thinned out so that the most medial portion of the membrane was of similar thickness to the pars tensa. Above the tympanic membrane the lateral wall of the tympanic

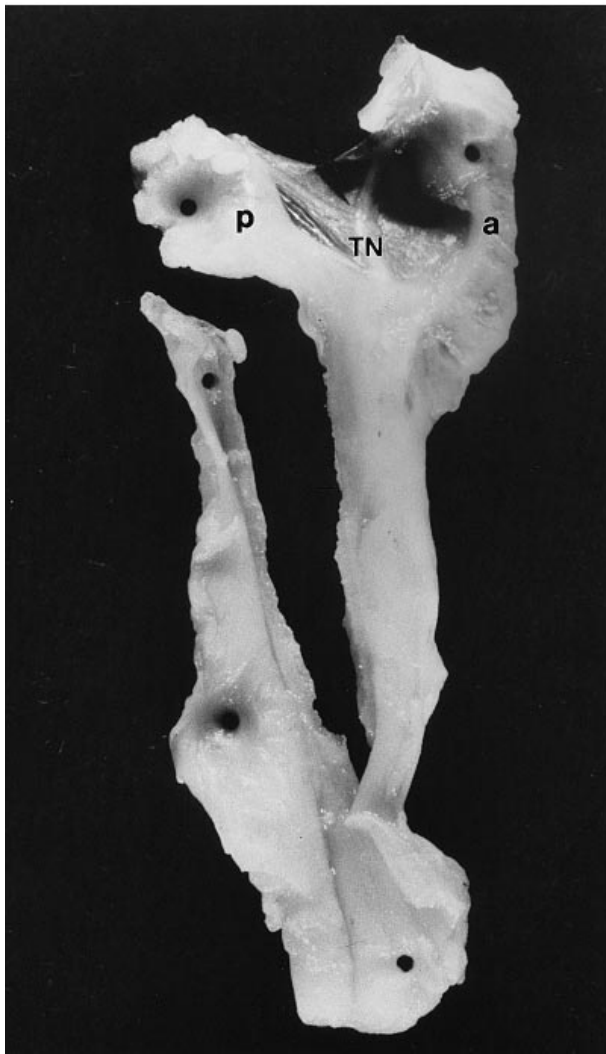

Fig. 3. Eustachian tube. The tympanic nerve (TN) is seen within the mucosa, and runs between the anterior (a) and posterior (p) limbs of the Y-shaped cartilage, and in life overlies the promontory. $\times 6$.

cavity was completed by the outer attic wall or scutum (Fig. 5).

The medial wall of the tympanic cavity separated the middle ear from the inner ear. The most obvious feature of the medial wall was the promontory, which is the bone overlying the basal turn of the cochlea. Immediately superior to the promontory the facial nerve ran in an anteroposterior direction in the fallopian canal, between the first and second genua (Fig. 2). The first genu was seen just behind the origin of the tensor tympani muscle which lay in a depression in the medial wall. This depression extended anteriorly into a conical bony pit from which the muscle fibres took their origin. The tensor tympani muscle fibres converged to form a tendon which inserted into the muscular process of the malleus (Fig. 5). Posteriorly, the fallopian canal passed above the oval window (fenestra vestibuli) before turning inferiorly at the

second genu at which point the canal formed the posterior wall of the tympanic cavity. The oval window was identified as an oval opening in the medial wall lying posterosuperiorly to the promontory, in a deep recess surrounded above and behind by the overhanging walls of the fallopian canal and below and in front by the promontory. The oval window connected the middle ear with the vestibule of the inner ear and was closed by the footplate of the stapes together with its annular ligament. The round window (fenestra cochleae) was found below and behind the oval window, separated from it by a projection of the promontory called the subiculum. As in the human this window was situated in a deep niche under the overhanging promontory and was closed by a secondary tympanic membrane. The tympanic nerve was seen crossing posteroanteriorly beneath the mucosa of the promontory, grooving the bone (Fig. 2).

The contents of the tympanic cavity

The contents of the pig tympanic cavity were essentially the same as those seen in the human. Although the ossicular chain occupied most of the space, the tensor tympani muscle, the chorda tympani and the tympanic nerve were also present (Fig. 5).

As in the human the ossicular chain together with the tympanic membrane formed the transducer mechanism of the middle ear. The malleus was the most lateral of the ossicles and was attached to the tympanic membrane along the length of its handle (Fig. 6). The stapes was the most medial and its footplate closed the oval window, thus separating the middle ear cleft from the inner ear (Fig. 7).

The malleus in the pig was of a similar shape to the human malleus, consisting of a head, neck, and handle and possessing lateral, medial and anterior processes (Fig. 6). Apart from its articular surface the malleus was covered with mucosa. The head was ovoid in shape and lay medial to the scutum. The articular surface of the head was saddle shaped, covered with cartilage and formed a synovial joint with the corresponding articular facet of the incus. Below the malleolar head the bone attenuated before giving rise to 3 processes as well as to the manubrium or handle. The anterior process provided attachment to the anterior ligament which inserted into a shallow fossa in the anterosuperior wall of the tympanic cavity. The lateral process received the anterior and posterior malleolar folds which ran centrally from the extremities of the tympanic annulus. Inferior to the malleolar neck and at right angles to the anterior

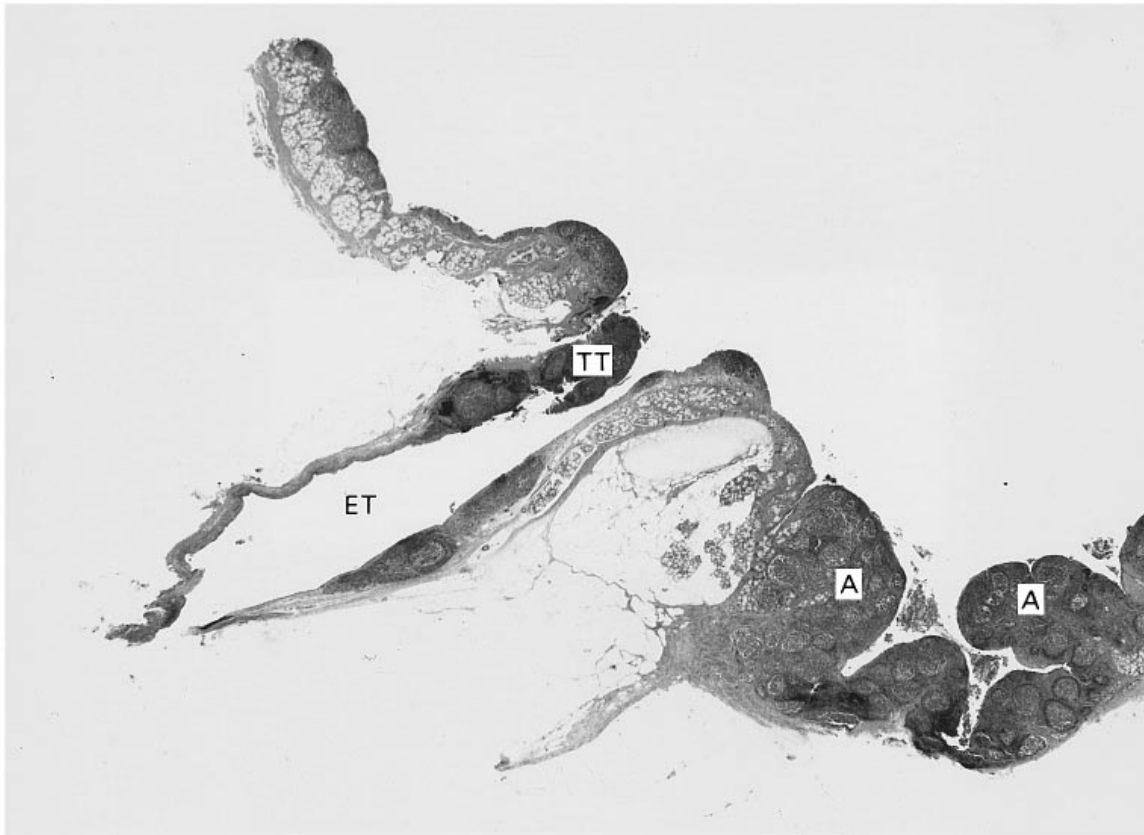


Fig. 4. Transverse section through the left nasopharynx showing the midline, the adenoid (A) and laterally the left tubal tonsil (TT) guarding the nasopharyngeal orifice of the eustachian tube (ET). $\times 6$.

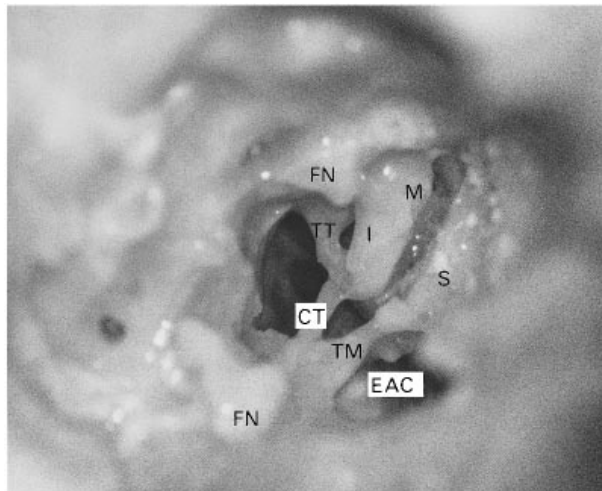


Fig. 5. Contents of the tympanic cavity: the posterior wall of the tympanic cavity has been removed, the facial nerve divided and the stapes removed. S, scutum or outer attic wall; TM, tympanic membrane remnant; TT, tensor tympani; CT, chorda tympani; M, malleus; I, incus; FN, cut ends of facial nerve; EAC, external auditory canal. $\times 25$.

process was a medial process which received the insertion of the tendon of tensor tympani. Interestingly, the handle of the malleus, which was approximately 4 mm long, had a different orientation

to that seen in man: it inclined downwards, medially and anteriorly (Fig. 6) as opposed to downwards, medially and slightly posteriorly as in man.

Although having a body and 2 processes, the pig incus was squarer than the human incus. The body lay in the epitympanum posterior to the malleus rather than medial to it. It articulated with the malleus via a saddle shaped articular surface (Fig. 6). The 2 processes were approximately 1 mm long. The posterior process, equivalent to the short process in man, projected posteroinferiorly and was held in position by a ligament arising from a shallow fossa in the posterior wall of the tympanic cavity. The medial or inferior process was much shorter than that found in man but it ran posteriorly and slightly medially to articulate with the head of the stapes.

The pig stapes was similar to that of man. It consisted of a flattened head, 2 crura and an oval footplate (Fig. 7). The head articulated with the incus and projected laterally so that the ossicle was seen to lie horizontally in a deep fossa created by the overhanging fallopian canal and the promontory. The stapes measured 2 mm from the footplate to the head and its greatest width was at the oval shaped footplate which was 1.8 mm in its longest diameter. Unlike the

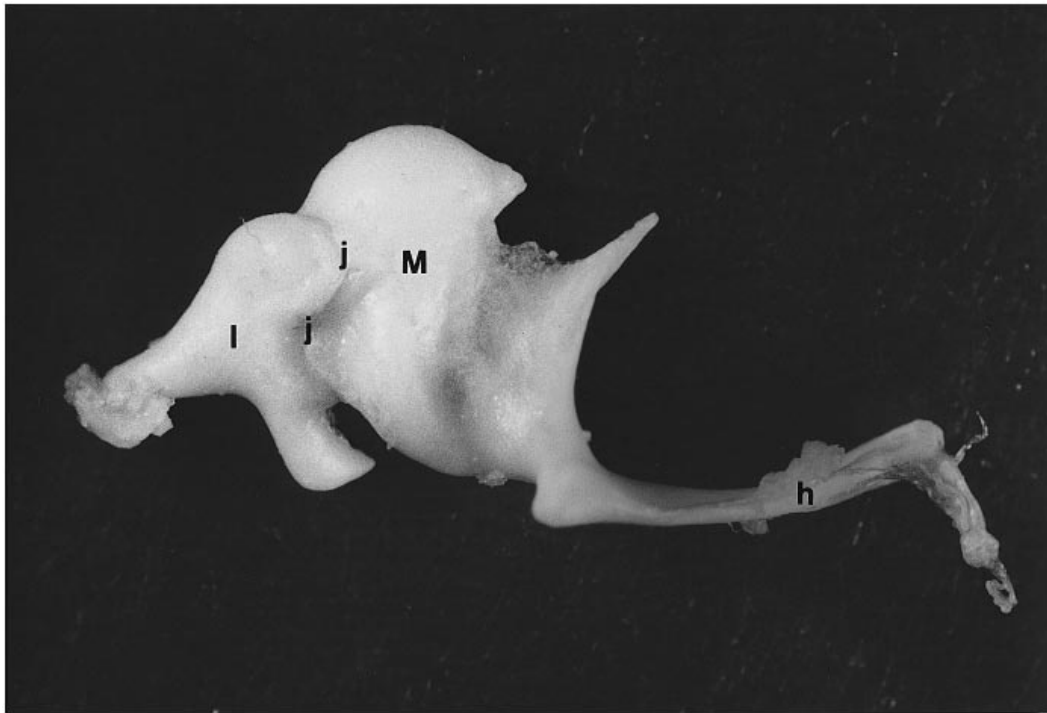


Fig. 6. Articulated malleus (M) and incus (I); j, joint; h, handle of malleus. $\times 10$.

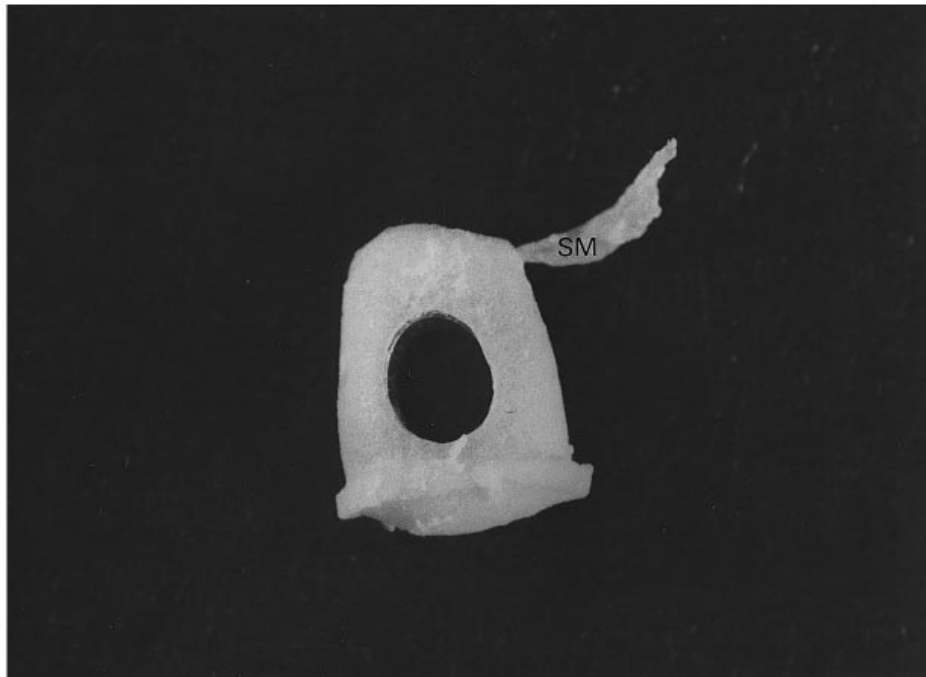

Fig. 7. Stapes showing the attachment of the stapedius muscle (SM). $\times 16$.

human stapes, in which the anterior crus is shorter than the posterior, in the pig the 2 crura were of equal length. The stapedius muscle was seen to arise from a depression in the posterior wall of the tympanic cavity deep to the overhang of the facial nerve canal. The muscle was attached to the lateral part of the posterior crus of the stapes by a delicate slender tendon.

The origin of the tensor tympani muscle was found in a shallow fossa situated in the medial wall of the tympanic cavity. This fossa had a short anterior conical extension (Fig. 2). From their broad origin the muscle fibres converged and then passed laterally at an angle of 90° to insert into the medial process of the malleus.

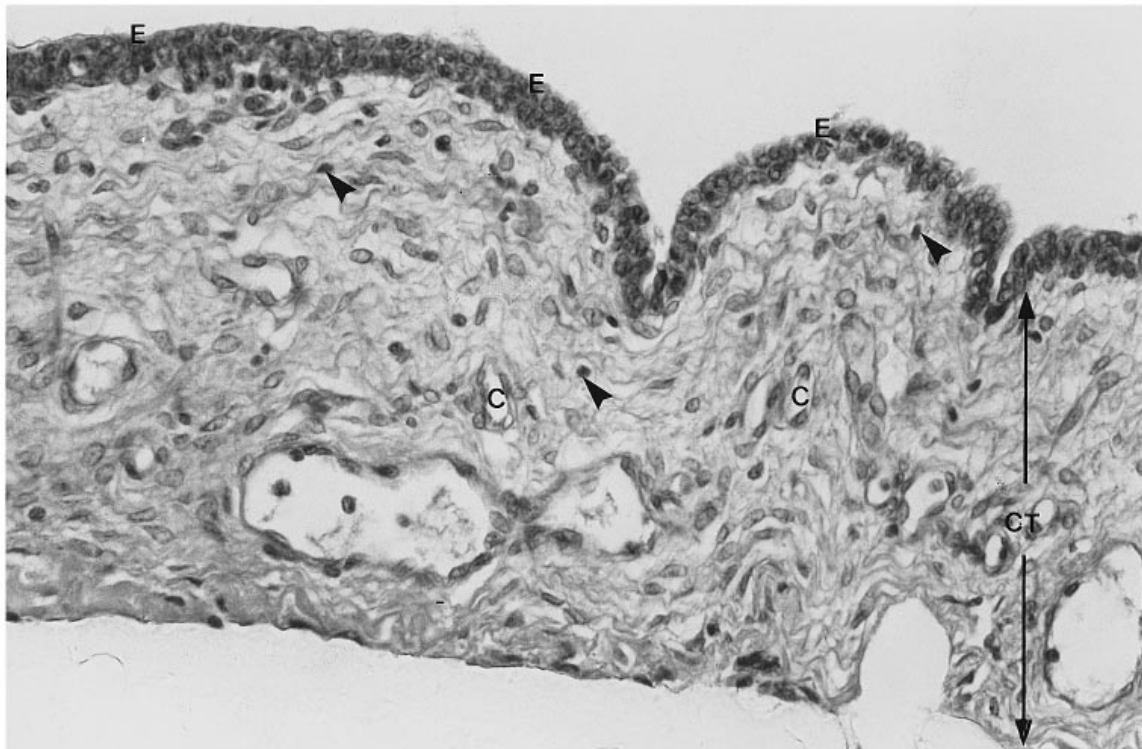


Fig. 8. Transverse section of normal porcine middle ear mucosa showing stratified cuboidal epithelium (E) overlying vascularised connective tissue (CT). C, capillary; arrowheads, lymphocytes. $\times 25$.

The chorda tympani nerve followed a similar course to that of the human. It branched from the facial nerve, ran for a short distance in the temporal bone on the posterior wall of the tympanic cavity before entering the cavity itself. It traversed the cavity posteroanteriorly, supported by a fold of middle ear mucosa, passing between the long process of the incus and the malleus, above the attachment of tensor tympani (Fig. 5). The chorda tympani exited the tympanic cavity via an anterior canaliculus situated in the anterior wall.

The tympanic nerve formed a plexus overlying the promontory as it crossed the cavity from front to back and grooved the bony surface of the promontory.

The microanatomy of the mucous membrane of the tympanic cavity

The tympanic cavity was lined by a thin delicate mucous membrane, which was continuous with the lining of the air cells within the tympanic bulla and that of the eustachian tube. As it does in man, the membrane lined the bony walls and was reflected onto the surface of the ossicles. The mucosal surface consisted of stratified cuboidal cells (Fig. 8), ciliated in places. The epithelium lay above a thick layer of loose connective tissue, which became denser as it approached the underlying bone. The connective tissue

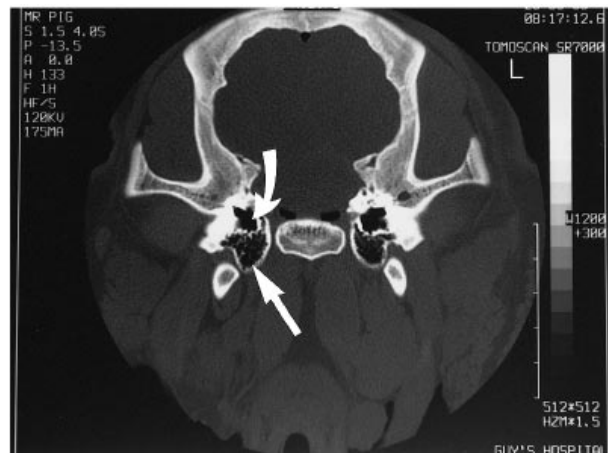

Fig. 9. Coronal CT scan of a pig head. The mastoid air cell system (straight arrow) is seen to lie medial to the temporomandibular joint and inferior to the tympanic cavity (curved arrow).

was highly vascular, containing numerous capillaries, low endothelial venules and in some areas high endothelial venules (HEVs). Very few resident lymphocytes were seen lying within the thickness of this normal, noninflamed mucosa (Fig. 8).

The air cell system

In contrast to the human, the air cell system of the pig was found lying inferiorly rather than posteriorly to the tympanic cavity (Fig. 9). There was no aditus ad

antrum or antrum seen in any of the pigs examined. The floor of the tympanic cavity was cribriform in appearance and the air cells were positioned inferior to this, lying within the plexiform bone of the tympanic bulla (Fig. 1). A variable number of interconnecting air cells were found within the tympanic bulla. The mucosal lining of these air cells was continuous with the lining of the tympanic cavity.

DISCUSSION

The observations of the present study have shown that the basic structure of the pig middle ear cavity is the same as that of the human, with the 3 main structural elements of (1) the eustachian tube, (2) the tympanic cavity and (3) an air cell system. The anatomy of each of these components was similar to that of man, although there were some minor morphological variations which do not seem to indicate a significant functional difference.

Macroscopically and microscopically the eustachian tube was very similar to that of man, was of approximately the same length and followed a more or less identical course. The main difference between the 2 species was the finding that the pig eustachian tube continued as a cartilaginomembranous structure into the tympanic cavity and appeared to be attached to the under surface of the promontory. Such an arrangement has also been reported in the Rhesus monkey (*Macaca mulatta*) (Doyle & Rood, 1980). In contrast, in man, the osseocartilaginous junction of the eustachian tube is a definite, clearly identifiable structure. There is a short extension of the cartilage into the protympanum, or bony medial third of the eustachian tube which is a continuation of the tympanic cavity (Berry et al. 1995). The cartilage extends for approximately 3 mm into the tube at which point the bony canal is lined by a very thin mucosa, identical to that found in parts of the tympanic cavity.

The structure of the pig eustachian tube appears to lie somewhat between that of man and the monkey, since the tube was cartilaginous throughout its length as in the monkey; however, the lateral third ran in a bony tube as in man. The bony channel in the pig was not an extension of the tympanic cavity as in man, but rather a channel created by a groove in the surface of the tympanic bulla and the overlying origin of tensor tympani. This feature may well indicate greater functional similarity between the eustachian tube of man and the pig rather than man and the monkey.

The pig tympanic cavity, bounded by 6 walls, had 4 walls in common with those of man and 2 (the

posterior wall and the floor) which differed. The posterior wall in man has a number of features which were absent in the pig. Firstly, the aditus ad antrum is a large irregular hole in the upper part of the posterior wall which leads directly into the human mastoid antrum (Ballantyne, 1979). Since in the pig the air cell system lay inferiorly to the tympanic cavity, this feature was absent. Secondly, in man the fallopian canal forms a prominence in the posterior wall as it runs vertically, separating a deep medial recess, the sinus tympani, from a shallower lateral one, the facial recess. In the pig the posterior wall was relatively featureless and neither of these recesses was readily discernible. Thirdly, a constant anatomical feature of the posterior wall in man is the pyramid, a conical bony projection lying just below the fossa incudis, from which the stapedius muscle tendon emerges to attach to the stapes. In this study we did not find evidence of a pyramid in the pig, instead the stapedius muscle was seen to arise from a shallow depression in the posterior wall under the overhang of the facial nerve canal. Furthermore in the pig the oval window was sited in a very deep recess formed by the overhanging fallopian canal and the promontory, so that the stapes was positioned in a very deep pit.

In his detailed account of the development of the tympanic cavity of the pig and other animals, Bondy (1908*a, b*) described structures which he called the 'Chordafortsatz' and the 'Chordafalte' in pigs. The 'Chordafalte', a mucosal fold which supports the chorda tympani as it traverses the tympanic cavity, was identified in our study. However, the 'Chordafortsatz', a bony or more rarely cartilaginous projection attached to the posterior crus of the tympanic ring, was not found in our series of Large White pigs. Although our dissection was not designed to demonstrate the 'Chordafortsatz' specifically, the original descriptions (Bondy, 1908*a, b*) refer to a sizeable structure which would have been easily identifiable. A more recent account of porcine middle ear anatomy (Gandhi, 1975) does not mention a 'Chordafortsatz', suggesting that this structure may not be present in all pigs, and that while of anatomical interest, it may be of only limited functional significance.

The floor of the tympanic cavity in the pig was cribriform and provided the entrance to the inferiorly positioned air cell system within the tympanic bulla. In contrast, in man, the floor overlies the jugular bulb, and consists of a thick plate of bone, which is occasionally deficient so that the jugular bulb encroaches on the tympanic cavity and may be at risk of damage during middle ear surgery (Wright, 1987).

In some domestic animals such as the dog (Evans, 1993) and sheep (Gandhi, 1975), the floor opens out to form a greatly expanded chamber, the tympanic bulla. The horse, on the other hand, has a floor similar to that of man but does not have a mastoid air cell system.

In this study the middle ear cavity of the pig was found to be anatomically similar to that of man. There was no structural evidence to indicate any significant functional differences between the 2 species. In addition the pig pharynx contains palatine tonsils, nasopharyngeal tonsils and, as we have demonstrated, tubal tonsils. Thus the pig has all of the pharyngeal lymphoid aggregates which together comprise Waldeyer's ring in the human. In conclusion, we propose that the pig has the potential to provide a good model for experimental studies of the dynamic immunopathological changes seen in the human during the course of middle ear inflammation.

ACKNOWLEDGEMENTS

This work was supported by the Special Trustees of St Thomas' Hospital.

REFERENCES

- BALLANTYNE J (1979) Anatomy of the ear. In *Diseases of the Ear, Nose and Throat* (ed. Ballantyne J, Groves J), 4th edn, vol. 1, pp. 1–65. London: Butterworths.
- BANCROFT JD, COOK HC (1984) *Manual of Histological Techniques*. Edinburgh: Churchill Livingstone.
- BERRY MM, STANDRING SM, BANNISTER LH (1995) Nervous system. In *Gray's Anatomy* (ed. Williams PL), 38th edn, pp. 901–1397. Edinburgh: Churchill Livingstone.
- BONDY G (1908a) Beiträge zur vergleichenden Anatomie des Gehörorgans der Säuger. *Anatomische Hefte* **35**, 106, 293–408.
- BONDY G (1908b) Über die Entwicklung des Tympanicum und der Shrapnellschen Membran des Schweines. *Anatomische Hefte* **37**, 113, 591–602.
- DOYLE WJ, ROOD SR (1980) Comparison of the anatomy of the Eustachian tube in the Rhesus monkey (*Malacca mulatta*) and man. *Annals of Otolaryngology* **89**, 49–57.
- EVANS HE (1993) The ear. In *Miller's Anatomy of the Dog* (ed. Evans HE), 3rd edn, pp. 988–1008. Philadelphia: W. B. Saunders.
- GANDHI SS (1975) The middle ear. In *Sisson & Grossman's The Anatomy of the Domestic Animals* (ed. Getty R), 5th edn, vol. 1, pp. 1204–1208. Philadelphia: W. B. Saunders.
- RYAN AF (1988) Immune-mediated otitis media in an animal model. *Annals of Otolaryngology, Rhinology and Laryngology* **97**, 24–27.
- RYAN AF, SHARP PA, HARRIS JP (1990) Lymphocyte circulation to the middle ear. *Acta Otolaryngologica (Stockh.)*, **109**, 278–287.
- WATANABE N, YOSHIMURA H, SHINODA M, BUNDO J, MOGI G (1992) Lymphocyte–mucosal interaction of the middle ear mucosa. *Acta Otolaryngologica (Stockh.)* **493**, 137–140.
- WHITEHAIR CK (1964) Nutritional deficiencies. In *Diseases of Swine* (ed. Dunne HW), 2nd edn, pp. 797–821. Iowa: Iowa State University Press.
- WILCOCK BP (1993) The eye and ear. In *Pathology of Domestic Animals* (ed. Jubb KVF, Kennedy PC, Palmer N), 4th edn, vol. 1, p. 525. San Diego: Academic Press.
- WRIGHT A (1987) Anatomy of the ear. In *Diseases of the Ear, Nose and Throat* (ed. Kerr A), 5th edn, vol. 1, pp. 1–46. London: Butterworths.