

Review

Computer-generated three-dimensional reconstructions of serially sectioned mouse embryos

M. H. KAUFMAN¹, R. M. BRUNE¹, D. R. DAVIDSON² AND R. A. BALDOCK²

¹ *Department of Anatomy, University Medical School, and* ² *MRC Human Genetics Unit, Western General Hospital, Edinburgh, UK*

(Accepted 25 November 1997)

ABSTRACT

We have been involved with a group of computer scientists and anatomists in the development of computer-based methodologies that not only combine the advantages of scanning electron microscopy and conventional histology, but provide the additional dimension of tissue recognition. The latter is achieved by the appropriate labelling of tissues and structures by delineation or ‘painting’. Individually segmented anatomically defined tissues can be highlighted in a particular colour and viewed either in isolation or in combination with other appropriately labelled tissues and organs. Tissues can be shown in any orientation either as a transparent overlay on computer-generated histological sections or as 3-D images without the histological background. An additional feature of the system is that computer graphics technology combined with 3-D glasses now also allows the viewer to see the object under analysis in stereo. This facility has been found to be particularly helpful in drawing attention to topological relationships that had not previously been readily noted. As the mouse is now the mammalian model of choice in many areas of developmental research, it is of critical importance that a basic level of skill is available in the research community in the interpretation of serially sectioned material, for example, for the rapidly expanding field in which gene expression studies play a significant role. It is equally important that there is an understanding of the dynamic changes that occur in relation to the differentiation of the various organ systems seen in these early stages of development. What we emphasise here is the additional information that it is possible to gain from the use of this tool which, in our view, could not readily have been gained from the analysis of scanning electron micrographs or by studying conventional serial histological sections of similar stages of mouse embryonic development. The methodology has been developed as part of a large project to prepare a database of mouse developmental anatomy covering all stages from fertilisation to birth in order to allow the accurate spatial mapping of gene expression and cell lineage data onto the digital Atlas of normal mouse development. In this paper we show how this digital anatomical Atlas also represents a valuable teaching aid and research tool in anatomy.

Key words: Cardiovascular system; gastrointestinal system; neurogenesis; somitogenesis.

INTRODUCTION

For most embryologists, the histological analysis of their material has been more than adequate for the type of questions that they have wished to pose. Indeed, with few exceptions, all information in the standard embryology literature has been obtained from studying this type of material (for a selection of

general reference texts for mouse, rat and human, see—mouse: Otis & Brent, 1954; Snell & Stevens, 1966; Rugh, 1968; Theiler, 1972; Kaufman, 1992; rat: Keibel, 1937; Witschi, 1962; Hebel & Stromberg, 1986; human: Keibel & Mall, 1910, 1912; Streeter, 1942; Hamilton & Mossman, 1972; Gasser, 1975; O’Rahilly & Müller, 1987). In more recent times, however, with the upsurge of interest in the molecular

basis of development, it is now apparent that relatively few scientists who work in this field have had any formal training in the basic anatomical sciences. Previously most biomedical scientists would have had an adequate knowledge of the appropriate terminology needed to describe in detail the anatomical features of any region that might be under investigation. Even more of a problem is posed by the fact that many researchers appear to be unable even to recognise the specific tissue or organ in which their gene probe is displaying activity, and the situation is compounded by the fact that many genes do not confine their activity to specific anatomical domains, nor to sites where, from other information, they might be expected to be located.

A collaborative project (the Mouse Atlas Project (MAP)) between the MRC Human Genetics Unit and the Department of Anatomy, Edinburgh, has started to build a digital Atlas of normal mouse development. The techniques developed at the MRC are designed to reconstruct a full grey-level (voxel) image of the embryo histology which can be arbitrarily resectioned to view the embryo as if sectioned at a different orientation. This histology image will act as a context-free spatial domain for mapping anatomical, gene expression and other spatially organised information. It is in this aspect that this technique is superior and more flexible than previous approaches that have been employed to obtain 3-D images of mammalian embryos, such as that developed and routinely used by the Carnegie Institute to reconstruct early stages of human embryonic development (O'Rahilly & Müller, 1987), and in the Anatomisches Institut der Universität Göttingen for the preparation of the Blechschmidt collection of embryological models (Blechschmidt, 1963).

The original aim of this project was to prepare a representative series of normal or 'standard' embryos onto which gene expression domains could be mapped (Baldock et al. 1992; Ringwald et al. 1994; Davidson et al. 1998), however, this material would also be of great value to those developmental and molecular biologists whose expertise and background did not ordinarily provide them with the necessary expertise to readily interpret serial sections of even morphologically normal mammalian embryos. While for most embryologists, the interpretation of serially sectioned embryonic material poses no particular problems, we would wish to emphasise that the methodology developed as part of the MAP provides new insights into the relationships that exist between the various components of early postimplantation mouse embryos that we, at least, had not previously appreciated.

Captured images of adjacent sections from specifically selected embryos, mostly published in *The Atlas of Mouse Development* (Kaufman, 1992) have been aligned using a warping programme to minimise section distortions. The computer-generated reconstructions of these embryos may then be resectioned in any plane in order to match the viewer's own material (Kaufman et al. 1997). This then acts as the starting point for the viewer who may wish to identify specific features or components within their own material. Within the representative or 'standard' embryos, anatomical domains have been delineated and painted in different colours. The individual anatomically discrete components, or indeed any set of components can then be viewed as transparent or solid overlays on sections of any orientation through the reconstruction, or as surface or volume rendered 3-D images. The surface rendered images can also be viewed with special glasses which create a stereo perception of the image on the computer screen. At this time, the MAP has completed the labelling of a series of representative embryos covering the period between fertilisation and Theiler Stage 14 (TS 14) (E9). (The standardised nomenclature, reconstructions and mapped anatomy are the subject of 2 publications in preparation and will be available in due course).

Examples will be presented to illustrate how this approach may be used to facilitate the interpretation of a primitive streak stage embryo (E7) and a selection of early postimplantation embryos, with particular reference to the early stages of development of the cardiovascular system, the gut and other organ systems. The configurational changes that take place in the axis of the embryo during the process of 'turning' (or 'axial rotation'), when the mouse embryo adopts the so-called 'fetal' position, will also be illustrated. This process is usually initiated when the embryo possesses about 6–8 pairs of somites (E8), and is normally completed by the time that the embryo possesses 14–16 pairs of somites (E8.5–9) (Kaufman, 1992).

Because we have previously described the methodology involved in the capturing, warping and generation of digital images (for general observations on the methodology, see Baldock et al. 1992; Guest & Baldock, 1995; Kaufman et al. 1997), we will confine ourselves here to a consideration of the advantages to be gained from the analysis of computer-generated 3-D reconstructions of serially sectioned mouse embryos, both for the experienced embryologist as well as for those who are less familiar with the interpretation of this material, but are nevertheless

required, because of the nature of their own research, to accurately recognise the various anatomical features of their own early postimplantation mouse embryos.

ADVANTAGES TO BE GAINED FROM THE
ANALYSIS OF EARLY POSTIMPLANTATION
EMBRYOS STUDIED BY COMPUTER-GENERATED
3-D RECONSTRUCTIONS

Attention has previously been drawn to the ability to prepare, at an early stage in this exercise, 3-D views of embryos as though still within their solid block of paraffin wax (Kaufman et al. 1997). It was also shown that sections could be removed from any face of the 'block' in any orientation to reveal digital grey level images which, due to the efficiency of the aligning and subsequent warping exercise, closely resembled histological sections (Fig. 1).

After all the morphologically distinguishable tissues observed on the sections of the reconstructed embryos were painted, it was then possible to view either the intact embryo or individual components of the embryo, either in isolation, or in combination with other components of the embryo. This approach has allowed the anatomical structure of embryos and the relationship between their component parts to be understood in considerably greater detail than had formerly been possible.

As emphasised above, the particular advantage of this methodology is that reconstructed embryos can be resectioned in any arbitrary plane. Furthermore, programs developed at the MRC allow 'real-time' browsing through the image volume at any orientation with the overlay of up to 32 structures of interest, of which 5 can be transparent (although colour-coded), so that the underlying histological features are still visible beneath the delineated tissues. Previously, the only way that a viewer could reconstruct a 3-D image of the histology of sectioned objects was by scanning through serial sections and producing a mental picture of the subject under analysis, often a technically difficult exercise, particularly when many sections are involved. The availability of a 3-D voxel image removes the 'computational load' on the viewer by 'remembering' the previous sequence of sections, and producing an image of the volume of the subject and its component tissues displayed in different colours. It is also now possible to investigate the relationship between a greater number of structures than was formerly the case.

With the appropriate visualisation software, the internal anatomically-discrete components of an

embryo to be viewed within a ghost-like (i.e. transparent) image of its external contours, and it is now a technically simple exercise to visualise in early limb bud embryos the exact location of the heart, hepatic diverticulum and septum transversum, as well as the derivatives of the intermediate mesoderm in relation to specific (i.e. numbered) somites. Equally, it is now possible to view accurately the relationship that exists between the 1st and 2nd pharyngeal arch arteries and the pharyngeal components of the developing foregut (see below). Despite the fact that such embryos are still at an early stage of hindbrain differentiation, it is nevertheless also now possible to relate specific structures, such as the trigeminal and facioacoustic neural crest outgrowths, to specific rhombomeres. It has again to be emphasised that none of these relationships could have been accurately determined from the analysis of histological sections alone.

The MAP plans initially to confine activities to the establishment of a digital Atlas of normal embryos. The principal aim of this review therefore is to emphasise that if the methodology described here (or comparable methodology from other sources) is utilised, a lack of familiarity with the detailed morphology of a particular stage or stages of mouse development should not preclude the researcher from interpreting the important features of their own serially sectioned material with a high degree of confidence. At some stage in the future, should time and manpower permit, we would hope that it might be possible to maintain a similar type of digital Atlas of mutant embryos, as this would undoubtedly also be of considerable benefit to the scientific community.

LIMITATIONS OF THE METHODOLOGY

Having discussed the principal advantages that may be gained from the analysis of the computer-generated 3-D reconstructions that have been prepared, it is appropriate to draw attention to the main limitations of this material. This relates to the fact that each Theiler stage is presently represented by only a single embryo. This is because it is extremely time consuming to prepare even a single embryo, and only sufficient time and manpower has been available to us to prepare one embryo from each Theiler stage. Clearly, even though each of these 'representative' embryos has been selected because it possesses all of the specific features characteristically present at a particular developmental stage, there will inevitably be a spectrum of minor variations observed in embryos that are all nominally designated as being at the same

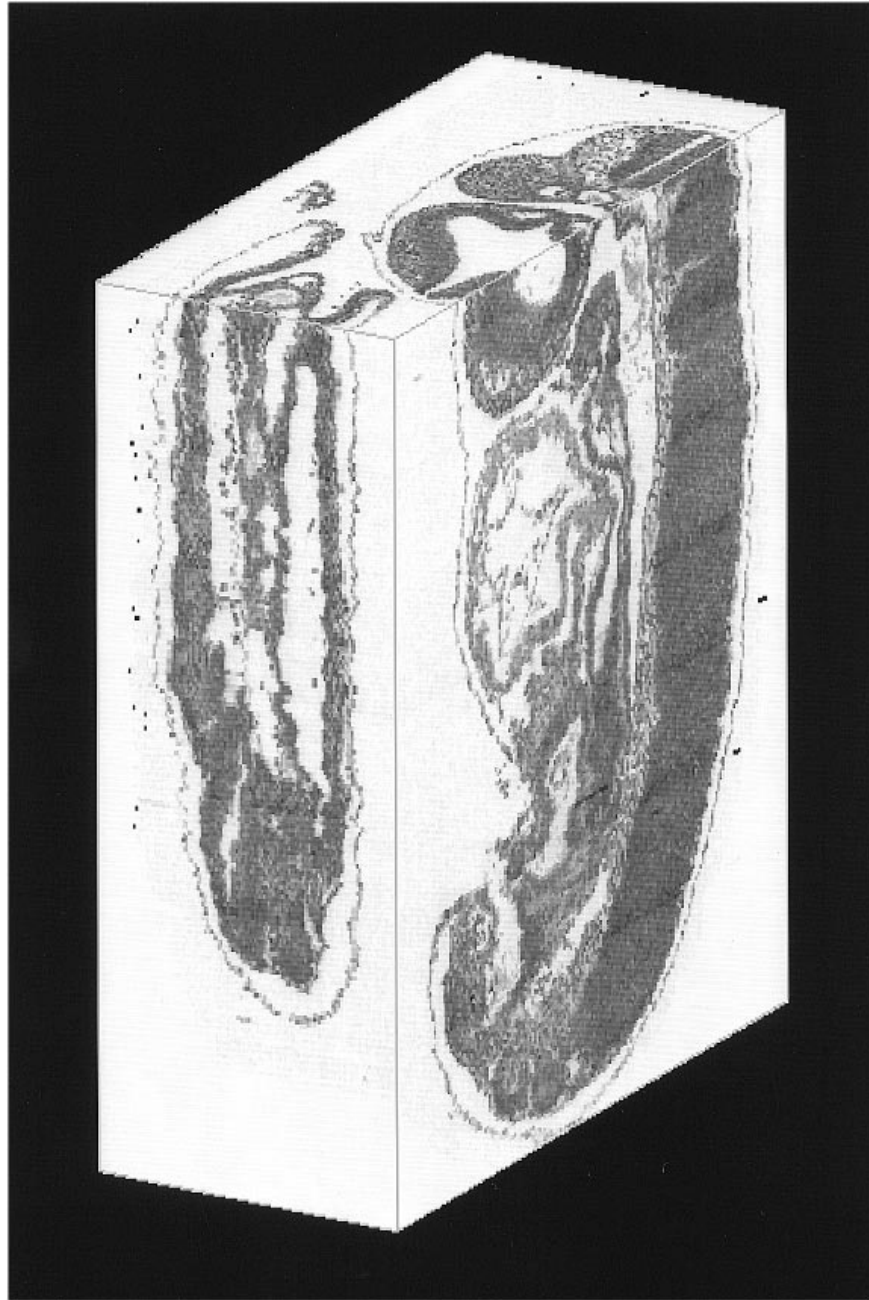


Fig. 1. 3-D reconstruction of the intact Theiler Stage 14 (TS 14) mouse embryo viewed as though still within its solid block of paraffin wax. Sections have been removed from different faces of the block to reveal grey level images which closely resemble histological sections. The section through the upper face of the block reveals the grey level image that closely resembles the orientation of the original transverse section that was captured, aligned and warped, being the first stage of the 3-D reconstruction exercise.

Theiler stage. The principal features observed at each of the Theiler stages between TS 6–14 are indicated in Table 1.

The situation is also complicated by interstrain variability, and this is particularly evident during the early primitive streak stage. It has previously been noted (see Kaufman et al. 1997) that difficulties are encountered in staging early primitive-streak stage mouse embryos because of significant strain differences in the timing of the first appearance of the

allantoic bud. In (C57BL × CBA) F1 hybrid mice, the allantoic bud is first seen at the late streak stage (now termed TS 10.5), while in the PO outbred strain, by contrast, the allantoic bud does not appear until during TS 11 (Downs & Davies, 1993) if the original criteria used by Theiler (1972) to classify these stages are strictly adhered to. Accordingly, it has been recommended that the original Theiler nomenclature be amended to accommodate this particular problem (Kaufman & Bard, 1998; K. Lawson, personal com-

Table 1. *The principal features observed at the various Theiler stages between TS 6–14*

Theiler stage	Developmental age (days p.c.*)	Principal features
6	4.5	Attaching blastocyst
7	5	Early egg cylinder. Ectoplacental cone appears. Embryo implanted
8	6	Differentiation of egg cylinder. Proamniotic cavity appears
9	6.5	Advanced endometrial reaction. Formation of mesoderm
10	7	Amnion formation. Primitive groove. Allantois
11	7.5	Neural plate, presomite stage
12	8–8.5	First somites. Neural folds begin to close in occipital/cervical region
13	8.5–9	'Turning'. Two pharyngeal bars, optic sulcus
14	9–9.5	Elevation of cephalic neural folds, formation of rostral neuropore. Optic vesicle formation

* p.c., postcoitum.

munication). The amended staging system is shown in Table 2.

Before discussing these various stages of development, it is appropriate to draw attention to the assumptions used to correct the random distortions of each section which arise from the microtome and histological processing. We require a representative embryo, and therefore do not attempt to reconstruct the embryo as embedded, but allow some of the systematic (common to all sections) distortion to remain. We correct the random distortions within each section by assuming that the anatomical structures are smooth at the scale of the section thickness.

This, in principle, could smooth (but not completely remove) a structural prominence (or indentation) of width less than 7 μm . During warping, each section image is treated as a thin elastic plate linked at corresponding points on the adjacent superior and inferior sections. The stack of images is then modified using an appropriately designed computer program until an equilibrium state in which the required alignment and distortion correction is achieved. The methodology involved is detailed elsewhere (Guest & Baldock, 1995).

EARLY POSTIMPLANTATION STAGES OF MOUSE DEVELOPMENT

In order to appreciate the value of the approach to be described here, it is useful to provide a brief overview of the changes that take place in the morphological features of the mouse embryo between implantation (which occurs during TS 6 (E4.5)) and TS 14 (E9–9.5), when the embryo possesses between 13–20 pairs of somites. Because mouse developmental anatomy is now normally, and conveniently, described in terms of the events occurring at specific Theiler stages (Theiler, 1972, reprinted 1989 with minor changes; Kaufman, 1992), it is relevant to draw attention to the principal features observed in embryos as they progress between TS 6–14 (see Table 1).

It should be emphasised that all morphological features noted in Table 1 may readily be recognised from a cursory analysis of serial sections of representative embryos at each of the Theiler stages indicated. What is more difficult to appreciate, however, is the exact shape of the various tissues and how they relate to each other. During the early postimplantation period, between TS 6 and TS 7/8, when the embryo progresses from the early to the

Table 2. *Recommended amended Theiler staging system to accommodate strain differences between embryos isolated from PO and (C57BL \times CBA) F1 hybrid mice (from Kaufman & Bard, 1998)*

Stage	Age (dpc)*	Staging system	
		Defining characteristic PO mice	Defining characteristic C57BL \times CBA F1 mice
TS 9	6.25–7.25	Late egg cylinder or prestreak stage	Late egg cylinder or prestreak stage
TS 9.5	6.25–7.25	Early streak	Early streak
TS 10	6.5–7.5	Primitive streak stage	Primitive streak stage
TS 10.5	6.5–7.5	Late streak stage	Late streak stage + allantoic bud
TS 11	7.25–8	Preallantoic bud stage	As TS 10.5
TS 11.25	7.25–8	Early allantoic bud stage	Allantoic bud stage
TS 11.5	7.25–8	Late allantoic bud stage	Late allantoic bud stage
TS 11.75	7.25–8	Early headfold stage	Early headfold stage
TS 12	7.5–8.75	1–7 pairs of somites	1–7 pairs of somites

* Day postcoitum.

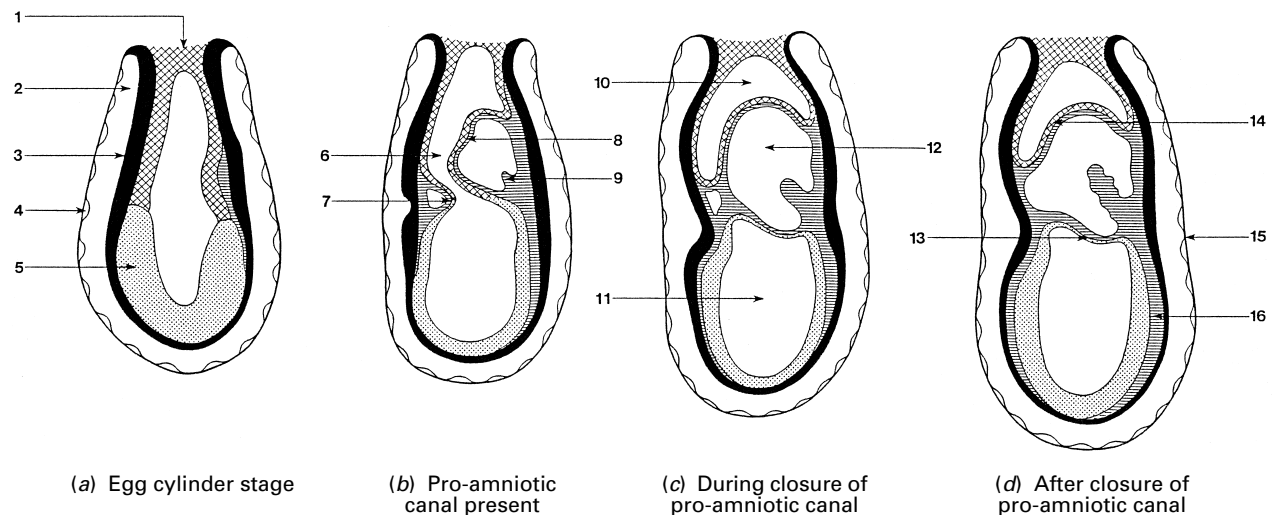


Fig. 2. Stages in the conversion of the egg cylinder into the primitive streak stage embryo. (a) Egg cylinder stage; (b) proamniotic canal present; (c) during closure of proamniotic canal; (d) after closure of proamniotic canal. (From Kaufman, 1990, with permission). 1, Ectoplacental cone; 2, yolk sac cavity; 3, visceral endoderm; 4, parietal endoderm; 5, embryonic ectoderm; 6, proamniotic canal; 7, anterior amniotic fold; 8, posterior amniotic fold; 9, allantois; 10, ectoplacental cavity; 11, amniotic cavity; 12, exocoelomic cavity; 13, amnion; 14, chorion; 15, Reichert's membrane; 16, mesoderm.

advanced egg cylinder stage, no obvious dorsiventral axis is apparent, although the embryo possesses an embryonic and an abembryonic pole, the latter being associated with the ectoplacental cone. The situation becomes clearer when the first evidence of an embryonic axis is seen, with the appearance of the primitive streak. Until this stage of development, there is little to be gained from computer-generated 3-D reconstructions of early postimplantation embryos beyond the ability to 'dissect' the outer endodermal 'shell' from the inner layer of ectoderm, although these have yet to become subdivided into embryonic (distal) and extraembryonic (proximal) components.

During TS 7, the egg cylinder shows progressive evidence of differentiation, while during TS 8, the proamniotic cavity first appears in the centre of the primitive ectoderm, initially in the embryonic pole, and extends proximally towards the abembryonic pole. Reichert's membrane is secreted by the distal endoderm cells, and the ectoplacental cone forms at this time. Slightly later, at the advanced egg cylinder stage (during TS 9), a morphological distinction becomes apparent between the embryonic and abembryonic components of the egg cylinder. Scanning microscopy of the external features of embryos at this stage reveals a variation in the morphology of the endodermal cells, with a relatively clear line of demarcation developing between the flattened (squamous) cells that overlie the embryonic pole, and cuboidal or columnar cells, with a characteristic microvillous border, that cover the abembryonic (extraembryonic) pole. The location of this border appears to migrate proximally during the differen-

tiation of the egg cylinder. It is also apparent that the embryonic ectoderm cells tend to have a larger volume than those of the extraembryonic ectoderm cells, and additionally show evidence of radial alignment not readily apparent in the extraembryonic cells. The most advanced embryos at this stage tend to be flattened from side-to-side along much of their longitudinal axis, and this will in due course be associated with the first appearance of a distinct embryonic axis.

When the anterior and posterior amniotic folds are at their greatest volume, at the end of the egg cylinder stage, they gradually merge together and this rapidly results in the obliteration of the middle portion of the proamniotic canal. This results in the formation of 3 distinct cavities within the primitive streak stage embryo, the amniotic cavity (distally), the exocoelomic cavity in an intermediate location, and proximally, the ectoplacental cavity. A diagrammatic series that displays the configurational changes that take place in egg cylinders as they differentiate into the primitive streak stage is illustrated in Figure 2.

The stages which are of particular relevance to the developmental biologist who is interested in the genetic control of morphogenesis are those between E7 and E9–9.5, although much needs to be learned about these stages of development, for example, up to E13, in order to investigate the events associated with early organogenesis.

The use of our method as an instruction aid will be illustrated by looking at a reconstruction of an early primitive streak stage embryo at TS 10 (E7), and early differentiation of a variety of organ systems in

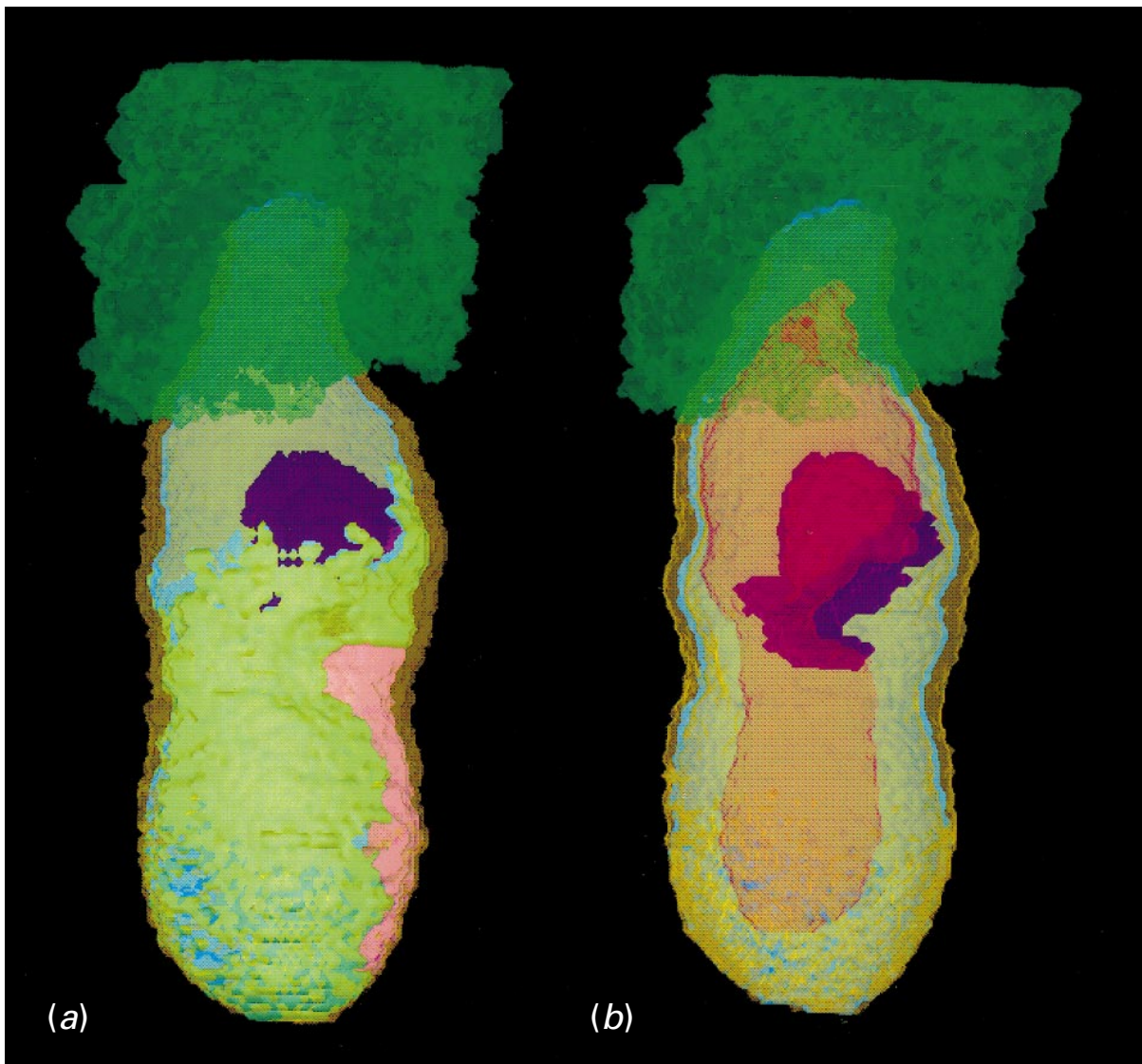


Fig. 3. Two views of reconstructions of the TS 10 primitive streak stage embryo. (a) Attention is particularly drawn in this view to the location of the primitive streak (pink) and extent of migration of the mesoderm (pale green). (b) No distinction is made in this view between the embryonic and extraembryonic ectoderm (pale yellow). The boundaries of the posterior amniotic fold are shown in purple, and the extent of the proamniotic canal (in *b*) is shown in pale brown. In *a* and *b*, the ectoplacental cone is shown in dark green, and the embryonic and extraembryonic endoderm in khaki green.

reconstructions of embryos at stages between TS 12–14 (E8–9). These systems are the neural tissue, heart and vascular system, somitogenesis and early stages in the development of the alimentary system. The stages to be considered here are as follows. (1) A primitive streak stage embryo, typical of one that might be isolated at about E7, in which the first evidence of the posterior amniotic fold is seen, but prior to anterior amniotic fold and allantoic bud formation; consistent with a TS 10 embryo. This embryo was fixed and embedded in Araldite before being sectioned at a nominal thickness of 2 μm and subsequently stained with 1% toluidine blue in 1% borax. The anatomical domains on every section were

painted. (2) A headfold stage embryo with about 8 pairs of somites, typical of one that might be isolated at about E8, which displays the features characteristically seen at TS 12. This embryo was treated in all respects as detailed for embryo (1), above. While only 1 in 3 of the original sections was painted, these delineations were propagated to the previous and following sections to ensure image continuity. (3) An embryo with 12 pairs of somites present which is progressing through the process of ‘turning’. This embryo is typical of one that might be isolated at about E8.5. It was fixed in Bouin’s solution and embedded in paraffin wax before being serially sectioned at a nominal thickness of 7 μm and

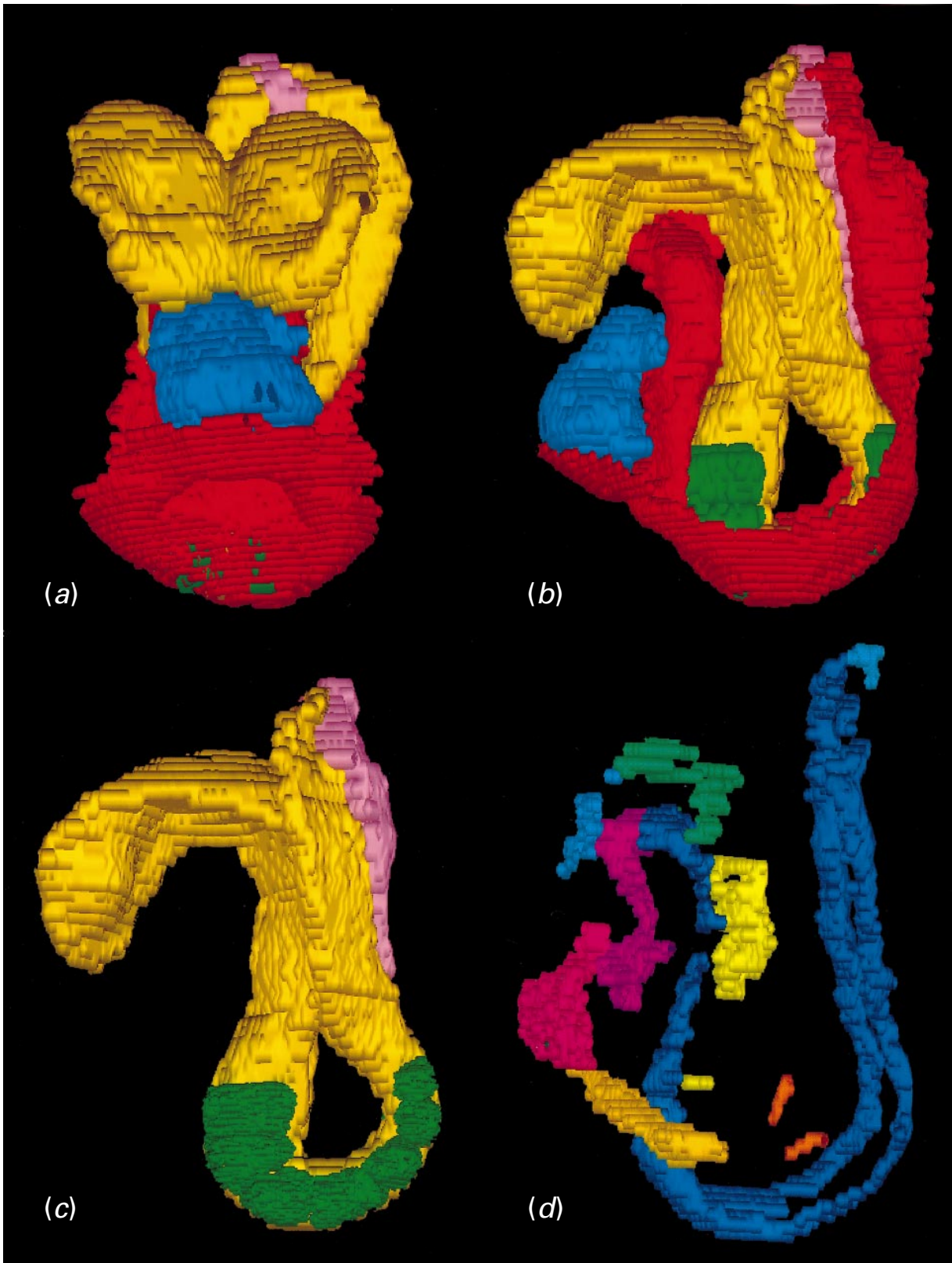


Fig. 4. Four views of reconstructions of the TS 12 headfold stage embryo with about 8 pairs of somites. (a, b) Frontal (a) and left lateral (b) views of this embryo; red, endoderm of gut; blue, heart; yellow, neuroepithelium; green, somites; pink, primitive streak. (c) In this view, only the neuroepithelium, somites and primitive streak are delineated. Note in particular, from the frontal view (a), the entrance to the foregut pocket, and the 2 neuroepithelial evaginations (the optic pits) in the future diencephalic region of the forebrain. Only when the everted gut endoderm is absent (c), is it possible to clearly view the somites. (d) View of the endothelial lining of the heart and vascular system viewed

subsequently stained with haematoxylin and eosin. A total of 24 representative intermittent serial sections through this embryo (out of a total of 244 sections) have previously been published as plates 16a and 16b in *The Atlas of Mouse Development* (Kaufman, 1992). The anatomical domains on every section were painted. (4) An embryo with about 17 pairs of somites which has almost completed the turning sequence. This embryo has the characteristic features seen in embryos isolated at about E9. It was fixed in Bouin's solution and embedded in paraffin wax before being serially sectioned at a nominal thickness of 7 µm and subsequently stained with haematoxylin and eosin. A total of 30 representative intermittent serial sections through this embryo (out of a total of 307 sections) have previously been published as plates 18a and 18b in *The Atlas of Mouse Development* (Kaufman, 1992). As in the previous embryo, all anatomical domains on every section were painted.

The TS 10 primitive streak stage embryo

One of the characteristic features of primitive streak stage embryos (TS 10) is the presence of the intra-embryonic mesoderm. These cells migrate forwards from the primitive streak region in the direction of the neuroepithelium of the future headfolds, and will shortly separate the latter from the subjacent covering of embryonic endoderm distally and more proximally, the extraembryonic ectoderm from the extraembryonic endoderm. The 3-D reconstruction of the mesoderm provides an accurate impression of the overall distribution of this tissue (Fig. 3a). The shape and extent of the posterior amniotic fold can now also be examined in a more detailed way than was formerly possible either through the analysis of conventional serial sections or by examining the intact embryo under the dissecting microscope (Fig. 3b).

The interpretation of histological sections through this stage of rodent development can be quite daunting, with sections through the posterior amniotic fold often being particularly difficult to interpret. Having a reconstructed embryo accessible as a set of histological sections, and with its various tissues displayed in differently coloured washes, greatly assists in the assigning of cells to particular tissues, while the volume rendering facilitates the interpretation of the topological relations of the different components of the embryo.

The TS 12 headfold stage embryo with about 8 pairs of somites

An analysis of the 3-D rendered image of the neural tissue clearly reveals the presence of the optic evaginations (Fig. 4a). The shape of the latter as well as the external contours of the neural tissue are particularly well seen; both are less readily appreciated from the analysis of serially sectioned material (Fig. 4b). As the majority of the somites are covered by the everted endodermal lining of the prospective midgut region (Fig. 4b), this makes it impossible to determine the exact number of somites present. When the neuroepithelium and somites are viewed in isolation, however, it is then possible to establish that this embryo possesses about 8 pairs of somites (Fig. 4c). At this early stage of somitogenesis, while the most rostral of the somites are present in the form of recognisable units, the most caudal part of the paraxial mesoderm has yet to differentiate into discrete segmental units.

The heart and vascular system in this embryo are at a particularly early stage of differentiation, and would have been particularly difficult to reconstruct from the analysis of serial section alone. Indeed, in places, segments of the primitive vasculature have yet to amalgamate together to form recognisable vessels (see Fig. 4d). This appears to be the case in the cephalic region, where the thin-walled primary head veins are in places particularly difficult to discern. By contrast, the paired dorsal aortae and principal components of the inflow and outflow tracts of the heart are clearly seen. In the reconstructions, asymmetries between the left and right sides of the vascular system are also clearly displayed, and could now be studied.

In embryos at this stage of development, it is particularly difficult to understand the relationship between the tissues that are differentiating into the septum transversum, those close to the caudal part of the heart, and the mesothelial lining of the intra-embryonic coelom. This is now technically feasible if each tissue is individually delineated and reconstructed.

The TS 13 stage embryo with 12 pairs of somites

The reconstruction of the TS 13 embryo is particularly informative, not least because it has yet to complete the turning process, and this has secondary conse-

from the left side, with anatomically discrete components colour-coded; key to principal components: yellow-orange, sinus venosus; magenta, primitive heart; mauve, 1st arch artery; dark blue, dorsal aorta; light blue, cephalic extension of dorsal aorta (future internal carotid artery); green, primary head veins; yellow, anterior cardinal vein; orange, posterior cardinal vein; blue-green, vitelline artery.

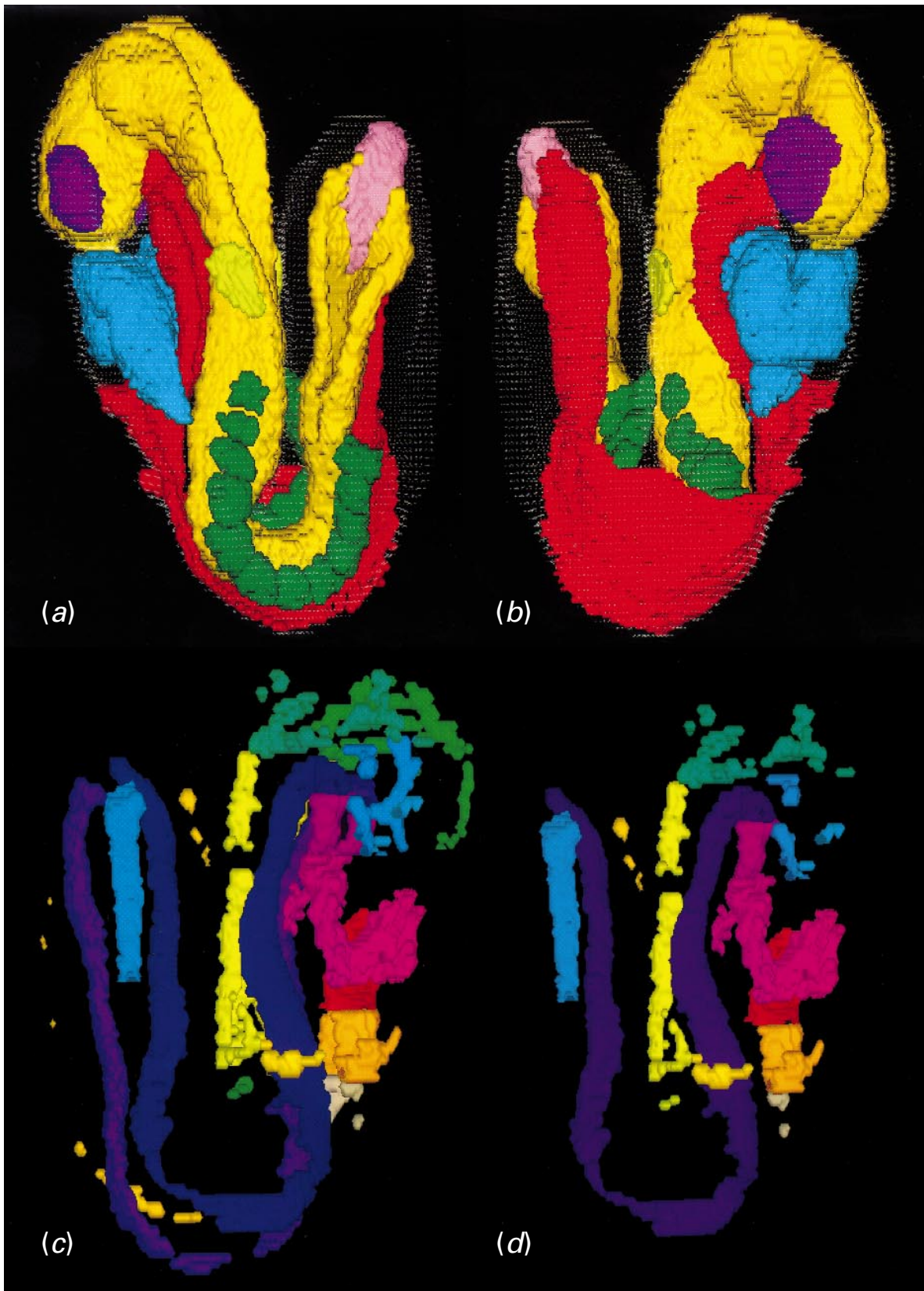


Fig. 5. Four views of reconstructions of the TS 13 stage embryo with 12 pairs of somites. (a, b) Left lateral (a) and right lateral (b) views of this embryo; same colour coding as for Figure 4a, b, with addition of mauve, optic vesicles; yellow, otic placode/pit. Note (1) that it is only possible to see all of the somites in (a), and that in (b) the majority of the somites are hidden by the everted endoderm of the future midgut region, (2) that the neural folds in the future hindbrain (the only part of the cephalic region that is clearly seen in this view) and tail region (caudal neuropore) are widely open, (3) that in (a), the wall of the left side of the common atrial chamber of the heart is in continuity with

quences on the configuration of all of its midaxial structures. While the external configuration is clearly seen in external views of the 3-D reconstruction, if the surface ectoderm is either excluded or only retained as a transparent image, it is possible to determine that this embryo possesses 12 discrete pairs of somites. From such a reconstruction it is possible to establish that the somites extend rostrally to a site just caudal to the lower border of the elongated otic placode and caudally almost to the rostral extent of the caudal neuropore (Fig. 5*a*). At this stage, the future rhombencephalic (hindbrain) region does not yet appear to be subdivided into rhombomeric units, although the extent of the occluded region of the hindbrain is clearly seen.

As this embryo is in the middle of the turning sequence, a clear degree of asymmetry is seen between its right and left sides. This is particularly evident with regard to the appearance of the midgut region of the exposed primitive gut, where the everted endodermal lining of the right side almost covers the somites of this side (Fig. 5*b*), while on the left side, the somites are all readily seen (Fig. 5*a*). The process of turning causes much (temporary) asymmetry in the embryo, and makes it difficult to envisage topological relationships between its component tissues. Panels *a* and *b* of Figure 5 clearly show this asymmetry and make it instantly understandable. Furthermore, much useful information can be gained about the direction of turning by studying the configuration of the tissues. The temporary asymmetry also complicates the interpretation of (seemingly) transverse sections which now do not have identical left and right sided components.

The configuration of the heart in this embryo is of interest because its inflow components (the left and right horns of the sinus venosus and the various vessels that drain into them) are clearly asymmetric. It is only possible to gain a reasonably complete impression of the degree of differentiation of the cardiovascular system at this stage of development from its 3-D reconstruction which is displayed in Figure 5*c*.

The venous system, in particular, illustrates the extreme degree of cephalocaudal progression evident

at this stage of development. Only a suggestion of the posterior cardinal veins is present in this embryo, and this is consistent with the fact that while the cephalic and upper trunk regions are reasonably well differentiated, the caudal half of the trunk and tail region are only poorly differentiated. Because of the complexity of the vascular system observed even at this stage of development, for most purposes it is usually necessary to view its left and right components separately (Fig. 5*d*).

The TS 14 stage embryo with about 17 pairs of somites

The detailed histological morphology of this embryo and the anatomical features that characterise this stage of development have been illustrated and described elsewhere (Kaufman, 1992), as well as the sequential stages involved in the preparation of the digital image of this mouse (Kaufman et al. 1997), so that these aspects will not be considered here.

Attention has also previously been drawn to the fact that using the reconstruction approach indicated here, it is now possible to determine both the total number of somites present, as well as to visualise the relationship between different components of this embryo accurately. A right lateral view of this embryo indicates that it appears to have about 17 pairs of somites (Fig. 6*a*), and that it has essentially completed the process of turning. In this Figure, the neuroepithelium of the neural tube, the somites, the gut tube and heart are displayed in different colours, against a transparent image of the surface ectoderm. The reconstruction of the somites makes it possible to determine the degree of segmentation of these units.

The heart, by this stage, is an asymmetric structure at an advanced stage of looping and its morphology would not have been readily understandable without displaying its various component parts in different colours; to emphasise its complex configuration, right and left lateral views of the heart are illustrated in Figure 6*b, c*, with the common atrial chamber, primitive ventricle and bulbus cordis (and outflow tract) delineated in different colours. The difference in orientation of the heart between that seen at TS 13

the primitive ventricle, while in (*b*), the primitive ventricle is seen to be in continuity with the bulbus cordis, which is itself in continuity with the outflow tract of the heart. (*c, d*) Right lateral views of the endothelial lining of the heart and entire vascular system (*c*), and the heart and only the right side of the vascular system (*d*); orange, sinus venosus; red, common atrium; various shades of pink, primitive ventricle, bulbus cordis, 1st arch artery; mauve, dorsal aorta; blue, internal carotid artery; green, primary head veins; yellow, anterior cardinal vein; yellow-orange, common cardinal vein; green, posterior cardinal vein; biscuit yellow, vitelline vein; pale orange (in tail region, *c*), umbilical vein; sky blue (in tail region), vitelline artery. Note that at this stage the dorsal aortae are seen to be 2 discrete vessels throughout their length.

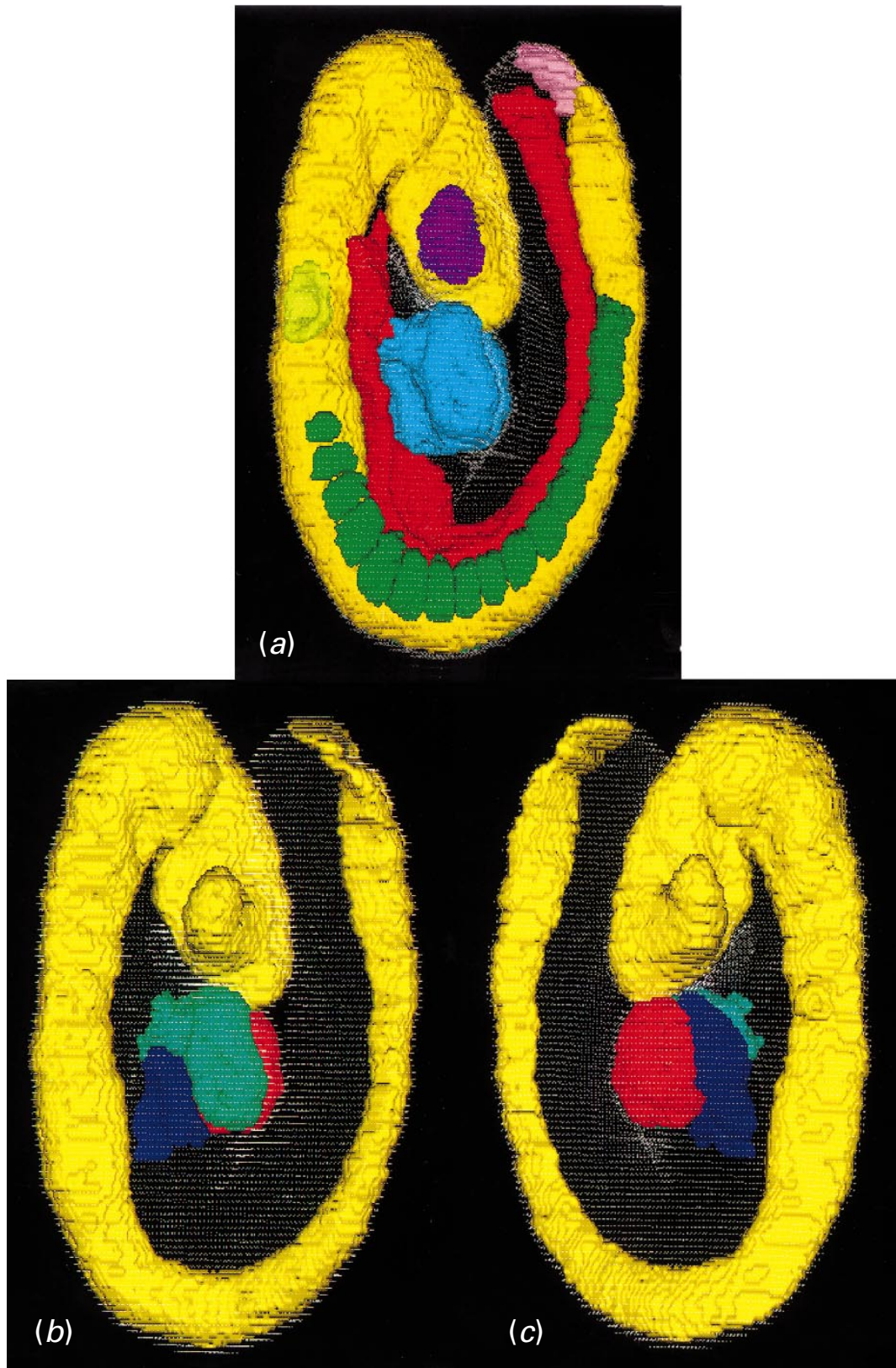


Fig. 6. For legend see opposite.

and TS 14 can best be gained from an analysis of the relevant reconstructions (compare Fig. 5*a, b* with Fig. 6*a*). A view of the endothelial lining of the heart and

components of the right side of the vascular system are illustrated in Fig. 6*d*. This Figure emphasises the dramatic changes that have taken place in the vascular

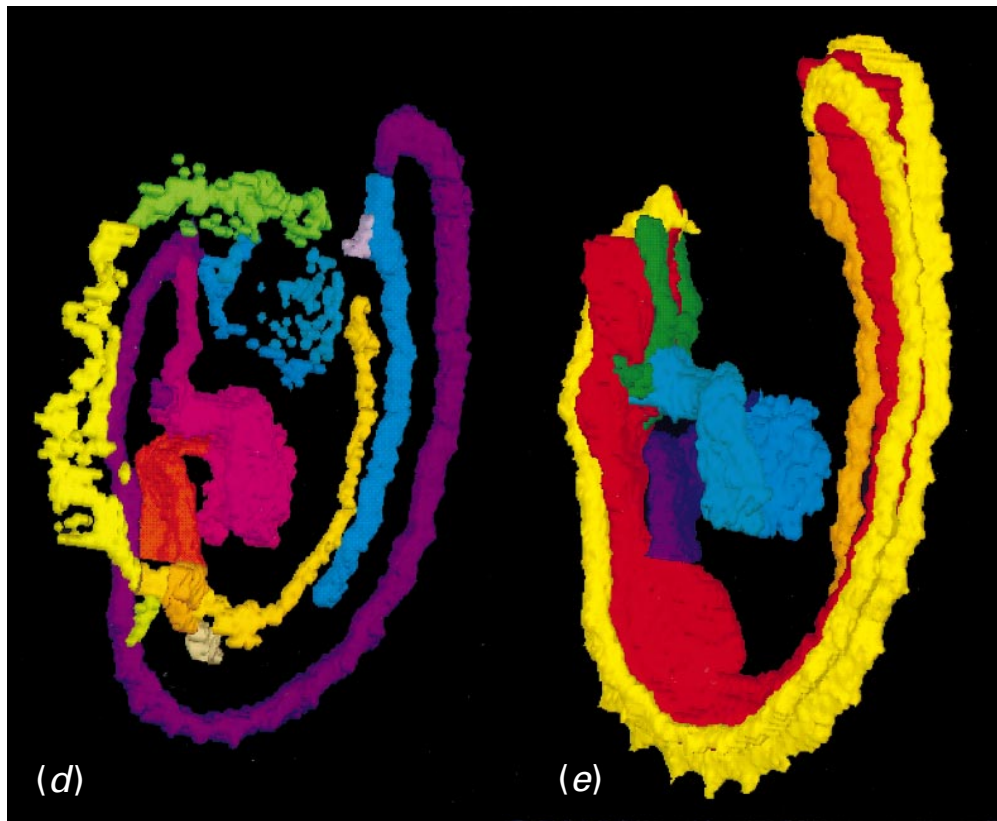


Fig. 6. Five views of reconstructions of the TS 14 stage embryo with about 17 pairs of somites. (a) Right lateral view of this embryo. Note that the first 14 somites are seen to be discrete entities, while the most caudal of the paraxial mesoderm has yet to form into discrete units. (b, c) Right lateral (b) and left lateral (c) views of the neuroepithelium and heart seen against a transparent image of the surface ectoderm; yellow, neuroepithelium; blue-mauve, common atrium; red, primitive ventricle; green, bulbus cordis and outflow tract of heart. (d) Endothelial lining of the heart and right components of the vascular system; same colour coding as for Figure c, d, with addition of blue-green for vessels connecting branches of internal carotid artery with primary head veins. Note that it is just possible to discern the proximal part (i.e. the origin) of the (incomplete) second arch artery. (e) Endothelial lining of the heart, outflow vessels, dorsal aortae and umbilical artery shown in relation to the endoderm of the gut; red, gut; mauve, common atrium; blue, primitive ventricle; blue-green, bulbus cordis and outflow tract; emerald green, 1st arch arteries; dark green, origin of the 2nd arch artery; yellow, dorsal aortae; orange, umbilical artery. Note the relationship between the 1st and 2nd arch arteries and the 1st branchial (pharyngeal) pouch and, caudal to this, the first indication of the 2nd branchial pouch. Note also the presence of the intersegmental arterial branches from the dorsal aortae, and how the dorsal aortae are related to the most caudal part of the hindgut.

system of this embryo when it is compared with the arrangement observed in embryos with 12 and about 8 pairs of somites (see Figs 5*d* and 4*d*, respectively).

A view of the reconstruction of the endothelial lining of the heart, the 1st and 2nd arch arteries, the dorsal aortae and vitelline artery in association with the gut provides another good example of the topological insight that can be gained from the analysis of 3-D reconstructions. While the 1st arch artery is located just rostral to the 1st pharyngeal pouch, the stump of the 2nd arch artery is seen to be closely related to its caudal boundary (see Fig. 6*e*).

A cursory examination of the reconstruction of the vascular system also demonstrates that it is possible to see the numerous intersegmental branches from the dorsal aortae, a feature that we had not expected to see from an analysis of the sections through this

embryo. A fuller account of this embryo is in preparation.

CONCLUSIONS

While it has not been possible in this review to highlight with the aid of appropriate illustrations all of the advantages to be gained from the analysis of 3-D reconstructions of early postimplantation mouse embryos prepared from previously serially sectioned material, it is hoped that the examples that have been selected will be adequate to justify the considerable effort taken on this exercise. Moreover, it is hoped that it will encourage others to utilise these representative embryos as aids to studying the histological and configurational complexities of these stages of development. In the near future it is planned

that all Theiler stages between fertilisation and E12.5, and in the longer term, all stages between fertilisation and birth, will be available for the use of the research community.

Unfortunately, what it has not been possible to emphasise here through the use of appropriate illustrations, is that the quality of the images seen on the screen by viewers is far superior to that which could be illustrated on the printed page. The character of the surface rendering of the reconstructions does not do justice to the resolution of our reconstructions. This is a limitation of computational power and only arises when viewing the 3-D images, and does not arise when browsing through the reconstructed histology with or without the painted overlays. Of even greater value is the fact that all images can be manipulated by the viewer so that they display the specific region or regions under investigation either in isolation or in combination with other tissues or organs. Equally, the reconstructions may be sectioned in any plane, or rotated and viewed in any orientation, in either 2-D, or stereo if appropriate glasses are available. The latter will, we believe, greatly facilitate the use of the methodology indicated here as a teaching aid for those wishing to study the complexities of gastrulation, neurulation, somitogenesis, and cardiovascular differentiation.

ACKNOWLEDGEMENTS

The images displayed in this paper were produced as part of the MAP which is the subject of a forthcoming paper. The authors wish to thank the other members of the MAP team for the early use of the data to illustrate the points raised here. In particular we thank J. B. L. Bard (Anatomy), C. Dubreuil, W. Hill, A. Ross and M. Stark (MRC Human Genetics Unit, Edinburgh) and members of the European Science Foundation workshops on the project. The financial support provided by the BBSRC, the MRC and the ESF is also gratefully acknowledged.

REFERENCES

- BALDOCK R, BARD J, KAUFMAN MH, DAVIDSON D (1992) A real mouse for your computer. *BioEssays* **14**, 501–502.
 BLECHSCHMIDT E (1963) *Der menschliche Embryo. Dokumentationen zur kinetischen Anatomie*. Stuttgart: Schattauer.

- DAVIDSON D, BALDOCK RA, BARD JBL, KAUFMAN MH, RICHARDSON JE, EPPIG JT et al. (1998) Gene-expression databases. In *In Situ Hybridization. A Practical Approach*. (ed. Wilkinson D). Oxford: IRL Press, in press.
 DOWNS KM, DAVIES T (1993) Staging of gastrulating mouse embryos by morphological landmarks in the dissecting microscope. *Development* **118**, 1255–1266.
 GASSER RF (1975) *Atlas of Human Embryos*. Hagerstown: Harper & Row.
 GUEST E, BALDOCK RA (1995) Automatic reconstruction of serial sections using the finite element method. *Bioimaging* **3**, 154–167.
 HAMILTON WJ, MOSSMAN HW (1972) *Hamilton, Boyd and Mossman's Human Embryology. Prenatal Development of Form and Function*, 4th edn. Cambridge: W. Heffer & Sons.
 HEBEL R, STROMBERG MW (1986) *Anatomy and Embryology of the Laboratory Rat*. Worthsee: BioMed Verlag.
 KAUFMAN MH (1990) Morphological stages of postimplantation embryonic development. In *Postimplantation Mammalian Embryos: A Practical Approach*. (ed. Copp AJ, Cockcroft DL), pp. 81–91. Oxford: IRL Press.
 KAUFMAN MH (1992) *The Atlas of Mouse Development*. London: Academic Press.
 KAUFMAN MH, BARD JBL (1998) *The Anatomical Basis of Mouse Development*. San Diego: Academic Press, in press.
 KAUFMAN MH, BRUNE RM, BALDOCK RA, BARD JBL, DAVIDSON D (1997) Computer-aided 3-D reconstruction of serially sectioned mouse embryos: its use in integrating anatomical organization. *International Journal of Developmental Biology* **41**, 223–233.
 KEIBEL F (1937) *Normentafel zur Entwicklungsgeschichte der Wanderratte (Rattus norvegicus Erxleben)*. Jena: Fischer.
 KEIBEL F, MALL FP (1910) *Manual of Human Embryology*, vol. 1. Philadelphia: JP Lippincott.
 KEIBEL F, MALL FP (1912) *Manual of Human Embryology*, vol. 2. Philadelphia: JP Lippincott.
 O'RAHILLY R, MÜLLER F (1987) *Developmental Stages in Human Embryos*. Carnegie Institute of Washington, Publication No. 637. Washington: Carnegie Institute.
 OTIS EM, BRENT R (1954) Equivalent ages in mouse and human embryos. *Anatomical Record* **120**, 33–64.
 RINGWALD M, BALDOCK R, BARD J, KAUFMAN MH, EPPIG JT, RICHARDSON JE et al. (1994) A database for mouse development. *Science* **265**, 2033–2034.
 RUGH R (1968) *The Mouse. Its Reproduction and Development*. Minneapolis: Burgess Publishing Company (reprinted 1990; Oxford: Oxford University Press).
 SNELL GD, STEVENS LC (1966) Early embryology. In *Biology of the Laboratory Mouse*, 2nd edn (ed. Green EL), pp. 205–245. New York: McGraw-Hill.
 STREETER GL (1942) Developmental horizons in human embryos. Description of age group XII, 21–29 somites. *Contributions to Embryology of the Carnegie Institute, Washington* **30**, 211–245.
 THEILER K (1972) *The House Mouse: Development and Normal Stages from Fertilization to 4 weeks of Age*. Berlin: Springer.
 THEILER K (1989) *The House Mouse: Atlas of Embryonic Development*. New York: Springer.
 WITSCHI E (1962) Development: rat. In *Growth Including Reproduction and Morphological Development* (ed. Altman PL, Dittmer DS), pp. 304–314. *Biological Handbooks of the Federation of American Societies for Experimental Biology*, Washington.