

Review

The anatomy of language: contributions from functional neuroimaging

CATHY J. PRICE

Wellcome Department of Cognitive Neurology, Institute of Neurology, London, UK

(Accepted 1 January 2000)

ABSTRACT

This article illustrates how functional neuroimaging can be used to test the validity of neurological and cognitive models of language. Three models of language are described: the 19th Century neurological model which describes both the anatomy and cognitive components of auditory and visual word processing, and 2 20th Century cognitive models that are not constrained by anatomy but emphasise 2 different routes to reading that are not present in the neurological model. A series of functional imaging studies are then presented which show that, as predicted by the 19th Century neurologists, auditory and visual word repetition engage the left posterior superior temporal and posterior inferior frontal cortices. More specifically, the roles Wernicke and Broca assigned to these regions lie respectively in the posterior superior temporal sulcus and the anterior insula. In addition, a region in the left posterior inferior temporal cortex is activated for word retrieval, thereby providing a second route to reading, as predicted by the 20th Century cognitive models. This region and its function may have been missed by the 19th Century neurologists because selective damage is rare. The angular gyrus, previously linked to the visual word form system, is shown to be part of a distributed semantic system that can be accessed by objects and faces as well as speech. Other components of the semantic system include several regions in the inferior and middle temporal lobes. From these functional imaging results, a new anatomically constrained model of word processing is proposed which reconciles the anatomical ambitions of the 19th Century neurologists and the cognitive finesse of the 20th Century cognitive models. The review focuses on single word processing and does not attempt to discuss how words are combined to generate sentences or how several languages are learned and interchanged. Progress in unravelling these and other related issues will depend on the integration of behavioural, computational and neurophysiological approaches, including neuroimaging.

Key words: Cerebral localisation; speech; aphasiology.

INTRODUCTION

Language is the mental faculty that we use to communicate. It involves the association of sounds and symbols with meaningful concepts and enables us to describe our external environment and abstract thoughts. The effective use of language requires the interaction of memory with sensory input and motor output systems. The principal types of memory required for language are phonological (the sounds of words), orthographic (the spellings of words) and semantic (our knowledge of the world). Sensory input

to these memories can be via auditory processing (for spoken words, environmental sounds and music), visual processing (for written words, objects, faces and sign), or tactile processing (braille). Motor output enables the expression of concepts via articulation, writing, signing or drawing; it can either be self generated (in response to internally generated thought) or stimulus driven (e.g. in response to written or heard words). This article considers how the functional anatomy of these diverse processes can be investigated with neuroimaging. It is divided into 5 sections. The first describes the neurological models of

language developed in the 19th Century by Broca, Wernicke and Lichtheim, the second the cognitive models devised by 20th Century psychologists, and the third how functional neuroimaging can potentially contribute to these models. The fourth section discusses the contributions of functional neuroimaging to date and the fifth attempts to relate the neuroimaging results to the cognitive and neurological models described in earlier sections.

1. THE 19TH CENTURY NEUROLOGICAL MODELS OF LANGUAGE

In 1861, Broca reported a postmortem study of a patient who had been impaired at articulating language. This patient had damage that encompassed the third frontal convolution in the left hemisphere. By deduction, the damaged area—later referred to as Broca's area—was associated with the motor images of speech. Similarly, Wernicke (1874) reported a postmortem study of a patient who had impaired speech comprehension. Damage was found in the left posterior superior temporal cortex and this region—later referred to as Wernicke's area—was associated with the auditory images of speech. Wernicke developed the model further to predict that if there was damage to the white matter tracts that connect Broca's and Wernicke's areas (the arcuate fasciculus), patients would have intact speech comprehension and production but a deficit repeating what was heard. This type of disconnection syndrome, referred to as 'conduction aphasia', was first reported by Lichtheim (1885). The upper panel of Figure 1 illustrates Broca's area, Wernicke's area and the arcuate fasciculus on a rendering of the left hemisphere of the brain. The anatomy of heard word repetition involves acoustic processing in the primary auditory cortex (PAC), connections to auditory images of speech in Wernicke's area, motor images of speech in Broca's area and speech generation in the motor cortex.

With respect to reading words, the first major contribution came from Dejerine (1891, 1892) who distinguished 2 main alexic syndromes: 'alexia with agraphia' and 'alexia without agraphia'. Alexia with agraphia described patients who had acquired a deficit in reading (alexia) and writing (agraphia) and this was associated with damage to the left angular gyrus. The left angular gyrus was therefore linked to memories of visual word forms. In contrast, alexia without agraphia (which is associated with lesions to the left occipital lobe and the splenium of the corpus callosum) was thought to arise from a disconnection of the left angular gyrus from the visual cortex (see

Repetition of Heard Speech

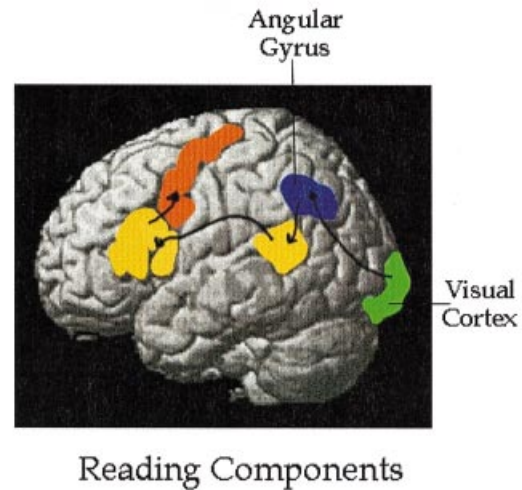
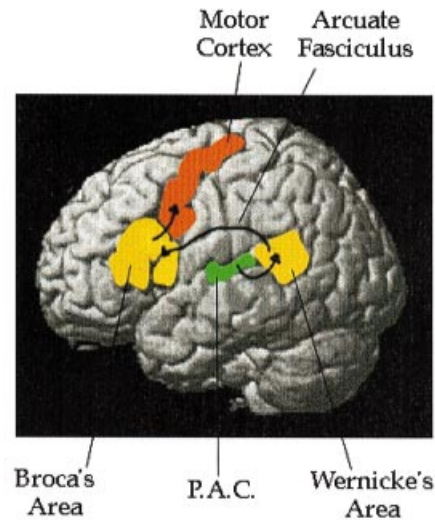


Fig. 1. The anatomy of the 19th century neurological model of language. The upper panel illustrates the anatomical location of the primary auditory cortex (PAC), Wernicke's area, the arcuate fasciculus, Broca's area and the motor cortex. The lower panel also includes the visual cortex and the angular gyrus for reading (see Geshwind, 1965).

Damasio & Damasio, 1983). The lower panel of Figure 1 illustrates how reading involves visual processing in the visual cortex and memory for visual word forms in the angular gyrus. Connections between the angular gyrus and Wernicke's area link visual word forms to the corresponding auditory word forms which can then be articulated as speech (see Geshwind, 1965). Figure 2 illustrates the cognitive components of this 19th Century neurological model.

One component seen in Figure 2, but not accounted for in Figure 1, is a 'concept centre' which holds the

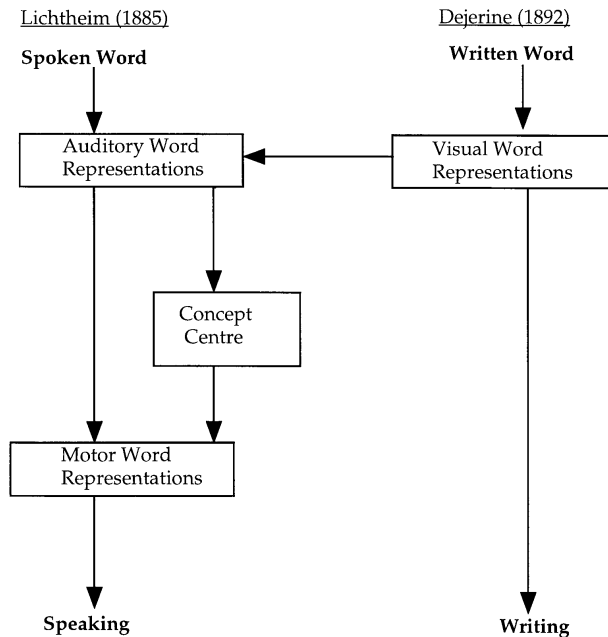


Fig. 2. The cognitive components of the 19th century neurological model. According to Lichtheim (1885), the sequence of cognitive events for spoken word processing involves access to 'auditory word representations' (in Wernicke's area), the concept centre (for the meaning of words) and motor word representations of speech (in Wernicke's area). For written word processing, access to visual word representations (in the angular gyrus) feeds into auditory word representations (in Wernicke's area; see Geschwind, 1965).

meaning of words. Comprehension deficits, involving both auditory and visual material, are typically associated with large left temporoparietal lesions that extend beyond the posterior superior temporal gyrus (Wernicke's area) and include the middle and inferior temporal lobe and the angular and supramarginal gyri in the left parietal lobe (Kertesz et al. 1982; Alexander et al. 1989; Hart & Gordon, 1990). For example, patients with transcortical sensory aphasia have a severe deficit in comprehension, with lesions distributed in the left inferior temporal lobe, the posterior, inferior parietal lobe (the junction of Brodmann's areas 39 and 19), the left thalamus and the white matter connecting these regions (Alexander et al. 1989). Thus language comprehension clearly involves areas outside the system specified in Figure 1.

The difficulty in interpreting these, and other lesion studies, relates to a lack of anatomical precision and the vagueness of the psychological constructs (see Shallice, 1990 for a review). For instance, neuropsychological profiles tend to be complicated, involving more than one cognitive deficit. The full extent of the cognitive deficit may also be obscured following compensatory strategies adopted by the patient to overcome the deficits (cognitive reorganisation) or changes in the functional anatomy (neuronal reorganisation). Likewise, pathological (as

opposed to experimental) lesions seldom conform to functionally homogenous neuroanatomical systems and some regions of the brain cannot be investigated because they are relatively immune to ischaemic damage (see Section 3). Another critical limitation is that it is impossible to distinguish whether the lost cognitive function is associated with the lesioned area or disconnection of undamaged areas. Indeed, all that can be concluded from a lesion deficit study is that the neuronal systems intrinsic to the lesioned area, or the connections passing through that area, were necessary for the lost function. One cannot say that the damaged region was either sufficient for, or uniquely identifiable with that function. As will be described later, functional neuroimaging studies on normal subjects provide the perfect compliment in that the neuronal systems sufficient for one task relative to another can be identified. However, the necessity for the different components cannot be established without recourse to lesion data. Thus functional neuroimaging identifies the complete set of regions for one task relative to another and the lesion deficit model identifies which of these regions (or connections) are necessary for a particular task component.

2. THE 20TH CENTURY COGNITIVE MODELS OF LANGUAGE

Because of the difficulties associated with the lesion deficit model, cognitive scientists over the past century have primarily emphasised the complexity of linguistic functions rather than focusing on their neurological underpinnings. Based on behavioural data alone, highly sophisticated models of language have been developed to describe the many different types of operation involved (e.g. McClelland & Rumelhart, 1981; Patterson & Shewell, 1987; Levelt, 1989; Seidenberg & McClelland, 1989). For instance, behavioural data from dyslexic patients suggest that there is more than one reading route. One type of dyslexic patient (referred to as surface dyslexics) retain the ability to read unknown words with no meaning (such as LONT) but fail to read irregularly spelled words (such as DEBT) while another type of dyslexia (referred to as phonological dyslexia) show the reverse dissociation. The obvious interpretation of this 'double dissociation' first described by Marshall & Newcombe (1973), is that the ability to generate the sound of a word from the component letters (sublexical reading) is functionally dissociable from the ability to read words with unique spelling patterns (e.g. YACHT). A deficit in the former results in

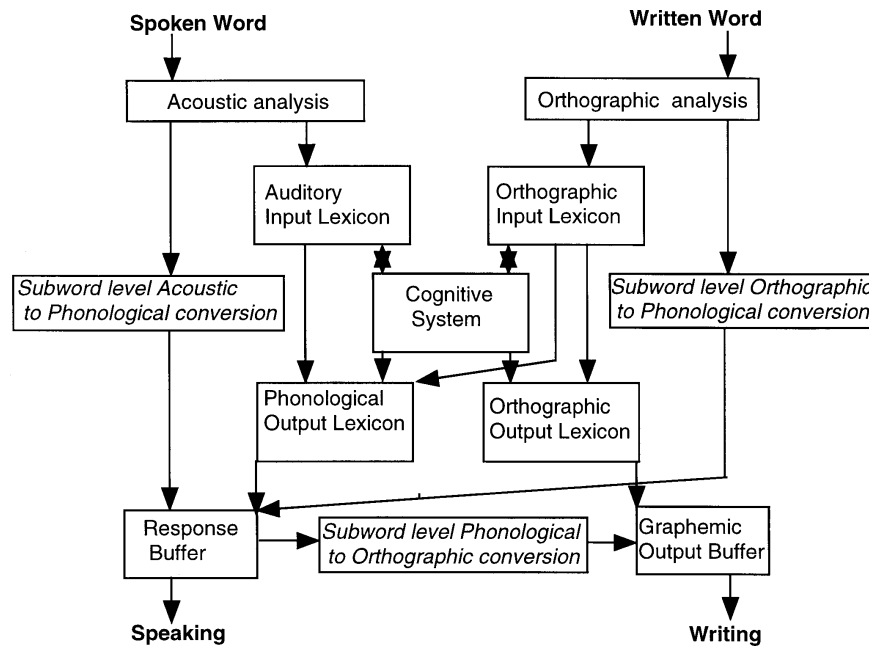


Fig. 3. A 20th century cognitive model of word processing. Cognitive model proposed by Patterson & Shewell (1987). The terminology is defined in the Table. The key components involve 4 distinct lexicons. The auditory input lexicon corresponds to the auditory images of speech. The orthographic input lexicon corresponds to the visual images of words. The auditory output lexicon corresponds to the motor images of speech. The orthographic output lexicon is not specified in the neurological model but specifies the motor images for writing. The cognitive system includes the concepts of words. Another important element of the model is that it incorporates more than one route for reading and speaking. For instance, words can either be read via orthographic analysis, the orthographic input lexicon and the phonological output lexicon or by direct links between orthographic analysis and a response buffer (sublexical level orthographic to phonological conversion).

phonological dyslexia and a deficit in the latter in surface dyslexia. These findings are not consistent with the neurological model depicted in Figures 1 and 2 which is clearly insufficient to account for the variety of neuropsychological cases that have been described.

In the last 2 decades, behavioural studies have decomposed the normal language system into many interacting subcomponents and devised information processing models comprised of boxes and arrows. A classic example is the word processing model proposed by Patterson & Shewell (1987), see Figure 3. The left side of the model describes the processing associated with heard and spoken speech and the right, the processing associated with reading and writing. A full description of the different components and how they interact is given in the figure legend and the Table.

Despite the apparent complexity of the model, it is restricted to single word processing and does not describe how different word types might be combined into sentences (Bock & Levelt, 1994; Bock, 1995) or how several different languages can be learnt and interchanged (Green, 1998). Box and arrow diagrams that attempt to incorporate these aspects of language would greatly increase the complexity. However, other types of cognitive model have shown that the same set of functions can be implemented by reducing the number of component parts and increasing the

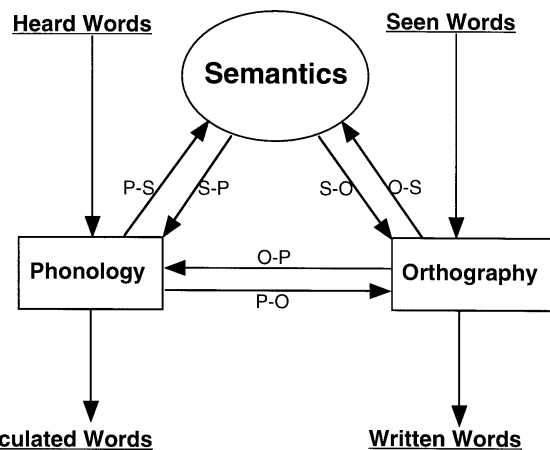


Fig. 4. A connectionist model of word processing. In this connectionist model adapted from Seidenberg & McClelland (1989), there are no separate input and output modules for phonology and orthography and the 4 input and output lexicons specified in Figure 3 are replaced by connections/interactions between phonology and semantics (P-S and S-P), semantics and orthography (O-S and S-O) and orthography and phonology (O-P and P-O). Retrieving the phonology (P) of seen words from orthography (O) can either occur via direct links (O-P) or indirectly via semantics (O-S, S-P).

interactions between them. These ‘connectionist’ or ‘parallel distributed processing’ models emphasise that a large number of functions can emerge from a system with a limited number of highly interactive components. An example of a connectionist model is depicted in Figure 4. In this model the function of the

Definitions

Phonemes are the range of vocal sounds we use for speaking.

Phonological processes are those involved in the perception or production of phonemes.

Graphemes are the visual symbols that depict one or more phonemes.

Orthography refers to the grapheme combinations that constitute the spellings of words.

Lexical processing refers to that concerned with whole words.

The *auditory input lexicon* stores the 'auditory images of words'.

The *orthographic input lexicon* stores the 'visual images of words'.

The *auditory output lexicon* stores the 'motor images for articulating words'.

The *orthographic output lexicon* stores the 'motor images for writing words'.

Semantic memory is our knowledge of the world.

Lexicosemantics concerns the conceptual meaning of words.

Sublexical processes concern those related to parts of words.

4 lexicons identified in Figure 3 is implemented by interactions between orthographic, phonological and semantic processes and there is no distinction between lexical and sublexical processing (the definitions of all these terms is given in the Table). Phonological dyslexia (a deficit for reading novel words) results from disruption of the connections between orthography and phonology (Plaut & Shallice, 1993) and surface dyslexia (the deficit reading irregularly spelled words) from a deficit in semantic processing (Plaut et al. 1996).

Despite the emphasis that connectionist models place on distributed rather than modular processing, they are still not constrained by neurophysiology. It is in this context that functional neuroimaging has the potential to redefine models of normal and abnormal language processing by providing appropriate neurological constraints. In particular it can assess whether there is a specialised neural system for a particular process or whether the implementation of that process is governed by patterns of distributed activity in neural systems that are shared by other functions.

3. THE POTENTIAL OF FUNCTIONAL NEUROIMAGING

The brain mechanisms underlying language remain largely unknown and until recently, the main source of data came from the association of a brain damaged site with a lost function, the lesion deficit model. In the last 10 y, functional neuroimaging has provided a new means for mapping the functional anatomy of language and the next decade should accelerate this endeavour. Functional imaging offers several fundamental advantages over the lesion deficit model. The most obvious is that brain activity can be observed, noninvasively, 'in vivo', in subjects who have normal psychological and physiological responses. In particular, functional imaging can identify functional specialisation in regions where naturally

occurring lesions are rare or where functionality is preserved following brain damage because of cognitive or neuronal reorganisation (see Section 1 above). The other major advantage is that, unlike the lesion deficit model, functional imaging is not limited to the region of the brain that has been damaged. Instead, the system of distributed cortical areas that sustain a particular sensory, motor or cognitive task can be identified. This systems level approach has several important implications for investigations both on normal subjects and on patients. First, unlike the lesion deficit model, it is not limited to the assumption that cognitive processes or operations are confined to discrete anatomical modules (functional segregation) but allows for functional specialisation which emerges from the interaction between 2 or more areas (functional integration). In relation to patient studies, the systems level approach enables the identification of the sites of abnormal function in the absence of structural damage (e.g. when undamaged regions are disconnected from a damaged region) and where there is normal function in the presence of structural damage (e.g. activation in or around a lesion).

The functional imaging studies reported below are based on data from 2 sources: positron emission tomography (PET) and functional magnetic resonance imaging (fMRI). Although there are some subtle differences between these techniques (PET measures blood flow, fMRI measures changes in deoxyhaemoglobin), they both measure neural activity by detecting the locally specific changes in blood composition and flow that accompany neural activity. In order to detect such changes, any functional imaging paradigm must include measurements from 2 or more brain states. The brain area associated with the cognitive process of interest (e.g. speech production) is identified by contrasting an 'activation' task (e.g. reading aloud) that engages the process of interest with a 'baseline' task that does not (e.g. reading silently). This method, referred to as 'subtraction

methodology', can be elaborated in several different ways. For example, using a hierarchical subtraction approach, the first functional imaging study of language, reported by Petersen et al. (1988), attempted to identify the brain regions associated with lexical and semantic processing by contrasting activity in a hierarchy of different states that included visual fixation, listening to words, repeating heard words and generating the meanings associated with heard words. The expectation engendered by this study was that the functional anatomy of all subtle word processes would be identified by finding baseline tasks that engaged all but the process of interest.

It did not, however, turn out to be as simple as this because there are 2 critical limitations of subtraction methodology with respect to language processing. The first is that the normal language system is very responsive to seeing and hearing word-like stimuli. As a result, even when subjects are not required to recognise or name a word or word-like stimulus, it is difficult to prevent extensive (implicit) word processing (see Macleod, 1991; Price et al. 1996*a*). This means that it is difficult to find 2 tasks that differ by only the process of interest. Activation differences will be diminished when the baseline task engages the process of interest to the same degree as the activation task. Conversely, activation differences will be superfluous to the process of interest when the activation task engages processes unrelated to task requirements. It is in this sense that it cannot be said that the regions identified for one task, relative to another, are necessary for task performance. It can only be said that the areas identified were sufficient for one task relative to another. Functional imaging thereby provides complementary information to that offered by lesion studies (which indicate the areas that are necessary for a task but not the full set of regions required, see Section 1).

The second limitation of subtraction methodology with respect to language is that, even when a particular process is thought to be equivalently engaged by the activation and baseline tasks, activation may vary with the demands of the task (see Friston et al. 1996). For instance, visual processing of seen words may increase when subjects are required to read words aloud relative to reading the same words silently even though the visual input is matched (Price et al. 1997*a*; Shulman et al. 1997). As a consequence of these task-dependent effects in nonlinguistic regions, the design and interpretation of functional imaging studies needs to consider the way that linguistic processes and memories interact with sensory input and motor output (see Introduction).

In summary, functional neuroimaging provides a means to reveal the neuronal systems underlying language processing and the extent to which functional specialisation depends on functional segregation and functional integration. Ultimately, the aim of such studies is to integrate cognitive models of language (see Section 2) with biological mechanisms. However, the methodology is not straightforward and at the beginning of the 21st Century, functional imaging studies are still attempting to answer the most elementary questions. For instance, which brain regions are involved in speech perception and production? How does the processing of spoken speech differ from the processing of written speech? How are the meanings of words represented? Since precise answers to these questions are still a matter of debate, the neuroanatomy of more complex linguistic functions such as sentence production and bilingualism, is well beyond the scope of this article and cannot be addressed usefully at this stage.

4. FUNCTIONAL IMAGING STUDIES OF AUDITORY AND VISUAL WORD PROCESSING

The data presented in this section attempt to test the validity of the 19th and 20th Century models of language illustrated in Figures 1 to 4. First, the full set of regions that comprise the neuronal systems associated with heard word repetition and reading are identified relative to rest (see Fig. 5). The top panel of Figure 5 illustrates the activation associated with heard word repetition relative to rest. The middle panel of Figure 5 illustrates the activation associated with reading aloud relative to rest. These figures can be directly contrasted with those in Figure 1 which illustrates the 19th Century neurological model. As can be seen, the functional imaging data and the neurological model are very consistent. Activation for repetition of heard speech relative to rest includes the primary auditory cortex, Wernicke's area, the posterior part of Broca's area (the pars opercularis) and ventral motor cortex. These regions are also engaged during reading, along with the predicted responses in the visual cortex. The primary auditory cortices are engaged during reading because when words are spoken aloud, subjects hear the sound of their own voice. This is demonstrated in the bottom panel of Figure 5 which shows activation of primary auditory cortices when subjects generate the sounds of seen words relative to articulating the same words silently. Thus far, the data appear to conform entirely to the predictions of the neurological model. However, there are some discrepancies, particularly between the

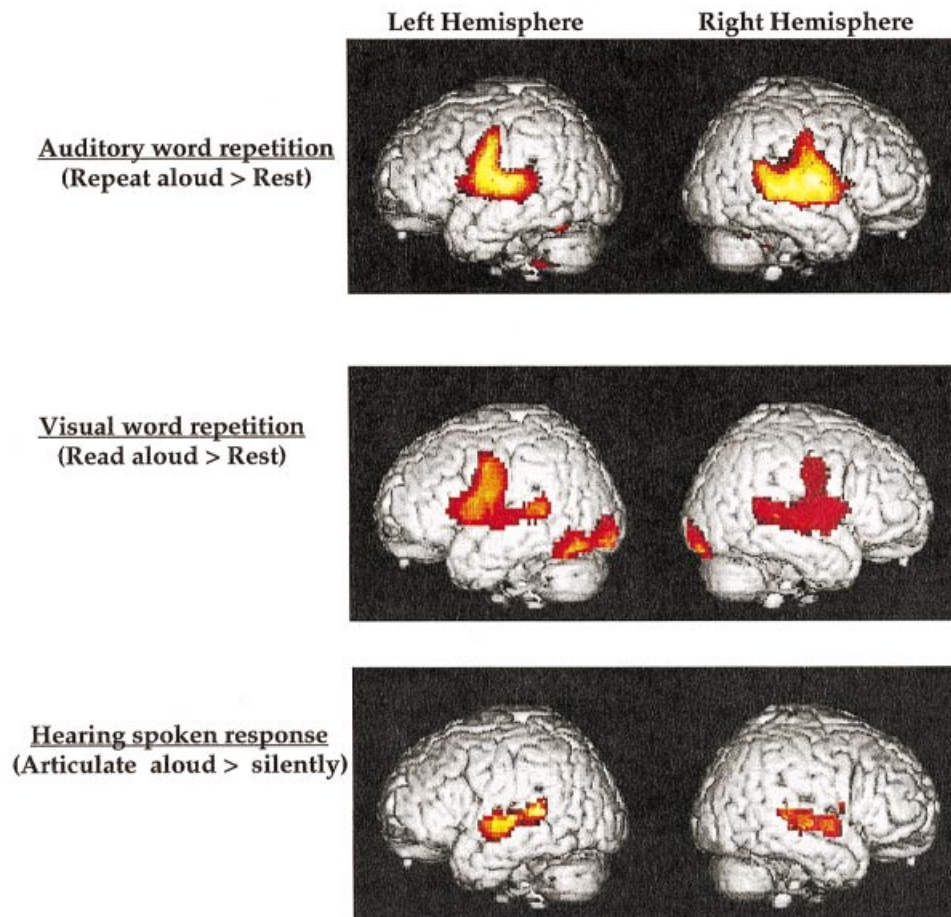


Fig. 5. The neural systems for auditory and visual word repetition. Brain areas activated (in red and yellow). At top: repeating heard words relative to rest (data from McCrory et al. 2000); middle: reading aloud relative to rest (data from Price et al. 1996*b*); and bottom: reading aloud relative to articulating the sounds of words without generating any sound (data from Price et al. 1996*c*).

reading data and the reading model. First, reading aloud relative to rest does not activate the angular gyrus but it does activate the left posterior inferior temporal cortex in the middle of the fusiform gyrus. Secondly, activation in Broca's area both during reading and heard word repetition was restricted to the pars opercularis with no detectable activity in the more anterior region (the pars triangularis). Thirdly, all 3 panels in Figure 5 clearly illustrate a bilateral rather than left lateralised language system. These inconsistencies with the neurological model must therefore be addressed with studies that attempt to dissociate specific roles for the component regions. Particular attention will be paid to the role of the left posterior inferior temporal cortex, the left angular gyrus and the anterior portion of Broca's area (the pars triangularis).

Heard word repetition (see Fig. 6)

The data illustrated in Figure 6 are presented to dissociate the functions of the diversity of regions

activated by repetition of heard speech. The top panel illustrates areas involved in *speech input* by contrasting activity during listening to words with activity during listening to nonspeech noise bursts (see Mummery et al. 1999). As expected from both lesion and imaging studies, activation can be seen in the anterior and posterior superior temporal gyri (including Heschl's gyri), the dorsal surface of the superior temporal gyri (the planum temporale), the superior temporal sulci and more ventrally in the middle temporal gyri. Heschl's gyrus and the planum temporale are the primary cortical projection areas of the ascending auditory pathway; the rest of the superior temporal gyri is also unimodal auditory association cortex (Creutzfeld et al. 1989). Isolated lesions to bilateral superior temporal gyri result in the syndrome of 'word deafness' (Buchman et al. 1986; Engelein et al. 1995). Such patients have normal language skills for speaking, reading and writing, can identify environmental sounds, but are unable to comprehend heard speech. In other words they have a speech specific perception deficit. One suggestion is that word

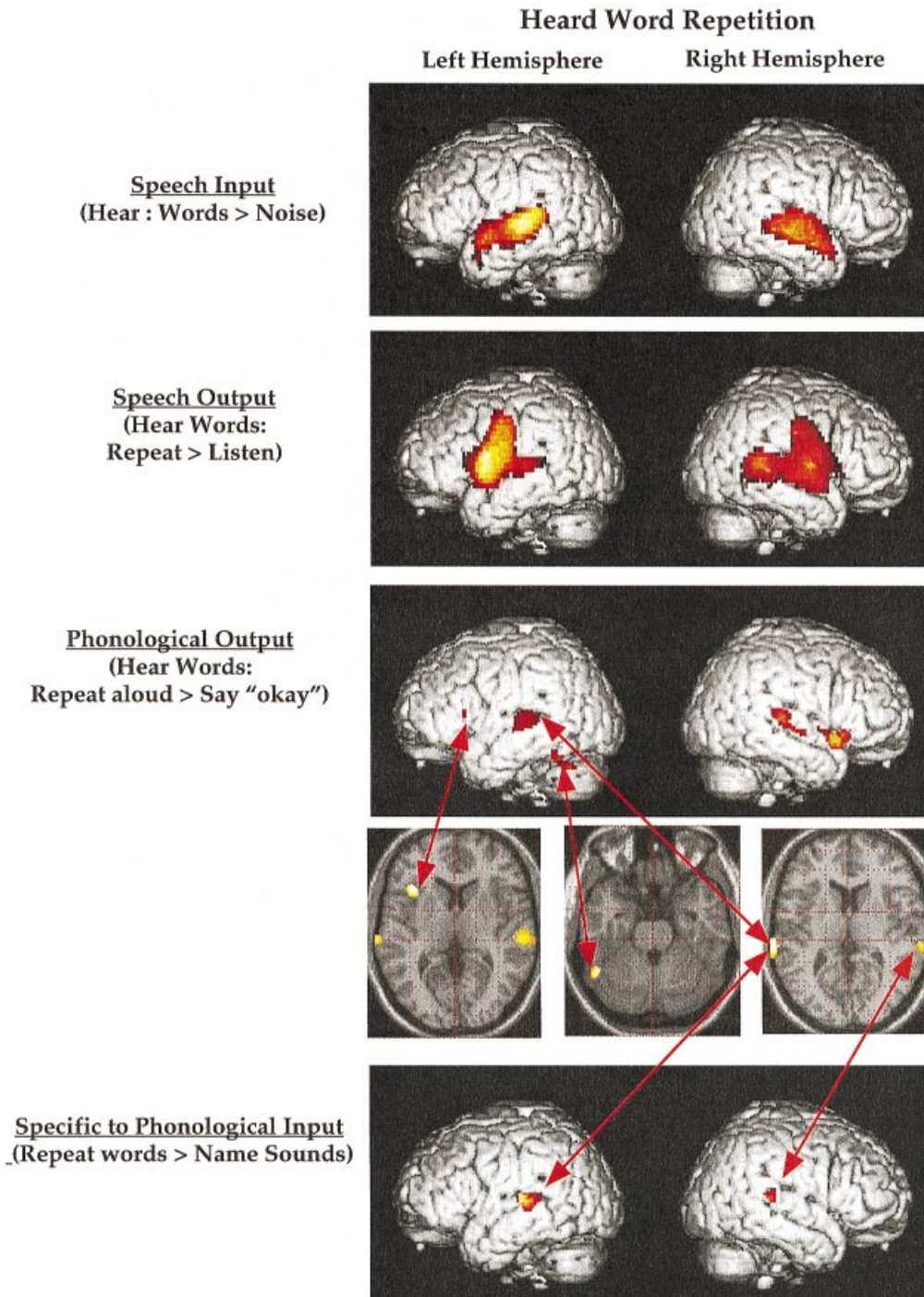


Fig. 6. The anatomical components of heard word repetition. Brain areas activated (in red and yellow). At top: listening to words relative to signal correlated noise equivalents (data from Mummery et al. 1999); second row: repeating words aloud relative to listening to words at the same rate (data from Price et al. 1996*b*); third row: repeating heard words aloud relative to listening to the same words and saying 'Okay' (data from A. L. Giraud & C. J. Price, unpublished); fourth row: transverse sections to show the precise anatomical location of the activation in the third and fifth rows; fifth row: repeating heard words aloud relative to naming environmental sounds after acoustic differences have been controlled (data from A. L. Giraud & C. J. Price, unpublished).

deafness results from an impairment in distinguishing rapid changes in auditory input as perception of speech is more reliant on these fine-tuned discriminations than environmental sounds (Auerbach et al. 1982). In contrast, the superior temporal sulci and middle temporal gyri, which are also activated for

speech, relative to noise bursts, contain polymodal areas that receive visual, somatosensory and auditory projections (Seltzer & Panya, 1994). These areas are likely to be the sites for higher order language functions (see below).

The second panel of Figure 6 illustrates the areas

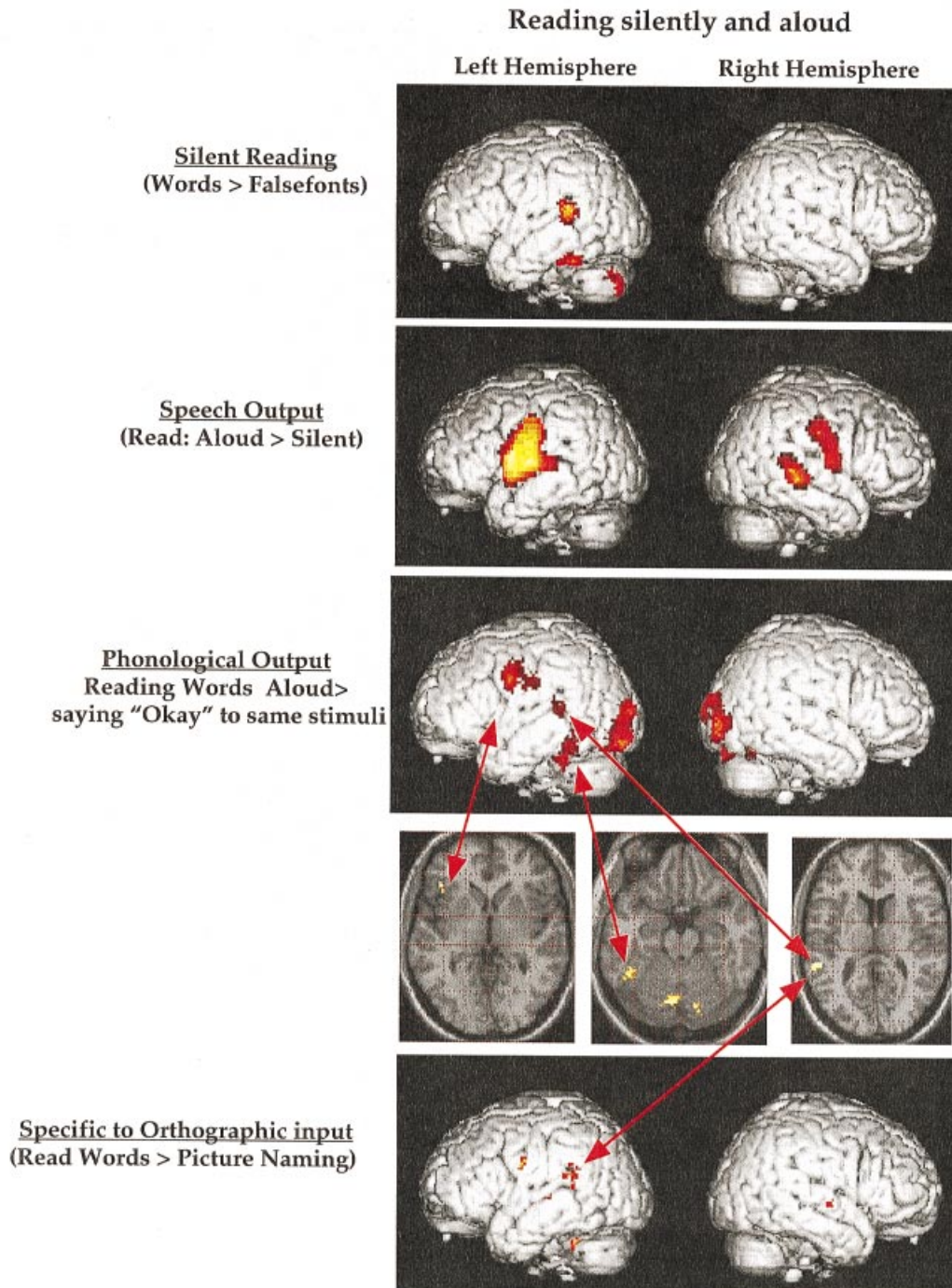


Fig. 7. The anatomical components of reading. Brain areas activated (in red and yellow). At top: viewing words silently relative to viewing falsefonts matched for visual complexity (data from Brunswick et al. 1999); second row: reading aloud relative to reading silently (data from Price et al. 1996b); third row: reading aloud relative to viewing the same words and saying 'Okay' (data from Moore & Price, 1999); fourth row: transverse sections to show the precise anatomical location of the activation in the third and fifth rows; fifth row: reading aloud relative to picture naming after visual differences have been controlled (data from Moore & Price, 1999).

involved in *speech output* by directly contrasting repetition of heard words with listening passively to the same words (see Price et al. 1996b). This comparison reveals activation in bilateral sylvian sensorimotor cortices which extends into the anterior superior temporal lobes and the left frontal operculum (the pars opercularis). Activity in the sensorimotor

cortices during articulation is associated with output to laryngeal, lingual and facial muscle but activation extends more than 20 mm above the intercommissural line, dorsal to the motor representations for lip, tongue and larynx. The observed activations may be related to the voluntary control of respiration (Ramsay et al. 1993), a necessary component of

articulation. Activation was also observed (but is not illustrated) in the supplementary motor area (SMA) and the cingulate gyrus. These areas are associated with the initiation of speech because lesions result in transcortical motor aphasia, i.e. impaired spontaneous speech production with preserved repetition (Damasio & Geschwind, 1984; Mesulam, 1990).

Finally, the right posterior superior temporal cortex is also activated for repetition of heard words relative to listening. The temporal activations may relate to retrieving the sounds of heard words (phonological output), hearing the sound of the spoken response (see third panel of Fig. 5) or changes in attention to auditory input when a response is required (Frost et al. 1998). These possibilities are addressed in the third panel of Figure 6 which contrasts heard word repetition with a task in which subjects hear the same words and articulate an arbitrary word ('Okay') to each presentation. The 'Okay' response was selected to partially control (1) attention to the words, (2) articulation, (3) speech generation and (4) hearing the sound of the spoken response. Even in this contrast, activation in bilateral primary auditory cortices illustrates that when the response is specified by the input (i.e. for repetition but not for saying 'Okay') auditory processing is enhanced and therefore the activation pattern is not specific to phonological retrieval. Nevertheless, the experiment successfully isolated activation in the left anterior insula (shown on the left of fourth panel in Fig. 6) from that in the surrounding motor and inferior frontal cortex. This is interesting because recent lesion (Dronkers, 1996) and neuroimaging (Wise et al. 1999) studies have emphasised that the critical speech production region in Broca's area is the anterior insula. More lateral and anterior lesions typically cause deficits in sentence comprehension and production, in particular the ability to generate word lists and assemble phonemes into words and words into sentences (Rubens, 1976; Damasio & Geschwind, 1984; Costello & Warrington, 1989; see the section on frontal activation below).

The third panel of Figure 6 also illustrates activation of the left posterior inferior temporal lobe on the border with the cerebellum (shown in the middle of the fourth panel in Fig. 6) for repetition relative to saying 'Okay' to the same words. Activation in this area has not previously been detected for repetition relative to rest (e.g. Price et al. 1996*b*; Wise et al. 1999; McCrory et al. 2000). Furthermore, repetition is not usually impaired following damage to the posterior inferior temporal lobe. However, the same area is activated by reading (Figs 5, 7) and it appears to be critical for picture naming and verbal fluency

(see below). It is possible, that it is implicitly activated during heard word repetition by virtue of direct connections from Wernicke's area (DiVirgilio & Clarke, 1997). Implicit activation in this context means that it was not necessary for task performance.

The bottom panel of Figure 6 illustrates a more precise characterisation of speech specific areas by contrasting heard word repetition with environmental sound naming. This was achieved by first identifying areas that were more active for (1) speech repetition relative to stimulus specific noise bursts (matched to the speech stimuli for duration, amplitude and mean frequency), and (2) environmental sound naming relative to noise bursts. In a second step, the sound-noise activation is subtracted from the speech-noise activation. This contrast controls for inevitable differences in the duration, amplitude and mean frequency of words and sounds and reveals speech specific areas in the upper bank of the left posterior superior temporal sulcus (the inferior part of Wernicke's area) and a homologous area in the right hemisphere. Although this is consistent with speech specific areas, A. L. Giraud, C. J. Price, J. M. Graham, & R. S. J. Frackowiak (unpublished) have demonstrated that the same superior temporal sulci regions are activated for naming environmental sounds in patients recovering their hearing with the aid of cochlear implants. Similarly, Belin et al. (2000) have reported identical activations for hearing human sounds (coughing, sneezing, etc.) relative to environmental sounds. Activation in this area is therefore not necessarily speech specific. The data suggest it may depend on attention to the input particularly when fine tuned auditory discriminations are required.

In summary, speech input activates bilateral superior and middle temporal cortices. Speech output enhances activation in the left posterior superior temporal sulcus and engages the left anterior insula and bilateral sensorimotor cortices. The left posterior inferior temporal cortex may also be involved.

Reading (see Fig. 7)

The layout of Figure 7 corresponds to that in Figure 6. In the top panel, the areas involved in silent reading are revealed relative to a baseline that controls for the visual features of letters. These are referred to as false fonts and look like this: $\alpha\sigma\kappa\eta\gamma\downarrow$. Three areas of significant activation can be seen: the left posterior inferior temporal cortex in the midfusiform gyrus (as identified in the middle panel of Fig. 5), the left posterior superior temporal cortex (Wernicke's area) and the cerebellum. It should be noted, however,

that the activation pattern detected for silent reading varies between studies, subjects, word type, word presentation rate and the duration over which words remain on the screen (see Price et al. 1994, 1996*c*; Bookheimer et al. 1995; Beauregard et al. 1997; Herbster et al. 1997; Price & Friston, 1997*a*; Rumsey et al. 1997; Brunswick et al. 1999; Moore & Price, 1999; Paulesu et al. 2000). For instance, in some studies, silent reading activates the angular gyrus (Bookheimer et al. 1995; Price et al. 1996*c*) particularly when the words make up sentences (Bottini et al. 1994; Bavalier et al. 1997; R. Vandenberghe et al. A. C. Nobre, C. J. Price, unpublished) but other silent reading studies using single words do not show angular gyrus activation (Beauregard et al. 1997; Herbster et al. 1997; Rumsey et al. 1997; Brunswick et al. 1999; Moore & Price, 1999). As will be discussed later, activation in the angular gyrus appears to be related to accessing semantics which may be more prominent when sentences are read (Bavalier et al. 1997) or when unrelated words are presented slowly (Price et al. 1996*c*).

The second panel of Figure 7 illustrates the areas involved in reading aloud relative to reading silently. The areas identified correspond exactly to those illustrated in the second panel of Figure 6 although the 2 studies were run independently with different groups of subjects. This confirms a common speech output system for repetition and reading as predicted by the Neurological and Cognitive models described in Figures 1–4. The third panel of Figure 7 illustrates activation for reading aloud relative to seeing the same stimuli and articulating ‘Okay’. As described in relation to the third panel of Figure 6, the ‘Okay’ response was selected to partially control (1) attention to the words, (2) articulation, (3) speech generation and (4) hearing the sound of the spoken response. Activation in the left posterior inferior temporal cortex, left anterior insula and left superior temporal sulcus corresponds almost exactly to those associated with phonological output in response to heard words. Transverse sections through these regions are shown in both Figures 6 and 7 and demonstrate the identical set of brain areas for reading and heard word repetition. The left posterior superior temporal cortex is illustrated again in the bottom panel of Figure 7 where it was found to be more active for reading aloud relative to picture naming. As can be seen, it extends into the parietal cortex (see also Bookheimer et al. 1995; Menard et al. 1996; Vandenberghe et al. 1996) and lies superior to the area associated with repeating words relative to sound naming (see bottom panel of Fig. 6). To evaluate the similarities and

differences between heard word repetition and reading a direct contrast is required. This will be addressed in the next section.

Reading relative to saying ‘Okay’ to the same stimuli also activated the lingual gyrus (medial extrastriate visual cortex) and areas associated with motor control (medial cerebellum and left precentral gyrus). The latter illustrates that the demands on articulation increase when words that correspond to the input are retrieved (reading) relative to when subjects say ‘Okay’ to each stimulus. This has also been observed for heard word repetition (Price et al. 1996*b*) but not in the study illustrated in Figure 6. Activation in the lingual gyrus is more controversial. One possibility is that activation in the lingual gyrus corresponds to activation in a visual word form area (Petersen et al. 1988, 1990). The word form account was based on lesion studies that showed that the left medial extrastriate area is damaged in alexia without agraphia (see Section 1 above). Other investigators, however, have challenged the association of the left medial extrastriate cortex with the visual word form system. For instance, Howard et al. (1992) found no differences in the striate or extrastriate cortex when reading aloud was contrasted to saying ‘Crime’ in response to strings of false fonts (although see Price et al. 1994, 1996*a*). Indefrey et al. (1997) demonstrated that activation changes in the visual cortex were related to the length or visual complexity of the stimulus (rather than lexicality); and Bookheimer et al. (1995) and Moore & Price (1999) reported activation in the lingual gyrus both for reading and object processing relative to visual controls but found no difference when reading was contrasted with object processing. Clearly then, activation in the lingual gyrus is not specific to words.

An alternative to the word form hypothesis is that the left medial lingual gyrus is involved in some aspect of visual processing that is enhanced when subjects are required to make a stimulus specific response such as naming (Shulman et al. 1997; Price et al. 1997*a*). This explanation gains some support from a functional imaging study by Fink et al. (1996) that employed the Navon task (Navon 1977). The study of Fink et al. involved the presentation of hierarchically organised letters (global letters composed of local letters) and a requirement to attend to the identity either of the local or the global parts. Activation increased in the medial lingual gyrus when attention was directed to the global parts, and in bilateral fusiform gyri when attention was directed to the local parts. Since the visual input remained the same, irrespective of task, the study of Fink et al. suggested

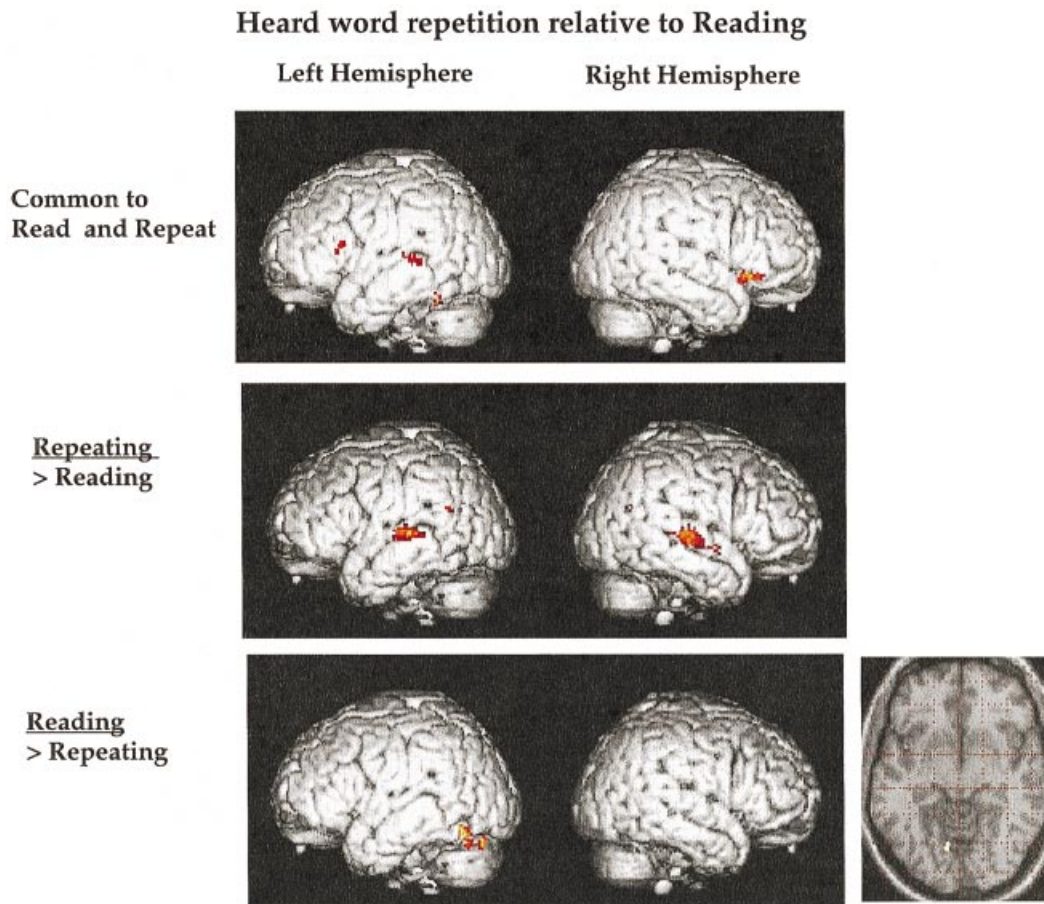


Fig. 8. Similarities and differences between the anatomy of reading and repetition. Brain areas activated (in red and yellow). At top: repeating heard words aloud relative to listening to the same words and saying 'Okay' (data from A. L. Giraud & C. J. Price, unpublished) and also reading aloud relative to viewing the same words and saying 'Okay' (data from Moore & Price, 1999); second row: areas more active for repeating; third row: areas more active for reading by contrasting data from Moore & Price, (1999) with A. L. Giraud & C. J. Price (unpublished) using standard methodology.

that the bilateral fusiform gyrus was concerned with local feature processing and the medial lingual gyrus was concerned with global processing. If these results are applied to those depicted in the third panel of Figure 7, we might deduce that subjects attend more to the global shape of words (or objects) when a naming response is required.

In summary, reading words activates the same set of regions as heard word repetition but written words also engage the visual cortex.

Similarities and differences between reading and heard word repetition (Fig. 8)

To examine the similarities and differences between auditory and visual word repetition, the data illustrated in the third panel of both Figures 6 and 7 are combined together in Figure 8. The top panel illustrates similarities in activation for heard word repetition (relative to saying 'Okay' to auditory noise bursts) and reading aloud (relative to saying 'Okay'

to falsefonts). As predicted from Figures 6 and 7, common activation is identified in the left posterior inferior temporal cortex and the left posterior superior temporal sulcus (Wernicke's area). It therefore appears that auditory and written word input can engage both areas. However, the spatial resolution of the functional imaging data does not allow us to exclude the possibility that within the shared regions there is specialisation for auditory and visual word processing. The activation for reading relative to object naming extends 8 mm superior to activation for repetition relative to naming environmental sounds and 8 mm is not within the spatial resolution of the PET methodology used. Furthermore, although the superior temporal sulcus is a multisensory area it is comprised of unimodal patches from different sensory modalities (Seltzer et al. 1996) that would not be differentiated either by PET or fMRI.

What then are the differences between repetition and reading once sensory input has been controlled? The second panel of Figure 8 illustrates activation for

heard word repetition relative to reading. Consistent with the neurological model, bilateral auditory cortex is demonstrated including Wernicke's area. Although sensory input was controlled (by comparing words to noise bursts), the increased activation for heard word repetition relative to reading includes primary auditory areas. This is because auditory activation increases when stimulus specific phonology must be articulated (see above). Just as Wernicke's area is more active for heard word repetition, the left posterior inferior temporal area is more active for reading (see third panel of Fig. 8). In addition, stimulus-specific phonological responses for reading activated a region of the left medial extrastriate visual cortex (see inset on right of third panel in Fig. 8) that is also observed for object naming but not heard word repetition. In the previous section this area was associated with increased visual processing when a stimulus specific response was required.

In summary, the data presented in Figure 8 indicate that although Wernicke's area and the left posterior inferior temporal cortex can be activated both by reading and heard word repetition, Wernicke's area is more active for heard word repetition and the left posterior inferior temporal cortex is more active for reading. In addition, heard word repetition increases the demands on bilateral primary auditory cortex whereas reading increases the demands on medial extrastriate visual cortex.

Wernicke's area and the left posterior inferior temporal cortex (see Figs 8, 9)

The previous sections have demonstrated that the left posterior superior temporal sulcus (Wernicke's area) and the left posterior inferior temporal cortex can be activated both by heard word repetition and reading. This section discusses their possible functions. The first point (as mentioned previously) is that while Wernicke's area is consistently activated by heard word repetition, it is not consistently activated by reading (see above). Conversely, while the left posterior inferior temporal lobe is almost always activated by reading, it is not always activated by heard word repetition. This relates to the second point: functional imaging data identify the distributed set of regions for a task but do not inform us which areas are necessary for task performance. For this we must consider the lesion data.

Lesions to Wernicke's area do indeed result in impaired reading and repetition (Wernicke, 1874) but not when the lesion is limited to the superior temporal gyrus. The multimodal areas that respond to auditory

and visual stimuli are in the superior temporal sulci and the middle temporal gyri (Seltzer & Panya, 1994). Lesions that selectively take out the left posterior inferior temporal cortex are much rarer because the blood supply to the region comes from both the posterior and middle cerebral arteries thereby protecting it from profound ischaemic damage. This could possibly explain why the left posterior inferior temporal area was missed by the 19th Century neurologists. Consequently, on the basis of primate studies, the posterior inferior temporal cortex has traditionally been associated with visual object processing. Recent lesion, electrophysiological and neuroimaging studies have been more enlightening. For instance, the linguistic role of the inferior temporal cortex was first noted in electrical stimulation studies (see Luders et al. 1986; Burnstine et al. 1990) and the surrounding area was referred to as the 'basal temporal language area'. Second, the left posterior inferior temporal cortex is associated with a range of word retrieval tasks in neuroimaging, irrespective of stimulus modality. This is illustrated in Figure 9 which identifies the left posterior inferior temporal cortex and the left anterior insula/frontal operculum as word retrieval areas irrespective of stimulus modality. Third, 2 recent lesion studies have associated damage to a discrete region of the left posterior inferior temporal cortex with anomia in the absence of impaired object recognition, semantic impairment or heard word repetition (Raymer et al. 1997; Foundas et al. 1998). Lesion studies therefore indicate a necessary role for the left posterior inferior temporal cortex in word retrieval but not in repetition and a necessary role for Wernicke's areas in both reading and heard word repetition.

The absence of the left posterior inferior temporal cortex from the 19th Century neurological model (see Fig. 1) may underlie the criticism that the model was unable to explain why phonological dyslexics are able to read familiar words but not new words and surface dyslexics have the reverse dissociation (see Section 2 above). When the left posterior inferior temporal cortex is included in the neurological model, then 2 routes to reading are provided: one that links visual input via Wernicke's area to the frontal operculum and one that links visual input via the left inferior temporal lobe to the frontal operculum. Indeed, this proposal concurs with the dissociation of lesion sites reported for surface and phonological dyslexia: surface dyslexia is associated with left inferior temporal lesions (Vanier & Caplan, 1985) and phonological dyslexia is associated with more superior lesions which extend into the supramarginal gyrus

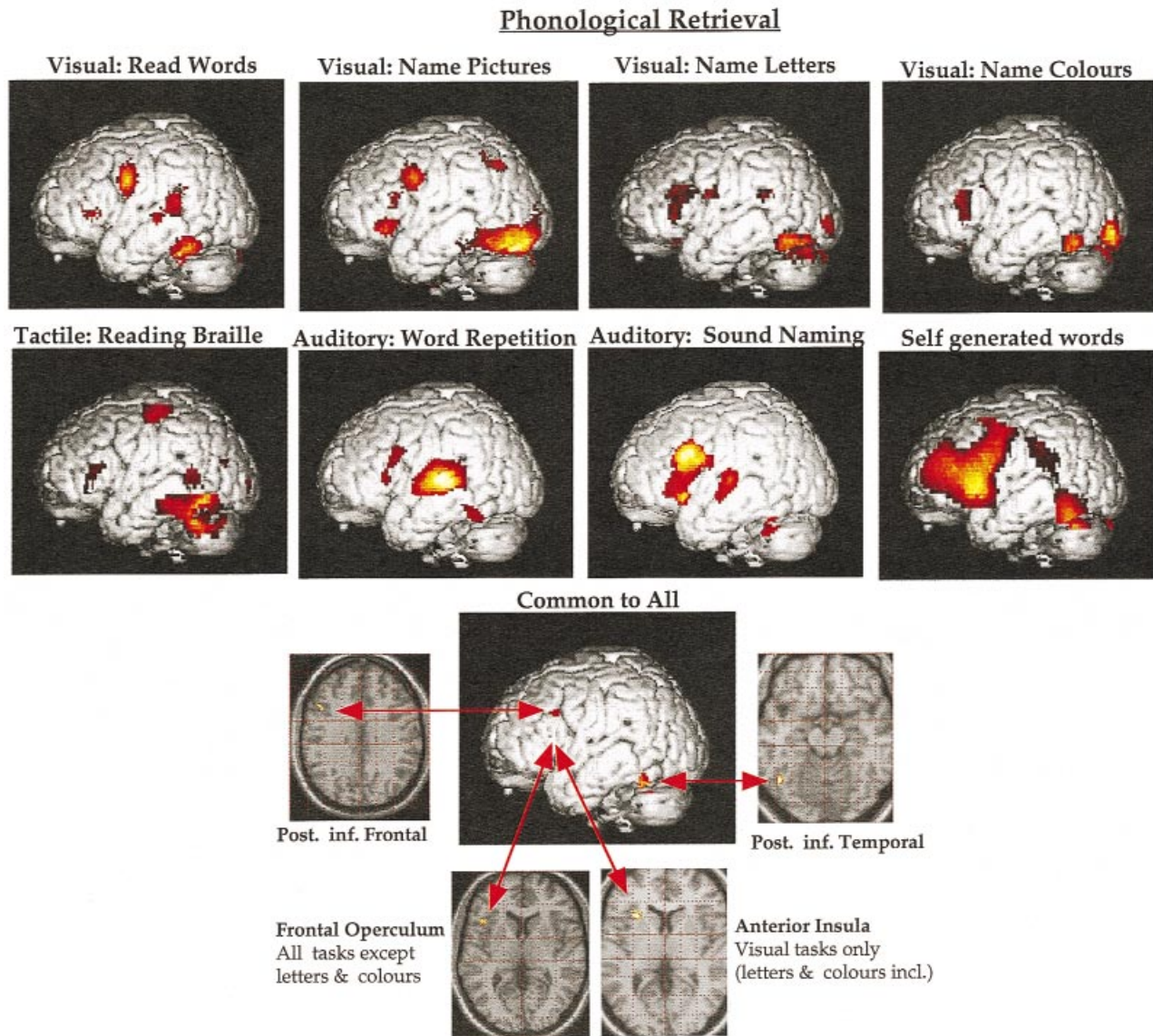


Fig. 9. Modality independent word retrieval. Areas of the brain that activate during name retrieval are illustrated in red and yellow on renderings of the left side of the brain only. Top row: naming visual words (reading) contrasted with viewing strings of falsefont and saying 'Okay' (data from Moore & Price, 1999), naming visual pictures contrasted with viewing nonsense figures and saying 'Okay' (data from Moore & Price, 1999); naming visual letters contrasted with viewing single falsefont and saying 'Yes'; and naming the colour of meaningless shapes contrasted with viewing the same coloured shapes and saying 'Okay' (data from Price & Friston, 1997*b*); second row: naming tactile words (reading braille) contrasted with feeling consonant letter strings in braille (data from Buechel et al. 1998); auditory word repetition and environmental sound naming contrasted to hearing signal correlated noise and saying 'Okay' (data from A. L. Giraud & C. J. Price unpublished); self generated words related to auditorily presented letters (e.g. hear 'H' say 'House') contrasted with auditory repetition of the same letters (data from Frith et al. 1991*a*). Third and fourth rows: areas common to all studies illustrated; these include the posterior inferior temporal cortex in the fusiform gyrus, the posterior inferior frontal cortex, the frontal operculum (for all tasks except letter and colour naming) and the anterior insula for the visual tasks only.

(Marin, 1980). The function of the left inferior temporal cortex is therefore consistent with the semantic route to reading and the function of the left posterior superior temporal cortex is consistent with a nonsemantic route to reading.

For functional neuroimaging studies to distinguish the different roles of the posterior superior temporal sulci and the left posterior inferior temporal region, a

comparison between familiar and novel words might be considered. The first prediction is that familiar words will activate the semantic reading route and novel words (e.g. 'LONT') will activate the non-semantic reading route. However, the results of such studies have been very inconsistent. More activation for novel words than familiar words has been reported in the left inferior frontal cortex (Fiez et al. 1993;

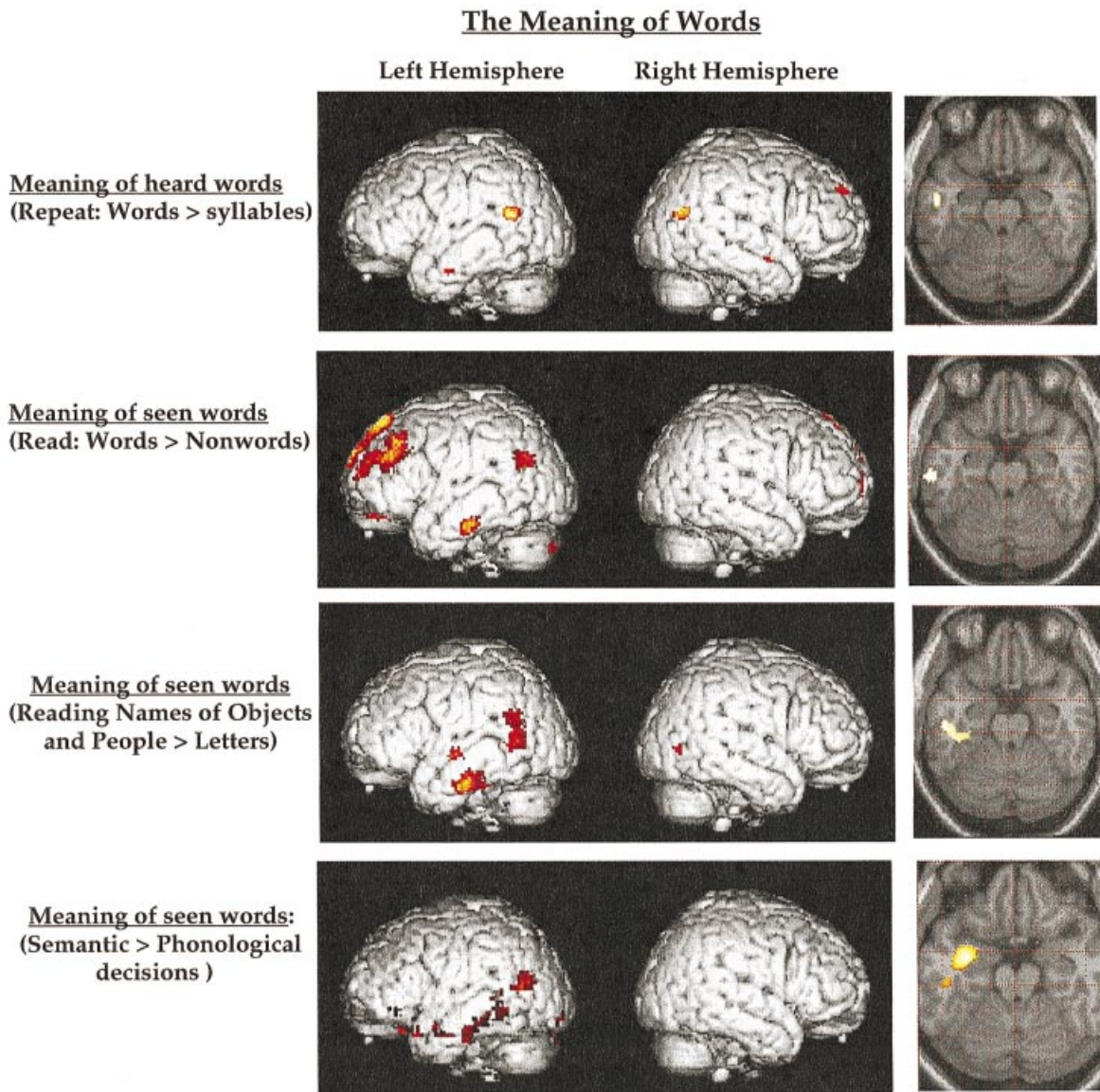


Fig. 10. The meaning of words. Areas of the brain that activate when the meaning of words is available are illustrated in red and yellow on renderings of the left and right side of the brain. Top row: repeating words relative to repeating meaningless syllables (e.g. tatata); data from A. L. Giraud and C. J. Price (unpublished). Second row: reading aloud real words relative to reading meaningless pseudowords (e.g. LONT); data from Brunswick et al. (1999). Third row: reading the names of famous people (e.g. 'MARILYN MONROE') and objects (e.g. 'WHEEL BARROW') relative to strings of consonant strings ('MNRTRBNMTTRW'); data from Gorno-Tempini et al. (1998). Fourth row: semantic decisions (is it a living item?) on written words (e.g. 'TABLE' or 'PIG') relative to syllable decisions (does it have 2 syllables?) on the same words; data from Price et al. (1997*b*). On the right of each row, a transverse slice 20 mm below the intercommisural line illustrates the precise locations of the anterior inferior temporal activations.

Price et al. 1996*a*; Herbster et al. 1997; Fiez & Petersen, 1998; Brunswick et al. 1999; Paulesu et al. 2000), left superior temporal cortex (Price et al. 1996*a*; Rumsey et al. 1997; Brunswick et al. 1999; Paulesu et al. 2000) and left middle fusiform/posterior inferior temporal lobe (Price et al. 1996*a*; Brunswick et al. 1999; Paulesu et al. 2000). Increased activation for familiar relative to novel words has only been reported by Herbster et al. (1997) in the same midfusiform region that was more active for novel words in the studies by Price et al. (1996*a*); Brunswick

et al. (1999) and Paulesu et al. (2000). Overall, it appears that novel words tend to tax both the semantic and nonsemantic systems more than familiar words, perhaps because the semantic system attempts to find a meaning to the novel words and the nonsemantic route attempts to assimilate the sounds (see Price et al. 1996*a*).

Nevertheless, 2 lines of functional imaging evidence support the implication from lesion data that novel words might be more dependent on the superior temporal cortex (Wernicke's area) than the left

posterior inferior temporal lobe. The first is that it is Wernicke's area that is more active for reading than picture naming (see bottom panel of Fig. 7) whereas the left posterior inferior temporal lobe is activated both by reading and picture naming (Bookheimer et al. 1995; Moore & Price, 1999, Murtha et al. 1997; see also Fig. 9). The critical distinction here is that picture naming can only proceed following access to semantics, whereas reading can also proceed in the absence of semantics (e.g. for reading novel words such as 'Dobocodoo'). Therefore, the role of the left posterior inferior temporal area is more consistent with the semantic route to naming. The other line of evidence is that Wernicke's area is more active when Italian speakers read Italian than when English speakers read English (Paulesu et al. 2000). The critical distinction here is that the relationship between orthography and phonology is consistent in Italian but inconsistent in English. This means that direct translation from orthography to phonology is more reliable in Italian thereby biasing Italians to engage Wernicke's area more than English readers.

In summary, both reading and repetition activate the posterior superior temporal sulci and the left posterior inferior temporal lobe relative to conditions that attempt to control for sensory input and motor output. Activation in the left posterior inferior temporal lobe is not always activated during repetition, appears to be involved in retrieving phonology irrespective of stimulus modality and is usually accompanied by activation in the left frontal operculum/anterior insula (see Fig. 9). It may correspond to a semantic word retrieval route predicted by the 20th Century cognitive models but it is not consistent with the predictions of the 19th Century neurologists. Conversely, activation in the left posterior superior temporal sulcus (Wernicke's area) for both tasks is consistent with the 19th Century neurological model and may correspond to the nonsemantic word retrieval route hypothesised by the 20th Century cognitive models. Neuroimaging studies show that the left posterior superior temporal sulcus (Wernicke's area) is always engaged by heard word repetition but not always engaged by reading.

Accessing semantics (Figs 10, 11)

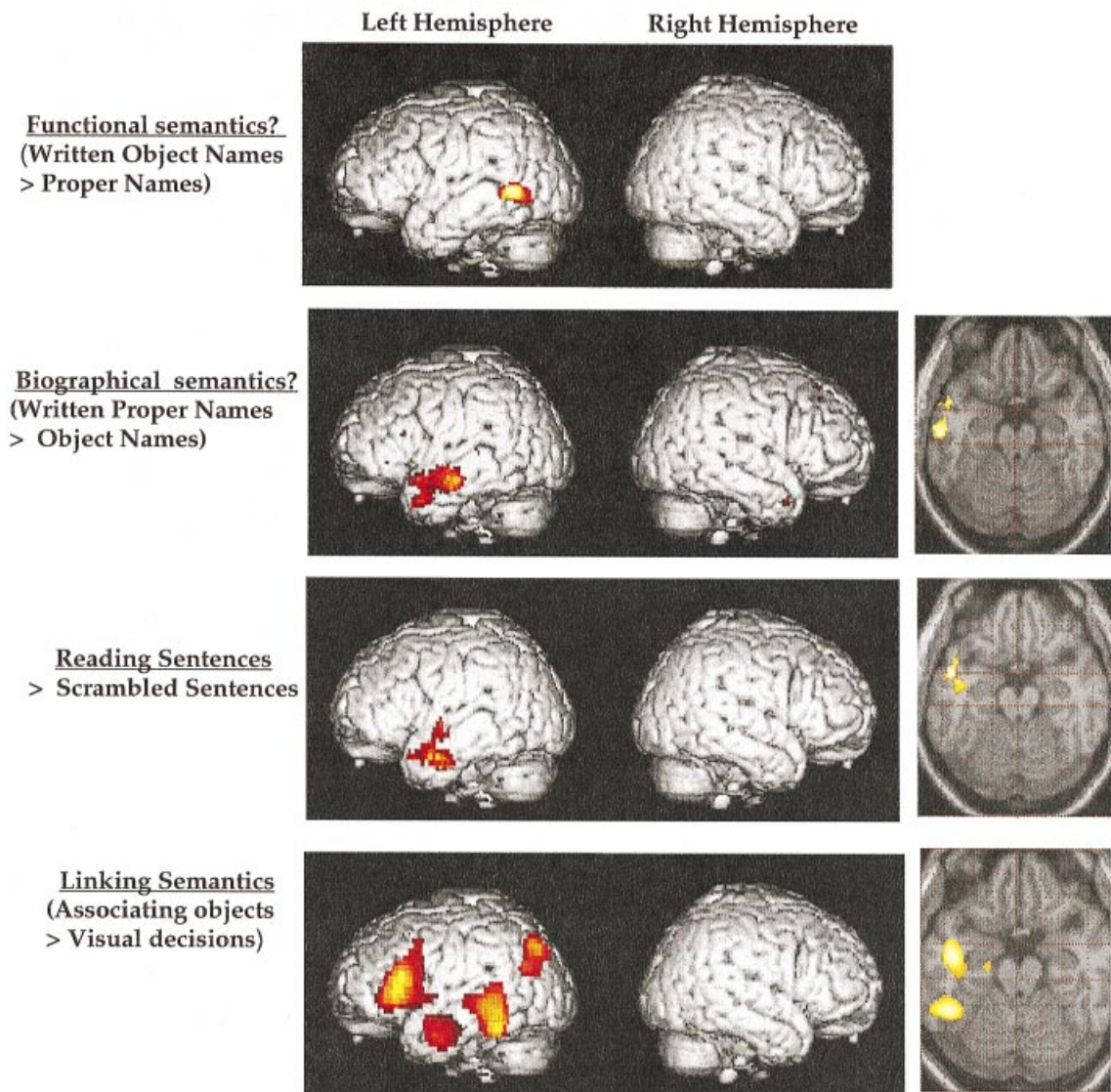
So far, this article has focused entirely on the neural systems for auditory and visual word repetition and only touched briefly on the systems underlying meaning and recognition. In this section, data will be presented to illustrate a regionally distributed sem-

antic memory system that includes a number of extrasylvian temporal and parietal regions including the left angular gyrus. One of questions that was raised in the discussion of Figure 5 related to the absence of activation in the left angular gyrus during reading. Although the angular gyrus is not activated when unrelated words are read aloud relative to rest, it is observed during sentence reading (Bavaliere et al. 1997), when unrelated words are read silently at a slow rate (Price et al. 1996c) and when the meaning of words is accessed. Figures 10 and 11 show that the posterior inferior left parietal lobe, including the angular gyrus, is involved in semantic processing. The top panel of Figure 10 illustrates the areas that are more active for heard word repetition relative to repetition of meaningless syllables. Activation can be seen in bilateral posterior temporoparietal regions and the left anterior inferior temporal lobe. These areas have been associated with semantic processing in numerous visual and auditory studies (Demonet et al. 1992, 1994a; Gorno-Tempini et al. 1998; Mumery et al. 1998). Panels 2–4 in Figure 10 show that the left posterior temporoparietal junction and the left anterior inferior temporal lobe can also be more active for reading words relative to novel words (second panel), for reading the names of objects and famous people relative to letters (third panel of Fig. 10) and when subjects read the names of objects, animals and fruits in order to make semantic decisions (living or nonliving?) relative to phonological decisions (2 syllables or not?): see bottom panel of Fig. 10.

The hypothesis that semantic processing occurs in the angular gyrus and the anterior inferior temporal lobes is supported both by lesion and electrophysiological studies. Patients with damage to the left angular gyrus have deficits with both written and spoken word comprehension (Dejerine, 1892; Geschwind, 1965; Hart & Gordon, 1990). Patients with atrophy in the left anterior and inferior temporal cortices have profound loss of semantic knowledge (Hodges et al. 1992). Likewise, patients with transcortical sensory aphasia have a severe deficit in comprehension, with lesions distributed in the left inferior temporal lobe, the posterior inferior parietal lobe (the junction of Brodmann's areas 39 and 19), the left thalamus and the white matter connecting these regions (Alexander et al. 1989). Cortical and intracortical recording studies also associate semantic processing with the left anterior temporal lobe (Nobre et al. 1995) and left parietal cortex (Connolly et al. 1994).

Although the studies illustrated in Figure 10 show consistency in the occurrence of activation of the left

Accessing different types of Semantics



Summary of activations in the Inferior Temporal lobe

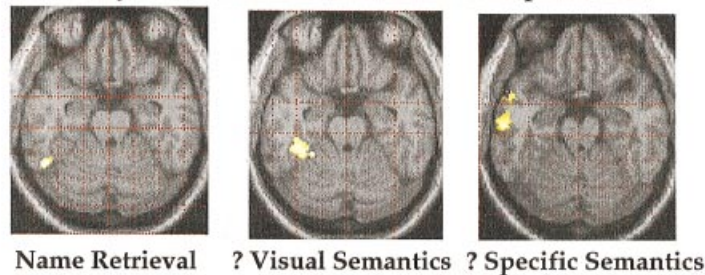


Fig. 11. Accessing different types of semantics. Areas of the brain more active for (top row) reading the names of objects relative to the names of famous people (data from Gorno-Tempini et al. 2000); second row: reading the names of famous people relative to objects (data from Gorno-Tempini et al. 1998); third row: reading sentences relative to the same list of words scrambled into a random order (data from R. Vandenberghe, A. C. Nobre, C. J. Price, unpublished); fourth row: associating a target word with 1 of 2 choices on the basis of meaning relative to physical size on the screen (data from Vandenberghe et al. 1996). On the right of each row, a transverse slice 20 mm below the intercommisural line illustrates the precise locations of the inferior temporal activations. Fifth row: transverse slices 20 mm below the intercommisural line to illustrate the relative locations of different areas in the inferior temporal lobe (data from Moore & Price, 1999 and Gorno-Tempini et al. 1998).

posterior temporoparietal junction and the left anterior inferior temporal lobe, the precise location of these activations varies slightly between studies and subjects (see right column of Fig. 10). One explanation for this variance is that there are anatomically segregated areas specialised for accessing different types of semantic attribute (Warrington & Shallice, 1984; Warrington & McCarthy, 1987, 1994; Martin et al. 1995, 1996; Damasio et al. 1996). This is considered in Figure 11. The top panel shows an area in the left posterior middle temporal lobe that is more active for reading the names of objects and body parts than the names of famous people. Activation in this area also increases when the actions associated with objects must be retrieved (Martin et al. 1995; Phillips et al. 1999). One possibility then is that when objects and body parts are named, associated actions are more likely to be retrieved implicitly than when famous people are named (Warrington & Shallice, 1975; Farah & McClelland, 1991; Martin et al. 1996). Conversely, the second panel of Figure 11 shows an area in the anterior inferior temporal cortex that is more active for reading the names of famous people than the names of objects. The underlying function of this region remains unclear. For instance, although in 3 experiments it has been shown to be more active for famous faces than everyday objects (Gorno-Tempini et al. 1998, 2000), it is also more active for reading grammatical sentences than when the order of the same words is scrambled (compare the second and third panels of Fig. 11). Similarly, the anterior temporal cortex is more active for reading sentences relative to unrelated words (Mazoyer et al. 1993; Bottini et al. 1995) and reading stories relative to unrelated sentences (Fletcher et al. 1995). One possibility is that activation in the anterior inferior temporal lobe increases when the semantic attributes become more specific. For instance, famous people are associated with very specific biographical memories and sentences require the integration of many semantic attributes into more specific concepts.

There may also be some anatomical specialisation in the left posterior inferior parietal cortex. In some studies semantically induced activity lies close to the temporal cortex (see Fig. 10) whereas in others activation extends posteriorly and superiorly into the angular gyrus (see picture naming in Fig. 9 and fourth panel in Fig. 11). Although the precise role of these different regions remains unclear, differentiation within subjects has been shown by Mummery et al. (1998) who found that the dorsal posterior inferior parietal cortex was more active when semantic processing required judgements about where objects

are typically located (e.g. hammers and screwdrivers in the tool box, rakes and spades in the garden shed) relative to judgements on the colour of objects.

The fourth panel of Figure 11 illustrates the activation for associating the names of objects on the basis of their meaning (e.g. linking the word 'Baby' to 'Cot' rather than 'Bed') relative to associating words on the basis of their physical size (e.g. linking the word 'Baby' to 'Baby' rather than 'Baby'). In addition to activation in the anterior and posterior middle temporal and posterior parietal regions, 2 other areas were activated that have not been discussed so far. The first is an area of the middle fusiform gyrus that lies medial and anterior to the naming area (for relative position of these areas, see bottom panel of Fig. 11). The second area covers the left inferior and middle frontal gyri including the anterior part of Broca's area. These areas will now be discussed in turn.

The middle fusiform area (Brodmann's area 20) around the collateral sulcus (which separates the fusiform and parahippocampal gyri), is commonly activated when words and pictures are viewed (Bookheimer et al. 1995; Damasio et al. 1996; Martin et al. 1996; Herberster et al. 1997; Moore & Price, 1999). It is also more active when people listen to object names and imagine the stimulus relative to when abstract words are listened to passively (D'Esposito et al. 1997). Thus it appears to respond irrespective of the stimulus input modality. D'Esposito et al. (1997) associated the region with the visual attributes of semantic memory but it is clearly not specific to visual memory, since the same area is activated when congenitally blind subjects read words with abstract meanings in Braille (see Buechel et al. 1998; Moore & Price, 1999), i.e. using tactile input.

Frontal activations

The extensive frontal activation seen for associating triads of words on the basis of meaning corresponds to the area that is most frequently reported and discussed in functional imaging studies of semantic processing (e.g. Petersen et al. 1988, 1989, 1990; Kapur et al. 1994; Demb et al. 1995; Shaywitz et al. 1995; Gabrielli et al. 1996, 1998; Thompson-Schill et al. 1997; Chee et al. 1999). Why might this be the case when only the frontal operculum is activated during single word reading and heard word repetition? The answer clearly lies in the cognitive tasks that are employed. When subjects are asked to select a word that matches a target, several nonlinguistically specific

processes are required including (1) initiation of a new sequence of cognitive processes, (2) reading the target word (e.g. 'Baby') and the 2 choices (e.g. 'Cot' and 'Bed'), (3) accessing perceptual and functional semantic associations (e.g. what it looks like and how it is used); (4) holding the meaning of these words in memory; (5) selecting the stimulus most closely associated with the target; and (6) making response. Prefrontal activity may relate to any of these processes. Indeed, dorsolateral prefrontal activation has been associated with nonlinguistic processes such as 'willed action' (Frith et al. 1991*b*) and working memory (Paulesu et al. 1993). For instance, Frith et al. (1991*b*) demonstrated that extensive prefrontal activation is involved in self initiation of motor responses as well as self initiation of speech (see Fig. 9). Furthermore, when attempts are made to control as many aspects of the cognitive strategy as possible, semantic tasks primarily result in activation of the temporal lobes (Demonet et al. 1992, 1994*a*; Binder et al. 1997; Price et al. 1997*b*; Pugh et al. 1998). Raichle et al. (1994) has also demonstrated that as a new task becomes more familiar, activation in the left prefrontal cortex decreases. Nevertheless, there is also some suggestion that different parts of the inferior frontal cortex are specialised for semantic and phonological tasks (Buckner et al. 1995; Fiez 1997). Tasks that require decisions about the meaning of words tend to enhance activation in the anterior inferior frontal cortex (Fiez et al. 1997; Mummery et al. 1998; Dapretto & Bookheimer, 1999) whereas tasks that require decisions about the phonemic content of words tend to enhance activation in the dorsal posterior inferior frontal cortex (Demonet et al. 1992, 1994*a, b*; Paulesu et al. 1993; Buckner et al. 1995; Zatorre et al. 1996; Fiez et al. 1997). In summary, activation in the left middle frontal cortex increases for novel complex tasks that require executive control. Likewise activation in the anterior ventral inferior frontal cortex appears to be involved in associating the meanings of different words and activation in the dorsal posterior inferior frontal cortex is most active for phonemic decisions. However, to my knowledge, there are no lesion studies that correspond to these divisions. For the purposes of this article, the critical point is that the anterior part of Broca's area is not required for reading or repeating single words, but it is required for generating word associates, a necessary part of sentence production.

In summary, when the meaning of words is accessed, activation is observed in the left posterior temporoparietal cortex (including the angular gyrus) and several regions in the middle and inferior temporal

cortices. The differential roles that these areas play in semantic processing is still a matter of debate, as are the functions of several regions in the frontal lobe that are activated when the meanings of different words must be linked together. The data on functional specialisation in these temporal and frontal areas deserve their own review but this is not the focus of the present article which is concerned with testing 3 specific models of auditory and visual word processing.

5. COMBINING FUNCTIONAL IMAGING DATA WITH NEUROLOGICAL AND COGNITIVE MODELS

(See Fig. 12 and Figs 1–4)

The data presented in Section 4 are consistent with the following account (see Fig. 12). Auditory processing of heard words activates bilateral superior temporal gyri. Accessing the meaning of words activates the left posterior middle temporal, posterior temporoparietal and anterior inferior temporal cortices (the different regions may be involved in different types of semantic attribute). When speech output is required, activation is enhanced in the posterior superior temporal sulci and left posterior inferior temporal cortex. Activation in the posterior superior temporal sulci increases when words or sublexical speech are repeated or read but not when pictures are named. Thus the posterior superior temporal sulci (Wernicke's area) may sustain nonsemantically mediated speech output. In contrast, the left posterior inferior temporal cortex, which is in close proximity to the middle fusiform semantic area (see bottom panel of Fig. 11), is activated by a range of word retrieval tasks such as picture naming and verbal fluency. It is therefore involved in lexical, semantically mediated speech output. Irrespective of which temporal areas mediate speech output, articulatory planning activates the left anterior insula or an adjacent region in the frontal operculum (the determinants of the location of this activation remain unclear). The process of phonological retrieval therefore involves integration of activity in the anterior insula/frontal operculum with activity in posterior superior temporal sulci or the left posterior inferior temporal cortex. Finally, motor control of speech output activates bilateral sensorimotor cortices and hearing the sound of the spoken response increases activation in the superior temporal gyri.

For written words, the same set of regions is activated. The only areas activated by reading but not auditory word processing are the posterior fusiform and lingual gyri. These areas are not specific to

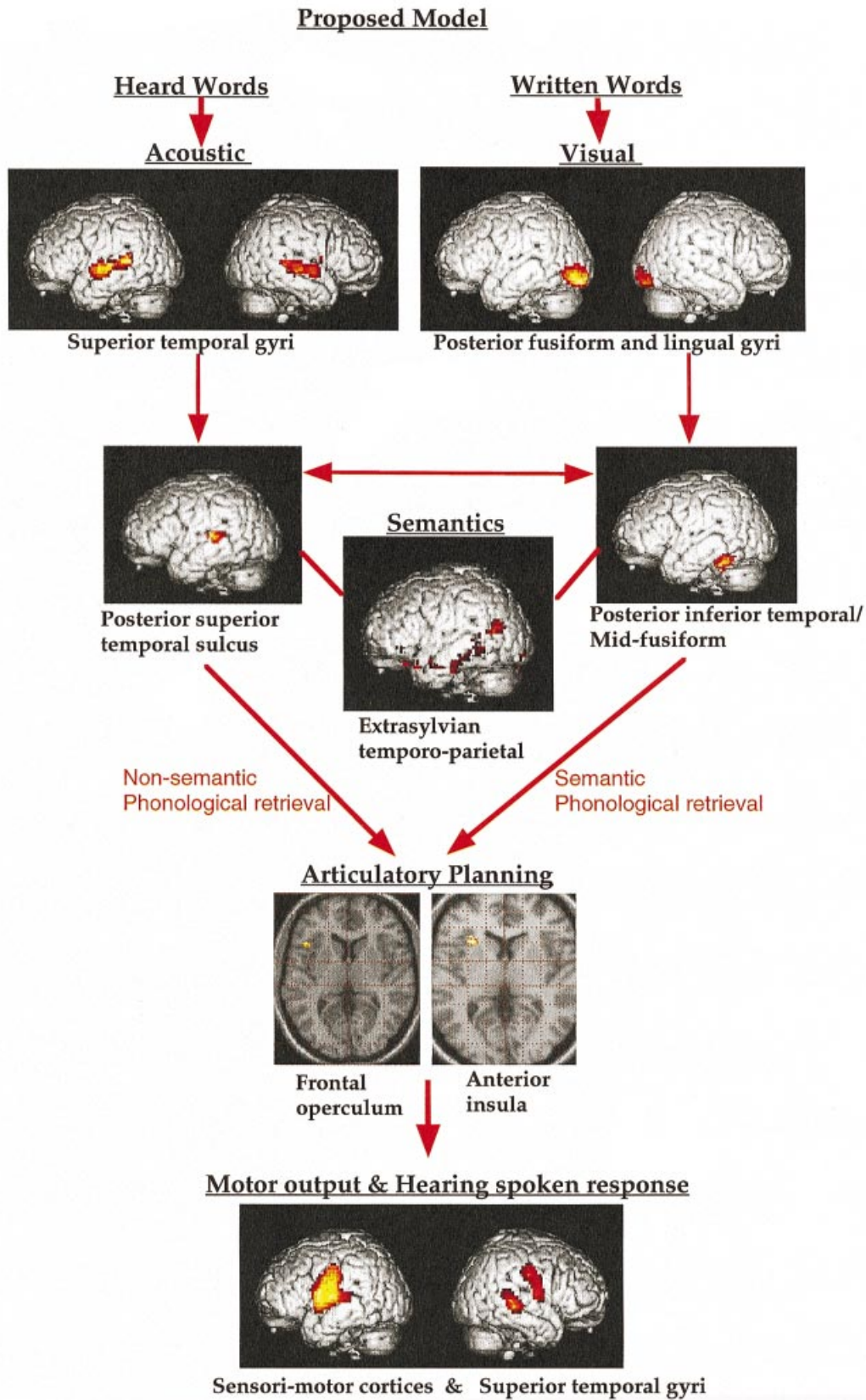


Fig. 12. Proposed neurological and cognitive model of language. Brain areas activated. Top row: acoustic processing of heard words and visual processing of written words (data from Price et al. 1996c). Second row, left: phonological processing of speech sounds relative to environmental sounds (data from A. L. Giraud & C. J. Price, unpublished). Second row, middle: semantic decisions relative to phonological decisions on the same words (data from Price et al. 1997b). Second row, right: retrieving the name (via lexical semantics) relative to seeing visual controls and saying 'Okay' or 'Yes' (data from Price & Friston, 1997b). Third row: transverse slices to show the anterior insula and

reading because they are also activated by picture naming. What is specific to reading is the cooccurrence of activity in visual cortex and the posterior superior temporal sulci. This type of specialisation is referred to as 'functional integration'. There might be reading specific connections between visual and temporal areas or anatomical segregation of visual and auditory inputs within the 'shared' regions but further studies are required.

How does the model presented in Figure 12 relate to the neurological and cognitive models described in Figures 1–4? The correspondence to the 19th Century neurological model illustrated in Figure 1 is clear although a few refinements have been made. First, the site that corresponds to the function of Wernicke's area is the upper bank of the posterior superior temporal sulcus. Second, the critical site for articulatory planning is the anterior insula, not the third frontal convolution (Broca's area). Third, the angular gyrus is not specific to visual word forms but is engaged when semantic associations are made. Fourth, the meaning of words is also distributed along the left inferior and middle temporal cortices. Fifth, reading and name retrieval tasks activate the left posterior inferior temporal lobe. This region is thought to have monosynaptic connections to Broca's area (DiVirgilio & Clarke, 1997) thereby providing the semantic reading route that was missing from the 19th Century model. In brief, the only anatomical regions that were missing from the 19th Century neurological model were in the inferior temporal cortices, areas that are relatively resistant to the ischaemic damage that the lesion deficit model is dependent upon.

With respect to the cognitive components of the 19th Century model (Fig. 2), activation in the posterior superior temporal sulci corresponds to 'auditory word representations', activation in the left anterior insula/frontal operculum corresponds to 'motor word representations' and activation in the extrasyllabic temporoparietal regions correspond to the 'concept centre'. The inconsistency lies in the reading components. Critically, there are no consistent functional imaging data to indicate an anatomical region that corresponds to 'visual word representations'. A study by Puce et al. (1994) found a region in the left fusiform area that was more responsive to

letters than faces but the coordinates of the 'letter area' correspond exactly to those associated with naming (see Fig. 9 and bottom panel of Fig. 11) suggesting that the participants in the Puce et al. study named the letters but not the faces. Furthermore, there are no regions of the visual cortex that appear to be more active for words than pictures. It may be that the design or spatial resolution of the experiments so far have been insufficient to reveal a visual word form area. However, another possibility is that the function of the visual word form area is not localised in a specific cortical area but emerges from the interaction between visual, phonological and semantic processing (see Fig. 4). Returning to Figure 2, the functional imaging data described in Figure 12 indicate that the visual word representation box in Figure 2 needs to be replaced by a visual processing box and a 'word retrieval' box with the latter connecting to the 'auditory word representation', the 'concept centre' and the 'motor word representations' boxes.

The correspondence of the functional imaging data (Fig. 12) and the cognitive components of the Patterson & Shewell model (Fig. 3) is more speculative and less compelling. The 2 critical features of this model relative to the 19th Century version are (1) the provision for more than one reading route; and (2) word specific lexicons (see Fig. 3 and the Table). With respect to the former, the neuroimaging data do indeed suggest 2 routes to reading: a nonsemantic route via Wernicke's area and a semantic route via the left posterior inferior temporal cortex. With respect to the latter, there are no clear neuroimaging data to provide any evidence for anatomical sites for the word specific input and output lexicons. This may relate to the experimental designs used or the spatial resolution. Alternatively, it is just as likely to reflect how these functions emerge from the interactions between semantic and phonological processing sites. As summarised by Mesulam (1990) 'Each behavior is represented in multiple sites and each site subserves multiple behaviors, leading to a distributed and interactive system with a one to many and many to one mapping of anatomical substrate onto neural computation and computation onto behavior'. The same point is emphasised by connectionist models such as that illustrated in Figure 4 which depicts 3 essential building blocks for auditory and visual word

frontal operculum activations during phonological output (data from Price & Friston, 1997b). Fourth row: motor areas for articulation and auditory processing of spoken response for reading aloud relative to reading silently (data from Price et al. 1996b). Red arrows connect these areas to indicate the proposed model of auditory and visual word processing.

processing: semantics, orthography and phonology. However such connectionist models are not constrained by physiological facts and have little biological validity. For instance, the physiological data reported in this article indicate that there is more than one anatomical system involved in retrieving the phonology of words and there are no areas specific to orthographic input. Future cognitive models therefore need to be constrained by the underlying physiological infrastructure. In summary, progress in specifying the cognitive and anatomical components of word processing requires the combined and integrated application of all the neuroscience techniques available.

It is too early in the history of functional neuroimaging to tell whether the details of the model presented in Figure 12 are correct or incorrect. The main aim of this article is to illustrate how functional neuroimaging can contribute to cognitive and anatomical models of language and reconcile the different perspectives. Many future studies which integrate data from a variety of techniques are required to refine the model further, to explain how single words are integrated into sentences, describe the role of the right hemisphere, and answer many other related questions.

ACKNOWLEDGEMENTS

I would like to thank Karl Friston, Joseph Devlin, Jeff Binder and 2 anonymous reviewers for their comments on earlier drafts of this manuscript. The illustrations were prepared using data collected by Caroline Moore, Anne Lise Giraud, Eamon McCrory, Maria Luisa Gorno-Tempini, Nicky Brunswick, Catherine Mummery, Rik Vandenberghe, Elizabeth Warburton, Christian Buechel and myself. Funding for these studies was provided by the Wellcome Trust.

REFERENCES

ALEXANDER MP, HILTBRUNNER B, FISCHER RS (1989) Distributed anatomy of transcortical sensory aphasia. *Archives of Neurology* **46**, 885–892.

ALLISON T, McCARTHY G, NOBRE A, PUCE A, BELGER A (1994) Human extrastriate visual cortex and the perception of faces, words, numbers and colors. *Cerebral Cortex* **4**, 544–554.

AUERBACH SH, ALLARD T, NAESER M, ALEXANDER MP, ALBERT ML (1982) Pure word deafness: an analysis of a case with bilateral lesions and a deficit at the prephonemic level. *Brain* **105**, 271–300.

BAVELIER D, CORINA D, JEZZARD P, PADMANABHAN S, PRINSTER A, BRAUN A (1997) Sentence reading: a functional MRI study at 4 tesla. *Journal of Cognitive Neuroscience* **9**, 664–686.

BEAUREGARD M, CHERTKOW H, BUB D, MURTHA S, DIXON R, EVANS A (1997) The neural substrate for concrete,

abstract, and emotional word lexica: a positron emission tomography study. *Journal of Cognitive Neuroscience* **9**, 441–461.

BELIN P, ZATORRE RJ, LAFAILLE P, AHAD P, PIKE B (2000) Voice selective areas in human auditory cortex. *Nature* **403**, 309–312.

BINDER JR, FROST JA, HAMMEKE TA, COX RW, RAO SM, PRIETO T (1997) Human brain language areas identified by functional magnetic resonance imaging. *Journal of Neuroscience* **17**, 353–362.

BOCK K. (1995) Sentence production: from mind to mouth. In *Speech, Language and Communication* (ed. Miller J, Eimas P), pp. 181–216. San Diego: Academic Press.

BOCK K, LEVELT WJM (1994) Language production: grammatical encoding. In *Handbook of Psycholinguistics* (ed. Gernsbacher MA), pp. 945–984. San Diego: Academic Press.

BOOKHEIMER SY, ZEFFIRO TA, BLAXTON T, GAILLARD W, THEODORE W (1995) Regional cerebral blood flow during object naming and word reading. *Human Brain Mapping* **3**, 93–106.

BOTTINI G, CORCORAN R, STERZI R, PAULESU E, SCHENONE P, SCARPA P et al. (1994) The role of the right hemisphere in the interpretation of figurative aspects of language: a positron emission tomography activation study. *Brain* **117**, 1241–1253.

BROCA P (1861) Remarques sur le siège de la faculté du langage articulé; suivies d'une observation d'aphemie. *Bulletin de la Société Anatomique de Paris* **6**, 330–357.

BRUNSWICK N, McCRORY E, PRICE CJ, FRITH CD, FRITH U (1999) Explicit and implicit processing of words and pseudowords by adult developmental dyslexics: a search for Wernicke's Wortschatz. *Brain* **122**, 1901–1917.

BUCHMAN AS, GARRON DC, TROST-CARDAMONE JE, WICHTER MD, SCHWARTZ D (1986) Word deafness: one hundred years later. *Journal of Neurology, Neurosurgery and Psychiatry* **49**, 489–499.

BUCKNER RL, RAICHLE ME, PETERSEN SE (1995) Dissociation of human prefrontal cortical areas across different speech production tasks and gender groups. *Journal of Neurophysiology* **74**, 2163–2173.

BUECHEL C, PRICE CJ, FRISTON KJ (1998) A multi-modal language area in the ventral visual pathway. *Nature* **394**, 274–277.

BURNSTINE TH, LESSER RP, HART J. JR, UEMATSU S, ZINREICH SJ, DRAUSS GL et al. (1990) Characterization of the basal temporal language area in patients with left temporal lobe epilepsy. *Neurology* **40**, 966–970.

CHEE MWL, O' CRAVEN KM, BERGIDA R, ROSEN BR, SAVOY RL (1999) Auditory and visual word processing studied with fMRI. *Human Brain Mapping* **7**, 15–28.

CONNOLLY JF, PHILLIPS NA (1994) Event-related potential components reflect phonological and semantic processing of the terminal word of spoken sentences. *Journal of Cognitive Neuroscience* **6**, 256–266.

COSTELLO AL, WARRINGTON EK (1989) Dynamic aphasia: the selective impairment of verbal planning. *Cortex* **25**, 103–114.

CREUTZFELD O, OJEMANN G, LETTICH E (1989) Neuronal activity in the human lateral temporal lobe. I. Responses to speech. *Experimental Brain Research* **77**, 451–475.

DAMSIO A, DAMASIO H (1983) The anatomic basis of pure alexia. *Neurology* **33**, 1573–1583.

DAMASIO A, GESCHWIND N (1984) The neural basis of language. *Annual Review of Neuroscience* **7**, 127–147.

DAMASIO H, GRABOWSKI TJ, TRANEL D, HICHA RD, DAMASIO AR (1996) A neural basis for lexical retrieval. *Nature* **380**, 499–505.

DAPRETTO M, BOOKHEIMER SY (1999) Form and content: dissociating syntax and semantics in sentence comprehension. *Neuron* **24**, 427–432.

D'ESPOSITO M, DETRE JA, AGUIRRE GK, STALLCUP M,

- ALSOP DC, TIPPET LJ et al. (1997) A functional MRI study of mental image generation. *Neuropsychologia* **35**, 725–730.
- DEJERINE J (1891) Sur un cas de cécité verbale avec aggraphie, suivi d'autopsie. *Mémoires de la Société Biologique* **3**, 197–201.
- DEJERINE J (1892) Contribution à l'étude anatomoclinique et clinique des différentes variétés de cécité verbale. *Compte Rendu Hebdomadaire des Séances et Mémoires de la Société de Biologie* **4**, 61–90.
- DEMB JB, DESMOND JE, WAGNER AD, VAIDYA CJ, GLOVER GH, GABRIELI JDE (1995) Semantic encoding and retrieval in the left inferior prefrontal cortex: a functional MRI study of task difficulty and process specificity. *Journal of Neuroscience* **15**, 5870–5878.
- DEMONET J-F, CHOLLET F, RAMSAY S, CARDEBAT D, NESPOULOUS J-D, WISE R et al. (1992) The anatomy of phonological and semantic processing in normal subjects. *Brain* **115**, 1753–1768.
- DEMONET JF, PRICE CJ, WISE R, FRACKOWIAK RSJ (1994a) Differential activation of right and left posterior sylvian regions by semantic and phonological tasks: a positron emission tomography study. *Neuroscience Letters* **182**, 25–28.
- DEMONET JF, PRICE CJ, WISE R, FRACKOWIAK RSJ (1994b) A PET study of cognitive strategies in normal subjects during language tasks: influence of phonetic ambiguity and sequence processing on phoneme monitoring. *Brain* **117**, 671–682.
- DE RENZI E, ZAMBOLIN A, CRISI G (1987) The pattern of neuropsychological impairment associated with left posterior cerebral artery territory infarcts. *Brain* **110**, 1099–1116.
- DI VIRGILIO G, CLARKE S (1997) Direct interhemispheric visual input to human speech areas. *Human Brain Mapping* **5**, 347–354.
- DRONKERS NF (1996) A new brain region for co-ordinating speech articulation. *Nature* **384**, 159–161.
- ENGELEIN A, SILBERSWEIG D, STERN E, HUBER W, DORING W, FRITH C et al. (1995) The functional anatomy of recovery from auditory agnosia. A PET study of sound categorisation in a neurological patient and normal controls. *Brain* **118**, 1395–1409.
- FARAH MJ, McCLELLAND JL (1991) A computational model of semantic memory impairment: modality specificity and emergent category specificity. *Journal of Experimental Psychology, General* **120**, 339–357.
- FEIZ JA (1997) Phonology, semantics and the role of the left inferior prefrontal cortex. *Human Brain Mapping* **5**, 79–83.
- FEIZ JA, BALOTA DA, RAICHLER ME, PETERSEN SE (1993) The effects of word frequency and spelling to sound regularity on the functional anatomy of reading. Presented at the Society of Neuroscience 23rd Annual Meeting, Washington DC.
- FEIZ JA, PETERSEN SE (1998) Neuro-imaging studies of word reading. *Proceedings of the National Academy of Sciences of the USA* **95**, 914–921.
- FEIZ JA, RAICHLER ME, MIEZIN FM, PETERSEN SE, TALLAL P, KATZ WF (1995) PET studies of auditory and phonological processing: effects of stimulus characteristics and task demands. *Journal of Cognitive Neuroscience* **7**, 357–375.
- FINK GR, HALLIGAN PW, MARSHALL JC, FRITH CD, FRACKOWIAK RSJ, DOLAN RJ (1996) Where in the brain does visual attention select the forest and the trees? *Nature* **382**, 626–628.
- FLETCHER PC, HAPPE F, FRITH U, BAKER SC, DOLAN RJ, FRACKOWIAK RSJ et al. (1995) Other minds in the brain: a functional imaging study of 'theory of mind' in story comprehension. *Cognition* **57**, 109–128.
- FOUNDAS A, DANIELS SK, VASTERLING JJ (1998) Anomia: case studies with lesion localisation. *Neurocase* **4**, 35–43.
- FRISTON KJ, PRICE CJ, FLETCHER P, MOORE C, FRACKOWIAK RSJ, DOLAN RJ (1996) The trouble with cognitive subtraction. *NeuroImage* **4**, 97–104.
- FRITH CD, FRISTON KJ, LIDDLE PF, FRACKOWIAK RSJ (1991a) A PET study of word finding. *Neuropsychologia* **29**, 1137–1148.
- FRITH CD, FRISTON KJ, LIDDLE PF, FRACKOWIAK RSJ (1991b) Willed action and the prefrontal cortex in man: a study with PET. *Proceedings of the Royal Society of London, Series B*, **244**, 241–246.
- FROST J, BINDER, JR, POSSING ET, BELLGOWAN TA, HAMMEKE TA (1998) Stimulus novelty affects superior temporal gyrus activation. *NeuroImage* **7**, S3777.
- GABRIELI JDE, DESMOND JE, DEMB JB, WAGNER AD, STONE MV, VAIDYA CJ et al. (1996) Functional magnetic resonance imaging of semantic memory processes. *Psychological Science* **7**, 278–283.
- GABRIELI JDE, POLDRACK RA, DESMOND JE (1998) The role of left prefrontal cortex in language and memory. *Proceedings of the National Academy of Sciences of the USA* **95**, 906–913.
- GESHWIND (1965) Disconnection syndromes in animals and man. *Brain* **88**, 237–294.
- GORNO-TEMPINI ML, PRICE CJ, JOSEPHS O, VANDENBERGHE R, CAPPAS SF, KAPUR N et al. (1998) The neural systems sustaining face and proper name processing. *Brain* **121**, 2103–2118.
- GORNO-TEMPINI ML, CIPOLOTTI L, PRICE CJ (2000) Category specific brain activation: where does it come from? *Proceedings of the Royal Society of London, Series B*, in press.
- GREEN DW (1998) Mental control of the bilingual lexico-semantic system. *Bilingualism* **1**, 67–81.
- HART J, GORDON B (1990) Delineation of single word semantic comprehension deficits in aphasia, with anatomical correlation. *Annals of Neurology* **27**, 226–231.
- HERBSTER AN, MINTUN MA, NEBES RD, BECKER JT (1997) Regional cerebral blood flow during word and nonword reading. *Human Brain Mapping* **5**, 84–92.
- HODGES JR, PATTERSON K, OXBURY S, FUNNELL E (1992) Semantic dementia. *Brain* **115**, 1783–1806.
- HOWARD D, PATTERSON K, WISE RJS, BROWN WD, FRISTON K, WEILLER C et al. (1992) The cortical localization of the lexicons: positron emission tomography evidence. *Brain* **115**, 1769–1782.
- INDEFREY P, KLEINSCHMIDT A, MERBOLDT K-D, KRÜGER G, BROWN C, HAGOORT P et al. (1997) Equivalent responses to lexical and nonlexical visual stimuli in occipital cortex: a functional magnetic resonance imaging study. *NeuroImage* **5**, 78–81.
- KAPUR S, ROSE R, LIDDLE PF, ZIPURSKY RB, BROWN GM, STUSS D et al. (1995b) The role of the left prefrontal cortex in verbal processing: semantic processing or willed action? *NeuroReport* **5**, 2193–2196.
- KERTESZ A, SHEPPARD A, MacKENZIE R (1982) Localization in transcortical sensory aphasia. *Archives of Neurology* **39**, 475–478.
- LEVELT WJM (1989) *Speaking: From Intention to Articulation*. Cambridge, MA: MIT Press.
- LICHTHEIM L (1885) On aphasia. *Brain* **7**, 433–484.
- LUDERS H, LESSER RP, HAHN J, DINNER DS, MORRIS HH, WYLLIE E et al. (1991) Basal temporal language area. *Brain* **114**, 743–754.
- LUDERS H, LESSER RP, HAHN J, DINNER DS, MORRIS H, RESOR S et al. (1986) Basal temporal language area demonstrated by electrical stimulation. *Neurology* **36**, 505–510.
- MARIN OSM (1980) CAT scans of five deep dyslexic patients. Appendix 1, in *Deep Dyslexia* (ed. Coltheart M, Patterson KE, Marshall JC), pp. 407–433. London: Routledge.
- MARSHALL JC, NEWCOMBE F (1973) Patterns of paralexia: a psycholinguistic approach. *Journal of Psycholinguistic Research* **2**, 175–199.

- MARTIN A, HAXBY JV, LALONDE FM, WIGGS CL, UNGERLEIDER LG (1995) Discrete cortical regions mediate knowledge of colors and knowledge of actions. *Science* **270**, 102–105.
- MARTIN A, WIGGS CL, UNGERLEIDER LG, HAXBY JV (1996) Neural correlates of category-specific knowledge. *Nature* **379**, 649–652.
- MAZOYER BM, TZOURIO N, FRAK V, SYROTA A, MURAYAMA N, LEVRIER D (1993) The cortical representation of speech. *Journal of Cognitive Neuroscience* **5**, 467–479.
- MACLEOD CM (1991) Half a century of research on the Stoop effect: an integrative review. *Psychological Bulletin* **109**, 163–203.
- McCRORY E, FRITH U, BRUNSWICK N, PRICE C. (2000) Abnormal functional activation during a simple word repetition task: a PET study of adult dyslexics. *Journal of Cognitive Neuroscience*, in press.
- McCLELLAND JL, RUMELHART DE (1981) An interactive activation model of context effects in letter perception. I. An account of basic findings. *Psychological Reviews* **88**, 375–407.
- MENARD MT, KOSSLYN SM, THOMPSON WL, ALPERT NM, RAUCH SL (1996) Encoding words and pictures: a positron emission tomography study. *Neuropsychologia* **34**, 184–194.
- MESULAM MM (1990) Large scale neurocognitive networks and distributed processing for attention, language and memory. *Annals of Neurology* **28**, 597–613.
- MOORE CJ, PRICE CJ (1999) Three distinct regions for word and picture naming in the ventral visual pathway. *NeuroImage* **10**, 181–192.
- MUMMERY CJ, PATTERSON K, HODGES J, PRICE CJ (1998) Organisation of the semantic system—divisible by what? *Journal of Cognitive Neuroscience* **10**, 766–777.
- MUMMERY CJ, ASHBURNER J, SCOTT SK, WISE RJ (1999) Functional neuro-imaging of speech perception in six normal and two aphasic subjects. *Journal of the Acoustic Society of America* **106**, 449–457.
- MURTHA S, CHERTKOW H, BEAUREGARD M, EVANS A (1997) The neural substrate of picture naming. *Journal of Cognitive Neuroscience* **11**, 399–423.
- NAVON D (1977) Forest before trees: the precedent of global features in visual perception. *Cognitive Psychology* **9**, 353–383.
- NOBRE AC, ALLISON T, McCARTHY G (1994) Word recognition in the human inferior temporal lobe. *Nature* **372**, 260–263.
- PATTERSON K, SHEWELL C (1987) Speak and spell: dissociations and word class effects. In *The Cognitive Neuropsychology of Language* (ed. Coltheart M, Sartori G, Job R), pp. 273–294. London: Erlbaum.
- PAULESU E, FRITH CD, FRACKOWIAK RSJ (1993) The neural correlates of the verbal component of working memory. *Nature* **362**, 342–344.
- PAULESU E, McCRORY E, FAZIO F, MENONCELLO L, BRUNSWICK N, CAPPAS SF et al. (2000) A cultural effect on brain function. *Nature Neuroscience* **3**, 91–96.
- PETERSEN SE, FOX PT, POSNER MI, MINTUM M, RAICHLER ME (1988) Positron emission tomographic studies of the cortical anatomy of single word processing. *Nature* **331**, 585–589.
- PETERSEN SE, FOX PT, POSNER MI, MINTUM M, RAICHLER ME (1989) Positron emission tomographic studies of the processing of single words. *Journal of Cognitive Neuroscience* **1**, 153–170.
- PETERSEN SE, FOX PT, SYNDER AZ, RAICHLER ME (1990) Activation of extrastriate and frontal cortical areas by words and word-like stimuli. *Science* **249**, 1041–1044.
- PHILLIPS J, HUMPHREYS GW, PRICE CJ (1999) Different routes to action from words and pictures: evidence from neuroimaging. *NeuroImage* **9**, S 1042.
- PLAUT DC, McCLELLAND JL, SEIDENBERG MS, PATTERSON K (1996) Understanding normal and impaired reading: computational principles in quasi-regular domains. *Psychological Reviews* **103**, 56–105.
- PLAUT DC, SHALLICE T (1993) Deep dyslexia: a case study of connectionist neuropsychology. *Cognitive Neuropsychology* **10**, 377–500.
- PRICE CJ, GIRAUD AL (1998) The constraints functional anatomy places on cognitive models of auditory word processing. Fourth International Conference on Functional Mapping of the Human Brain. *NeuroImage*, S168.
- PRICE CJ, WISE RJS, WATSON JDG, PATTERSON K, HOWARD D, FRACKOWIAK RSJ (1994) Brain activity during reading: the effects of exposure duration and task. *Brain* **117**, 1255–1269.
- PRICE CJ, WISE RJS, FRACKOWIAK RSJ (1996a) Demonstrating the implicit processing of visually presented words and pseudowords. *Cerebral Cortex* **6**, 62–70.
- PRICE CJ, WISE RJS, WARBURTON E, MOORE CJ, PATTERSON K, HOWARD D et al. (1996b) Hearing and saying: the functional neuroanatomy of auditory word processing. *Brain* **119**, 919–931.
- PRICE CJ, MOORE CJ, FRACKOWIAK RSJ (1996c) The effect of varying stimulus rate and duration on brain activity during reading. *NeuroImage* **3**, 40–52.
- PRICE CJ, FRISTON KJ (1997a) The temporal dynamics of reading: a PET study. *Proceedings of the Royal Society of London, Series B* **264**, 1785–1791.
- PRICE CJ, FRISTON KJ (1997b) Cognitive conjunctions: a new approach to brain activation experiments. *NeuroImage* **5**, 261–270.
- PRICE CJ, MOORE CJ, FRISTON KJ (1997a) Subtractions, conjunctions and interactions in experimental design of activation studies. *Human Brain Mapping* **5**, 264–272.
- PRICE CJ, MOORE CJ, HUMPHREYS GW, WISE RJS (1997b) Segregating semantic from phonological processing. *Journal of Cognitive Neuroscience* **9**, 727–733.
- PUCE A, ALLISON T, ASGARI M, GORE JC, McCARTHY G (1996) Differential sensitivity of human visual cortex to faces, letterstrings and textures: a functional magnetic resonance imaging study. *Journal of Neuroscience* **16**, 5205–5215.
- PUGH KR, SHAYWITZ BA, SHAYWITZ SE, CONSTABLE RT, SKUDLARSKI P, FULBRIGHT RK et al. (1996) Cerebral organisation of component processes in reading. *Brain* **119**, 1221–1238.
- RAICHLER ME, FIEZ JA, VIDEEN TO, MACLEOD AK, PARDO JV, FOX PT et al. (1994) Practice-related changes in human brain functional anatomy during non-motor learning. *Cerebral Cortex* **4**, 8–26.
- RAMSAY SC, ADAMS L, MURPHY K, CORFIELD DR, GROOTNOONK S, BAILEY DL et al. (1993) Regional cerebral blood flow during volitional expiration in man: a comparison with volitional inspiration. *Journal of Physiology* **461**, 85–101.
- RAYMER AM, FOUNDAS AL, MAHER LM (1997) Cognitive neuropsychological analysis and neuroanatomic correlates in a case of acute anomia. *Brain and Language* **58**, 137–156.
- RUBENS AB (1976) Transcortical motor aphasia. In *Studies in Neurolinguistics* (ed. Whitaker H), pp. 293–306. New York: Academic Press.
- RUMSEY JM, HORWITZ B, DONOHUE C, NACE K, MAISOG JM, ANDREASON P (1997) Phonologic and orthographic components of word recognition: a PET-rCBF study. *Brain* **120**, 739–759.
- SEIDENBERG MS, McCLELLAND JL (1989) A distributed developmental model of word recognition and naming. *Psychological Reviews* **96**, 523–568.
- SELTZER B, COLA MG, GUTIERREZ C, MASSEE M,

- WELDON C, CUSICK CG (1996) Overlapping and non-overlapping cortical projections to cortex of the superior temporal sulcus in the Rhesus monkey: double anterograde studies. *Journal of Comparative Neurology* **370**, 173–190.
- SELTZER B, PANDYA DN (1994) Parietal, temporal, and occipital projections to cortex of the superior temporal sulcus in the rhesus monkey: a retrograde tracer study. *Journal of Comparative Neurology* **343**, 445–463.
- SHALLICE T (1988) *From Neuropsychology to Mental Structure*. Cambridge: Cambridge University Press.
- SHAYWITZ BA, PUGH KR, CONSTABLE T (1995) Localization of semantic processing using functional magnetic resonance imaging. *Human Brain Mapping* **2**, 149–158.
- SHULMAN GL, FIEZ JA, CORBETTA M, BUCKNER RL, MEIZIN FM, RAICHLE ME et al. (1997) Common blood flow changes across visual tasks: II. Decreases in cerebral cortex. *Journal Cognitive Neuroscience* **9**, 648–663.
- THOMPSON-SCHILL SL, D'ESPOSITO M, AGUIRRE GK, FARAH MJ (1997) Role of left inferior prefrontal cortex in retrieval of semantic knowledge: a reevaluation. *Proceedings of the National Academy of Science of the USA* **94**, 14792–14797.
- VANDENBERGHE R, PRICE CJ, WISE R, JOSEPHS O, FRACKOWIAK RSJ (1996) Semantic system(s) for words or pictures: functional anatomy. *Nature* **383**, 254–256.
- VANIER M, CAPLAN D (1985) CT scan correlates of surface dyslexia. In *Surface Dyslexia* (ed. Patterson KE, Marshall JC, Coltheart M), pp. 511–525. London: Lawrence Erlbaum.
- WARBURTON E, WISE RJS, PRICE CJ, WEILLER C, HADAR U, RAMSAY S et al. (1996) Studies with positron emission tomography of noun and verb retrieval in normal subjects. *Brain* **119**, 159–180.
- WARRINGTON EK (1975) A selective impairment of semantic memory. *Quarterly Journal of Experimental Psychology* **27**, 635–657.
- WARRINGTON EK, SHALLICE T (1984) Category specific semantic impairments. *Brain* **103**, 99–112.
- WARRINGTON EK, McCARTHY R (1987) Categories of knowledge: further fractionation and an attempted integration. *Brain* **110**, 1273–1296.
- WARRINGTON EK, McCARTHY R (1994) Multiple meaning systems in the brain: a case for visual semantics. *Neuropsychologia* **32**, 1465–1473.
- WERNICKE C (1874) *Der aphasische Symptomenkomplex*. Breslau, Poland: Cohen and Weigert.
- WISE R, CHOLLET F, HADAR U, FRISTON K, HOFFNER E, FRACKOWIAK R (1991) Distribution of cortical neural networks involved in word comprehension and word retrieval. *Brain* **114**, 1803–1817.
- WISE RJS, GREENE J, BÜCHEL C, SCOTT SK (1999) Brain regions involved in articulation. *Lancet* **353**, 1057–1061.
- ZATORRE RJ, MEYER E, GJEDDE A, EVANS A (1996) PET studies of phonetic processing of speech: review, replication and reanalysis. *Cerebral Cortex* **6**, 21–30.