

## Short Report

# Variations in the normal anatomy of the collateral ligaments of the human elbow joint

K. S. BECKETT<sup>1</sup>, P. McCONNELL<sup>2</sup>, M. LAGOPOULOS<sup>3</sup> AND R. J. NEWMAN<sup>4</sup>

<sup>1</sup>Queen Alexandra Hospital, Portsmouth, <sup>2,3</sup>Centre for Human Biology, University of Leeds and

<sup>4</sup>Department of Orthopaedic and Trauma Surgery, Harrogate District Hospital, UK

(Accepted 30 May 2000)

---

### ABSTRACT

The variations which occur in the medial and lateral ligament complexes of the elbow were investigated. These occurred frequently with the standard appearances occurring in no more than half the specimens on the medial side and one quarter of those on the lateral side. Surgeons who regularly perform elbow arthroplasty must be aware of these considerations, especially with the introduction of unconstrained prostheses which rely upon the ligament complex for their postoperative stability.

*Key words:* Medial and lateral collateral ligaments of elbow; joint stability.

---

### INTRODUCTION

Anatomical descriptions of the ligaments of the elbow joint describe medial and lateral bands (Gray, 1858; Bryce, 1915; Wood-Jones, 1949; Martin, 1958; Schwab et al. 1980; Tullos et al. 1981; Morrey & An, 1983, 1985; Søjbjerg et al. 1987; Williams et al. 1989; Fuss, 1991), but little is known about the range of variation of these structures. Such knowledge is increasingly important as unconstrained elbow arthroplasty is dependent upon retention of the original ligaments for its stability. This study aimed to establish the most common morphology of the medial and the lateral collateral ligament complexes and to assess the variability from standard descriptions of the normal pattern.

### METHODS

Thirty-nine embalmed cadaveric elbow joints were studied. There were 24 male and 15 female specimens, their average age being 81(range 66–101) y. No information was available regarding the dominance of

each elbow joint. A strict dissection protocol was followed. The components of each collateral ligament were identified, classified according to appearance and measured in the position of maximum tension within the flexion/extension arc with the forearm in a neutral position using a set of micrometer calipers. No specimens with a history of elbow pathology or trauma were included. Two specimens were excluded as pathological changes were found in the elbow during dissection. The remainder of the joints were grossly pristine.

### *Medial collateral ligament*

This ligament was divided into 1 of 4 descriptive groups (Fig. 1) based on classical descriptions (Gray, 1858; Sharpey et al. 1867; Wood-Jones, 1949; Morrey & An, 1985; Williams et al. 1989; Fuss, 1991) but modified.

*Group 1 (normal).* The classical description of the medial collateral ligament, i.e. anterior, posterior and oblique bands with the latter inserting only into the coronoid process.

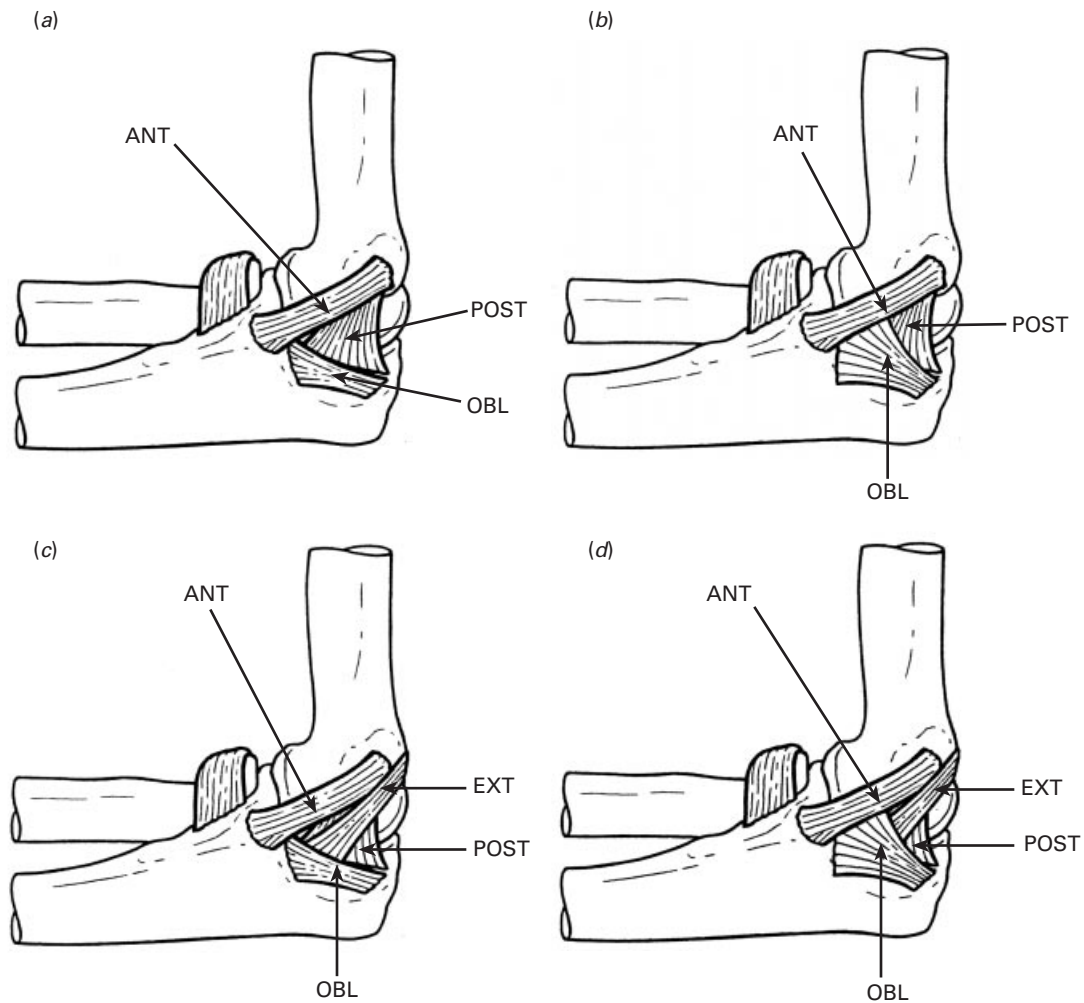


Fig. 1. Classification of the medial collateral ligament complex (a) group 1 (classic); (b) group 2 (strong oblique); (c) group 3 (extra band); (d) group 4 (combination). ANT, anterior band; POST, posterior band; OBL, oblique band; EXT, 'extra' band.

*Group 2 (strong oblique pattern).* The oblique band is expanded into a fan-shaped structure such that its maximum width occupies at least 40% of the length of the anterior band into which it inserts in addition to the coronoid process.

*Group 3 (extra band pattern).* This resembled group 1 but with an additional band in the medial collateral ligament complex passing from the posterior capsule to the oblique band of the medial collateral ligament.

*Group 4 (combination pattern).* A combination of groups 2 and 3.

*Lateral collateral ligament*

This was classified according to the presence or absence of the lateral ulnar collateral ligament and the accessory collateral ligament (Fig. 2).

*Group 1.* Only the lateral collateral ligament and annular ligament present.

*Group 2.* As in group 1 but with a lateral ulnar collateral ligament present.

*Group 3.* As in group 1 but with an accessory collateral ligament present.

*Group 4.* A combination of groups 2 and 3.

RESULTS

The variation in the pattern of the medial and lateral ligament complexes is presented in the Table. The average ( $\pm$ S.D.) lengths of the anterior, posterior and oblique bands of the medial collateral ligament were  $26.7 \pm 3.7$  mm,  $23.2 \pm 3.7$  mm, and  $20.5 \pm 3.4$  mm respectively. The extra band, when present, had an average length of  $39.5 \pm 8.5$  mm. The average ( $\pm$ S.D.) lengths of the lateral collateral ligament, accessory collateral ligament, and the lateral ulnar collateral ligament were  $25.7 \pm 2.7$  mm,  $43.1 \pm 3.3$  mm, and  $45.9 \pm 6.3$  mm respectively.

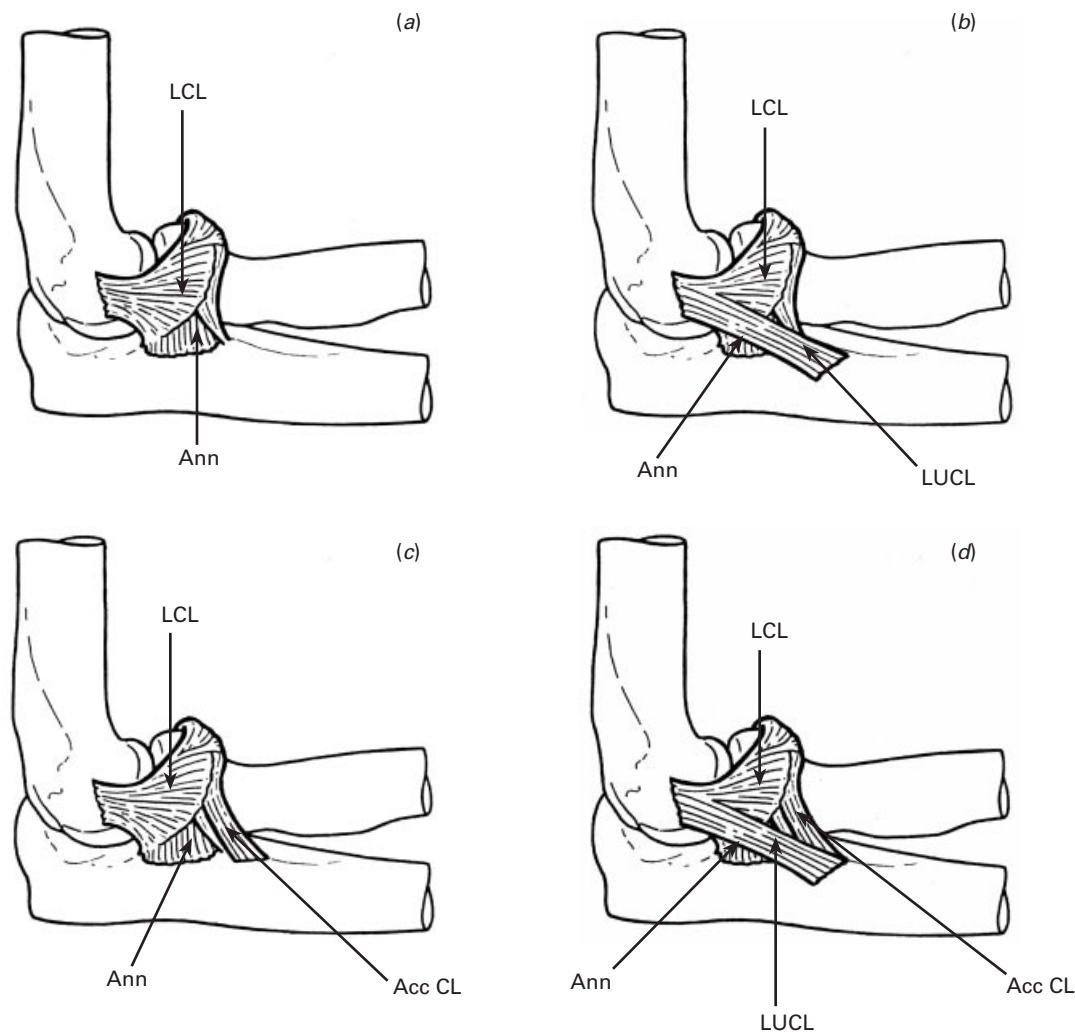


Fig. 2. Classification of the lateral collateral ligament complex. (a) group 1: LCL+annular ligament; (b) group 2: group1+LUCL; (c) group 3: group1+accessory collateral ligament; (d) group 4: group1+LUCL+accessory collateral ligament. LCL, lateral collateral ligament; LUCL, lateral ulnar collateral ligament; AccCL, accessory collateral ligament; Ann, annular ligament.

Table. Variation in the patterns of the collateral ligaments of the elbow

| Group | Medial collateral ligament (%) | Lateral collateral ligament (%) |
|-------|--------------------------------|---------------------------------|
| 1     | 49                             | 23                              |
| 2     | 28                             | 44                              |
| 3     | 08                             | 25                              |
| 4     | 15                             | 07                              |

## DISCUSSION

### Medial collateral ligament complex

Most older works suggest that little variation occurs in this structure (Gray, 1858; Bryce, 1915; Wood-Jones, 1949; Tullos et al. 1981; Williams et al. 1989; Fuss, 1991; O'Driscoll et al. 1991, 1992a; Stroyan &

Wilk, 1993) but our detailed study indicates that variations occur frequently with the so-called classical appearance occurring in no more than half the specimens dissected. The basic structure of the anterior and posterior bands of the medial collateral ligament remains the same in all specimens and variations arise in the arrangement of the oblique band. The oblique band expands into a fan-shaped structure that inserts into the anterior band in addition to the coronoid process of the ulna in approximately a quarter (28%) of cases. It appears that the oblique band is not poorly developed as stated by earlier workers (Sharpey et al. 1867; Bryce, 1915; Wood-Jones, 1949; Morrey & An, 1985; Søjbjerg et al. 1987; Williams et al. 1989; Fuss, 1991; Bass & Stern, 1994; Safran, 1995; Callaway et al. 1997.) but has a well-demarcated structure. Its role remains uncertain.

A second variation observed in the structure of the

medial ligament complex was the presence of a band that passed from the posterior aspect of the capsule to an insertion on the oblique band. A similar structure has only been reported previously by Pauchet & Dupret (1928). This band followed the course of the ulnar nerve into the anterior compartment of the forearm but was separate from its fascial covering.

#### *Lateral collateral ligament complex*

Variations in the lateral collateral ligament are recognised (Sharpey et al. 1867; Wood-Jones, 1949; Martin, 1958; Morrey & An, 1983; O'Driscoll et al. 1991, 1992*b*) and our study shows that the traditional description of this structure (group 1) only occurred in one quarter of specimens (23%). An accessory collateral ligament was observed in one third of cases, a finding very similar to that of Morrey & An (1983). Furthermore, a lateral ulnar collateral ligament was identified in half (51%) of the specimens. This incidence is less than the findings of O'Driscoll et al. (1991) and Olsen et al. (1998) who found this structure present in all their specimens. However, these workers restricted themselves to a relatively small number of specimens.

Most papers have suggested that the lateral ulnar collateral ligament is the most important stabilising part of the lateral ligament complex (O'Driscoll et al. 1991, 1992*b*; O'Driscoll, 1994). Recent studies have shown that the lateral collateral ligament itself may act as the primary constraint with the annular ligament and lateral ulnar collateral ligament acting as secondary constraints (Cohen, 1997; Olsen et al. 1996*a, b*, 1998). This may explain why in our study, the lateral ulnar collateral ligament is only present in half the joints dissected. The lateral ulnar collateral ligament, the accessory collateral ligament, or both were seen in over three quarters of cases (77%) and it may be that these 2 components both perform the same stabilising function. This would be by virtue of their sharing the same insertion into the supinator crest of the ulna even though their points of origin differ. These findings support those of Olsen et al. (1998) who stated that the lateral collateral ligament complex is made up of a complex of fibres rather than discrete ligament bands.

Two of the specimens demonstrated anomalous insertions of the lateral ulnar collateral ligament. These ligaments were longer, passing not only onto the supinator crest, but also further distally onto the shaft of the ulna, as similarly documented by Fuss (1991). The posterior band of the lateral collateral

ligament was found to be present in all the dissected specimens.

This study has demonstrated that variations in the normal anatomy of the collateral ligament complexes of the elbow joint are frequent. These variations may have functional and surgical considerations and it is important that surgeons are aware of them.

#### REFERENCES

- BASS RL, STERN PJ (1994) Elbow and forearm anatomy and surgical approaches. *Hand Clinics* **10**, 343–356.
- BRYCE TH (1915) *Quain's Elements of Anatomy*, 11th edn, vol. 4, pp. 241–242. London: Longmans, Green.
- CALLAWAY GH, FIELD LD, DENG XH, TORZILLA PA, O'BRIEN SJ, ALTCHER DW et al. (1997) Biomechanical evaluation of the medial collateral ligament of the elbow. *Journal of Bone and Joint Surgery* **79A**, 1223–1231.
- COHEN MS (1997) Rotatory instability of the elbow. The anatomy and role of the lateral stabilizers. *Journal of Bone and Joint Surgery* **79A**, 225–233.
- FUSS FK (1991) The ulnar collateral ligament of the human elbow joint: anatomy, function and biomechanics. *Journal of Anatomy* **175**, 203–212.
- GRAY H (1858) *Anatomy: Descriptive and Surgical*, 1st edn, pp. 161–162. London: John W. Parker and Son.
- MARTIN BF (1958) The annular ligament of the superior radio-ulnar joint. *Journal of Anatomy* **92**, 473.
- MORREY BF, AN KN (1983) Articular and ligamentous contributions to the stability of the elbow joint. *American Journal of Sports Medicine* **11**, 315–319.
- MORREY BF, AN KN (1985) Functional anatomy of the ligaments of the elbow. *Clinical Orthopaedics and Related Research* **201**, 85–89.
- O'DRISCOLL SW (1994) Elbow instability: a spectrum of disability. *Hand Clinics* **10**, 405–415.
- O'DRISCOLL SW, BELL DF, MORREY BF (1991) Posterolateral rotatory instability of the elbow. *Journal of Bone and Joint Surgery* **73A**, 440–446.
- O'DRISCOLL SW, JALOZYNSKI R, MORREY BF, AN KN (1992*a*) Origin of the medial ulnar collateral ligament. *Journal of Hand Surgery* **17A**, 164–167.
- O'DRISCOLL SW, HORII E, MORREY BF, CARMICHAEL SW (1992*b*) Anatomy of the ulnar part of the lateral collateral ligament of the elbow. *Clinical Anatomy* **5**, 296–303.
- OLSEN BS, SØBJERG JO, DALSTRA M, SNEPPEN O (1996*a*) Kinematics of the lateral ligamentous constraints of the elbow joint. *Journal of Shoulder and Elbow Surgery* **5**, 333–341.
- OLSEN BS, VAESSEL MT, JENS O, SØBJERG JO, HELMIG P, SNEPPEN O (1996*b*) Lateral collateral ligament of the elbow joint: anatomy and kinematics. *Journal of Shoulder and Elbow Surgery* **5**, 103–112.
- OLSEN BS, SØBJERG JO, NIELSEN KK, VAESSEL MT, DALSTRA M, SNEPPEN O (1998) Posterolateral elbow joint instability: the basic kinematics. *Journal of Shoulder and Elbow Surgery* **7**, 19–29.
- PAUCHET V, DUPRET S (1928) *A Pocket Atlas of Anatomy*, 3rd edn. Oxford: Oxford University Press.
- SAFRAN MR (1995) Elbow injuries in athletes: a review. *Clinical Orthopaedics and Related Research* **310**, 257–277.
- SCHWAB GH, BENNETT JB, WOODS GW, TULLOS HS (1980) Biomechanics of elbow instability: the role of the medial collateral ligament. *Clinical Orthopaedics and Related Research* **146**, 42–51.
- SHARPEY W, THOMSON A, CLELAND J (1867) *Quain's*

- Elements of Anatomy*, 7th edn, vol. 1, pp. 140–141. London: James Walton.
- SØBJERG JO, OESON J, NIELSON S (1987) Experimental elbow instability after transection of the medial collateral ligament. *Clinical Orthopaedics and Related Research* **218**, 186–90.
- STROYAN M, WILK KE (1993) The functional anatomy of the elbow complex. *Journal of Sports and Physical Therapy* **17**, 279.
- TULLOS HS, SCHWAB G, BENNET JB, WOODS GW (1981) Factors influencing elbow instability. *Instructional Course Lectures* **30**, 185–199.
- WILLIAMS PL, WARWICK R, DYSON M, BANNISTER LH (1989) *Gray's Anatomy*, 37th edn, pp. 406–413; 505–507. Edinburgh: Churchill Livingstone.
- WOOD-JONES F (1949) *Buchanan's Manual of Anatomy*, 8th edn, pp. 514–515. London: Baillière, Tindall and Cox.