

Surgical anatomy of the sural and superficial fibular nerves with an emphasis on the approach to the lateral malleolus

L. B. SOLOMON¹, L. FERRIS², R. TEDMAN³ AND M. HENNEBERG³

¹ Department of Orthopaedics, Alice Springs Hospital, Australia, and Department of Anatomy and Orthopaedics, University of Sibiu, RO, ² Wakefield Orthopaedic Clinic, Adelaide, and ³ Department of Anatomical Sciences, Adelaide, Australia

(Accepted 28 August 2001)

ABSTRACT

The aim of this study was to investigate the risk and to analyse the significance of laceration of the sural and superficial fibular nerves during the surgical approach to the lateral malleolus. The sural and the superficial fibular nerves, and their branches were dissected under $\times 3$ magnifying lenses in 68 embalmed leg-ankle-foot specimens. The specimens were measured, drawn and photographed. In 35% of specimens the superficial fibular nerve branched before piercing the crural fascia, and in all these specimens the medial dorsal cutaneous nerve of the foot was located in the anterior compartment while the intermediate dorsal cutaneous nerve of the foot was located in the lateral compartment. In 35% of specimens the intermediate dorsal cutaneous nerve of the foot was absent or did not innervate any toe. The deep part of the superficial fibular nerve was in contact with the intermuscular septum. Its superficial part was parallel with the lateral malleolus when the nerve pierced the fascia more proximally and oblique to the lateral malleolus when the nerve pierced the fascia distally. In one case the intermediate dorsal cutaneous nerve of the foot was in danger of laceration during a subcutaneous incision to the lateral malleolus. In 7 cases (10%) the sural nerve overlapped or was tangent to the tip of the malleolus. Malleolar nerve branches were identified in 76% of the cases (in 28% from both sources). The sural nerve supplies the lateral 5 dorsal digital nerves in 40% of cases. Our study indicates that during the approach to the lateral malleolus there is a high risk of laceration of malleolar branches from both the sural and the superficial fibular nerves. There is less risk of damage to the main trunk of these nerves, but the 10% chance of laceration of sural nerve at the tip of the malleolus is significant. As the sural nerve supplies the superficial innervation to the lateral half of the foot and toes in 40% of cases, the risk of its laceration is even more important than indicated by the common anatomical teaching.

Key words: Lateral malleolus; sural nerve; superficial fibular nerve.

INTRODUCTION

The fracture of the lateral malleolus is one of the most common types of fractures and most malleolar fractures are treated operatively. The sural and the superficial fibular nerves are recognised as at risk during the approach to the lateral malleolus (Hoppenfeld & de Boer, 1994).

The sural nerve becomes superficial in the proximal part of the leg and descends lateral to the calcaneal tendon to the region between the lateral malleolus and

the calcaneus. After innervating the posterior and lateral part of the distal third of the leg, it continues its course on the lateral side of the foot to the lateral aspect of the little toe (Williams et al. 1989). Although the sural nerve has a constant topographical localisation, anatomical variation is frequent, and 4 patterns are described (Benjamin et al. 1995). The sural nerve has close relations in with the small saphenous vein (Williams et al. 1989; Murakami et al. 1994) and sural nerve damage (nerve tear, neuroma and scar inclusion) was reported after small saphenous

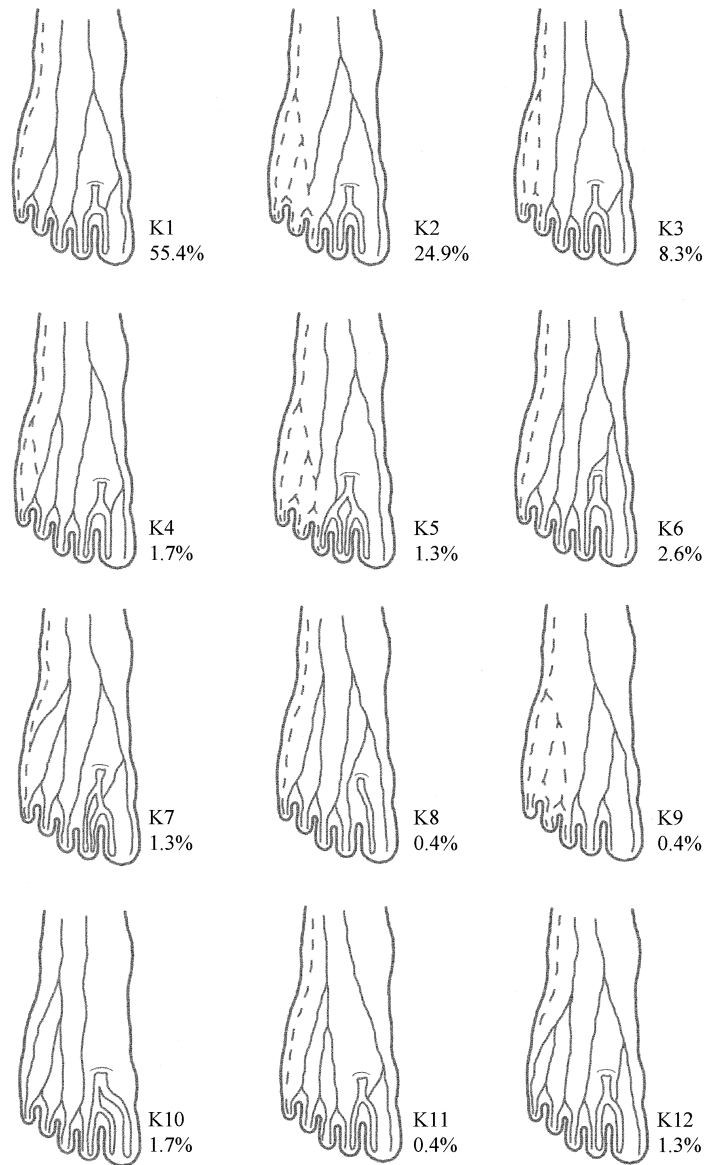


Fig. 1. The variation in the distribution of the cutaneous nerves of the dorsum of the foot in the series of 229 feet reported in 1892 and known as Kosinski's variants. The sural nerve is marked by the dotted line. The double line marks the deep fibular nerve. The medial dorsal cutaneous nerve of the foot and the intermediate dorsal cutaneous nerve of the foot are marked by a continuous line.

nerve stripping (Mondelli et al. 1997; Simonetti et al. 1999). The superficial fibular nerve, also known as the superficial peroneal nerve, becomes superficial in the distal third of the leg and divides into medial and lateral branches. The medial branch, known as the medial dorsal cutaneous nerve of the foot, divides into 2 dorsal digital nerves for the medial side of the hallux and the second interdigital space. The lateral branch, which is smaller and is known as the intermediate dorsal cutaneous nerve of the foot, supplies the skin of the lateral aspect of the foot as well as the digital nerves to the contiguous sides of the third to fifth toes. This lateral branch is also responsible for the innervation of the lateral aspect of the ankle and is usually anastomosed with the sural nerve (Williams et

al. 1989). A report of the Committee of Collective Investigation of the Anatomical Society of Great Britain and Ireland (1892), known today as Kosinski's classification (Kosinski, 1926; Canovas et al. 1996), compiled the results of dissection of 226 feet and described 12 patterns of termination of the dorsal nerves of the foot stressing the great variability of these nerves (Fig. 1).

MATERIALS AND METHODS

We performed dissection on 68 cadaver leg-ankle-foot specimens. All the specimens were embalmed for the Ray Last laboratory (dissecting room) of the De-

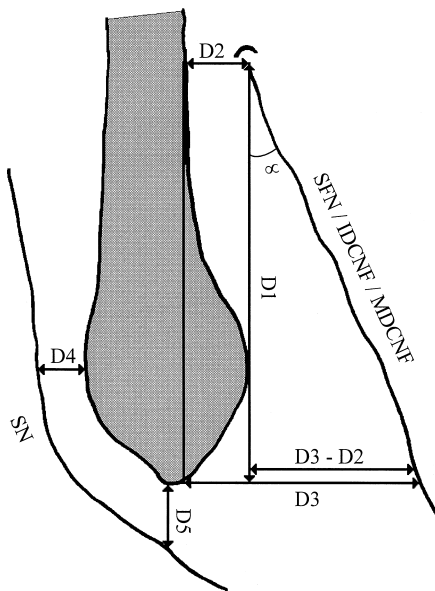


Fig. 2. Schematic drawing of the distances measured for the superficial fibular nerve and the sural nerve. D1, distance from the superficial fibular nerve, or its most lateral terminal branch, penetration of the crural fascia to the tip of the malleolus; D2, distance from superficial fibular nerve, or its most lateral terminal branch, penetration of the crural fascia to the anterior margin of the lateral malleolus; D3, distance between the superficial fibular nerve, or its most lateral terminal branch, and the tip of the lateral malleolus; D4, distance between the sural nerve and the most prominent posterior part of the lateral malleolus; D5, the distance between the sural nerve and the tip of the lateral malleolus; SFN, superficial fibular nerve; IDCNF, intermediate dorsal cutaneous nerve of the foot; MDCNF, medial dorsal cutaneous nerve of the foot; SN, sural nerve; α , angle formed by the superficial fibular nerve, or its most lateral terminal branch, and the lateral malleolus.

partment of Anatomical Sciences of the University of Adelaide and kept at 4 °C for at least 6 mo prior to dissection.

After skin removal, the trunk of the sural nerve was identified in the subcutaneous tissue behind the lateral malleolus and the superficial fibular nerve, or its main branches, in front of the malleolus. These nerves were then carefully dissected proximally to the origin of the sural and superficial fibular nerves, and distally to their terminal digital branches. Three times magnifying surgical lenses were used to aid the dissection.

The following data were recorded: (1) the position of the superficial fibular nerve in the lateral and anterior compartments of the leg and its relationship with the fibular muscles and the intermuscular septum; (2) the distance from the superficial fibular nerve penetration of the deep fascia to the tip of the malleolus (D1); (3) the distances between the superficial fibular nerve and the lateral malleolus at the level of penetration of the deep fascia (D2) and at the distal end of the malleolus (D3); (4) the distance between the most prominent posterior part of the lateral

malleolus and the sural nerve (D4); (5) the distance between the tip of the lateral malleolus and the sural nerve (D5) (Fig. 2); and (6) the peripheral distribution of the sural and fibular nerves (Fig. 3). The specimens were photographed with a Sony Mavica digital camera for further review. The nerve pattern, distribution and relationship with the lateral malleolus were drawn on foot diagrams.

RESULTS

All the superficial fibular nerves and their branches were identified anterior to the lateral malleolus. In all the samples the deep part of the superficial fibular nerve or its branches exited the fibular muscles in the proximal third of the leg and passed down to the distal half of the shin in contact with the posterior aspect of the antero-lateral intermuscular septum. In 24 cases (35%) the superficial fibular nerve branched into the medial dorsal cutaneous nerve of the foot and the intermediate dorsal cutaneous nerve of the foot before piercing of the crural fascia (Fig. 4). In all these cases the medial dorsal cutaneous nerve of the foot pierced the intermuscular septum to pass in the anterior compartment of the leg and was placed on the anterior surface of the intermuscular septum. Fine muscular branches emerged from all the medial dorsal cutaneous nerves of the foot located in the anterior compartment to innervate the extensor digitorum longus and the extensor hallucis longus. In all but 4 cases out of the 24 that presented a deep division of the superficial fibular nerve the medial dorsal cutaneous nerve of the foot became superficial proximal to the intermediate dorsal cutaneous nerve of the foot.

In 24 cases (35%) there was either no intermediate dorsal cutaneous nerve of the foot as a branch of the superficial fibular nerve or, in 10 of these cases, the nerve terminated before branching in to digital nerves. Six out of these 10 were in specimens with deep branching of the superficial fibular nerve (Fig. 4).

The superficial fibular nerve or the intermediate dorsal cutaneous nerve of the foot pierced the crural fascia at 91 ± 23 mm proximal to the tip of the lateral malleolus. The nerve was located at 3 ± 3 mm anterior to the anterior margin of the fibula at the level of its hiatus and at 23 ± 8 mm anterior to the margin of the malleolus at the level of the tip of the lateral malleolus. At the level of the ankle joint the superficial fibular nerve, or the most lateral of its terminal branches, passed towards the foot over the extensor digitorum longus or just lateral to the muscle. As a rule, once the superficial fibular nerve becomes superficial it runs

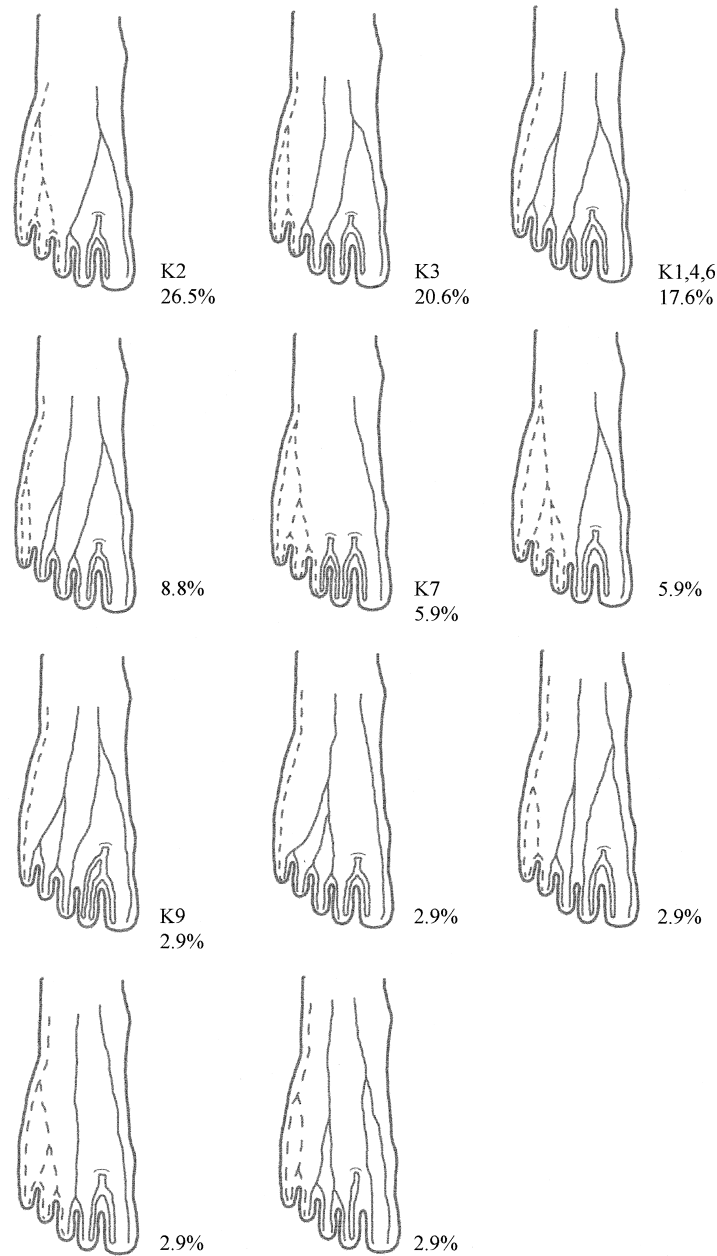


Fig. 3. The variation in the distribution of the cutaneous nerves of the dorsum of the foot found in our series of 68 feet. K followed by the number of the variant marks Kosinski's variants. The variants that are marked only by the incidence have not been described in Kosinski's variants. The sural nerve is marked by the dotted line. The double line marks the dorsal cutaneous nerve of the foot. The medial dorsal cutaneous nerve of the foot and the intermediate dorsal cutaneous nerve of the foot are marked by the continuous line.

away from the malleolus and in only one case did the intermediate dorsal cutaneous nerve of the foot have its whole superficial leg course (85 mm) overlying the distal fibula and the lateral malleolus. The more distal the nerve becomes superficial, the bigger is the angle that it forms with the fibula.

In 40 cases (59%) we could identify cutaneous branches of the superficial fibular nerve or the intermediate dorsal cutaneous nerve of the foot supplying the malleolar skin and crossing a direct incision to the lateral malleolus. The same was true for

the sural nerve. In 28 cases (41%) malleolar cutaneous branches of both the sural nerve and the superficial fibular nerve were encountered.

The sural nerve was found in contact with the most posterior aspect of the lateral malleolus in 14 cases (21%). In 7 of these cases (10%) the nerve was also in contact with the distal aspect of the tip of the lateral malleolus (Fig. 5).

The peripheral toe innervation and the patterns of toe nerve distribution as identified in our dissection are presented in Figures 3 and 6.

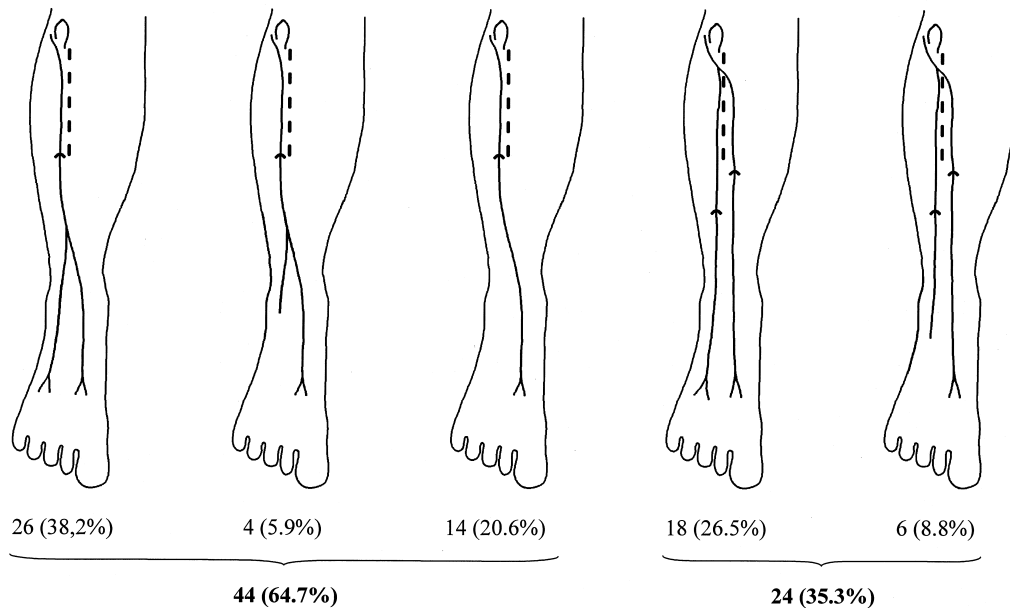


Fig. 4. The compartmental localisation and the peripheral distribution of the superficial fibular nerve. The superficial fibular nerve is marked with a continuous line. The intercompartmental septum between the anterior and the lateral compartments of the leg is marked with the dotted line. In 65% of cases the superficial fibular nerve divided after piercing the crural fascia. In 35% of cases the superficial fibular nerve divided deep to the crural fascia and in all these cases the medial cutaneous nerve of the foot had most of its course in the anterior compartment. In 21% of cases there was no lateral cutaneous nerve of the foot and in 15% of cases this nerve resolved before branching in digital nerves.

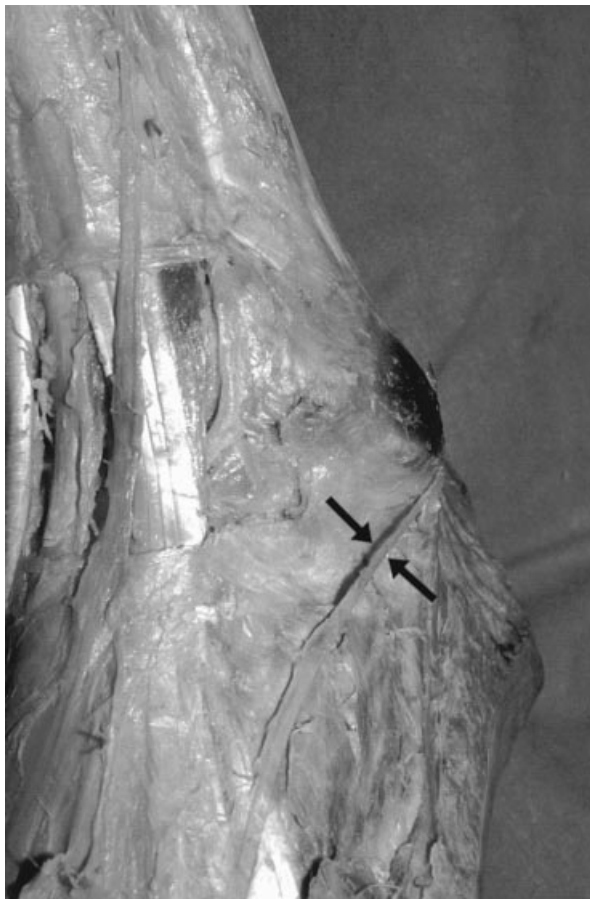

Fig. 5. Sural nerve (arrows) tangent to the tip of the lateral malleolus. In this case the sural nerve supplies the lateral half of the foot and toes.

DISCUSSION

Even though recognised at risk during surgery (Hoppenfeld & de Boer, 1994) there are minimal data in the literature about the quantification of the risk to damage of the superficial nerves surrounding the lateral malleolus (Blair & Botte, 1994), apart from their close relationship described in the anatomical textbooks.

Great variability was described in both the deep course (Kosinski, 1926; von Reinman, 1984; Blair & Botte, 1994; Benjamin et al. 1995) and the peripheral toe distribution (Brodie et al. 1892; Kosinski, 1926) of the sural and superficial fibular nerves. These facts would suggest that during the approach to the lateral malleolus a careful dissection is required in order to isolate and protect the variable branches of these nerves.

Because the malleolar branches of the sural and superficial fibular nerves have an oblique or transverse course and are of small diameter, they would be rather difficult to identify during the exposure of the fracture, and are probably damaged. The cumulative incidence of malleolar branches (76%) suggests a high risk of damaging some during the approach. The significance of laceration of the malleolar branches is difficult to estimate. The dual supply of the malleolar branches from both the sural and the superficial fibular nerves, as well as the frequent anastomosis between them

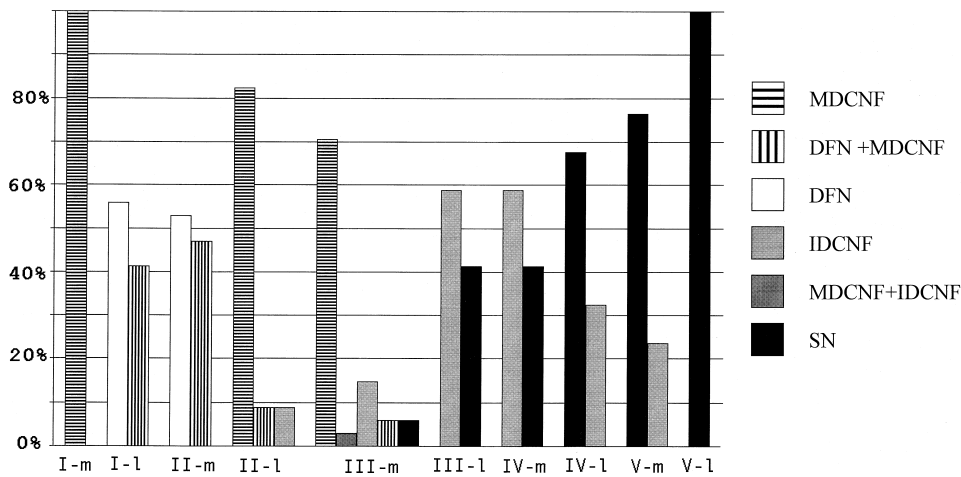


Fig. 6. The dorsal toe innervation as identified in our specimens. The toes are labelled with Roman numerals. The medial side of every toe is marked 'm' and the lateral side of every toe is marked 'l'. MDCNF, medial dorsal cutaneous nerve of the foot; DFN, deep fibular nerve; IDCNF, intermediate dorsal cutaneous nerve of the foot; SN, sural nerve.

suggests that anaesthetic malleolar areas should not develop after surgery.

The toe distribution pattern of the sural and superficial fibular nerves (Fig. 6) indicates that, if one of these nerves is damaged during surgery, the distal anaesthetic area can be extremely variable. Our dissections demonstrated 11 anatomical variations in the dorsal toe innervation (Fig. 3). Unlike Kosinski we ignored the various patterns of anastomosis between the digital branches which would have brought our variants to 14. Considering these, we identified 8 of the 12 variations described by Kosinski (1926) and we described 5 new ones. The most common variation we encountered was Kosinski's type II in 27% in which the lateral 2.5 toes are innervated by the sural nerve. In Kosinski's report this type II variant was found in 24%, while the most common variant was type I, which together with the very similar variants IV and VI had a total incidence of 62% (55% + 4% + 3%). In our series, these types I, IV and VI, which correspond to the description given at the beginning of our paper, were found in 18%.

The sural nerve was located at an average of 7 ± 5 mm posterior to lateral malleolus. The only place where the sural nerve contacted the posterior border of the lateral malleolus was at the level of its most posterior aspect where usually no retraction is necessary during surgery. The sural nerve was also located at an average of 13 ± 7 mm distal to the tip of the lateral malleolus. However, in 7 of the specimens the nerve was tangent to or crossed the distal tip of the malleolus. In these cases the sural nerve could easily be lacerated during exposure of the distal part of the lateral malleolus. In 4 specimens an anastomosis

between the sural nerve and the intermediate dorsal cutaneous nerve of the foot was tangent to the tip of the lateral malleolus. In none of these cases could we trace any of the anastomosing fibres to the digital nerves.

The superficial fibular nerve can be damaged in both its subcutaneous and deep segments. In its superficial part the nerve can be transected if it is located along the skin incision. If the skin incision is made closer to the anterior margin of the malleolus there is an increased risk to lacerate the superficial fibular nerve/intermediate dorsal cutaneous nerve of the foot as it penetrates the crural fascia.

The superficial fibular nerve or the intermediate dorsal cutaneous nerve of the foot were found to pierce the crural fascia, anterior to the margin of the malleolus, at 3 ± 3 mm. In 18 of the cases the nerve pierced the crural fascia at the level of the anterior margin of the malleolus which made it more vulnerable. The more distal the nerve pierces the fascia the greater the angle of its superficial path to the malleolus (and thus away from the surgical field). As a consequence, the more distal the nerves pierce the fascia the less likely it is that they will be damaged during the skin and subcutaneous tissue incision. Conversely, the more proximal the nerves pierce the fascia the more likely it is that their course will stay more parallel with the fibula and thus the more likely it is that they can be damaged by an incision located anterior to the middle of the malleolus.

Deep to the fascia, the superficial fibular nerve, or its lateral compartment branches, are located in the vicinity of the intermuscular septum. As in most instances the fibular tendons, and/or muscles, are retracted posteriorly to expose the bone, the nerve is

easily exposed. The more proximal the nerve exits the deep compartment the less the chances to lacerate it in its deep portion. Vice versa, the more distal the nerve becomes superficial the greater the need to protect it in its deep part, from retractor compression.

In our series, 24 (35%) of the specimens had the medial dorsal cutaneous nerve of the foot located in the anterior compartment. This, together with the more medial location of the nerve in its superficial part, makes this nerve less vulnerable to laceration. Adkinson et al. (1991) reported that 14% of 85 legs had the superficial fibular nerve located in the medial compartment and that in 12% of cases the superficial fibular nerve divided deep to the deep fascia in the lateral compartment and then the medial dorsal cutaneous nerve of the foot passed into the anterior compartment. In our series there were no cases where the whole trunk of the superficial fibular nerve was located in the anterior compartment. Our findings correspond to those described by von Reimann (1984) who describes a *nervus peroneus superficialis accessorius* in 10% (14 of 140) of his specimens. The accessory superficial peroneal nerve is described as a deep branch of the superficial fibular nerve located in the anterior compartment of the leg that terminated as the medial dorsal cutaneous nerve of the foot.

The anterior compartment location of the superficial fibular nerve makes it less susceptible to being lacerated during the approach to the lateral malleolus. However, this location of the superficial fibular nerve or the medial dorsal cutaneous nerve of the foot should be remembered to avoid confusions in the signs of the compartment syndromes of the leg.

Another variant of the superficial fibular nerve with more practical implications in the approach to the lateral malleolus is that described by Blair & Botte (1994). These authors reported that in 16% of 25 cases the nerve branched deep and the medial dorsal cutaneous nerve of the foot pierced the fascia anterior to the lateral malleolus while the intermediate dorsal cutaneous nerve of the foot pierced the fascia posterior to the lateral malleolus and then crossed the bone to follow its course towards the dorsum of the foot. This type of branching is particularly important in the approach to lateral malleolus because this will invariably interfere with the nerve.

In none of our specimens did we encounter the following variant: superficial fibular nerve located in the anterior compartment; intermediate dorsal cutaneous nerve of the foot crossing the lateral malleolus.

Because the reported incidence of the different patterns of branching of the superficial fibular nerve varies significantly we question a possible difference between various populations in the constitution and distribution of the superficial fibular nerve and possible other anatomical structures. Also, as the peripheral distribution of the dorsal nerves of the foot in this series varies significantly from that described last century, we suggest a possible microevolution change in these nerves similar to that found for the median artery (Henneberg & George, 1992*a, b*, 1995).

REFERENCES

- ADKINSON DP, BOSSE MJ, GACCIONE DR, GABRIEL KR (1991) Anatomical variations in the course of the superficial peroneal nerve. *Journal of Bone and Joint Surgery* **73A**, 112–114.
- BENJAMIN AC, TUMA-JUNIOR P, GRILLO MA, FERREIRA MC (1995) *Revista do Hospital das Clinicas Faculdade de Medicina de Sao Paulo* **50**, 25–29.
- BLAIR JM, BOTTE MJ (1994) Surgical anatomy of the superficial peroneal nerve in the ankle and foot. *Clinical Orthopaedics and Related Research* **305**, 229–238.
- BRODIE G, SHAW EH, MACLEOD P, HARRIS WA, FAWCETT E et al. (1892) Collective investigation on the distribution of cutaneous nerve of the dorsum of the foot. *Journal of Anatomy and Physiology* **26**, 89–90.
- CANOVAS F, BONNEL F, KOULOUMDJIAN P (1996) The superficial peroneal nerve at the foot. Organisation, surgical applications. *Surgical & Radiological Anatomy* **18**, 241–244.
- HENNEBERG M, GEORGE BJ (1995) Possible secular trend in the incidence of anatomical variant: median artery of the forearm. *American Journal of Physical Anthropology* **96**, 329–334.
- HENNEBERG M, GEORGE BJ (1992*a*) High incidence of the median artery of the forearm in a sample of recent cadavers. *Journal of Anatomy* **180**, 185–188.
- HENNEBERG M, GEORGE BJ (1992*b*) A further study of the high incidence of the median artery of the forearm in Southern Africa. *Journal of Anatomy* **181**, 151–154.
- HOPPENFELD S, DE BOER P (1994) *Surgical Exposures in Orthopaedics*. Philadelphia: Lippincott.
- KOSINSKI C (1926) The course, mutual relations and distribution of the cutaneous nerves of the metatarsal region of the leg and foot. *Journal of Anatomy and Physiology* **60**, 274–297.
- MONDELLI M, REALE F, CAVALLARO T (1997) Neuroma of the sural nerve as a complication of stripping of the small saphenous vein. *Surgical Neurology* **48**, 330–332.
- MURAKAMI G, NEGISHI N, TANAKA K, HOSHI H, SEZAI Y (1994) Anatomical relationship between saphenous vein and cutaneous nerves. *Okajimas Folia Anatomica Japonica* **71**, 21–33.
- SIMONETTI S, BIANCHI S, MARTOLINI C (1999) Neurophysiological and ultrasound findings in sural nerve lesions following stripping of the small saphenous vein. *Muscle and Nerve* **22**, 1724–1726.
- VON REINMAN R (1984) Überzählige Nervi peronei beim Menschen. *Anatomischer Anzeiger* **155**, 257–267.
- WILLIAMS PL, WARWICK R, DYSON M, BANNISTER LH (1989) *Gray's Anatomy*, 37th edn Edinburgh: Churchill Livingstone.