

Anhidrotic Ectodermal Dysplasia: Autosomal Dominant Inheritance with Palate and Lip Anomalies

ROBERT S. RAPP and WILLIAM E. HODGKIN

From Pediatric Service, Madigan General Hospital, Tacoma, Washington, U.S.A.

Ectodermal dysplasia involves faulty development of embryonic ectoderm and its subsequent derivatives. Cockayne (1933) described 200 defects of ectodermal origin. It has been suggested that cases fall into two clinical and genetical groups (Weech, 1929). The hidrotic form appears usually to be determined by an autosomal dominant gene and the anhidrotic (or hypohidrotic) form by an X-linked recessive gene mutation. However, there are clinical differences, other than ability to sweat, that characterize the two groups of cases. This paper reports a mother and her son and daughter, all with diminished capacity to sweat and all with hare-lip and cleft palate.

Case Reports

Case 1. III. 5 in the pedigree (Fig. 1) is a 30-year-old Caucasian female with a history of inability to sweat, slow hair growth, and poor dental development. An unexplained rise in temperature was noted at 3 days of age. This seems to be the precursor of a pattern of frequent headaches, dizziness, and fatigue whenever environmental temperature increased or vigorous physical activity was required.

Considerable coarse, wiry scalp hair was present at birth. Subsequent hair growth was slow, with little improvement in quality, and a wig was purchased at the age of 13 for cosmetic purposes. General body hair has been sparse with the exception of normal pubic hair.

At 11 years of age, because of numerous caries and a decreased number of teeth, she was fitted with a full set of dentures. Only one half the number of expected teeth were present. No mention is made of abnormally shaped or positioned teeth. A unilateral (left) cleft palate, with no lip involvement, and disfigured nails on all digits were noted at birth. A poorly defined thyroid disorder requiring 'up to six grains of thyroid per day' was described during adolescence. It has been of no

consequence since and no further information is available regarding it.

Physical Examination. This revealed an obese woman in apparent good health. Her head showed mild frontal bossing, with minimal depression of the nasal bridge; however, her profile was not characteristic of X-linked hypohidrotic ectodermal dysplasia. Pseudorhages were noted at the mouth corners but none at the naso-labial fold. The scalp was shaved as a wig was worn. Eyebrows were absent laterally and sparse growth was present medially. Eyelashes were sparse and the tarsal plate was red and inflamed. No axillary or pubic hair was present. Little hair growth was present on the rest of the body. A full set of dentures and evidence of a repaired (left) cleft palate were noted in the mouth. The nails were dystrophic, with distal soft tissue tufting on all digits; they were disfigured, small, and had no longitudinal fissuring. The breasts were fully developed. The remaining physical examination was within normal limits.

Laboratory data. The white blood cell count (WBC) was 5600 per cu.mm., with 61 neutrophils, 33 lymphocytes, 2 monocytes, 4 eosinophils, and 0.5% reticulocyte. The haematocrit was 39% and haemoglobin 13.4 g./100 ml. Total platelet count was 268,000/ml. The protein-bound iodine was 5.6 μ g./100 ml. An audiogram showed a 30 decibel conductive type hearing loss.

Case 2. IV. 1 the daughter of III. 5, age 6, the oldest of 3 sibs was the product of a normal pregnancy and delivery. Since birth she has had short, slow-growing, wiry hair which has been difficult to manage. Dental development has been slow, and she possesses only 7 teeth all of which are carious. The incisors are short and square shaped. Sweat production has been noted over her back and posterior neck. Little difficulty with hyperthermia has been encountered in warm weather and she has no limitation of her activities. Disfigured nails are present on all fingers and toes. Plastic surgeons have described a short soft palate with no uvula and a marked limitation of motion. This has been documented with cinefluoroscopic examination.

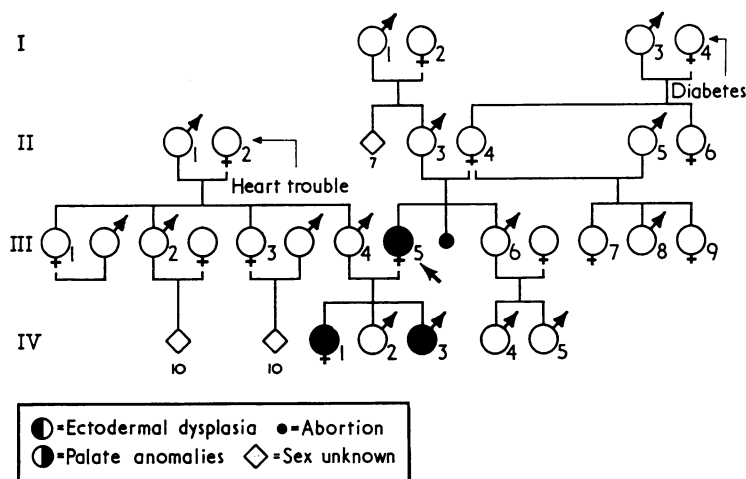


FIG. 1. Pedigree of kindred.

Physical Examination. Examination of the head revealed minimal frontal prominence, with a mildly depressed nasal bridge. No pseudorhages were present at the mouth or naso-labial fold. The uvula was absent, and soft palate tissue was scant. Square-shaped, worn upper canine teeth were present. Four lower incisors were carious and worn. Her hair was coarse, short, and wiry. Eyebrows were scant and eyelashes sparse. All nails were small and misshapened. There were no fissures or soft tissue tufting.

Case 3. IV. 3 the brother of IV. 1, age 20 months, was the product of a normal pregnancy and delivery. Hair growth was slow on the scalp, eyelashes, and eyebrows. Dental development was slow as only 7 teeth were present. He sweated on his back, forehead, and neck, and hyperthermia was a minimal problem. Episodes of purulent conjunctivitis were frequent.

Physical Examination. Examination revealed a well-nourished child in good health. The forehead was prominent, with mild depression of nasal bridge. A left cleft lip (repaired) and bilateral cleft palate (repaired) were present. Seven teeth had erupted, which were all normally placed and shaped. The hair was coarse and wiry. Eyebrows were sparse laterally. The tarsal plate showed evidence of chronic inflammation. All nails were dystrophic, with marked soft tissue tufting.

Special Investigations

The affected subjects were tested in three ways.

Sweat Test (Iontophoresis Method). A sweat test was performed on the right and left forearm of all family members. This area normally contains 150-200 sweat glands per cubic centimetre (Kuno, 1956). Pilocarpine was the stimulating agent and the patient was subjected to 1.5 milliamp. current for 5 minutes. Total weight of sweat produced was measured.

Skin Biopsy. A 4 mm. skin biopsy was taken on III. 5 from an area adjacent to that previously stimulated by iontophoresis, to determine if sweat glands were absent or merely atrophic and non-functioning.

Raised Environmental Temperature. III. 5 and IV. 1 were then compared to a control in their ability to produce sweat in a raised environmental temperature. IV. 3 was not challenged. The indicator system chosen was described by Wagner (1952) and consisted of a solution containing 15 g. iodine, 100 ml. castor oil, and 900 ml. alcohol. This was painted on the skin and allowed to dry. A fine powdered potato starch was then carefully applied to the skin. Each subject was placed in a Sauna bath at a temperature of 82.2° C. and a relative humidity of 5%. Oral temperatures were recorded before and after exposure. The time required for sweat to appear was recorded for each subject. Exposure was terminated when symptoms consistent with hyperthermia appeared. Photographs of involved members were taken before and after exposure.

Results of Testing

The skin biopsy from the left forearm of III. 5 disclosed no hair follicles, sweat gland tubules, or abnormalities of collagen fibres. Lack of sweat glands and hair follicles is not pathognomonic of the syndrome but their absence in an area normally endowed with a plentiful supply is consistent with the clinical observation.

Stimulation of eccrine secretion with a routine sweat test yielded total secretion weighing less than 30 mg. in affected members. III.5 produced 20 mg., IV.1 20 mg., and IV.3 26 mg. sweat. IV. 1, the unaffected member, produced 90 mg. total sweat. Failure to produce adequate sweat

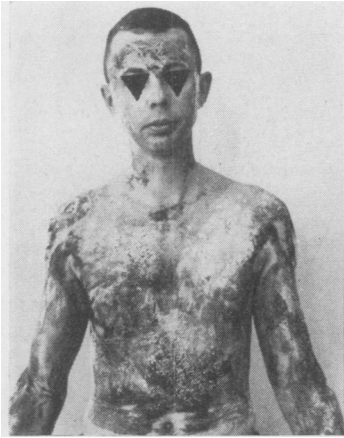

FIG. 2. Control after thermal stimulation.



FIG. 3. III. 5 after thermal stimulation shows perspiration under left breast.

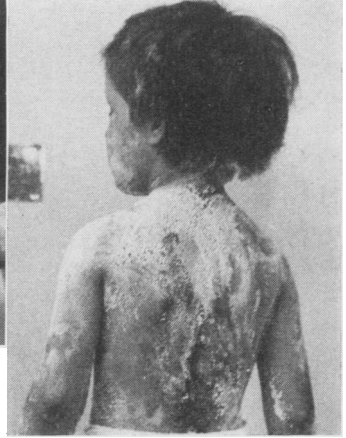

FIG. 4. IV. 1 after thermal stimulation.

volume after chemical stimulation represents another area in which physiological response is suboptimal.

Ecrrine stimulation by increasing environmental temperature showed in both subjects marked contrast in response as compared to a normal control (Fig. 2). The control experienced a temperature increase from 36° C. to 37° C., III. 5 from 37.2° C. to 37.8° C. and IV. 1 from 37.2° C. to 37.4° C. After 3 minutes exposure the control showed fine, black, pinpoint areas of sweat production, followed in one to two minutes by larger coalescing areas. At 7 minutes beads of sweat rolled down his face, neck, and chest, washing away the chemical indicator.

III. 5 showed 25–50 black pinpoint areas of colour change on the posterior neck at 3½ minutes. After 4 minutes of stimulation a fine black semi-circle, ½ × 4 cm., developed in the intertriginous area of her left breast, and a sharply circumscribed oval 1 × 1.5 cm. was noted at the medial aspect of her left wrist (Fig. 3). This area exhibited the most intense colour change. At no time did coalescing areas develop.

IV. 1 showed several areas of sweat production. Most noticeable was that over the right and left paravertebral musculature (Fig. 4). Additionally, sweat activity was apparent on the extensor surface of her hands and very minimally over her brow. Exposure was concluded for all persons at 10 minutes when III. 5 complained of occipital headache, dizziness, and fatigue.

Discussion

Many excellent reviews are available regarding

the clinical characteristics of anhidrotic ectodermal dysplasia (Helweg-Larsen and Ludvigsen, 1946; Upshaw and Montgomery, 1949; Marshall, 1958; Butterworth and Streat, 1962). Our intent is to focus on method of inheritance and the occurrence of palate and lip anomalies.

Hypohidrosis during raised environmental temperature, low sweat volume during pilocarpine stimulation, and lack of sweat glands in skin biopsy places this kindred in the hypohidrotic category. Cockayne (1933) described an X-linked recessive form in families with affected males. Helweg-Larsen and Ludvigsen (1946) stated that the anhidrotic variety with dominant inheritance was variably expressed. Upshaw and Montgomery (1949) concluded that the syndrome could be transmitted as a sex-linked recessive or autosomal dominant or recessive trait. Kerr, Wells, and Cooper (1966) felt that reported cases of dominant inheritance were 'recorded without adequate detail or were very atypical'.

Palatal and lip anomalies have not previously been reported with anhidrotic ectodermal dysplasia. Setleis *et al.* (1963) report a family with a midline scar beneath the lower lip. By description it was not a cleft lip and no mention is made of palatal anomalies.

III. 5, IV. 1, and IV. 3 (by history and pilocarpine stimulation) show full expression and concordance of the mutant gene or genes, and probably represent an autosomal dominant form of inheritance. From available information, no definitive statement can be made regarding ectodermal dysplasia and palate anomalies stemming from a single mutant gene or two genes.

Summary

A family manifesting hypohidrotic ectodermal dysplasia and anomalies of palate and lip is described. In the family there was no obvious difference in the trait in the mother, daughter, and son. An autosomal dominant form of transmission is postulated.

REFERENCES

- Cockayne, E. A. (1933). *Inherited Abnormalities of the Skin and its Appendages*. Oxford University Press, London.
- Butterworth, T., and Streat, L. P. (1962). *Clinical Genodermatology*. Williams and Wilkins, Baltimore.
- Helweg-Larsen, H. F., and Ludvigsen, K. (1946). Congenital familial anhidrosis and neurolabyrinthitis. *Acta. derm.-venereol. (Stockh.)*, **26**, 489.
- Kerr, C. B., Wells, R. S., and Cooper, K. E. (1966). Gene effect in carriers of anhidrotic ectodermal dysplasia. *J. med. Genet.*, **3**, 169.
- Kuno, Y. (1956). *Human Perspiration*. Thomas, Springfield, Illinois.
- Marshall, D. (1958). Ectodermal dysplasia: report of kindred with ocular abnormalities and hearing defect. *Amer. J. Ophthal.*, **45** (4 part II), 143.
- Setleis, H., Kramer, B., Valcarcel, M., and Einhorn, A. H. (1963). Congenital ectodermal dysplasia of the face. *Pediatrics*, **37**, 540.
- Upshaw, B. Y., and Montgomery, H. (1949). Hereditary anhidrotic ectodermal dysplasia; a clinical and pathological study. *Arch. Derm. Syph. (Chic.)*, **60**, 1170.
- Wagner, H. N. (1952). Electrical skin resistance studies in two persons with congenital absence of sweat glands. *ibid.*, **65**, 543.
- Weech, A. A. (1929). Hereditary ectodermal dysplasia (congenital ectodermal defect). *Amer. J. Dis. Child.*, **37**, 766.