

# Camptodactyly, Cleft Palate, and Club Foot

## A Syndrome Showing the Autosomal-dominant Pattern of Inheritance

HYMIE GORDON\*, DAVID DAVIES, and MERVYN BERMAN

*From the Comprehensive Medicine Group, Department of Medicine; the Plastic Surgery Unit, Department of Surgery; and the Department of Chemical Pathology: University of Cape Town, South Africa*

Camptodactyly is the name introduced by Landouzy (1906) for one of the varieties of constitutionally crooked digits. Camptodactyly almost always affects the fifth finger, the characteristic lesion being a flexion contracture of the proximal interphalangeal joint. The degree of flexion may vary from a very slight deformity to an almost right-angled bend; it is seldom more than this. The fourth to second fingers, in decreasing order of frequency, may be affected similarly, the extent of the deformity being progressively less in the more radial fingers. Often there is hyperextension of the metacarpophalangeal joints of the affected fingers, and occasionally the proximal interphalangeal joints of some fingers are also hyperextended. Rarely there is flexion deformity of the terminal interphalangeal joints as well. Involvement of the thumb is unusual. In advanced cases, there is ulnar deviation of the affected fingers, with radial rotation of the fifth finger, and the palm becomes cup-shaped. Longi-

tudinal bands of thickened palmar fascia may be seen or felt extending from the base of the middle phalanx into the palm. The toes are often affected with similar flexion and hyperextension deformities; in the advanced case the toes become crowded and overlap each other. Both in the hands and in the feet there is usually bilateral involvement, but the deformities are not usually symmetrical. The condition may be present from birth or it may first appear in early childhood. It runs a variable course of increasing deformity till about young adulthood, after which there is usually no further progression. Even in advanced cases, despite severe deformities, the degree of disability may be surprisingly little.

Camptodactyly may be sporadic or familial. In the latter, there is a simple autosomal dominant pattern of inheritance, with a high degree of penetrance but very variable phenotypic expression. In these genetic cases, camptodactyly is often the only lesion, but it may be associated with other connective tissue anomalies, or it may be a major or a minor component of a variety of complex syndromes. Table I indicates the conditions with which campto-

Received February 10, 1969.

\* Present address: Section of Statistics, Epidemiology and Population Genetics, Mayo Clinic, Rochester, Minn., U.S.A.

**TABLE I**  
CONDITIONS OR SYNDROMES WITH WHICH CAMPTODACTYLY MAY BE ASSOCIATED

Associated Condition or Syndrome	Inheritance Pattern*	Authors
Knuckle pads	AD	Garrod (1904); Welch and Temtamy (1966)
Bony outgrowths from the base of the 2nd metatarsals, occasionally with extra phalanges	AD	Neel and Rusk (1963)
Marfan's syndrome	AD	Marfan (1896); McKusick (1960)
Pectus excavatum, kyphoscoliosis, other skeletal anomalies, and ptosis	AD	Maurer (1938)
Recurrent dislocations of knee	AD	Murphy (1926)
Cranio-carpo-tarsal dystrophy (abnormal facies and skull, camptodactyly, and club foot)	AD	Freeman and Sheldon (1938); Welch and Temtamy (1966)
Oculo-dento-digital dysplasia (microphthalmia, enamel hypoplasia, camptodactyly, and occasionally cleft lip and palate)	?	Gorlin, Meskin, and St. Geme (1963b); Gillespie (1964)
Focal dermal hypoplasia (anomalies of the skin, teeth, eyes, and skeleton; digital anomaly is commonly syndactyly but camptodactyly may occur)	XD	Gorlin <i>et al.</i> (1963a)
Oral-facial-digital syndrome (hyperplasia of frenula, cleft palate; hypertelorism and flat maxillae; digital anomalies including camptodactyly)	XD	Dodge and Kernohan (1967)
Congenital absence of finger-prints	AD	Baird (1964)
Pterygium colli syndrome (short stature, pterygium colli, ptosis, vertebral anomalies, cleft palate, and camptodactyly)	AD or XD	Moldenhauer (1964)

\*AD, autosomal dominant; XD, X-linked dominant; ?, no known familial aggregation.

dactyly has been reported to be associated. The extreme degree of flexed, overlapping fingers, which is characteristic of the E-trisomy syndrome (Edwards *et al.*, 1960; Taylor, 1967) and which is also quite common in the D-trisomy syndrome (Patau *et al.*, 1960; Taylor, 1967), is quite different from the kind of deformity which we are considering; these chromosomal anomalies, therefore, have not been included in Table I.

The present report describes a family in which camptodactyly is a major component of a syndrome which also includes cleft palate and club foot. The pedigree shows the inheritance pattern of an autosomal gene with dominant effect and varying phenotypic expression. No record of a similar syndrome has been found in the literature available to us.

Parish, Horn, and Thompson (1963) reported a family in which a somewhat atypical form of camptodactyly was associated with an abnormal urinary constituent, probably on  $\alpha$ -amino acid. Nevin, Hurwitz, and Neill (1966) reported the presence of increased taurinuria in members of 4 families with typical camptodactyly. These observations of a biochemical abnormality accompanying a connective tissue disorder showing the autosomal dominant pattern of inheritance would, if confirmed, be of great importance. We have therefore investigated the urinary excretion of amino acids and taurine in members of the family who are the subjects of this report.

### Case Report

The *index case* (II.7 in Fig. 1) was a Cape Coloured male, 18 years old. He had written to us under an

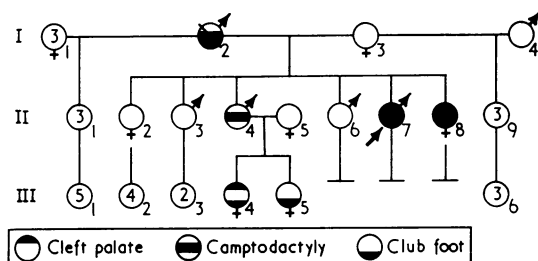


FIG. 1. Pedigree chart showing the near relatives of the index case (II.7). With the exception of I.2, all the individuals shown in this chart have been examined by us. I.2, father of the index case, was dead, but adequate clinical records were available.

assumed name to request advice because of his deformed hands and feet; other members of his family were similarly affected and his sister-in-law had recently given birth to a daughter with severely clubbed feet. He suspected that these deformities were inherited, and was concerned about the likelihood of their recurrence in his own children should he ever marry. He was interviewed and persuaded to discuss the matter with his mother. Through her it was possible to arrange for all the living first, second, and third degree relatives of the index case to be examined.

The index case was born after a normal pregnancy and delivery. He was his mother's eighth child; his mother and father were 28 and 44 years old respectively when he was born. At birth he had bent fingers, clubbed feet, a cleft palate, and undescended testes. During the first two years of his life his feet were repeatedly immobilized in plasters, but he was able to walk well by the time he was 18 months old. When he was 2 years old the cleft palate was repaired. At the age of 11 years he was operated on for undescended testes; the left testis was

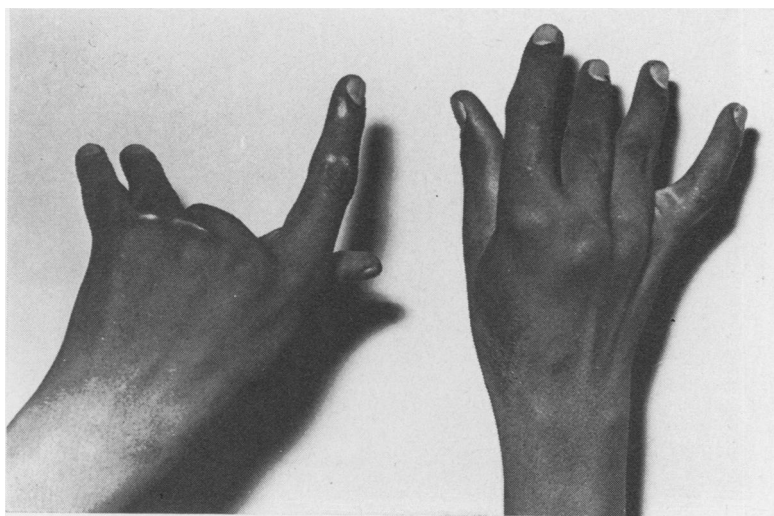


FIG. 2. The hands of the index case, dorsal view.

found to be atrophic and associated with an indirect inguinal hernia.

At the age of 18 years his general physical and mental development was good. Examination revealed a well-repaired cleft of the whole secondary palate, normal external genitalia with a normal right but an atrophic left testis, and extensive deformities of the hands and feet.

In both hands (Fig. 2 and 3) there was ulnar deviation of the third to fifth fingers with hollow palms and palpable longitudinal intra- and subcutaneous cords extending from the bases of the third to fifth proximal phalanges into the palms. The thumbs were unaffected. There was a slight flexion contracture of the proximal interphalangeal joint of the right index finger but not of

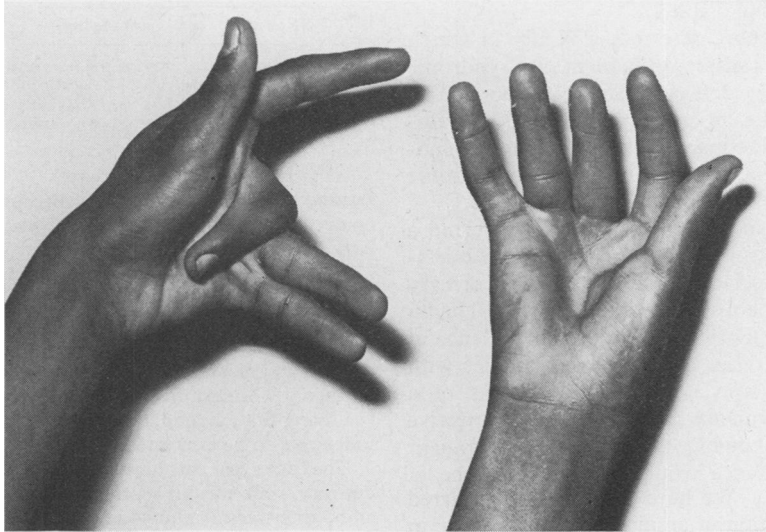


FIG. 3. The hands of the index case, palmar view. A band of subcutaneous thickening can be seen at the base of the left fifth finger.

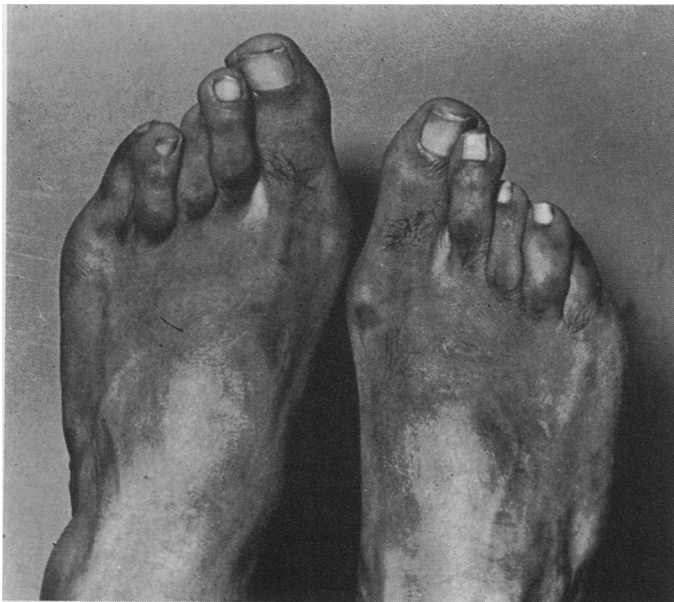

FIG. 4. The toes of the index case. There is flexion contracture of most of the proximal interphalangeal joints, hyperextension of several metatarsophalangeal joints, and overlapping toes.

the left. The right third finger was held in flexion at the metacarpophalangeal joint but could be extended passively almost completely; the proximal interphalangeal joint was slightly hyperextended. The left third finger was severely affected, with rigid right-angled flexion contractures of the metacarpophalangeal and proximal interphalangeal joints. Both fourth fingers were slightly flexed at the metacarpophalangeal joints and hyperextended at the proximal interphalangeal joints. Both

fifth fingers had slight flexion contractures of the proximal interphalangeal joints, the right being more affected. The right fifth metacarpophalangeal joint was flexed, the left one was hyperextended. Despite these rather grotesque deformities there was relatively little disability: he could write easily and worked in a factory as a clerk.

The deformities of his feet consisted of a slight degree of bilateral talipes equinovarus, and there was camptodactyly of several toes (Fig. 4). Both first toes were

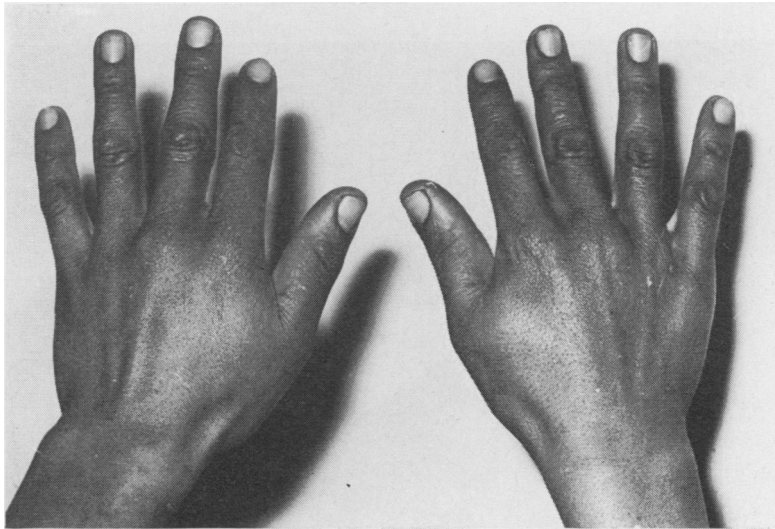


FIG. 5. Hands of the brother (II.4) showing very slight camptodactyly: flexion contracture of proximal interphalangeal joint of left fifth finger and hyperextension metacarpophalangeal joint of left third finger.

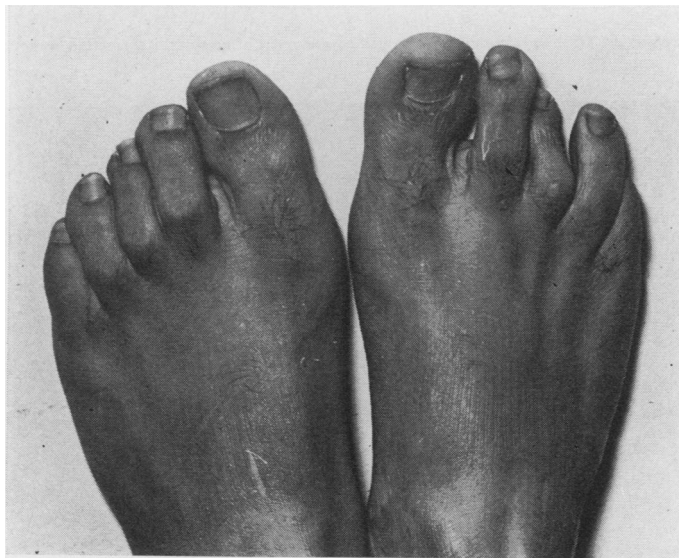

FIG. 6. The toes of the brother (II.4) showing flexion contractures of the proximal interphalangeal joints of several toes, most conspicuous in the right third toe.

normal. All the other toes on both feet were deformed, with hyperextension of the metatarsophalangeal joints and flexion contractures of the proximal interphalangeal joints. The toes were crowded, with the second toe overlapping the first and third toes and the fourth toe overlapping the fifth. He walked with a normal gait and wore ordinary shoes.

**Sibs.** An older sister (II.2) and two older brothers (II.3 and II.6) were normal. Another older *brother* (II.4; 22 years old) was regarded as normal by his

family, but examination revealed mild camptodactyly (Fig. 5 and 6). The proximal interphalangeal joints of his left fifth finger and of the second to fifth toes of both feet showed flexion contractures, with hyperextension of the metatarsophalangeal joints of most of the affected toes. He had neither a cleft palate nor clubbed feet. A younger *sister* (II.8) was severely affected. She was born with camptodactyly, cleft palate, and severe bilateral talipes equinovarus. During the first 6 years of her life she had several operations on her feet and at the age of 2 years her cleft palate was repaired. When she was

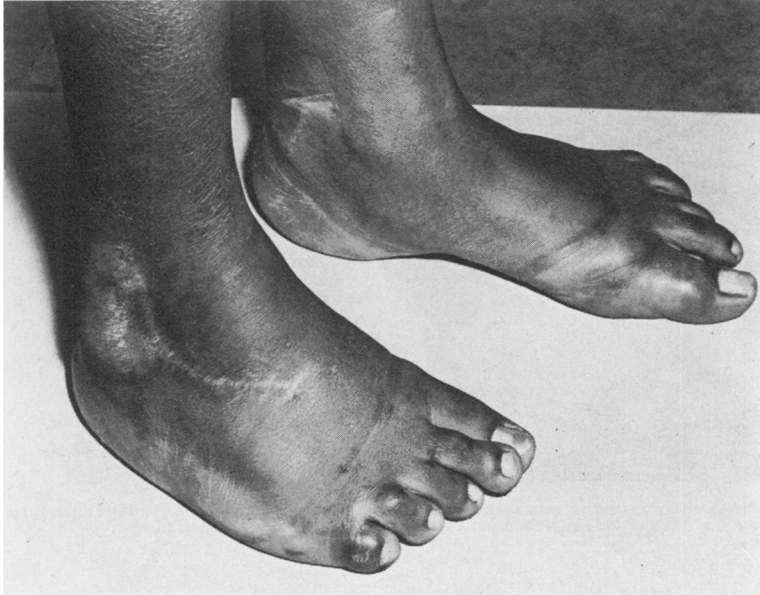

FIG. 7. The feet of the affected sister (II.8) showing residual talipes equinovarus after several corrective operations, and camptodactyly of several toes.

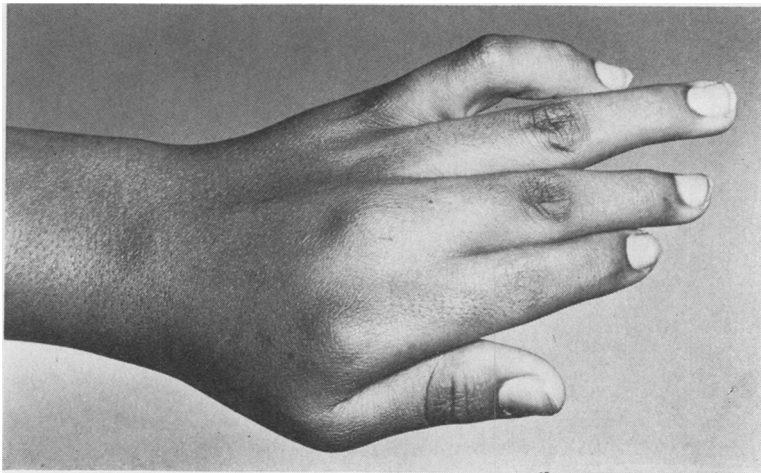


FIG. 8. Left hand of the affected sister (II.8) showing ulnar deviation and camptodactyly.

examined at the age of 16 years, her general physical and mental health was good. There was a well-repaired cleft of the whole secondary palate. The feet, especially the right, still showed some equinovarus deformity (Fig. 7). The camptodactyly was conspicuous, but not quite as severe as in the index case (Fig. 8). There was flexion contracture of the proximal interphalangeal joints of the fifth fingers and the fourth and fifth toes, hyperextension of the proximal interphalangeal joint of both fourth fingers, and ulnar deviation of the third to fifth fingers of both hands. The deformities caused little disability.

**Half-sibs.** There were three paternal half-sibs (II.1; two males and a female, the children of three different women) and three maternal half-sibs (II.9; two males and a female). All six were examined; no congenital anomalies were found.

**Father (I.2)** had died two years previously at the age of 60 years. His death was due to essential malignant hypertension and cerebral haemorrhage. Three months before he died he had been admitted to the New Somerset Hospital in the care of Dr. Mark Horwitz. The clinical records clearly describe camptodactyly (flexion contractures of proximal interphalangeal joints of fifth fingers; hyperextension of proximal interphalangeal joints of fourth fingers) and bilateral talipes equinovarus. He did not have a cleft palate or other congenital anomaly. He had two sibs, both sisters, whom we were able to examine: neither had any congenital anomalies. The elder sister had given birth to three children; two were stillborn and the other was normal. Their parents (the paternal grandparents of the index case) are both dead; they were not known to have had any congenital anomalies.

**Mother (I.3)** had no congenital anomalies. She has two older brothers and two older sisters, none of whom is affected. Only one of her sibs, a brother, has children; all eight were examined and no congenital anomalies were found. Her parents (the maternal grandparents of the index case) are both dead; they were not known to have had any congenital anomalies. The mother and father of the index case are not consanguineous.

**Nephews and Nieces.** The elder sister of the index case (II.2) has two sons and two daughters (III.2) who are all normal. The eldest brother of the index case (II.3) has a son and a daughter (III.3) who are normal. The affected brother of the index case (II.4) has two daughters. The elder one (III.4) was first examined at the age of 2 months; she has a cleft of the whole secondary palate and severe bilateral congenital talipes equinovarus (Fig. 9). The younger one (III.5) was born while the investigation was in progress; she also has severe bilateral congenital talipes equinovarus. She has no cleft palate and neither of these nieces has camptodactyly.

### Biochemical Investigation

Full 24-hour specimens of urine were collected on 2 occasions from the index case, from the affected sister (II.8), and from the unaffected sister-in-law (II.5). All the specimens, except the first obtained from II.5, were collected under supervision in hospital. In the affected brother (II.4) it was possible to obtain only a single 24-hour specimen, collected at his home without supervision. The specimens, to which no preservative had been added, were received on the day their collections were completed. An aliquot from each was immediately stored at  $-4^{\circ}\text{C}$ . and analysed within a week. Quantitative analyses of the urinary amino acids were performed

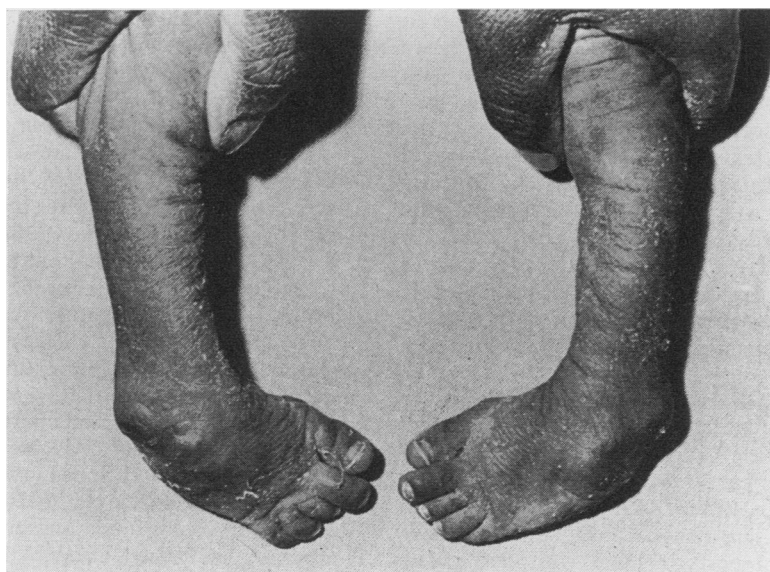


FIG. 9. Feet of the niece (III.4), at the age of 3 months, with severe talipes equinovarus.

TABLE II  
URINARY EXCRETION OF FREE TAURINE

Specimen No. Volume (ml.) Free taurine ( $\mu$ mole/24 hr.)	Index Case (II.7) Severely Affected		Sister (II.8) Severely Affected		Brother (II.4) Mildly Affected	Sister-in- law (II.5) Not Affected	
	1	2	1	2	1	1	2
	1930	820	1100	1340	720*	780*	1150
	1129	1267	471	575	180	163	344

\* Probably incomplete collections.

by the automatic column chromatographic method of Spackman, Stein, and Moore (1958), using a Beckman 120B amino-acid analyser.

### Results

No abnormality was detected in the daily amino acid excretion pattern in any of the 7 specimens examined; the quantitative values for the urinary amino acids were all within normal limits. The values for urinary taurine are shown in Table II. Using the same automated method of assay, Soupart (1959) found the average urinary excretion of taurine by 15 normal adults to be 812  $\mu$ moles per 24 hours, with a range of 220 to 1850  $\mu$ moles per 24 hours. The results in our 4 subjects, including 3 with camptodactyly, were well below the upper limit of this range. The rather low values found on one occasion in II.8 and in II.4 might have been due to incomplete urinary collections.

### Discussion

In this family there are 6 affected individuals in 3 successive generations: 3 males and 3 females are affected; a father and 2 of his sons are affected; and altogether 5 of the 11 children born to affected persons are also affected. Two of the affected, the index case and his sister, have all 3 anomalies: camptodactyly, cleft palate, and club foot: the other 4 affected have only 1 or 2 of these anomalies. Among the 6 affected, club foot has occurred 5 times, camptodactyly 4 times, and cleft palate 3 times. Despite this quite conspicuous phenotypic variability, the pedigree pattern suggests that we are dealing with a single mutant autosomal gene with dominant effect.

We have searched the literature available to us for other reports of similar aggregation of these 3 anomalies. Marfan's syndrome was considered because in this condition camptodactyly occurs quite commonly (Marfan, 1896; McKusick, 1960), club foot is not rare (Ross, 1949), and there have been occasional reports of cases with cleft palate (Gorlin and Pindborg, 1964a). However, we have

not found a single report of Marfan's syndrome with all 3 of these anomalies; in fact, the only case we know of with even 2 of these anomalies is a member of the family described by Wilson (1957) in whom Marfan's syndrome was complicated by a cleft palate and an 'equinus deformity of the feet'. There was no suggestion in any member of the family which we are reporting of any of the more usual skeletal, cardiovascular, or ocular manifestations of Marfan's syndrome.

Apart from their very rare association in Marfan's syndrome, *camptodactyly* and *cleft palate* may occur together in another 3 of the 11 conditions listed in Table I. In the oral-facial-digital syndrome, cleft palate is quite commonly present while the digital anomalies may or may not include *camptodactyly* (Dodge and Kernohan, 1967). In the syndrome of oculo-dento-digital dysplasia, *camptodactyly* is a regular feature, but clefts of the lip and palate have been seen only in the occasional case (Gillespie, 1964). In the family with the pterygium colli syndrome described by Moldenhauer (1964) there were affected individuals with both cleft palate and *camptodactyly*.

The association of *camptodactyly* and *club foot* has been observed in successive generations of the cranio-carpo-tarsal dystrophy syndrome (Welch and Temtamy, 1966; McKusick, 1966). Among the 19 patients with *camptodactyly* reported by Currarino and Waldman (1964) there were 3 with club foot, while Murphy (1926) and Barinka (1964) have each reported a single case in which these 2 anomalies were both present. In none of these reports was there any suggestion that these 2 anomalies were associated in other members of the families.

Rather more is known about the association of *cleft palate* and *club foot*. Wynne-Davies (1964) found 3 cases of cleft palate among 635 cases of different kinds of club foot; among her 340 cases of talipes equinovarus there was one with a cleft palate. On the other hand, in a recent investigation in Cape Town (Gordon *et al.*, 1969), no case of club foot was found among the 96 index cases with isolated cleft palate. In Edinburgh, Drillien, Ingram, and Wilkinson (1966) found 3 cases of club foot among 74 subjects with cleft palate. One of these was a patient with the Pierre Robin syndrome in which the association of these 2 anomalies is fairly common: for example, there were 3 cases of club foot among the 39 cases of Pierre Robin syndrome reported by Smith and Stowe (1961). In the syndrome of cleft lip and/or cleft palate with pits in the lower lip, club foot is sometimes present (Gorlin and Pindborg, 1964b; Taylor and Lane, 1966). In the popliteal-web syndrome, cleft lip and palate with

lower-lip pits, digital and genital anomalies, and a popliteal web, are occasionally accompanied by club foot; it was observed in 2 of the 8 cases reviewed by Hecht and Jarvinen (1967). In Larsen's syndrome, the main features are the abnormal facies, the multiple congenital dislocations, and the abnormally-shaped digits, but club foot and a partial cleft palate also may be present (Larsen, Schottstaedt, and Bost, 1950). Finally, in the D-trisomy syndrome of Edwards *et al.* (1960), club foot (usually calcaneo-valgus) is often present and cleft lip and/or palate also may occur. The flexion of fingers which occurs in this syndrome is quite different from that of camptodactyly in that both proximal interphalangeal and metacarpophalangeal joints are acutely flexed, all the fingers—including the thumb—are involved, with characteristic overlapping of the fingers, and the fingers can at least partly be straightened passively because there is no fibrous contracture. Again, in none of these reports is there any indication of consistent familial aggregation of cleft palate and club foot.

Our search through the literature has failed to reveal a previous instance of the association camptodactyly, cleft palate, and club foot in several members of a family with a pedigree suggesting the autosomal dominant pattern of inheritance. Though our data are consistent with the hypothesis that a single mutant gene is responsible for this syndrome, it would be reckless to assume this to be established on the evidence of a single family study. The recognition of this syndrome in other families with a similar kind of pedigree would confirm our hypothesis, unless we are dealing with a 'private' mutant gene which exists only in this family—a situation comparable to that of the several 'private' blood-group antigens (Race and Sanger, 1968).

If it is established that the familial aggregation of camptodactyly, cleft palate, and club foot constitutes a discrete genetical entity, then this syndrome can be added to the group of 'heritable disorders of connective tissue' (McKusick, 1960). In this group there are several conditions—for example, Marfan's syndrome and osteogenesis imperfecta—which also show the autosomal dominant pattern of inheritance, with variable phenotypic expression. The recognition of the heritability of this syndrome could have implications for genetical counselling. Cleft palate and club foot are common congenital anomalies in respect of which genetical counselling is sought. If they show family aggregation, and especially if there is even a slight degree of camptodactyly present in the patients or in their close relatives, then instead of the relatively good genetical prognosis which is usually given, a recurrence risk of

up to 50% in children or in subsequent sibs may have to be stated.

In the 3 living members of this family in whom there was camptodactyly we are unable to demonstrate an abnormal aminoaciduria or taurinuria. It may be that in this family we are dealing with a kind of camptodactyly which is different from those reported by Nevin *et al.* and by Parish *et al.* The cases studied by Nevin *et al.* had classical camptodactyly without other anomalies. The family reported by Parish *et al.* had an unusual form of camptodactyly which only affected females, with involvement of the thumb in the index case, and without involvement of the fifth finger in some of the other family members. Apart from this, it is difficult to compare our data with those of the 2 previous groups of investigators, neither of whom reported any quantitative data. Parish *et al.* did not identify the abnormal amino acid which they found by two-dimensional paper chromatography. It was not necessarily associated with camptodactyly since it was found in 2 other members of the family whose fingers were normal and it was not found in 2 cases of 'hereditary crooked fingers' belonging to other families. The association of taurinuria with camptodactyly described by Nevin *et al.* is even more difficult to assess. By paper chromatography, they found increased taurinuria in 6 of 7 subjects with camptodactyly and in 1 of 3 subjects with normal fingers. The normal urinary excretion of taurine varies considerably from person to person (Evered, 1956), and even in the same individual there may be substantial day-to-day differences (Soupart, 1962). As Nevin *et al.* did not study the 24-hour excretion of taurine in their subjects and gave no indication of repeated chromatograms being performed on the urines of their normal or affected subjects, we cannot subscribe to their conclusion that there is 'little doubt that the association between camptodactyly and abnormal excretion of taurine is real'.

### Summary

A possibly unique family is described in which 6 members are affected with varying combinations of camptodactyly, cleft palate, and club foot. The pedigree pattern suggests that the cause is a single mutant autosomal gene with dominant effect. There was no abnormal aminoaciduria or taurinuria in the 3 living family members with camptodactyly.

We thank Dr. Mark Horwitz for his clinical notes on the father of the index case. We are also obliged to Mrs. T. Maclagan for the photographs. One of us (H.G.) is in receipt of a grant from the National Institutes



of Health of the U.S. Public Health Service (HE 06267). Financial support was also received from a University of Cape Town Staff Research Grant (C. L. Hermann Bequest), and from the South African Council for Scientific and Industrial Research.

## REFERENCES

- Baird, H. W. (1964). Kindred showing congenital absence of the dermal ridges (fingerprints) and associated anomalies. *J. Pediat.*, **64**, 621.
- Barinka, L. (1964). Notes on camptodactylia (second communication). *Acta Chir. plast. (Praha)*, **6**, 154.
- Currairino, G., and Waldman, I. (1964). Camptodactyly. *Amer. J. Roentgenol.*, **92**, 1312.
- Dodge, J. A., and Kernohan, D. C. (1967). Oral-facial-digital syndrome. *Arch. Dis. Childh.*, **42**, 214.
- Drillien, C. M., Ingram, T. T. S., and Wilkinson, E. M. (1966). *The Causes and Natural History of Cleft Lip and Palate*, pp. 90-100. Livingstone, Edinburgh.
- Edwards, J. H., Harnden, D. G., Cameron, A. H., Crosse, V. M., and Wolff, O. H. (1960). A new trisomic syndrome. *Lancet*, **1**, 787.
- Evered, D. F. (1956). The excretion of amino acids by the human. A quantitative study with ion-exchange chromatography. *Biochem. J.*, **62**, 416.
- Freeman, E. A., and Sheldon, J. H. (1938). Cranio-carpo-tarsal dystrophy. An undescribed congenital malformation. *Arch. Dis. Childh.*, **13**, 277.
- Garrod, A. E. (1904). Concerning pads upon the finger joints and their clinical relationships. *Brit. med. J.*, **2**, 8.
- Gillespie, F. D. (1964). A hereditary syndrome: 'dysplasia oculodentodigitalis'. *Arch. Ophthalm.*, **71**, 187.
- Gordon, H., Davies, D., Botha, V., and Friedberg, S. (1969). Cleft lip and palate in Cape Town. *S. Afr. med. J.* In the press.
- Gorlin, R. J., Meskin, L. H., Peterson, W. C., and Goltz, R. W. (1963a). Focal dermal hypoplasia syndrome. *Acta dermatovenerol. (Stockh.)*, **43**, 421.
- , —, and St. Geme, J. W. (1963b). Oculodentodigital dysplasia. *J. Pediat.*, **63**, 69.
- , and Pindborg, J. J. (1964a). *Syndromes of the Head and Neck*, p. 355. McGraw-Hill, New York.
- , and — (1964b). *ibid.*, p. 118.
- Hecht, F., and Jarvinen, J. M. (1967). Heritable dysmorphic syndrome with normal intelligence. *J. Pediat.*, **70**, 927.
- Landouzy, L. (1906). Camptodactylie: stigmate organique précoce du neuro-arthritis. *Presse méd.*, **14**, 251.
- Larsen, L. J., Schottstaedt, E. R., and Bost, F. C. (1950). Multiple congenital dislocations associated with characteristic facial abnormality. *J. Pediat.*, **37**, 574.
- McKusick, V. A. (1960). *Heritable Disorders of Connective Tissue*, 2nd ed., p. 56. C. V. Mosby, St. Louis.
- (1966). *Mendelian Inheritance in Man*, p. 33. Johns Hopkins Press, Baltimore.
- Marfan, A. B. (1896). Un cas de déformation congénitale des quatre membres plus prononcée aux extrémités caractérisée par l'allongement des os avec un certain degré d'amincissement. *Bull. Soc. méd. hôp. Paris*, **13**, 220.
- Maurer, G. (1938). Die Kamptodaktylie. *Arch. orthop. Unfall-Chir.*, **38**, 365.
- Moldenhauer, E. (1964). Zur Klinik des Nielson-syndroms. *Derm. Wschr.*, **150**, 594.
- Murphy, D. P. (1926). Familial finger contracture and associated familial knee-joint subluxation. *J. Amer. med. Ass.*, **86**, 395.
- Neel, J. V., and Rusk, M. L. (1963). Polydactyly of the second metatarsal with associated defects of the feet: a new, simply inherited skeletal deformity. *Amer. J. hum. Genet.*, **15**, 288.
- Nevin, N. C., Hurwitz, L. J., and Neill, D. W. (1966). Familial camptodactyly with taurinuria. *J. med. Genet.*, **3**, 265.
- Parish, J. G., Horn, D. B., and Thompson, M. (1963). Familial striblodactyly with amino-aciduria. *Brit. med. J.*, **2**, 1247.
- Patau, K., Smith, D. W., Therman, E., Inhorn, S. L., and Wagner, H. P. (1960). Multiple congenital anomaly caused by an extra autosome. *Lancet*, **1**, 790.
- Race, R. R., and Sanger, R. (1968). *Blood Groups in Man*, 5th ed., p. 400. Blackwell Scientific Publications, Oxford.
- Ross, L. J. (1949). Arachnodactyly. Review of recent literature and report of a case with cleft palate. *Amer. J. Dis. Child.*, **78**, 417.
- Smith, J. L., and Stowe, F. R. (1961). The Pierre Robin syndrome (glossoptosis, micrognathia, cleft palate): a review of 39 cases with emphasis on associated ocular lesions. *Pediatrics*, **27**, 128.
- Spackman, D. H., Stein, W. H., and Moore, S. (1958). Automatic recording apparatus for use in chromatography of amino acids. *Analyt. Chem.*, **30**, 1190.
- Soupart, P. (1959). Urinary excretion of free amino acids in normal adult men and women. *Clin. chim. Acta*, **4**, 265.
- (1962). Free amino acids of blood and urine in the human. In *Amino Acid Pools*, p. 220. Ed. by J. T. Mulden. Elsevier, Amsterdam.
- Taylor, A. I. (1967). Patau's, Edwards' and cri du chat syndromes: a tabulated summary of current findings. *Develop. Med. Child Neurol.*, **9**, 78.
- Taylor, W. B., and Lane, D. K. (1966). Congenital fistulas of the lower lip. Associations with cleft lip-palate and anomalies of the extremities. *Arch. Derm.*, **94**, 421.
- Welch, J. P., and Temtam, S. A. (1966). Hereditary contractures of the fingers (camptodactyly). *J. med. Genet.*, **3**, 104.
- Wilson, R. (1957). Marfan's syndrome: description of a family. *Amer. J. Med.*, **23**, 434.
- Wynne-Davies, R. (1964). Family studies and the cause of congenital club foot. Talipes equinovarus, talipes calcaneo-valgus and metatarsus varus. *J. Bone Jt Surg.*, **46B**, 445.