

Benign, Recessively Inherited Choreo-athetosis of Early Onset*

PAUL A. NUTTING, BARBARA R. COLE, and R. NEIL SCHIMKE†

From the Departments of Pediatrics and Medicine, Kansas University Medical Center, Kansas City, Kansas, U.S.A.

Most cases of hereditary choreo-athetosis are assumed to be Huntington's chorea. Closer examination of patients so classified often has revealed their rather heterogeneous nature. We have recently encountered three sibs who presented with non-progressive, benign chorea of early onset with a family history compatible with autosomal recessive inheritance, a hitherto undescribed combination.

Case Reports

Case 1. III.2 (Fig.), a 10-year-old Caucasian male, was first seen at the University of Kansas Medical Center in September 1968, complaining of uncontrollable movements. He was the product of a full-term gestation and uneventful delivery with a birthweight of 4593 g. Other than the main complaint, growth and development had been normal. He had the usual childhood diseases without a history suggestive of rheumatic fever. The family history revealed that two sibs (Cases 2 and 3) were likewise affected, but no similar problem was found in the remaining female sibs nor in any other family member. The mother and father were 30 and 33 years old, respectively, and both were physically and intellectually normal. The three surviving grandparents were in their fifties and were neurologically normal. The deceased paternal grandfather died at the age of 51 of a myocardial infarction, though his previous health had been good. No consanguinity was detected.

The unusual movements in the patient were first noted by the maternal grandmother at approximately 4 years of age, and were observed to progress for two or three years before stabilizing in their present intensity. No associated tremors, seizures, or dysphagia were present nor was there gross lack of co-ordination or loss of motor strength.

Physical examination at the time of admission revealed a well-developed, well-nourished intelligent male who exhibited constant choreo-athetotic movements of the extremities and neck, absent only during sleep. There was no evidence for cerebellar or posterior column dysfunction and all sensory modalities were intact.

Muscle mass, tone, and strength were normal and symmetrical, and there was no tremor, rigidity, or spasm. Deep and superficial reflexes were equal and symmetrical, and the plantar responses were flexor bilaterally. All other aspects of the physical examination were within normal limits.

The following laboratory investigations were performed and were found to be normal: urinalysis, complete blood count, fasting blood sugar, serum calcium and phosphorus, blood urea nitrogen, hepatic function studies, serum protein electrophoresis, serum aldolase, caeruloplasmin, and uric acid and urinary lead and copper. Urinary amino acid chromatogram, electroencephalogram, routine chest and skull x-rays, and electromyographic and nerve conduction studies were all normal. A karyotype showed the expected 46/XY pattern. Analysis of the spinal fluid showed nothing unusual, and the opening and closing pressures were normal.

There was no change in the patient's condition during his hospital stay and he was discharged on procyclidine. Follow-up studies revealed no substantial change five months after discharge.

Cases 2 and 3. III.1 and III.4 (Fig. 1), the respective 12- and 7-year-old female sibs of Case 1 were found to exhibit choreiform and athetotic movements identical to those of their brother. The disease had an insidious onset between the ages of 4 and 5 in both sibs, and little

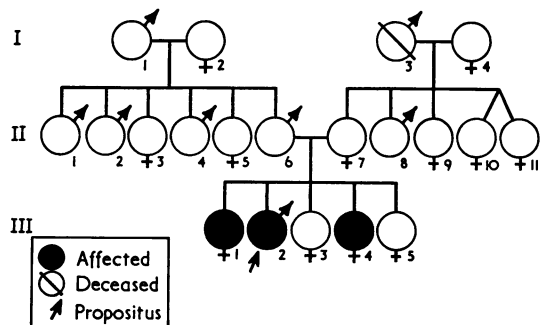


FIG. The pedigree. Note the absence of affected family members in earlier generations.

Received May 27, 1969.

* Supported in part by the Huntington Chorea Fund.

† Reprint requests should be sent to Dr. Schimke, Kansas University Medical Center, Kansas City, Kansas, U.S.A.

progression has been noted. Both girls have engaged in normal activities with their peers and apparently have not been handicapped to any great extent by their disease. They have performed satisfactorily in school and have shown no evidence of impaired intellectual function.

Physical examination was virtually identical in both children. In general, they were less severely affected than their brother, though both girls had somewhat more truncal than extremity movements. As in the proband, the remaining neurological examination and the general physical examination were normal.

Discussion

Chorea occurring in the first few years of life may be a manifestation of one of several diseases. Birth trauma with perinatal brain damage, hypoxia, encephalomyelitis, various congenital anomalies, including vascular malformations, brain tumours, ingestion of phenothiazine derivatives, and even hypoparathyroidism are among the disorders capable of evoking choreiform movements (Greenhouse, 1966; Pincus and Chutorian, 1967). One of the more common movement disorders of childhood is Sydenham's chorea. This disorder, associated chiefly with rheumatic fever, usually is a benign, self-limited disease, and affected children rarely have symptoms for more than six months (Parker and Lipschutz, 1958). A hereditary predisposition to rheumatic fever has been suggested by some workers, but the pedigrees are certainly not consistent with simple, single factor inheritance (Spagnuolo and Taranta, 1968). The presence of choreo-athetosis in 3 of 5 sibs, the absence of a history of environmental agents capable of inciting symptoms, the normal serum levels of calcium and phosphorus in the proband, and the prolonged course adequately distinguish our patients from those with acquired disease.

Various heritable metabolic diseases may present with chorea, and the onset may be in childhood. Wilson's disease, an autosomal recessive inborn error in copper metabolism, rarely presents with neurological symptoms in the first decade. The disease normally is relentlessly progressive and eventually results in serious hepatic and neurological dysfunction. Kayser-Fleischer rings are one of the diagnostic hallmarks of this disease, and urinary copper excretion is increased. Our patients had no evidence of abnormal copper metabolism, hepatic function studies were normal, and the characteristic eye findings were absent. The juvenile cerebral gangliosidoses are generally progressive in nature, and characteristically show hepatosplenomegaly due to histiocytic storage of the incompletely metabolized lipids. The three sibs

reported here lacked the typical features of these storage diseases. Similarly, the X-linked Lesch-Nyhan syndrome comprising choreo-athetosis, mental retardation, self-mutilation, and persistent hyperuricaemia can be excluded by the absence of typical clinical and laboratory features, and by the presence of affected female sibs (Lesch and Nyhan, 1964; Kelley, 1968).

Huntington's chorea rarely may appear in childhood. In a review of more than 2000 cases, Jervis (1963) found only 7 patients with symptoms beginning before the age of 5, and only 13 with disease onset between 6 and 10 years of age. In a similar study, Hansotia, Cleeland, and Chun (1968) reviewed the clinical aspects of juvenile Huntington's chorea, and emphasized that children often presented with a somewhat different clinical picture. Thus, 90% exhibited dyslalia uncorrelated with the degree of mental retardation, which was also present in 85% of the patients. Other features included choreo-athetosis (80%), rigidity (65%), cerebellar symptoms (50%), and seizures (35%). It is noteworthy that virtually every one of the reported cases of juvenile Huntington's chorea had a positive family history, showing the classical autosomal dominant mode of inheritance. Only rarely have individuals in the same generation had a childhood onset of symptoms (Byers and Dodge, 1967). The early appearance of neurological dysfunction in 3 sibs, the lack of progression, the absence of characteristic features other than choreo-athetosis, and the apparently different genetic transmission adequately serve to differentiate between Huntington's chorea and the disease in the family under consideration.

Two sisters with a disorder indistinguishable from Huntington's chorea were recently reported from Norway (Haugerud, 1968). However, both parents were in their sixties and unaffected, and there was no evidence for chorea in five previous generations. Consanguinity was present in both sets of grandparents. While the authors speculate on the possibility of a new mutation, a rare recessive disorder seems equally probable. Though the inheritance pattern in our family may be similar, the earlier age of onset and the lack of progression in our patients represent differential features.

Other hereditary choreo-athetotic disorders have been described. Mount and Reback (1940) reported a family with five generations of paroxysmal choreo-athetosis, characterized by periodic attacks of involuntary, bizarre, writhing movements of the entire body, often with grotesque posturing and grimacing. Between attacks, the patients appeared normal. In view of the non-paroxysmal and less

violent clinical manifestations of chorea in our patients, and the differing mode of inheritance, this diagnosis was untenable. Haerer, Currier, and Jackson (1967) described a large Negro family whose members exhibited choreiform movements of early onset and non-progressive nature. The movements were present throughout the day, were exacerbated by mental and physical stress, and were absent during sleep. The pedigree was compatible with autosomal dominant inheritance. Pincus and Chutorian (1967) have reported two other families in which multiple members showed the combination of benign chorea and intention tremor. Autosomal dominant inheritance of this disorder also seemed fairly certain. Both of these latter genetic entities superficially resemble the disease in our patients. However, other than the affected sibs, no other family member has neurological dysfunction, and on this basis autosomal dominant inheritance seemingly can be excluded.

It, therefore, appears on both clinical and genetic grounds that the type of choreo-athetosis present in the three sibs represents a unique entity.

Summary

A family is reported in which one male and two female sibs were afflicted with early onset, benign

choreo-athetosis. Genetic study strongly suggested autosomal recessive inheritance. This disorder is compared and contrasted with other forms of hereditary choreo-athetosis, and it is concluded that a distinct entity has been encountered.

REFERENCES

- Byers, R. K., and Dodge, J. A. (1967). Huntington's chorea in children. Report of four cases. *Neurology (Minneapolis)*, **17**, 587.
- Greenhouse, A. H. (1966). On chorea, lupus erythematosus and cerebral arteritis. *Arch. intern. Med.*, **117**, 389.
- Haerer, A. F., Currier, R. D., and Jackson, J. F. (1967). Hereditary nonprogressive chorea of early onset. *New Engl. J. Med.*, **276**, 1220.
- Hansotia, P., Cleeland, C. S., and Chun, R. W. M. (1968). Juvenile Huntington's chorea. *Neurology (Minneapolis)*, **18**, 217.
- Haugerud, S. (1968). Chronisch progressive chorea bei zwei Schwestern ohne nachweisbare Heredität. *Schweiz. med. Wschr.*, **98**, 2016.
- Jervis, G. A. (1963). Huntington's chorea in childhood. *Arch. Neurol. (Chic.)*, **9**, 244.
- Kelley, W. N. (1968). Hypoxanthine-guanine phosphoribosyltransferase deficiency in the Lesch-Nyhan syndrome and gout. *Fed. Proc.*, **27**, 1047.
- Lesch, M., and Nyhan, W. L. (1964). A familial disorder of uric acid metabolism and central nervous system function. *Amer. J. Med.*, **36**, 561.
- Mount, L. A., and Reback, S. (1940). Familial paroxysmal choreo-athetosis; preliminary report on hitherto undescribed clinical syndrome. *Arch. Neurol. Psychiat. (Chic.)*, **44**, 841.
- Parker, A. M., and Lipschutz, E. W. (1958). An unusual case of Sydenham's chorea of prolonged duration. *N.Y.S. J. Med.*, **58**, 2834.
- Pincus, J. H., and Chutorian, A. (1967). Familial benign chorea with intention tremor: a clinical entity. *J. Pediat.*, **70**, 724.
- Spagnuolo, M., and Taranta, A. (1968). Rheumatic fever in siblings. *New Engl. J. Med.*, **278**, 183.