

The Nature and Inheritance of Kirner's Deformity

T. J. DAVID and R. L. BURWOOD

From the Cardiac Department, General Hospital, Bristol and the Department of Radiodiagnosis, University of Bristol

Kirner first described ventral and radial bowing of the terminal phalanx of the 5th finger (Fig. 1) in 1927. In 1965, Blank and Girdany were able to trace 17 documented examples of the deformity, and they described vertical transmission of the condition through 3 generations of a family, suggesting dominant inheritance.

Neither the nature nor the inheritance of this deformity have been studied in detail, and most documented cases appear to have arisen as accidental findings (eg, Taybi, 1963). The literature indicates that the deformity can be inherited or sporadic, that it can be unilateral but is usually bilateral, and that it can affect both sexes although 70% of published cases have occurred in females.

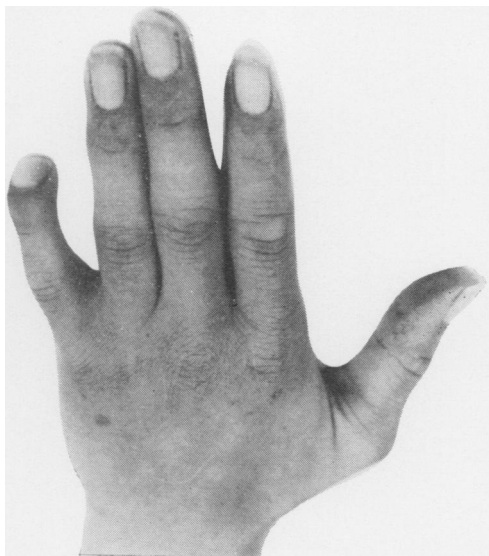


FIG. 1. Case 14 (II.2, family E, see Fig. 2) aged 14. Left hand. The distal phalanx is deformed, with shortening and ventral and radial bowing. There is a superficial appearance of clubbing, but there is a normal angle between the nail and nail bed.

Patients and Methods

The present series resulted from a palmar dermatoglyphic survey of patients with congenital heart disease (450), their first-degree relatives (500), patients with coeliac disease and other wasting diseases (700), a random selection of hospital inpatients (350), and healthy controls with no serious congenital malformations (500 males, 500 females). Detection of finger and hand deformities in these people was made at the time of finger and palm printing. The families of all subjects with Kirner's deformity were studied and usually visited at home by one of the authors. Wherever possible radiographs of the hands were taken (dorsopalmar and lateral views of both hands). Clinically unaffected members of the families were not x-rayed. All the patients and controls came from the south west of England. Nine families were studied, with 18 affected members. In 5 families the propositus was the only affected member.

Results

Incidence. Nine cases were detected in 3000 persons. Excluding the 450 patients with congenital heart disease and their relatives, there were 5 cases in 2050 persons examined, giving an incidence of 1 in 410.

Sex. There were 12 affected females and 6 males. Three out of the 4 unilateral cases were males. Thus 11 out of 14 of those with bilateral deformities were female, as opposed to only 1 out of 4 of those with the unilateral condition.

Laterality. The deformity was bilateral in 14 out of the 18 cases. The right side was affected in each of the unilateral cases.

Inheritance. Pedigrees A, B, C, and D (Fig. 2) were compatible with autosomal dominant inheritance, the gene having incomplete penetrance. Sex linkage can be excluded if one assumes that the same gene is responsible for all our cases. There was no suggestion of autosomal recessive inheritance, though this could not be excluded in pedigrees E, F, G, H, and I (Fig. 2), in whom there was no known consanguinity.

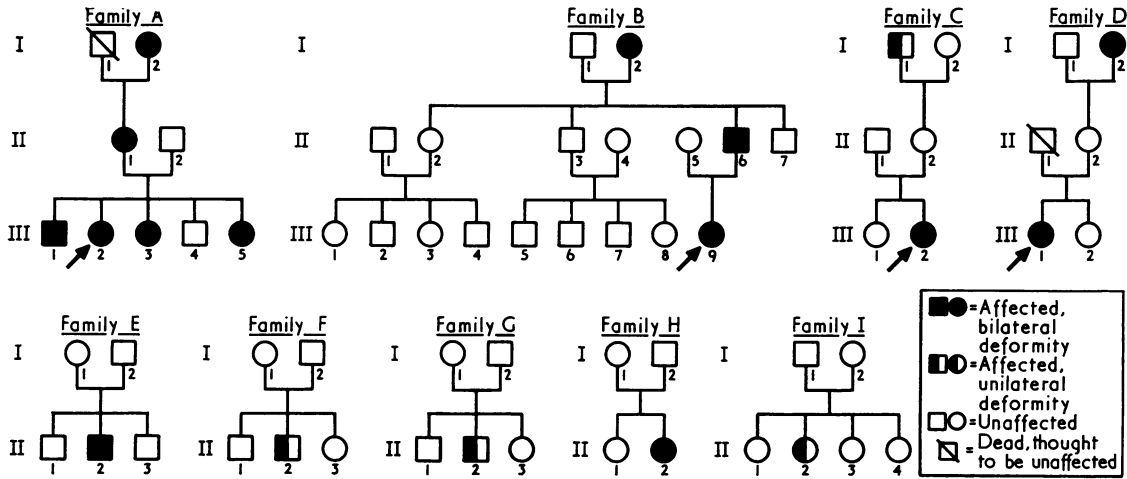


FIG. 2. Pedigrees of patients with Kirner's deformity.

Radiology. The radiological findings are summarized in Table I, to which the following comments are added:

Case 1. A 68-year-old woman (I.2, family A) with bilateral deformity. There were no gross radiological features of Kirner's deformity, but radial angulation of the distal interphalangeal joint was noted. This was considered to be secondary to the presence of osteoarthritis and Heberden's nodes.

Case 2 (II.1, family A). The middle and terminal phalanges were sclerosed due to a failure of medullarization (Fig. 3).

Case 6. A female infant (III.5, family A) aged 11 months. Radiologically normal.

Case 17 (II.2, family H). Fusion was present between the trapezium and the trapezoid, and between the hamate and capitate, in both wrists.

Associated Disease. Four of the propiiti had congenital heart disease, but this was not present in any relatives of the 9 propiiti. The cardiac lesions, proven by cardiac catheterization and angiocardiography, were: ventricular septal defect (case 13; III.1, family D), persistent ductus arteriosus (case 4; III.2, family A); secundum atrial septal defect (case 18; II.2, family I); and secundum atrial septal defect, ventricular septal defect, and valvular

TABLE I
RADIOLOGICAL FEATURES IN THE TERMINAL PHALANX

Case	Age	Side(s) Affected	Radiological Features*									
			1	2	3	4	5	6	7	8	9	10
2 (II.2, family A)	40	B	+	-	+	+	-	+	-	+	+	+
4 (III.2, family A)	14	B	-	+	+	+	+	+	+	+	-	+
5 (III.3, family A)	12	B	-	+	+	+	+	+	+	+	-	+
14 (II.2, family E)	14	B	+	+	+	+	+	+	+	+	-	+
15 (II.2, family F)	56	R	+	+	+	+	+	+	+	X	+	+
17 (II.2, family H)	20	B	-	+	+	+	+	+	+	+	X	+

* 1 = increased density of tuft; 2 = radiolucent nidus in the tuft; 3 = increased density of the diaphysis; 4 = ventro-radial angulation of the diaphysis; 5 = shortened diaphysis; 6 = reduction in dorsopalmar diameter of the diaphysis; 7 = radiolucent defect in the metaphysis; 8 = abnormal shape to epiphysis; 9 = epiphysis closed; 10 = normal distal interphalangeal joint.

Key to symbols. + = present; - = absent; X = epiphyses closed, no residual epiphyseal scar; B = bilateral; R = right.

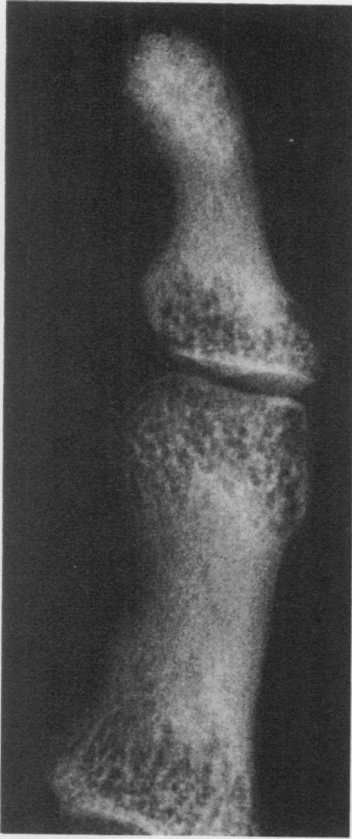


FIG. 3. Case 2 (II.1, family H) aged 40. Right little finger, oblique view. There is ventroradial angulation of the diaphysis, but sclerosis of the diaphysis cannot be seen because there is failure of medullarization in the phalanges.

pulmonary stenosis (case 9; III.9, family B). Case 15 (II.2, family F) had bilateral indirect inguinal hernias.

Discussion

Kirner's deformity appears to be inherited as an autosomal dominant character, the gene having incomplete penetrance. The figures in this paper support Thomas's contention (1936) that the condition is commoner in females. There was no history of trauma in any of the patients in this series, but this cannot be excluded in the 3 unilateral cases where there was no family history of the deformity. It is relevant that the unilateral deformity was always on the right. Since injuries to the left forefinger and right little finger are commoner than to any other digit (Cherrill, 1954), trauma must be considered as a possible cause in these 3 cases. However, the radiological appearances were identical in both the unilateral and the bilateral cases, and

it therefore seems unlikely that trauma accounted for any of our cases.

The radiological manifestations of Kirner's deformity may be defined as follows: (1) A well-defined radiolucent nidus of between 1 and 2 mm diameter is present in the terminal tuft (Fig. 4). In one case this nidus was loculated (Fig. 5). (2) A shortened diaphysis with ventroradial angulation of the distal phalanx relative to the middle phalanx. (3) Sclerosis of the diaphysis with sparing of both the epiphysis and the tuft (Fig. 4). (4) Reduction of the dorsopalmar diameter of the diaphysis (Fig. 4). (5) Apparent overgrowth of epiphysis of the distal phalanx is demonstrated at the ventral margin (Fig. 4). There is an anterior spur

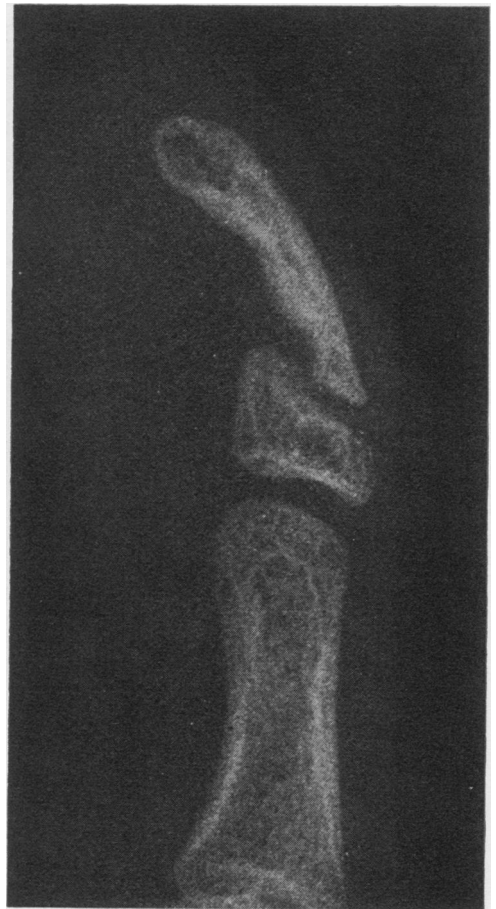


FIG. 4. Case 4 (III. 2, family A) aged 14. Right little finger, lateral view. The diaphysis is sclerosed and narrowed in its dorsoventral plane. There is a defect in the metaphyseal region on the ventral border. A well defined radiolucent nidus is present in the tuft. The epiphysis has a ventral spur. There is ventral angulation of the diaphysis.

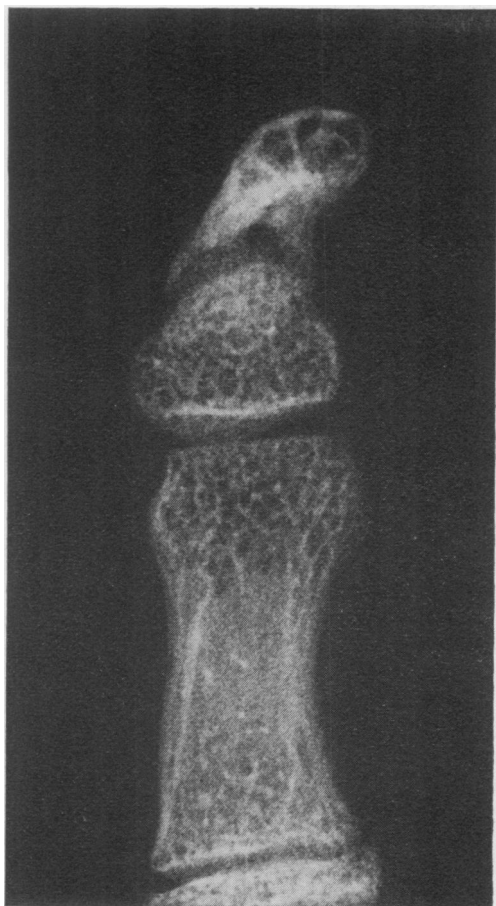


Fig. 5. Case 4, aged 14. Left little finger, dorsoventral view. There is sclerosis of the diaphysis. The epiphysis is cone-shaped, and there is a loculated radiolucent nidus in the tuft.

which in the anteroposterior projection may mimic a 'cone' epiphysis (Fig. 5). (6) The distal interphalangeal joint is normal.

We have demonstrated the deformity radiologically in a child of 12 years (case 5; III.3, family A), in whom the appearances were well marked. The absence of radiological changes in the affected baby aged 11 months (case 6; III. 5, family A) is not unexpected in that none of the epiphyseal ossification centres in the hand were present. Clinically we would consider the deformity as being congenital, but the radiological signs are lacking before epiphyseal ossification at about the age of 2 years. From the radiological appearances the primary defect arises on the ventral or ventroradial aspect of the metaphysis. There are no features to suggest an osteochondritis, although others (Thomas, 1936; Wilson, 1952; Taybi, 1963) have held this to be the

underlying lesion. Wilson (1952) stated that 'increased density of the terminal phalanx in the early stage [is] followed by a return to normal density in the later stages'. However, in the present series there were 8 patients over the age of 30 who were known to have had the deformity since early childhood, and in the 3 who were x-rayed the increased density of the terminal phalanx persisted. In no case was there a return to normal bone density.

Kirner's deformity was thought not to be associated with congenital heart disease for 2 reasons. Firstly, there was no common cardiac lesion. Secondly, relatives of patients with Kirner's deformity had no evidence of congenital heart disease even when they did exhibit Kirner's deformity.

It is suggested that Kirner's deformity is more common than the dearth of published cases might indicate. The shortage of published material may reflect the minor nature of the deformity which usually fails to attract the attention of physicians. On 2 occasions radiographs of what was thought to be a mild example of Kirner's deformity showed hypoplasia of the middle phalanx of the type commonly associated with Down's syndrome. In mild cases the diagnosis is best confirmed radiologically, although most examples are easy to identify clinically.

Summary

Kirner's deformity—ventral and radial bowing of the terminal phalanx of the 5th finger—is described in 18 patients. The radiological features are defined and held to be diagnostic. The deformity was bilateral in 14 patients, and it was twice as common in females. The condition is probably due to an autosomal dominant gene with incomplete penetrance, although a familial tendency is less evident in the unilateral cases.

We are indebted to Dr B. A. Gwynne Jenkins and Dr D. W. Barritt for their help. T.J.D. is in receipt of a grant from the South Western Regional Hospital Board and the United Bristol Hospitals.

REFERENCES

- Blank, E. and Girdany, B. R. (1965). Symmetric bowing of the terminal phalanges of the fifth fingers in a family (Kirner's deformity). *American Journal of Roentgenology, Radium Therapy, and Nuclear Medicine*, **93**, 367-373.
- Cherrill, F. R. (1954). *The Finger Print System at Scotland Yard*. HMSO, London.
- Kirner, J. (1927). Doppelseitige Verkrümmungen des Kleinfingerendgliedes als selbständiges Krankheitsbild. *Fortschritte auf dem Gebiete der Röntgenstrahlen und Nuklearmedizin*, **36**, 804-806.
- Taybi, H. (1963). Bilateral incurving of the terminal phalanges of the fifth fingers (osteochondrosis?). *Journal of Pediatrics*, **62**, 431-432.
- Thomas, A. R. (1936). A new dystrophy of the fifth finger. *Lancet*, **1**, 1412-1413.
- Wilson, J. N. (1952). Dystrophy of the fifth finger. *Journal of Bone and Joint Surgery*, **34B**, 236-239.