

# Pathologic Effects of 2,3,7,8-Tetrachlorodibenzo-*p*-dioxin in Laboratory Animals

by B.N. Gupta,\* J.G. Vos,\* J.A. Moore,\* J.G. Zinkl,\* and B.C. Bullock\*

## Introduction

The technical chlorophenols and products produced from them, such as the herbicide 2,4,5-trichlorophenoxyacetic acid (2,4,5-T) have been found to contain chlorodibenzo-*p*-dioxins such as 2,3,7,8-tetrachlorodibenzo-*p*-dioxin (TCDD). TCDD and other chlorodibenzo-*p*-dioxins are among the most toxic compounds known, and have been implicated in outbreaks of chloracne among chemical workers (1). Hepatic and cardiac lesions and thymic involution were found in rats treated with TCDD (2). Generalized subcutaneous edema, ascites, hydrothorax, and hydropericardium were observed in monkeys given toxic fat (3) which purportedly contained TCDD. It also caused focal necrosis of parenchymal cells of liver and gastric ulcers in these monkeys. The purpose of this paper is to describe the sequence of pathologic changes which occurred following exposure to TCDD in rats, guinea pigs, and mice.

## Materials and Methods

Young adult male and female random bred albino rats (CD stock, Charles River Breeding Laboratories, Wilmington, Mas-

sachusetts) were used. They were housed individually under conditions of controlled temperature (68–72°F) and 12 hr daily lighting. The diet consisted of commercially available sterilized diet. Water was provided *ad libitum*. Young, short-haired female albino guinea pigs (Hartley strain) and female mice (CD-1) were also used to study the toxic effect of TCDD. These animals were also housed under optimal controlled conditions.

TCDD (Dow Chemical Company, Midland, Michigan) was dissolved in acetone and diluted with corn oil. All animals (rats, guinea pigs and mice) were given TCDD by gastric intubation. Control animals were treated similarly with acetone and corn oil only. Dose range and frequency of treatments were as follows:

(a) rats treated daily with 10.0, 1.0, or 0.1  $\mu\text{g}$  TCDD/kg body weight and examined after 3, 6, 10, 13, 17, 24, and 31 treatments; (b) rats given a single treatment with 100.0 or 50  $\mu\text{g}$  TCDD/kg body weight and examined when the rats became moribund or dead; (c) rats given a single treatment with 25.0 or 5.0  $\mu\text{g}$  TCDD/kg body weight and examined 1, 3, 9, 10, 17, and 29 days after treatment; (d) rats given 6 weekly treatments with 5.0, 1.0, or 0.2  $\mu\text{g}$  TCDD/kg body weight and examined 10 days after the last treatment; (e) guinea pigs given 8 weekly

\*National Institute of Environmental Health Sciences, National Institutes of Health, P.O. Box 12233, Research Triangle Park, North Carolina 27709.

treatments with 1.0, 0.2, 0.04, or 0.008  $\mu\text{g}$  TCDD/kg body weight and examined 56 days after the initiation of the treatment; (f) guinea pigs given a single treatment with 3.0  $\mu\text{g}$  TCDD/kg body weight and examined either after death or moribund condition; (g) mice given a single dose with 50.0, 10.0, or 1.0  $\mu\text{g}$  TCDD/kg body weight and examined 7, 21, and 35 days after treatment. All animals received the scheduled treatment unless death intervened.

Necropsies were performed on euthanized animals and those which became moribund or died before the scheduled kill day. Tissue samples from liver, spleen, kidney, urinary bladder, heart, lung, thymus, trachea, brain, spinal cord, salivary glands, axillary and mesenteric lymph nodes, tongue, esophagus, stomach, small and large intestines, pancreas, striated muscle from hind legs and diaphragm, bone marrow from femur, tibia, sternum, and ribs, adrenal, thyroid, uterus, ovary or testes, and skin were collected from most of the animals and fixed in 10% buffered neutral formalin for histopathologic evaluation. All tissue specimens were paraffin-embedded, sectioned 6  $\mu$  thick and stained with Harris' hematoxylin and eosin Y (H & E). Liver, kidney, bone, and total body of dead or moribund rats and guinea pigs were grossly examined under the ultraviolet light (Wood's lamp) for the presence of red fluorescence as an indication of porphyrin accumulation.

## Results

### Gross Pathologic Findings

Most of the rats given TCDD at a level of 10.0  $\mu\text{g}/\text{kg}$  became moribund or died between 17 and 31 daily treatments. Six of 14 rats given a single dose at a level of 100.0  $\mu\text{g}/\text{kg}$  also died 18 to 21 days after treatment (4). These rats had ruffled hair and appeared depressed. They usually sat in a corner of the cage without much movement. Gross pathologic changes observed in dead or moribund rats given these doses were similar and will be described together (Table 1). The ears, subcutaneous tissues and visceral organs appeared icteric. Oc-

asionally, there were subcutaneous hemorrhages in tail, paws, and under the nails; some had a loss of hair from the ventral surface of the body. There was a loss of subcutaneous and abdominal fat in TCDD-treated rats. The size of the uterus in these rats appeared to be smaller. The liver was friable and dark tan in color. The liver and spleen sizes were small. There were ulcerations and hemorrhages in the stomach which also contained blood clots (Fig. 1). Congestion of meningeal vessels and submeningeal hemorrhages were also observed (Fig. 1). All thymuses were markedly atrophied.

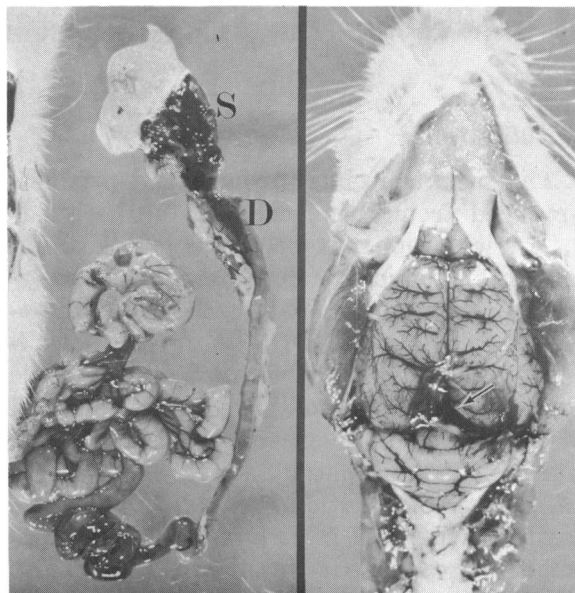


FIGURE 1. Gastrointestinal tract and brain of a rat given 26 daily treatments of 10.0  $\mu\text{g}$  TCDD/kg body weight. Notice congestion and hemorrhage in the brain (arrow), stomach (S) and duodenum (D).

The livers from rats killed after 10 to 17 daily intubations at 10.0  $\mu\text{g}/\text{kg}$  were dull gray (cooked appearance), swollen, and enlarged. There was accentuation of lobular markings (Fig. 2). The small intestine and mesenteric lymph nodes appeared slightly congested and the intestinal contents were more mucinous than that of control rats. Thymic atrophy (Fig. 2), which was dose-dependent, occurred in all rats examined. Significant gross pathologic changes were

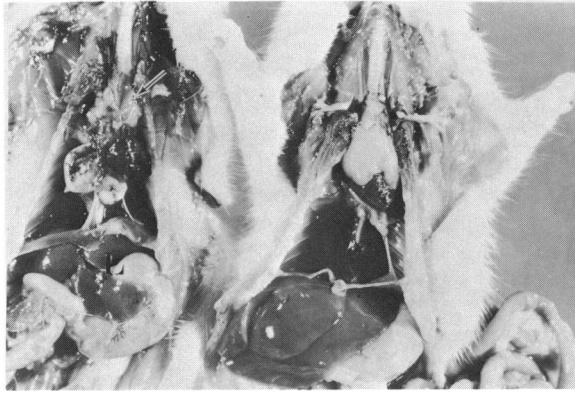


FIGURE 2. Rats (left) given 10 daily treatments of 10.0  $\mu\text{g}$  TCDD/kg body weight and (right) control. Notice the accentuation of lobular markings in the liver (L) and thymic atrophy (arrow).

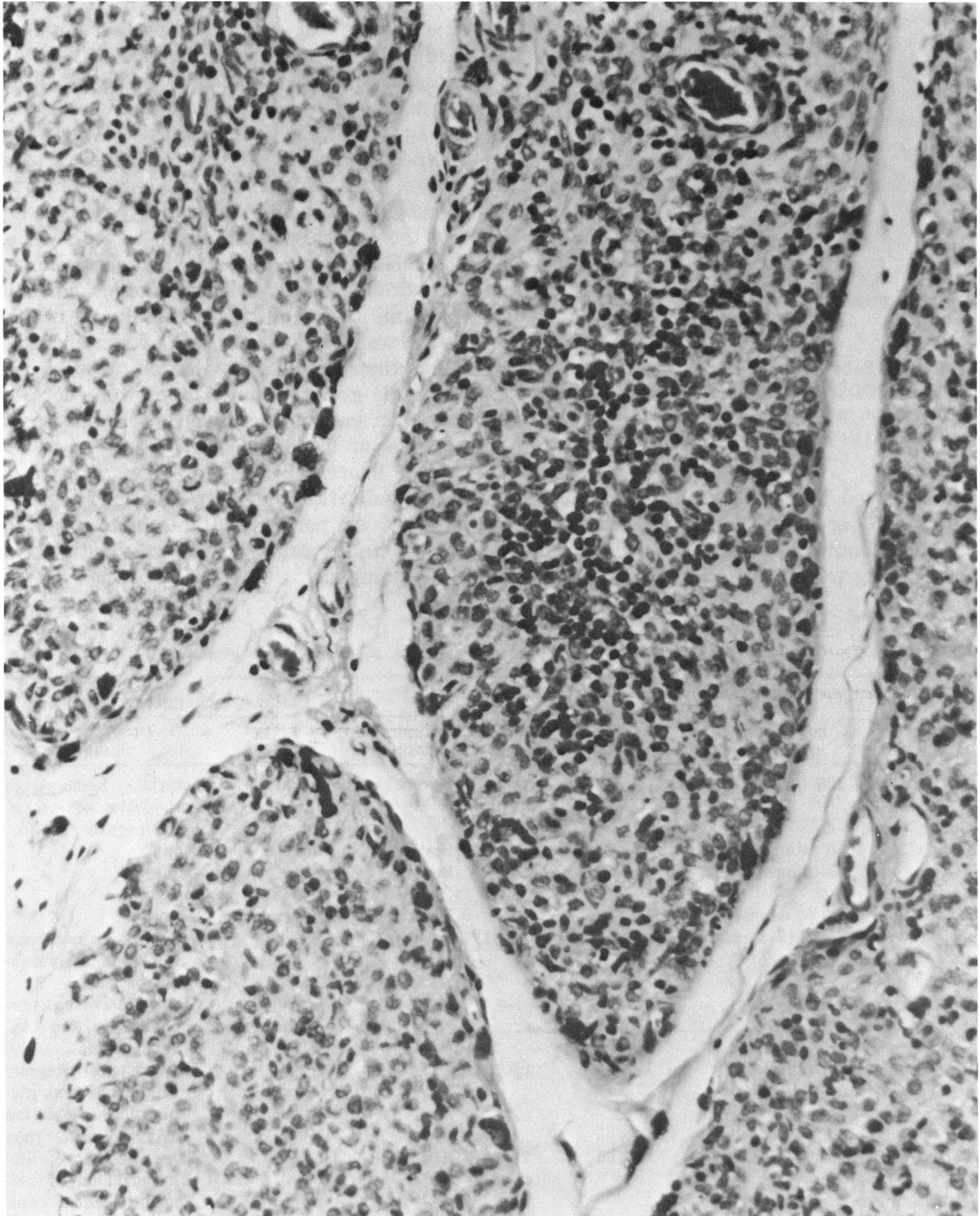
not observed in other organs of rats given 25.0 or 5.0  $\mu\text{g}$  TCDD/kg single dose, 1.0 or 0.1  $\mu\text{g}$ /kg multiple daily doses, and 5.0, 1.0, or 0.2  $\mu\text{g}$ /kg weekly doses.

All guinea pigs given weekly treatment at a level of 1.0  $\mu\text{g}$ /kg became moribund or died between 24 and 32 days after the initiation of the treatment (Table 1). Nine out of ten guinea pigs given a single dose of 3.0  $\mu\text{g}$  TCDD/kg body weight died between 15 and 28 days after treatment. There was a severe body weight loss, decreased amount of subcutaneous and visceral adipose tissues, and the guinea pigs appeared to be dehydrated. Hemorrhages were also observed in the adrenal gland, urinary bladder, gastrointestinal tract and mesenteric lymph nodes. There was marked atrophy of the thymus. Other than the relative thymic atrophy, remarkable gross tissue changes were not observed in guinea pigs given weekly doses of 0.2, 0.04 or 0.008  $\mu\text{g}$  TCDD/kg.

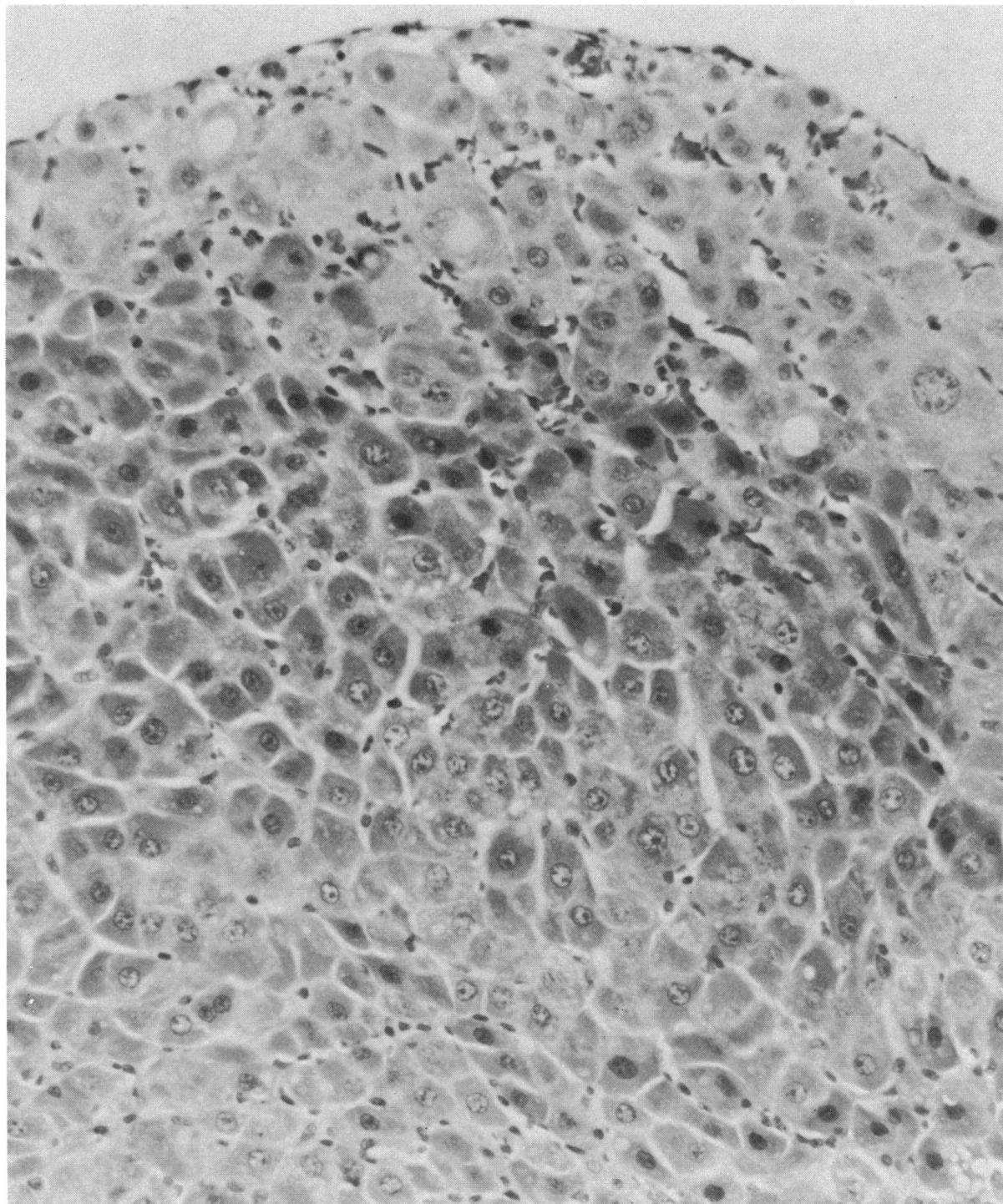
Red fluorescence under the ultraviolet light indicating the presence of excess amounts of porphyrins was not observed grossly in any organ of the rats and guinea pigs examined.

Table 1. Summary of Pathologic changes in rats, guinea pigs, and mice given TCDD orally.

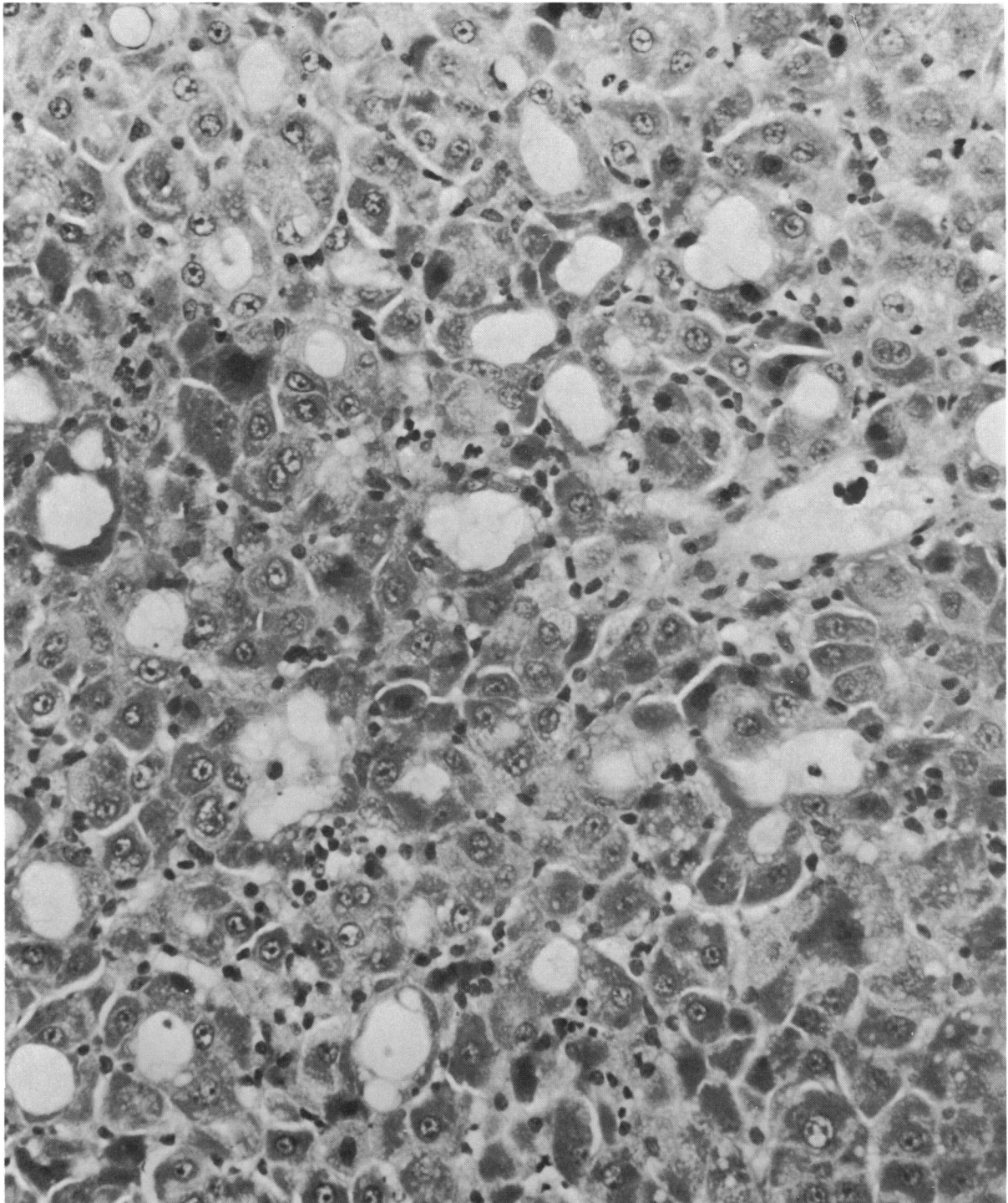
Species	Doses, $\mu\text{g}$ TCDD/kg body weight (no. of treatments)	Mortality, %	Period of death, days	Pathologic changes		
				Thymic atrophy	Liver damage	Other major changes
Rat	100 (single)	43	18-21	Severe	Severe	Icterus, hemorrhage depletion of lymphoid organs
Rat	50 (single)	7	11	Severe	Severe	None
Rat	25 (single)	0	—	Slight/moderate	None	None
Rat	5.0 (6 weekly)	0	—	Moderate	Slight	None
Rat	10.0 (16-31 daily)	94	15-31	Severe	Severe	Icterus, hemorrhage depletion of lymphoid organs
Rat	1.0 (31 daily)	0	—	Moderate	Slight/moderate	Degenerative changes in kidney and thyroid glands
Guinea pig	3.0 (single)	90	15-28	Severe	Slight	Hemorrhage atrophy of adrenal zona glomerulosa, depletion of lymphoid organs
Guinea pig	1.0 (4-5 weekly)	100	24-32	Severe	Slight	Same as above, and hyperplasia of urinary bladder epithelium
Guinea pig	0.2 (8 weekly)	0	—	Slight/moderate	None	None
Mouse	50.0 (single)	0	—	Slight	Slight	None



**FIGURE 3.** Thymus of a rat treated with 10.0  $\mu\text{g}$  TCDD/kg daily for 16 days. Notice the marked decrease in the number of cortical thymocytes and loss of demarcation between the cortex and medulla. H&E stain; magnification 307 $\times$ .



**FIGURE 4.** Liver of a rat given 31 daily treatments of 10.0  $\mu\text{g}$  TCDD/kg body weight. Regenerated hepatocytes are disorganized with moderate to marked degenerative changes. H&E stain; magnification 320 $\times$ .



**FIGURE 5.** Liver of a rat given 31 daily treatments of 10.0  $\mu\text{g}$  TCDD/kg body weight. Notice necrosis and tubule-like structures in the parenchymatous tissues of liver. H&E stain; magnification 320 $\times$ .



**FIGURE 6.** Heart of a rat given 18 daily treatments of 10.0  $\mu\text{g}$  TCDD/kg body weight, showing massive hemorrhages (H) separating the myocardial fibers (arrows). H&E stain; magnification 320 $\times$ .

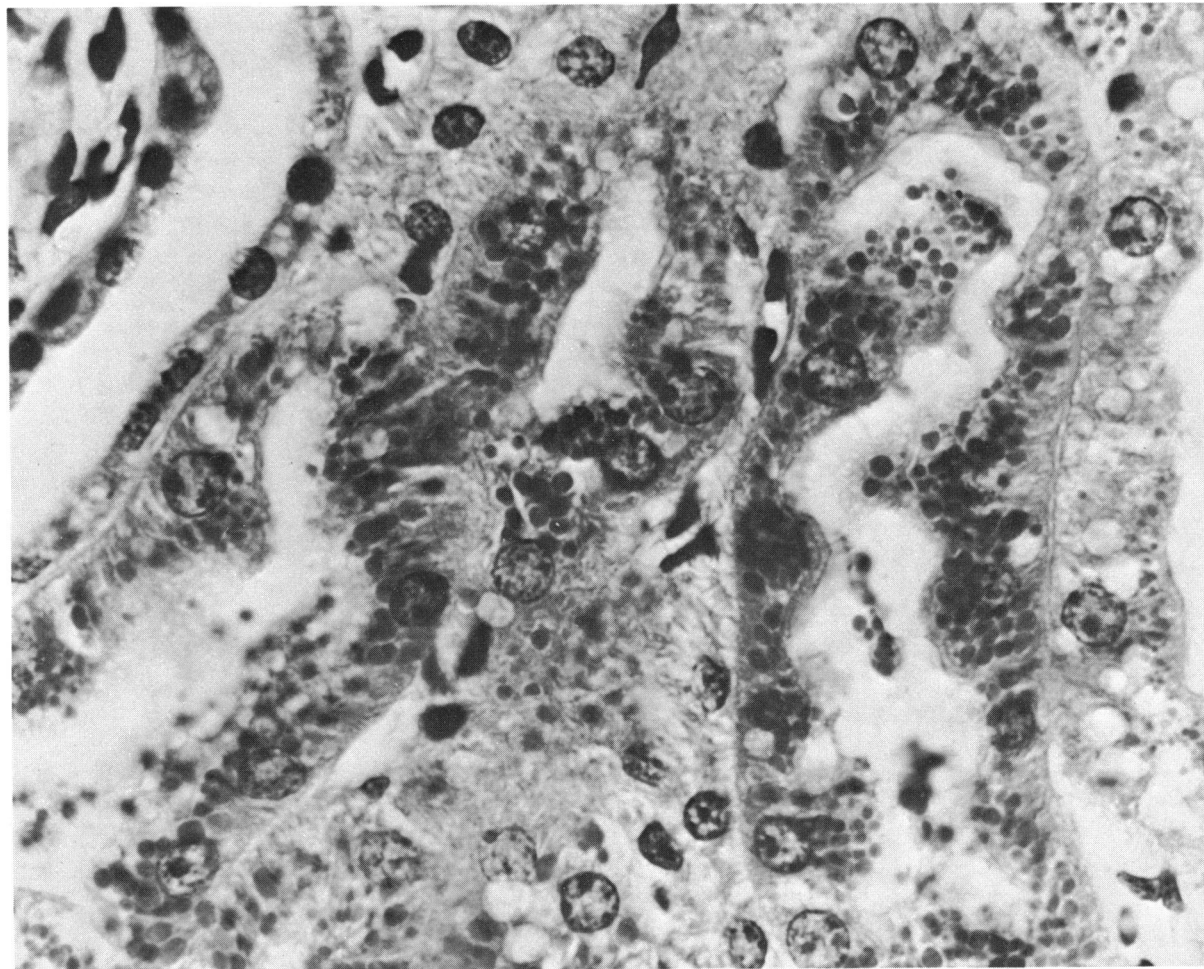


FIGURE 7. Kidney of a rat given 18 daily treatments of 10.0  $\mu\text{g}$  TCDD/kg body weight. Notice hyaline droplets, and foamy and vacuolated cytoplasm in the renal tubules. H&E stain; 904 $\times$ .

### Histopathologic Findings

**Rats**—In those rats which became moribund or died, remarkable changes were consistently observed in the thymus, liver, spleen and lymph nodes (Table 1). Changes in the ovary, uterus, gastrointestinal tract, heart, and brain were frequently observed. Marked atrophy of thymus was denoted by decrease in the number of cortical thymocytes (Fig. 3). The thymic lobules were markedly smaller, and there was no demarcation between the cortex and medulla. There was also a relative depletion of lymphoid cells in the spleen and lymph nodes. Pyknosis of the nuclei and degenerative

changes in the multinucleated megakaryocytic type giant cells of spleen and bone marrow were observed more frequently in treated rats. There was moderate to marked distortion of the architecture of liver parenchyma with marked necrosis of hepatocytes. The hepatocytes were round and large, and the hepatic cords were disorganized (Fig. 4). Some of the necrotic hepatocytes had tubulelike structures (Fig. 5). Rats which died or were killed when moribund had massive hemorrhages in the heart (Fig. 6), liver, brain, adrenal gland, and gastrointestinal tract. Occasionally, organized thrombi were observed in the heart,



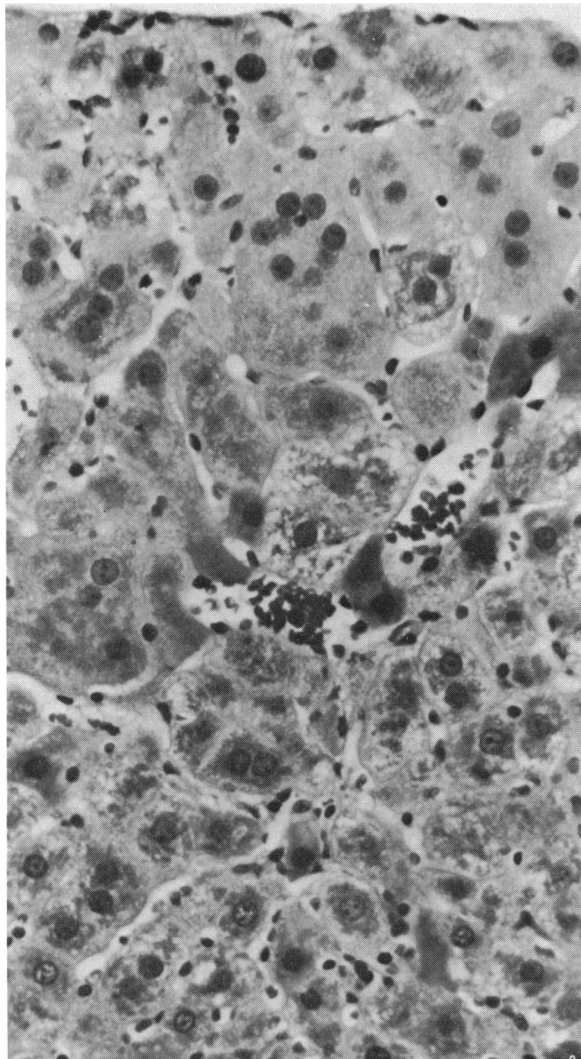


FIGURE 8. Liver of a rat given 6 weekly treatments of 5.0  $\mu\text{g}$  TCDD/kg body weight. Notice multinucleated giant hepatocytes. H&E stain; magnification 500 $\times$ .

brain, and lungs. There were necrosis and ulceration in the glandular part of the stomach. Atretic changes of the ovarian follicles were observed more frequently in treated than in control rats. There was also atrophy of mucosal folds and glandular structures of the uterus. The epithelial cells of renal tubules were foamy and vacuolated and contained numerous hyaline droplets (Fig. 7). This change was found in 3 out of 16 rats treated with 10.0  $\mu\text{g}$  TCDD/kg body weight given daily (Table 1).

Rats given sublethal doses of TCDD had regeneration of hepatic parenchyma denoted by megalocytosis and multinucleated hepatocytes (Fig. 8). There were increased mitoses in the parenchymatous tissue of liver. Some liver contained unusually large hepatocytes with seven to ten nuclei. Occasionally, a part of the cytoplasm of some hepatocytes appeared more eosinophilic and homogeneous while others contained eosinophilic hyaline bodies (Fig. 9). Swelling of hepatocytes, granular appearance of the cytoplasm, aggregation and condensation of cytoplasmic contents either around the nucleus or periphery of the cells, fatty infiltration, and vacuoles of different sizes and shapes were also observed in less affected livers.

Pyknosis and degenerative changes were observed in the connecting and collecting renal tubules of rats given multiple daily dosage during the early and middle of the study (Fig. 10). Moderate to marked degenerative changes were also observed in the epithelial cells of thyroid follicles. In addition, the epithelial lining was disorganized, exfoliated, or with papillary projections in the lumen of the follicle (Fig. 11). The follicular colloid was either absent or appeared foamy and thin. There were congestion and elongation of intestinal villi, and the goblet cells appeared to be increased only during the first half of the study.

Significant microscopic changes were not observed in different organs of rats given TCDD at levels of 0.1  $\mu\text{g}/\text{kg}$  (multiple daily doses), 5.0  $\mu\text{g}/\text{kg}$  (single dose), or 1.0 and 0.2  $\mu\text{g}/\text{kg}$  (multiple weekly doses).

**Guinea pigs**—Microscopic changes in moribund or dead guinea pigs were characterized by a severe atrophy of the cortex of thymus with destruction of lymphocytes (Table 1). Hassall bodies were large and cystic and filled with polymorphonuclear leukocytes. There was lymphoid cell depletion in spleen and lymph nodes. Hemorrhage

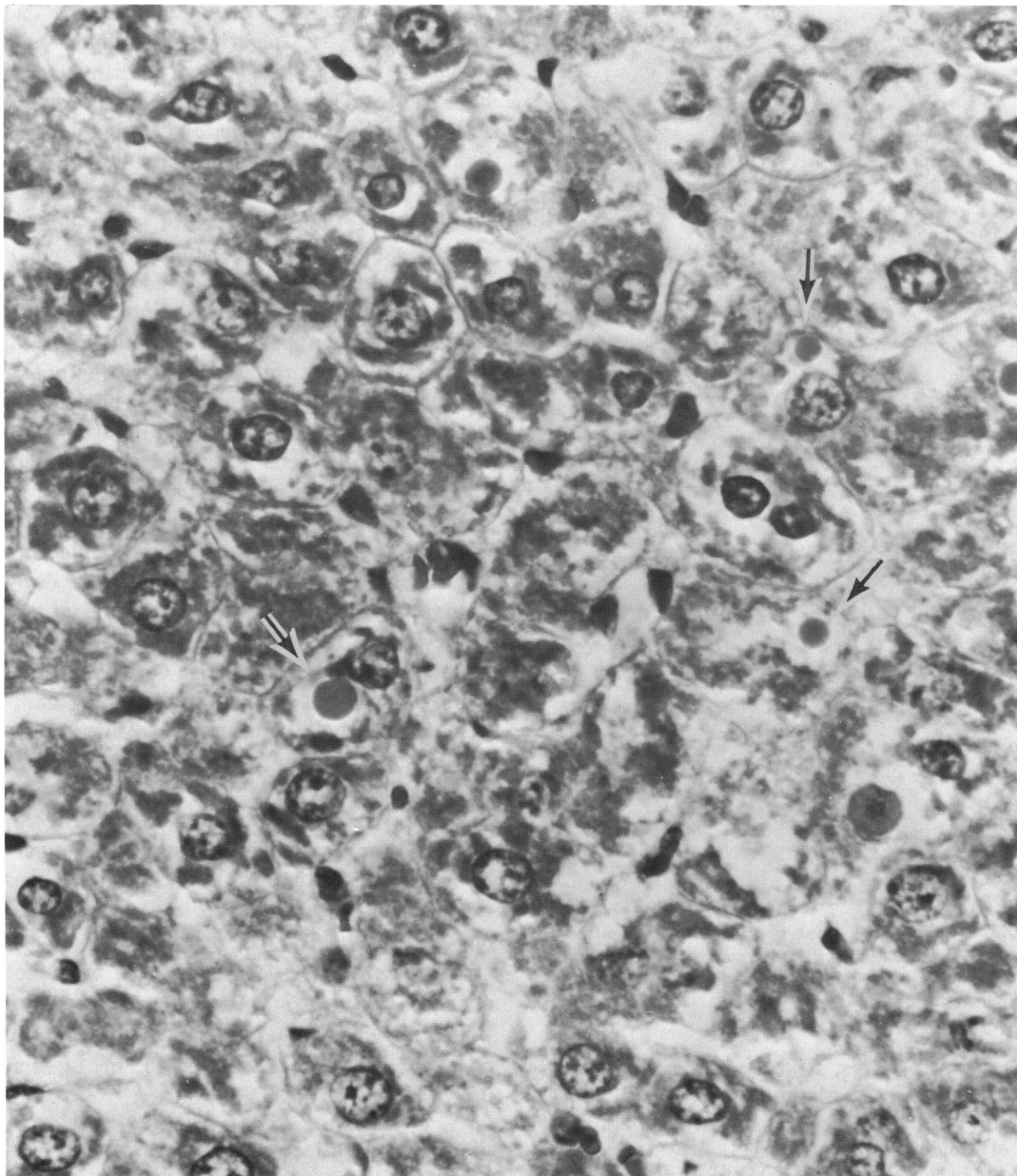


FIGURE 9. Liver of a rat given 10 daily treatments of 10.0  $\mu\text{g}$  TCDD/ kg body weight. Notice the intracytoplasmic hyaline bodies (arrows). H&E stain; magnification 950 $\times$ .

in the adrenal medulla extended into the zona reticularis and sometimes into the zona fasciculata. Atrophy of zona glomerulosa, and mitotic figures and loss of lipid

vacuoles were observed in zona fasciculata (Fig. 12). Liver effects were confined to a diffuse single cell necrosis of hepatocytes, predominantly in the periportal area. There

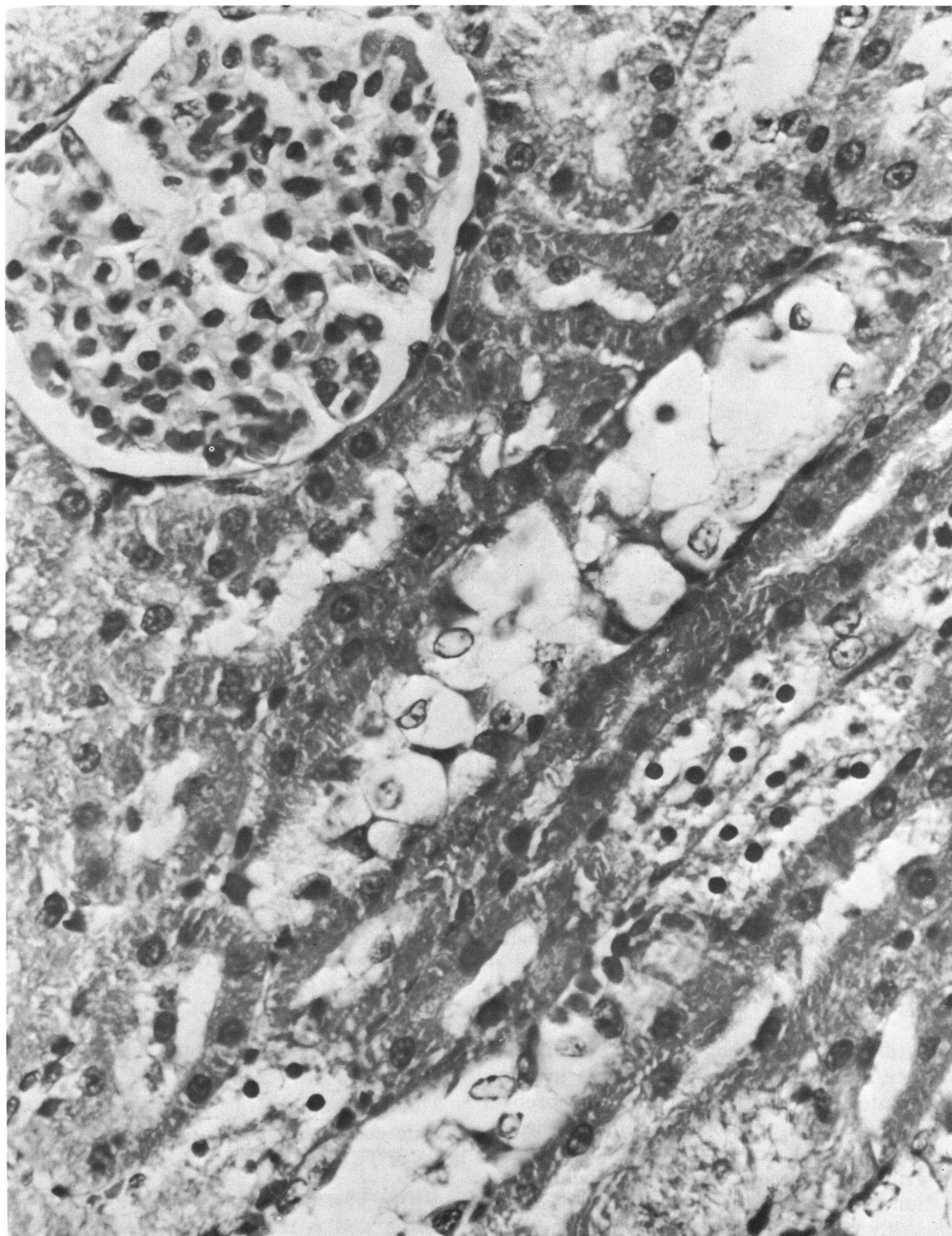


FIGURE 10. Degenerative changes and pyknosis of epithelial cells of renal tubules of a rat given 6 daily treatments of  $10.0 \mu\text{g}$  TCDD/kg body weight. H&E stain; magnification  $731\times$ .

September 1973

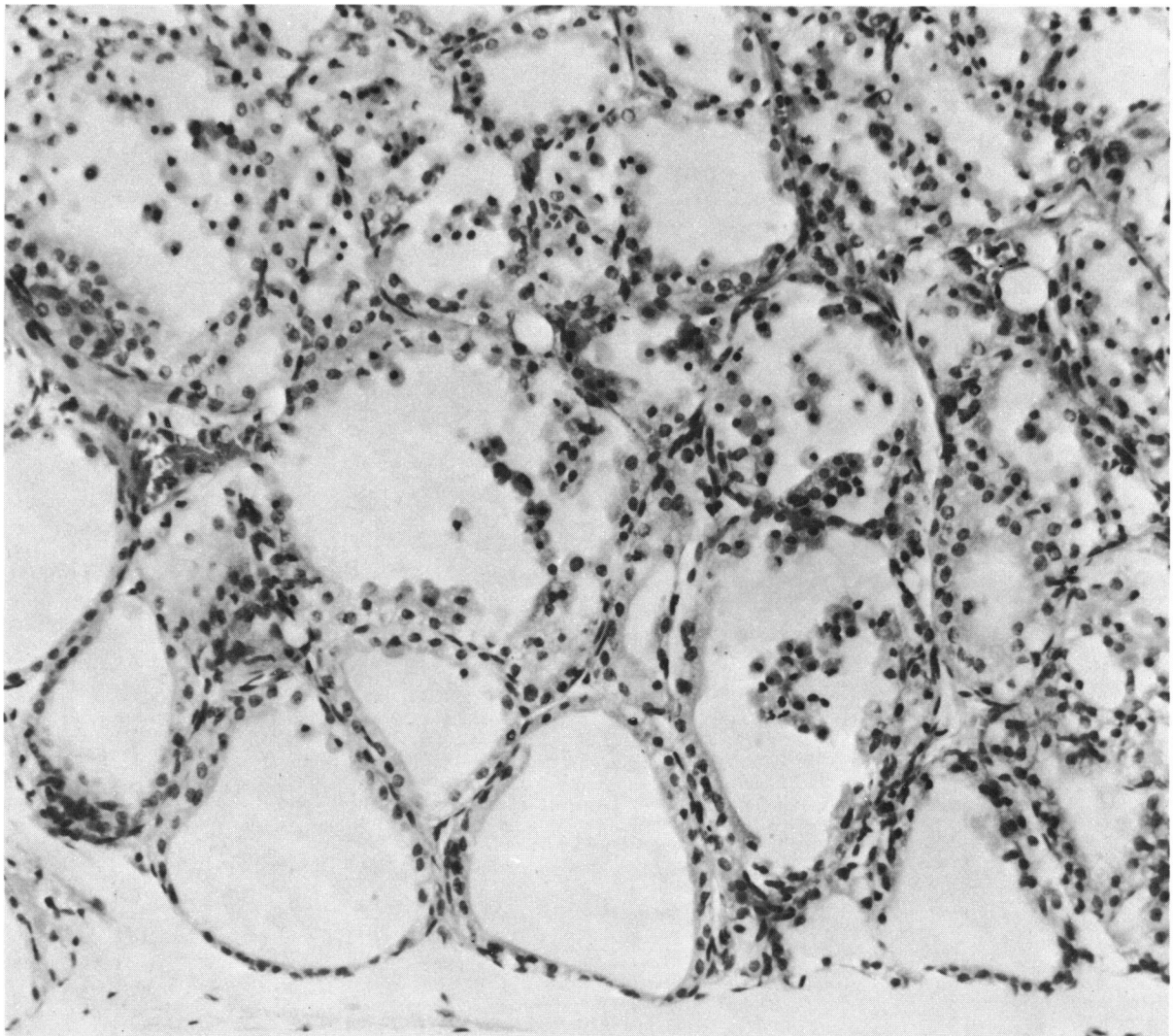


FIGURE 11. Pyknosis of nuclei, exfoliated epithelial cells and absence of colloid from the thyroid follicles of a TCDD-treated rat (10 daily treatments, 10.0  $\mu\text{g}$  TCDD/kg body weight). H&E stain; magnification 243 $\times$ .

were diffuse hemorrhages in the urinary bladder, and subserosal hemorrhages in the gastrointestinal tract. Blood pigment, probably hemosiderin, was observed in the medulla of cervical lymph nodes and lamina propria of the cecum. The transitional epithelium of urinary bladder appeared markedly hyperplastic, and the submucosal layer was edematous (Fig. 13). Occasionally, there were focal necrosis of smooth

muscle cells and infiltration of inflammatory cells in the urinary bladder.

There was slight to moderate atrophy of thymic cortex of guinea pigs given weekly doses of TCDD of 0.2  $\mu\text{g}/\text{kg}$ .

*Mice*—There was some hepatocellular swelling and a relative reduction of lymphoid cells in the thymus of mice 21 days after receiving a single 50  $\mu\text{g}/\text{kg}$  dose of

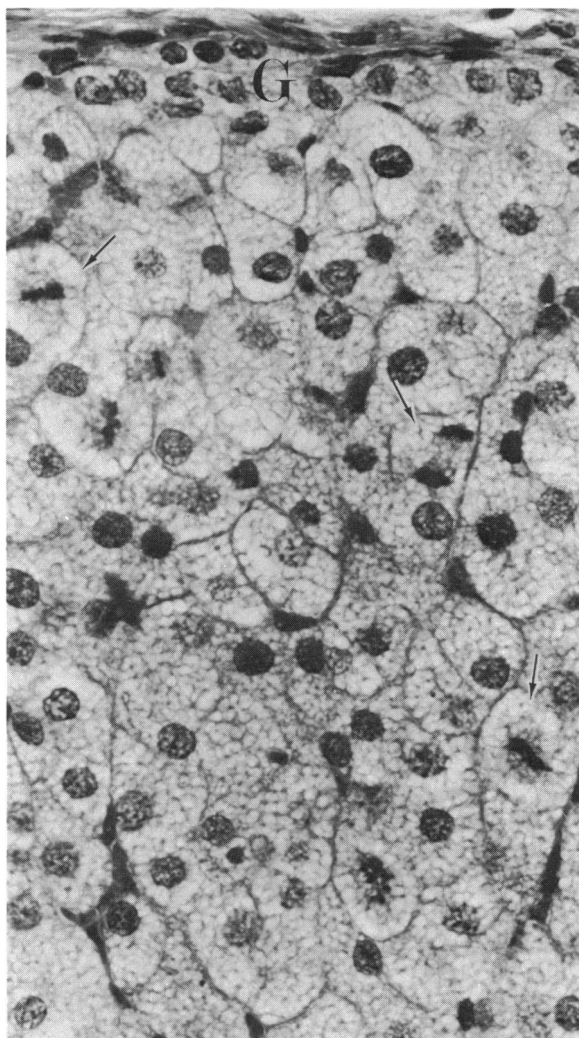


FIGURE 12. Atrophy of zona glomerulosa (G) and mitoses (arrows) in the zona fasciculata of adrenal gland of a guinea pig given 4 weekly doses of 1.0  $\mu\text{g}$  TCDD/kg body weight. H&E stain; magnification 176 $\times$ .

TCDD. However, microscopic changes were variable from one animal to another. No changes were observed in these tissues in mice necropsied 7 or 35 days after TCDD exposure. No effects were seen in mice given lower doses.

## Discussion

The main target organs of TCDD appear to be the liver of rats and the thymus of rats, guinea pigs, and mice. TCDD caused thymic atrophy in all three species. Liver

lesions severe enough to account for death were seen only in rats. The liver lesions seen in guinea pigs and mice were mild by comparison. Other lesions such as hemorrhages, degenerative changes in kidney, thyroid, megakaryocytes in spleen, ovarian follicles, lymphoid depletion of the spleen and lymph nodes in rats, and hemorrhages, hyperplasia of the urinary bladder mucosa, and atrophy of the adrenal zona glomerulosa in guinea pigs were also seen.

The liver lesions in rats dying after TCDD exposure were strikingly similar. This hepatotoxic reaction was characterized by such degenerative changes as swelling of hepatocytes, fatty metamorphosis and ultimately necrosis in rats which received 10  $\mu\text{g}$  TCDD/kg-day for 10–13 days. At this time there was also an increase in serum transaminases activities (5). Thereafter, the hepatic lesions progressed and the weight of the liver decreased as more parenchymatous tissue was destroyed. Hyperbilirubinemia and hypoproteinemia (5) became inadequate and death soon followed in the icteric animals. Besides these degenerative lesions, large multinucleated giant hepatocytes were also seen in liver of TCDD treated rats. The presence of these cells, increased numbers of mitotic figures and pleomorphism of cord cells suggest that a long term study should be done to assess the possibility of the development of hyperplastic nodules and/or neoplasm. Increases in liver weight (4) can be explained by swelling of hepatocytes, fatty metamorphosis, proliferation of smooth and rough endoplasmic reticulum as shown by electron microscopy (6), concomitant with induction of hepatic microsomal enzymes (7).

Although a marked difference in the amount of TCDD needed to produce thymic atrophy occurred between species, the severity of the lesion was dose-dependent within a species (4). It was also the organ most sensitive to TCDD treatment (4). In both guinea pigs and mice, the cell-mediated immune response was depressed; lymphopenia also occurred. In contrast, cell-mediated immunity was not suppressed and lymphopenia

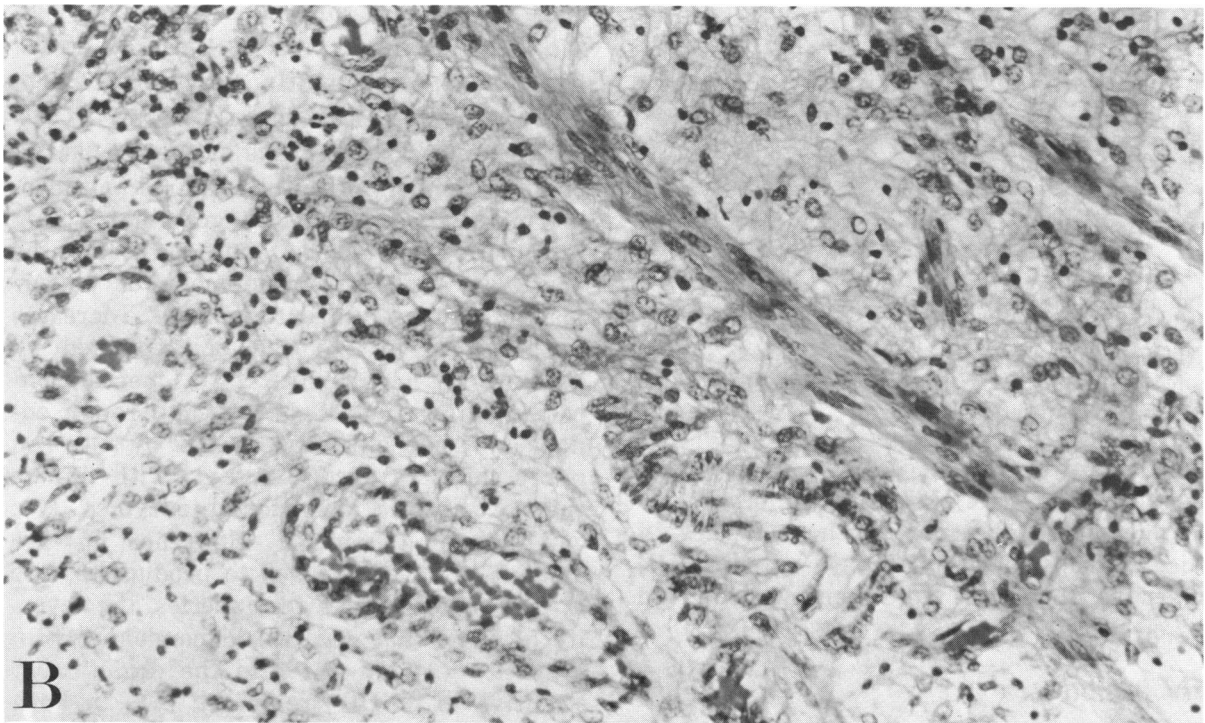
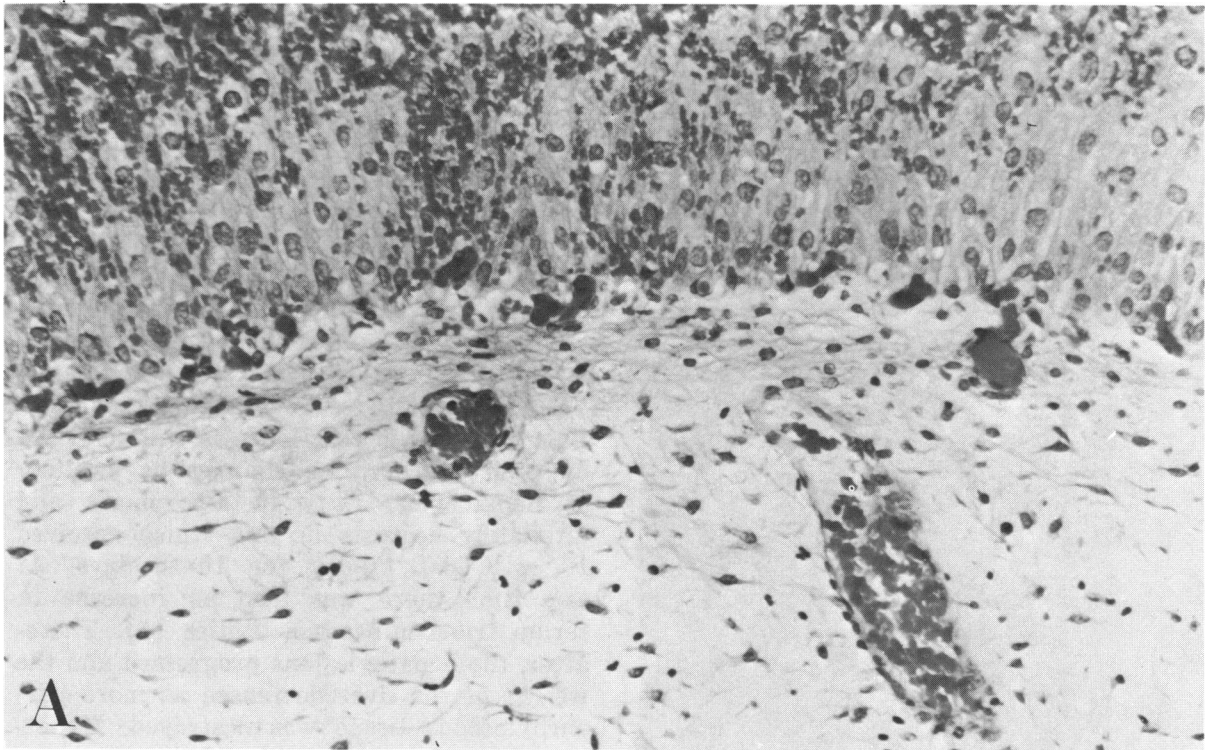


FIGURE 13. Urinary bladder of a guinea pig treated with 4 weekly doses of  $1.0 \mu\text{g}$  TCDD/kg body weight: (A) Notice marked hyperplasia of epithelial cells, congestion, hemorrhage, and edema; (B) infiltration of inflammatory cells into the submucosal and muscular layers. H&E stain; magnification  $214\times$ .

did not occur in the rat (8).

The only other lesion seen with some consistency was hemorrhage of various organs in dead or dying rats and guinea pigs. A possible cause of these hemorrhages might be the thrombocytopenia seen in these two species (5). The thrombocytopenia might be due to the reduction in number of and necrosis of megakaryocytes seen in the spleen and bone marrow of rats. However, in another study, megakaryocyte numbers and morphology were not altered by TCDD treatment (9). The hemorrhages might be caused by platelet deficiency or abnormalities in the clotting mechanism (9).

Porphyria was not seen in rats and guinea pigs dying from TCDD which agrees with the finding that TCDD did not increase hepatic  $\delta$ -aminolevulinic acid synthetase activities in rats (10). However, a marked increased activity of this enzyme was demonstrated in chick embryo liver (11). Therefore, it appears that species differences to the porphyrogenic action of TCDD exist.

## Summary

Gross pathologic and histopathologic examinations were performed on rats, guinea pigs and mice treated with TCDD. In rats and guinea pigs, dose ranged from no effect to one which produced death; frequency of dose ranged from a single intubation to daily or weekly administration for several weeks. Lymphoid organs, primarily thymus, were consistently affected over a wide spectrum of dose ranges in all species examined. Atrophy of the thymus, as denoted by a dose-related decrease in weight and decrease in cortical thymocytes, was a very sensitive index of TCDD exposure. Relative depletion of lymphoid cells in spleen and lymph nodes was also observed.

The liver was the only other organ in which microscopic changes were observed consistently. The degree of hepatic involvement seemed dose-dependent, but severity of changes produced was quite variable between species. The most severe hepatic effects were seen in rats which received a lethal

dose of TCDD. These rats, which were jaundiced, had diffuse degenerative and necrotic changes in the liver. At sublethal dose levels, transient degenerative changes in the liver were followed by megalocytosis, regeneration and unusual numbers of multinucleated giant hepatocytes. Other changes found inconsistently were hemorrhage in the gastrointestinal tract, heart, and brain as well as organized thrombi in various organs. Moderate to marked degenerative and necrotic changes were also observed in the epithelial cells of renal connecting and collecting tubules and thyroid follicles.

Although degenerative and necrotic changes in liver were also observed in guinea pigs and mice, the magnitude of these effects were markedly diminished. To illustrate this point, hepatic changes produced at lethal TCDD levels in the rat were severe enough to be a contributing cause of death, while hepatic changes in the guinea pig receiving a lethal dose were quite mild.

## Acknowledgement

The technical assistance of Ms. M. W. Harris, W. A. Watson, J. O. Taylor, F. A. Talley, M. G. Matheson, and A. B. Duke is gratefully acknowledged.

## REFERENCES

1. Schulz, K. H. Clinical picture and etiology of chloracne. *Arbeitsmed.-Sozialmed. Arbeitshyg.* 3: 25 (1968).
2. Buu-Hoi, N. P., et al. Organs as targets of "dioxin" (2,3,7,8-tetrachlorodibenzo-*p*-dioxin) intoxication. *Naturwiss.* 59: 174 (1972).
3. Allen, J. R., and Carstens, L. A. Light and electron microscopic observations in *Macaca mulatta* monkeys fed toxic fat. *Amer. J. Vet. Res.*, 28: 1513 (1967).
4. Harris, M., et al. General biological effects of TCDD in laboratory animals. *Environ. Health Perspect.* No. 5: 101 (1973).
5. Zinkl, J. G., et al. Hematologic and clinical chemical effects of 2,3,7,8-tetrachlorodibenzodioxin in laboratory animals. *Environ. Health Perspect.* No. 5: 100 (1973).
6. Fowler, B. A., et al. Ultrastructural changes in rat liver cells following a single injection of

- TCDD. Environ. Health Perspect. No. 5: 141 (1973).
7. Lucier, G., et al. Studies on TCDD-induced changes in rat liver microsomal and mitochondrial enzymes. Environ. Health Perspect. No. 5: 199 (1973).
  8. Vos, J. G., et al. Effect of TCDD on the immune system of laboratory animals. Environ. Health Perspect. No. 5: 149 (1973).
  9. Weissberg, J., and Zinkl, J. G. Effects of TCDD upon hemostasis and hematologic function in the rat. Environ. Health Perspect. No. 5: 111 (1973).
  10. Woods, J. Studies of the effects of TCDD on mammalian hepatic  $\delta$ -aminolevulinic acid synthetase. Environ. Health Perspect. No. 5: 221 (1973).
  11. Poland, A., and Glover, E. Studies on the mechanism of action of the halogenated dibenzo-*p*-dioxins. Environ. Health Perspect. No. 5: 245 (1973).