

Pulmonary Response to Polyurethane Dust

by Klaus L. Stemmer,* Eula Bingham,* and William Barkley*

Weanling and 9 months or older rats were exposed to particles of an aged (PUF I) or freshly prepared (PUF II) rigid polyurethane foam by intratracheal intubation. The dose was 5 mg of particles. The response of the lung tissue was examined morphologically by serial sacrifices. Inflammation and macrophage activity were the initial responses. Fibrosis developed after 6 months. Nodular scars and perifocal emphysema were seen after 12 months. Four rats had a papillary adenoma in a major bronchus after 18 months exposure to PUF II.

There is widespread usage of polyurethane foam in the insulation and construction industries. The potential for exposure of workers to dusts generated during cutting operations led Laskin and co-workers to initiate inhalation studies with freshly generated polyurethane foam dusts. (1).

In these experiments rats and hamsters were exposed by inhalation to polyurethane foam particles (3.6 or 20 mg/m³) for 5 days/week for 6 weeks. The plastic was a rigid foam used for structural insulation. These investigators found two squamous cell carcinomas among the exposed rats, one at each of the two dosage levels and, in addition, pulmonary lesions including centrilobular emphysema.

The studies presented at this meeting had as their objectives to define the morphological lesions induced by polyurethane particles, to determine the usefulness of intratracheal intubations of the particles as a procedure for comparative evaluation of pulmonary response to polyurethane particles, and to compare aged and young rats in their toxic responses, especially the average latent period for neoplasms.

These experiments using intratracheal intubations were not intended to replace inhalation exposures but were considered an exploratory effort to determine where it was possible to use this procedure as a screening technique and whether the test period required for

carcinogenic bioassay could be shortened using aged animals. Concomitant with this investigation, inhalation studies with rats were conducted by another laboratory for comparison.

Methods

White rats (Greenacres, controlled flora) of both sexes were used. The young ones were 2 to 3 months of age, whereas, the older ones ranged from 9 to 19 months at the time the plastic particles were intubated.

The procedure of intubation is as follows. While one operator holds the rat on a restraining rack, another visualizes the vocal cords and inserts into the trachea a blunt 20 gauge, 10 cm long needle with a Teflon tip. The Teflon tip is cooled to render it less flexible. A 1-ml syringe containing the dust suspended in saline is then attached to the needle. After injection of the suspension the syringe is replaced with one containing saline to wash through the needle to insure that the entire dosage of dust reaches the lung.

The concentration of the dust in the saline was 20 mg/ml. Of this suspension, 0.2 ml was intubated, giving a dose of 50 mg of dust which was followed by 0.3 ml of saline. The control animals received 0.5 ml of saline. The dose of 5 mg of polyurethane dust was calculated and based on the total amount of dust that may have been inhaled by the rats over a period of 30 days for an 8-hr exposure at a level between

* University of Cincinnati, Cincinnati, Ohio 45219.

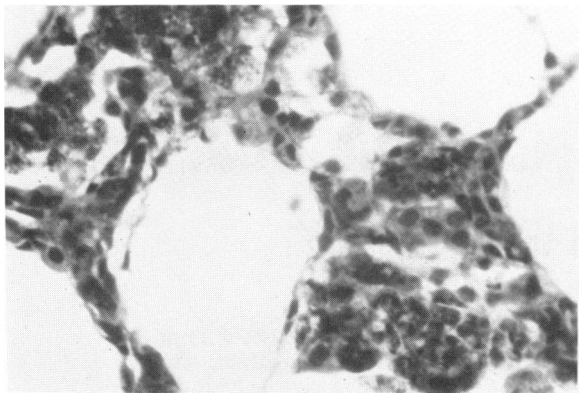


FIGURE 1. Infiltration by lymphocytes and accumulation of macrophages. One month exposure; PUF I; H & E stain. Original 50 \times .

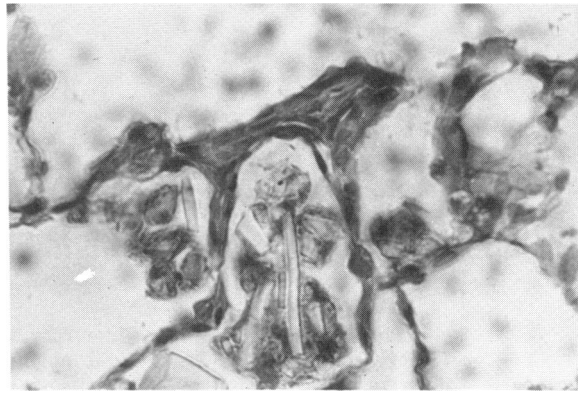


FIGURE 3. Macrophage activity with different sizes of particles. There is also early fibrosis of the alveolar wall. Six months exposure; PUF I; H & E stain. Original 50 \times .

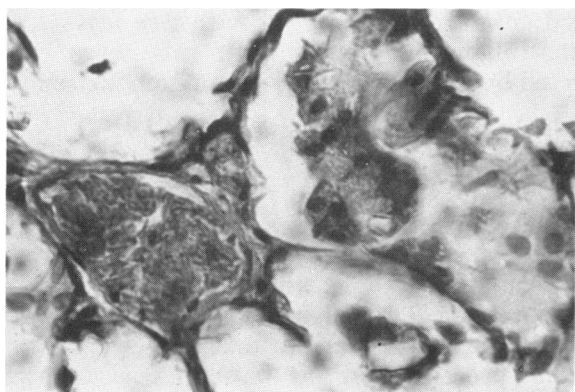


FIGURE 2. Shape of the particles and their size. Clusters of macrophages are enveloping the particles. The alveolar walls are unaffected. One month exposure; PUF II; H & E stain. Original 50 \times .

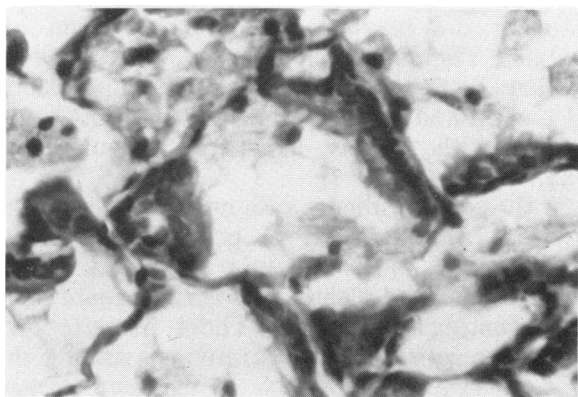


FIGURE 4. Epithelization of alveolar walls. Several macrophages can be seen. Six months exposure; PUF II; H & E stain. Original 50 \times .

the low and high concentrations used by Laskin et al. in inhalation exposures.

Two types of polyurethane dust were used. The original material administered by Laskin was designated PUF I. An unused portion of the polyurethane foam block had been stored and was made available to us. The other one, PUF II, was a freshly prepared sample manufactured to come as close in its composition to PUF I as possible. The particles were prepared by the National Institute of Occupational Safety and Health. Of the particles, 52% had an aerodynamic diameter of 5 μm or less and 93.5% of 10 μm or less.

Most of the animals were sacrificed after a longer post-exposure period (9, 12, 18, and 24 months) to determine their response (Table 1). Rats were sacrificed at short intervals (1, 3, and 6 months) after injection to follow the pulmonary response in its early stages. At autopsy the trachea and lungs were removed and infiltrated with neutral formalin via the trachea at a pressure of 20 cm of water. The fixed lungs were cut in blocks and embedded in paraffin. Sections were cut at 8 μm . Routine stains were hematoxylin and eosin. Special staining was done where indicated.

Results

The early response of the lung was that of inflammation. The particles were deposited in the respiratory bronchi and in the subpleural alveoli. There was an infiltrate by lymphocytes and marked macrophage activity (Fig. 1). The particles had a flakelike shape. The intubation obviously introduces larger particles into the lung which probably would not have occurred by the inhalation route of exposure (Fig. 2).

Six months after the intubation the macrophage response was still intense. Slight thickening of the alveolar walls occurred, and epithelization would be seen (Figs. 3 and 4). Many dust particles were still harbored in the lung, so macrophage activity was considered a continuous event involving an uninterrupted influx of new cells after the breakdown of the old ones.

Nine months after intubation the fibrosis has progressed. Inflammation was present manifested by lymphocytes and macrophages. The fibrosis involved primarily the respiratory bronchus and adjacent alveoli (Fig. 5). The pulmonary structure was still intact, although enlargement of the air spaces in the centrilobular region was seen. The emphysema is of low degree.

Small scars consisting of fibrous tissue nodules developed after 12 months. At this time, there was still a slight lymphocytic infil-

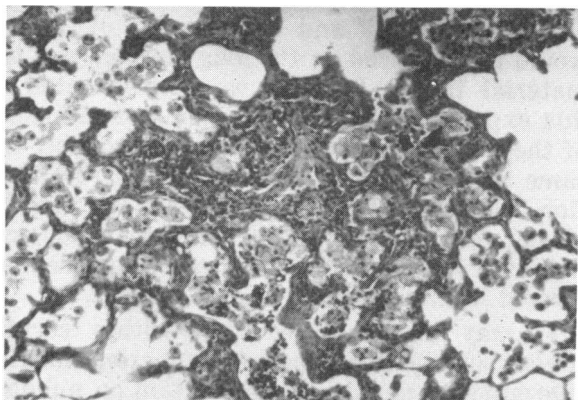


FIGURE 5. An advanced stage of fibrosis. There is still lymphocytic infiltrate and large numbers of macrophages. Nine months exposure; PUF I; H & E stain. Original 50 \times .

Table 1. Summary of length of survival after single exposure.*

Compound	Age at intubation, months	Post-intubation period, months	Age at autopsy, months	No. of rats at autopsy
Control	3	24	27	12
PUF I	2	9	11	10
	2	12	14	10
	3	24	27	6
PUF II	4	18	22	15
	Control	13	18	31
PUF I	19	12	31	8
	11	9	20	10
	11	12	23	9
PUF II	13	18	31	5
	19	12	31	9

* In each group were additional rats which were sacrificed at earlier intervals.

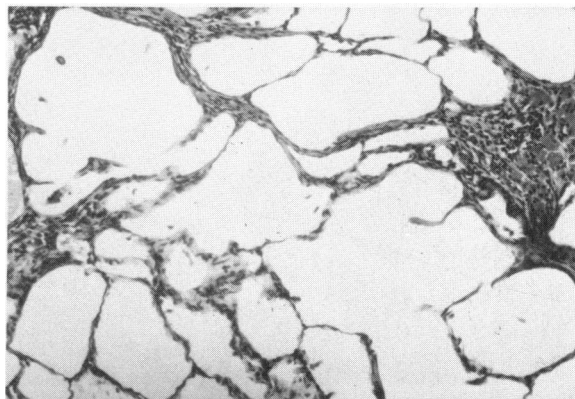


FIGURE 6. Early scars with loss of alveolar septa and significant perifocal emphysema. Twelve months exposure; PUF II; H & E stain. Original 50 \times .

trate. In cases where these nodules were subpleural, fibrosis of the pleura occurred. These foci could be seen at autopsy as small white dots. Surrounding the scar was a perifocal emphysema (Fig. 6).

The end stage of response was demonstrated also in later sacrifices (18 and 24 months). Table 2 summarizes the distribution of pathologic alterations in the different experimental groups. There were no differences between young and old animals nor between the males and females. The frequency of scarring and emphysema was similar for both dusts. In each microscopic section three to five foci of scarring and emphysema were present.

Table 2. Summary of pulmonary lesions.

Compound	Age at autopsy, months	No. rats with lesion/no. of rats examined		
		Scars	Emphysema ^a	Tumors
Young rats				
Control	27	0/12	0/12	0/12
PUF I	11	2/10	3/10	0/10
	14	6/10	6/10	0/10
	27	6/6	6/6	0/10
PUF II	22	10/15	12/15	4/15
Old rats				
Control	31	0/12	0/12	0/12
PUF I	20	5/10	5/10	0/10
	23	7/9	8/9	0/10
	31	5/5	5/5	0/10
PUF II	31	8/9	8/9	0/10

^a Centrilobular and perifocal types combined.

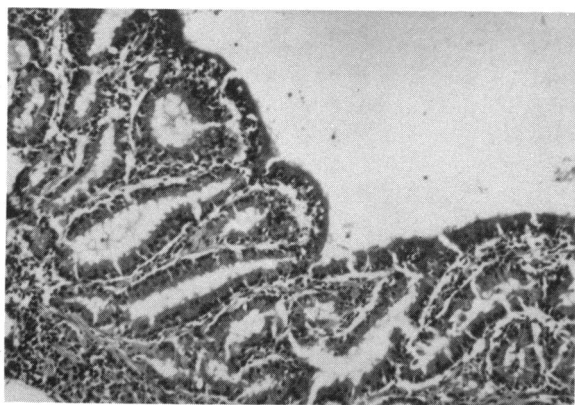


FIGURE 7. Segment of papillary adenoma of bronchus. Eighteen months exposure; PUF II; H & E stain. Original 50 \times .

Estimating the potential for induction of pulmonary neoplasms by the two dusts was of great interest in the study. A hyperplastic lesion in one of the rats (PUF I, old) was observed subpleurally and structurally was a fine papillary formation of fibrous tissue covered by a mature low cuboidal epithelium. Dust particles could not be demonstrated in the lesion. None of the other animals had a similar tumorlike formation in either the treated or control groups. The significance of this lesion is uncertain.

Eighteen months after the intubation, in one group of old rats exposed to 5 mg of PUF II, neoplasms were found. Generally, the lungs of these animals showed a hyperplastic bronchial

epithelium. Multiple papillomalike formations were seen in the large and smaller bronchi. This alteration was considered a hyperplasia and not a neoplasia, although these papilloma-like formations may develop into true neoplasms of the type we found in four rats in this group. These tumors were located in the bronchi and were composed of high columnar epithelium. They are papillary in structure (Fig. 7). The epithelial cells are mature. No invasion into the bronchial wall is present. The neoplasms were classified as benign intrabronchial adenomas.

The control rats exhibited none of the described lesions or neoplasms.

Comments

Whether the fibrosis and scars are caused solely by the polyurethane particles or their breakdown products is unknown, however, particles could be demonstrated at nine months after a single intratracheal intubation. Since the lifetime of the macrophages is relatively short, one has to assume that a large number of these cells disintegrated in the lung over a period of months. The release of their intracellular content may have played a role in causing the fibrosis of the lung.

Because of the small number of scars and foci of emphysema, there was probably no functional impairment of the lungs in the experimental animals. However, one has to consider that in this experiment only one intubation was made. Exposure over long periods of time would result in new depositions of particles. The development and progression of lesions would be enhanced by the long residency of the material in the lung as we demonstrated in this experiment. The mechanisms of clearance of these particles from the lung is probably the same as for other particles. However, in addition, consider that a certain amount of the plastic may be broken down by the biological activity of the macrophages, as has been demonstrated in implanted plastic prostheses.

It may be concluded that within certain limitations the intratracheal intubation can give relevant and pertinent information on pulmonary response to plastic dusts. Not only can the development of a lesion be followed but one may determine in a simple way the approximate residence time of particles in the lung. The latter we consider to be a significant factor

in the development of pulmonary alterations. The method is simple, allows for applications of precise doses of material, and is not prohibitive in terms of technical feasibility.

The response of the lung to polyurethane particles is not unique. One can state that it is the typical lesion seen after exposure to a variety of particulate matter. In this connection it might be more important to focus on the role of the macrophage breakdown products than on the chemical nature of the particle.

In regard to the development of neoplasms, the old rats seem not to have any advantage. The period until the occurrence of tumors was not shortened by increasing the age of the animal prior to the exposure. The length of time required for a neoplasm to develop appears once again to be 18 months or longer after the initial exposure. This recognition that a long latent period is required before one can reasonably expect to observe tumors cannot be emphasized too strongly in experimental carcinogenesis.

It may be of significance that the newly prepared sample of the polyurethane foam

caused the neoplasia. The sample (PUF I) originally used by Laskin (1) was several years old by the time we tested it. During this time aging of the foam certainly has altered its molecular composition. Laskin induced neoplasms in animals exposed to freshly generated dust. The type was different in Laskin's animals; however, we still consider the occurrence of tumors in current experiments to be significant.

Acknowledgements

This work was funded by the Society of Plastics Industry and in part by the Center for the Study of the Human Environment, USPHS Grant ES-00159.

REFERENCE

1. Laskin, S., et al. Inhalation studies with freshly generated polyurethane foam dust. In: Assessment of Airborne Particles. Fundamentals, Applications, and Implications to Inhalation Toxicity. T. T. Mercer, P. E. Morrow, and W. Stöber, Eds., Charles C Thomas, Springfield, Ill., 1972, p. 540.