

# Pulmonary Toxicity of Bleomycin

by Ian Y. R. Adamson\*

Diffuse pulmonary fibrosis is associated with bleomycin administration to humans. The sequential reactions of lung cells to this drug have now been investigated in mice following injection of 20 mg/kg bleomycin twice per week for 4 to 8 weeks. Cytoplasmic and subendothelial edema was first observed in large vessels and by 4 weeks involved the capillaries. The reaction in many animals did not progress further than endothelial lesions with accumulation of interstitial edema. However 30% of mice subsequently showed necrosis of type 1 epithelium with a fibrinous exudate in the alveoli. Fibroblastic organization of the fibrin resulted in the deposition of intraalveolar collagen as well as extensive septal fibrosis by 8 weeks. Epithelial repair, normally accomplished by type 2 cell proliferation and transformation to type 1 cells, is characterized in this case by division and metaplasia of type 2 cells. The metaplastic cells were, however, capable of DNA synthesis and probably of further cell division. The results indicate that the pulmonary endothelium is the initial site of injury. Extensive damage to these cells could allow the drug access to interstitial and epithelial cells. Focal necrosis of type 1 epithelium is the critical event that triggers the exudation of fibrin and the subsequent reparative processes.

The antibiotic bleomycin has been used over the last few years with some success in the treatment of certain types of tumor. The drug was first isolated from *Streptomyces verticillatus* by a Japanese group headed by Umezawa (1,2), who showed bleomycin to be a mixture of water-soluble peptides with differences in their terminal amine groups. Separation of these compounds was achieved and clinical trials were carried out on several of them. Initially, the drug was found to be effective on squamous cell carcinoma without inducing the renal toxicity that was found with related antibiotics, and in recent years bleomycin has been particularly successful in the treatment of skin tumors. Advantages of this therapeutic agent are the apparent absence of hematopoietic toxicity or immunosuppressive activity (2). With increasing use, however, it is now recognized that diffuse pulmonary fibrosis is a potential complication of bleomycin therapy.

There have been a few published case reports indicating pulmonary side effects of the drug, for

instance, the paper by Rudders and Hensley on a patient receiving bleomycin for a sarcoma (3). There was tumor regression, but the patient died of diffuse interstitial pneumonitis and pulmonary fibrosis. There have been two cases in Winnipeg in the last 6 months where similar pulmonary disease developed during bleomycin therapy for a tumor. Light and electron microscopy revealed diffuse pulmonary fibrosis with collagen deposition in interstitial regions as well as in the airways. Many alveoli were lined by cuboidal epithelial cells, often undifferentiated resembling those of fetal lung.

The problem associated with drug evaluation from such clinical material is the well known one of trying to decipher the specific reaction of bleomycin when several other drugs and, often radiation, have also been administered to a sick patient. A pulmonary reaction to the drug might have been foreseen from the original drug retention data of Umezawa (1). After one dose of bleomycin to mice, a high level of drug was present in the kidney and lung 5 hr later; by 5 days significant amounts were still present in skin and lung, while other organs were virtually drug-free.

\* Pathology Department, University of Manitoba, Winnipeg R3E 0W3, Canada.

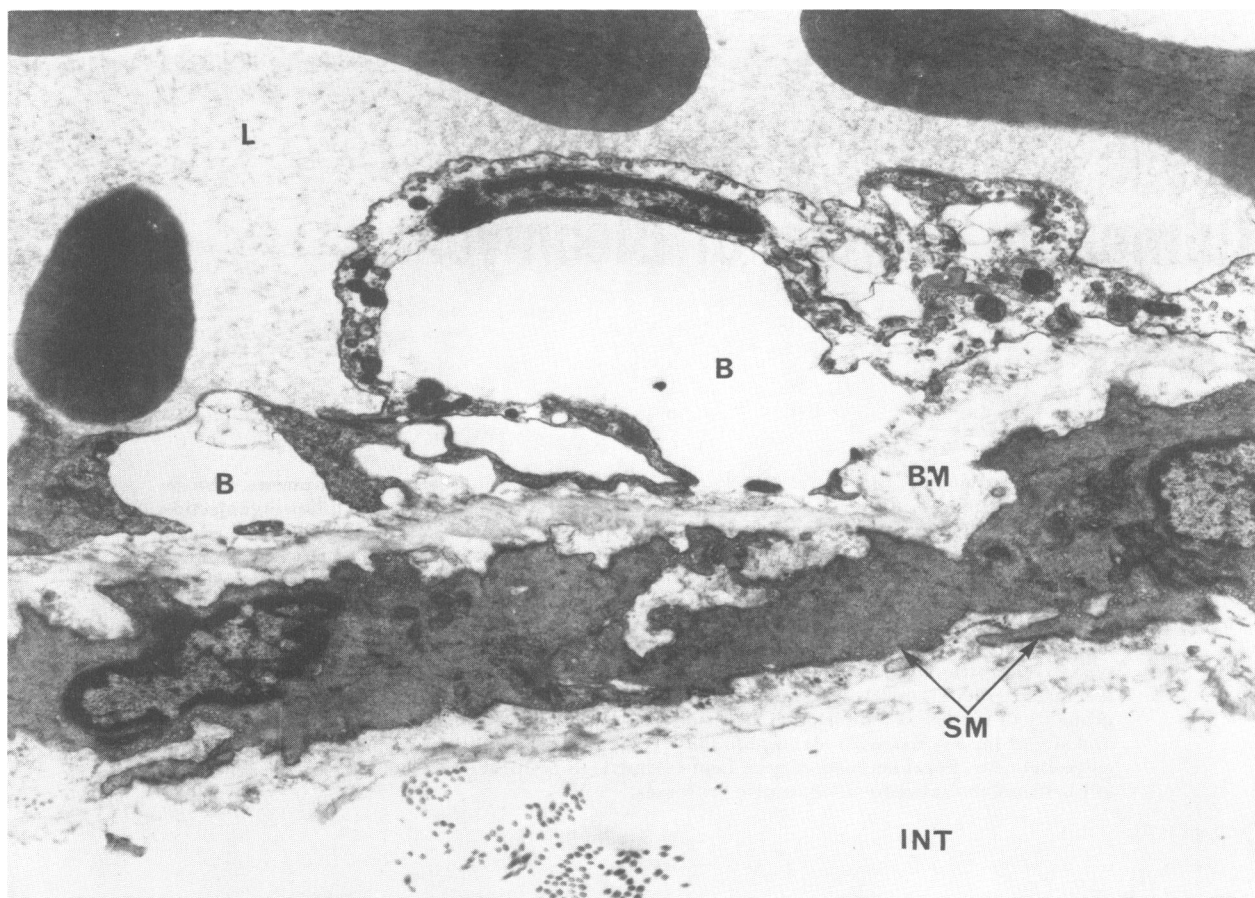


FIGURE 1. Electron micrograph of the wall of a pulmonary vein after 2 weeks bleomycin (20 mg/kg twice per week). The endothelial cell is edematous and is separated from basement membrane (BM) at several places by subendothelial blebs (B). L denotes lumen; SM, smooth muscle; INT, interstitium.  $\times 14,000$ .

## Toxicity

There are few experimental studies available to assess the pulmonary toxicity of bleomycin. In experiments in which 10 dogs received various doses of bleomycin intravenously, Fleishman and co-workers (4) found varying degrees of epithelial reactivity with inflammatory cell infiltrates and fibrosis as post-injection time increased.

In the present study, a large number of mice was used in what was initially a pilot experiment to determine whether bleomycin injection is a useful model for inducing epithelial metaplasia and pulmonary fibrosis. From dose/mortality figures, it became apparent that a higher dose is needed to produce pulmonary lesions in mice than in dogs; a 0.4 mg/kg dose produced lesions in dogs (4), whereas mice required at least 8-10 times this dose for significant changes to occur. A detailed chart relating dose to mortality and to the incidence of pulmonary fibrosis has already

been published (5). The most satisfactory schedule for producing pulmonary lesions was 20 mg/kg bleomycin IP twice per week for 4 to 8 weeks and sacrifice up to 20 weeks from the first injection. Most animals developed perivascular edema with cellular infiltrates, and, in addition, a proportion of these mice also showed epithelial metaplasia and fibrosis. The latter changes took longer to develop and it is likely that some mice, particularly in high dose groups, died of toxic effects of bleomycin on other systems before extensive pulmonary fibrosis occurred.

## Pathogenesis

The pathogenesis of bleomycin-induced pulmonary fibrosis was investigated in some detail, with particular emphasis on the sequential cellular responses. There are many cell types in the lung and their reactions to injury are known to be variable. Most biochemical-toxicologic evalua-

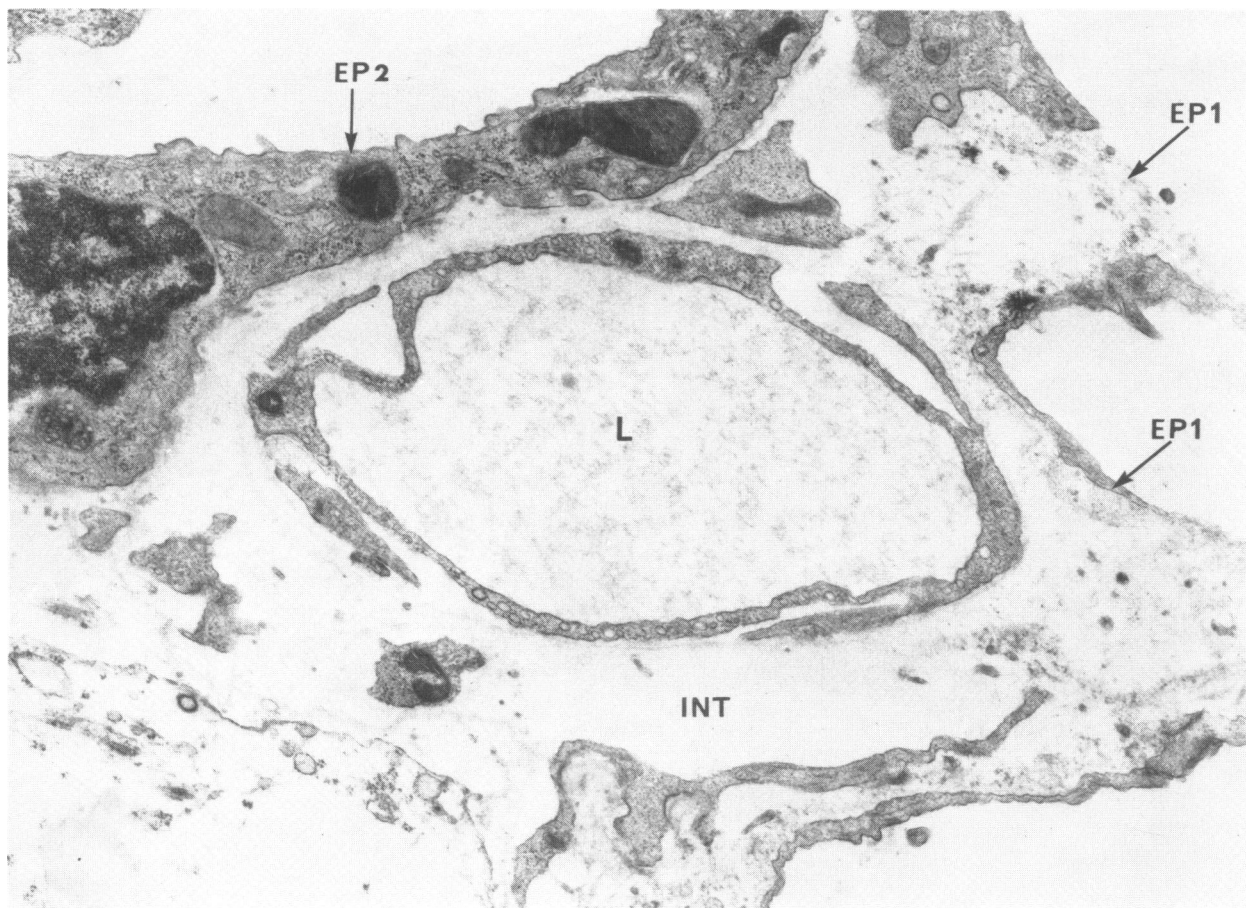


FIGURE 2. Electron micrograph of capillary and alveolar epithelium after 4 weeks bleomycin. There is focal necrosis of the type 1 cell (EP1), whereas the type 2 cell (EP2) appears normal; the interstitial space (INT) is edematous. L denotes capillary lumen.  $\times 18,000$ .

tions treat the lung as a whole, and specific cell types responding to the injurious agent and the cellular processes of repair, including cytodynamic studies of cell turnover, are not made. It was hoped that a study of these cellular events would lead to a better understanding of the sites and mechanisms of injury and perhaps suggest specific methods of blocking the reaction.

Morphologic data were obtained by electron microscopy and by light microscopy on 1  $\mu\text{m}$  methacrylate sections. This is a particularly useful method, since entire lobes of mouse lung can be embedded per block, and the sections obtained are thin enough to allow cellular identification to be made. The reaction now to be described was qualitatively similar for all doses used; the timing and extent of injury did vary.

#### Endothelial Reaction

The earliest changes observed by electron microscopy involved the endothelium of pulmonary

arteries and veins where subendothelial blebs bulged into vascular lumen resulting in severe attenuation of the endothelial cytoplasm; in addition, there was intracytoplasmic edema of the endothelial cells (Fig. 1). This was seen as soon as 2 weeks after the start of a 20 mg/kg dose schedule; by 4 weeks these changes were obvious by light microscopy. Frequently, the perivascular connective tissue was edematous and contained a cellular infiltrate, mainly lymphocytes and plasma cells. Lesions of large pulmonary vessels were well developed before changes were seen in the endothelium of capillaries. These cells also became swollen and separated from the underlying basement membrane. Diffuse interstitial edema was observed and the air sacs contained numerous vacuolated macrophages at this time.

The endothelial cells were therefore identified as the primary sites of injury and the anatomic pattern of lesions is likely related to the mode of drug administration. The preferential suscepti-

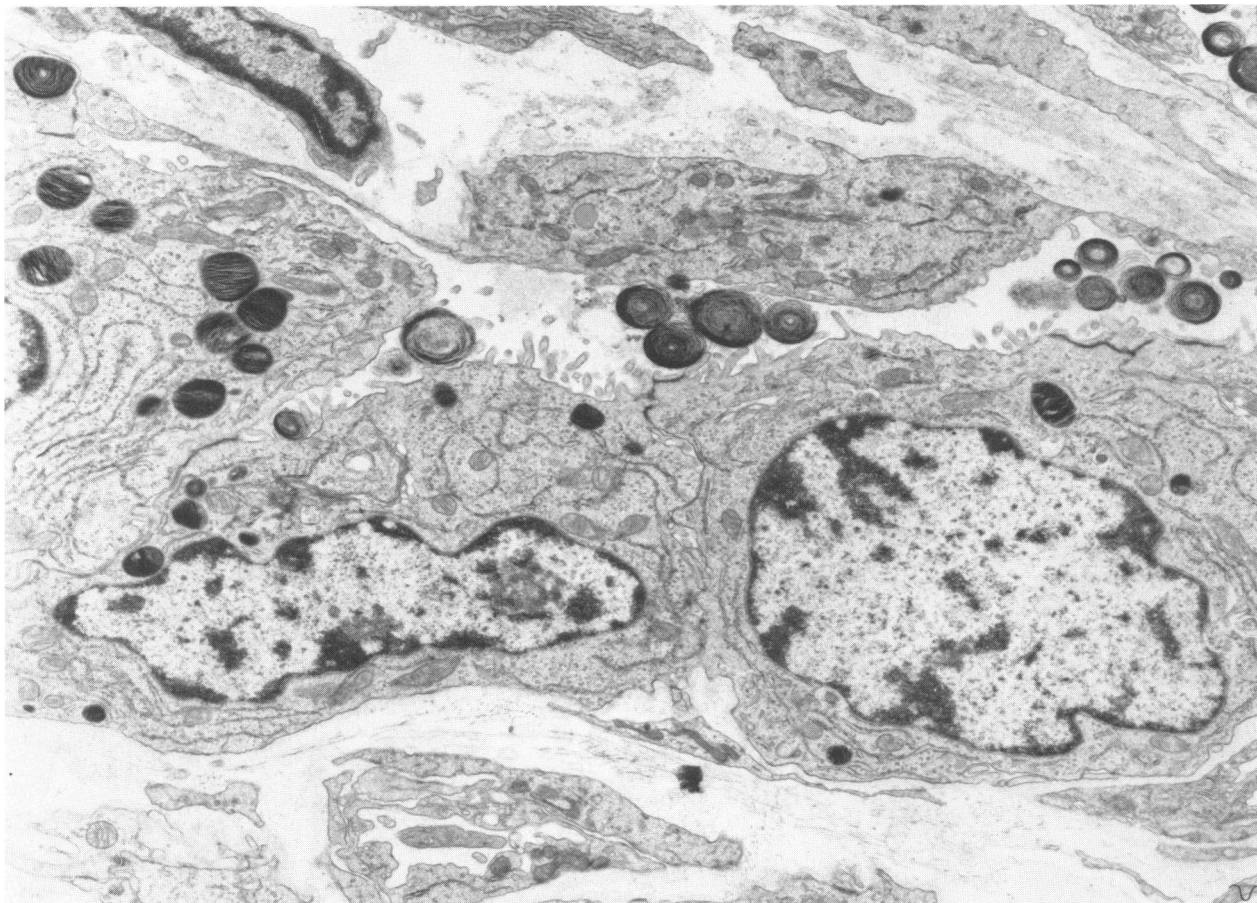


FIGURE 3. Electron micrograph of alveolar epithelium after 4 weeks bleomycin. The alveolar wall is lined by type 2 cells and some lamellar bodies can be seen in the air sac. The interstitial region is thickened by collagen deposition.  $\times 9000$ .

bility of endothelial cells of arteries and veins can be related to the fact that the drug is blood borne. This is in contrast to injury induced by  $O_2$  where the cells on the route of maximum gaseous transfer, the capillary endothelium, are preferentially injured (6,7).

### Epithelial Reaction

In some animals injury did not progress beyond endothelial swelling with accumulation of interstitial edema; in many, however, there were subsequent changes in the alveolar epithelium. As noted in other models of lung injury, there is a differential response of alveolar epithelial cells, whereby focal necrosis of the squamous type 1 cells was observed and the cuboidal type 2 cells appeared normal (Fig. 2). By destroying this epithelial barrier, the contents of the interstitium and of the blood may leak through damaged endothelium directly to the alveoli, and in fact, necro-

sis of type 1 cells was frequently associated with intra-alveolar aggregates of fibrin. Subsequently, evidence of reparative activity was found in the alveolar epithelium. Mitotic figures were seen in some cuboidal cells, and focal areas of alveolar walls were lined exclusively by this type of epithelium (Fig. 3).

The repair of injured type 1 cells by division of type 2 epithelium with subsequent transformation to the squamous form is now established as a common reparative mechanism for the injured epithelium by the studies of different models of lung injury and repair, e.g.  $O_2$  and  $NO_2$  (8,9). In the bleomycin-treated mice, there was type 2 epithelium and are also similar to the epithelial forms seen in the bleomycin-injured human lung. type 1 form, but others seemed to undergo change to a metaplastic form of epithelium in which the alveolar lining cells were cuboidal, possessed microvilli but not lamellar bodies (Fig.

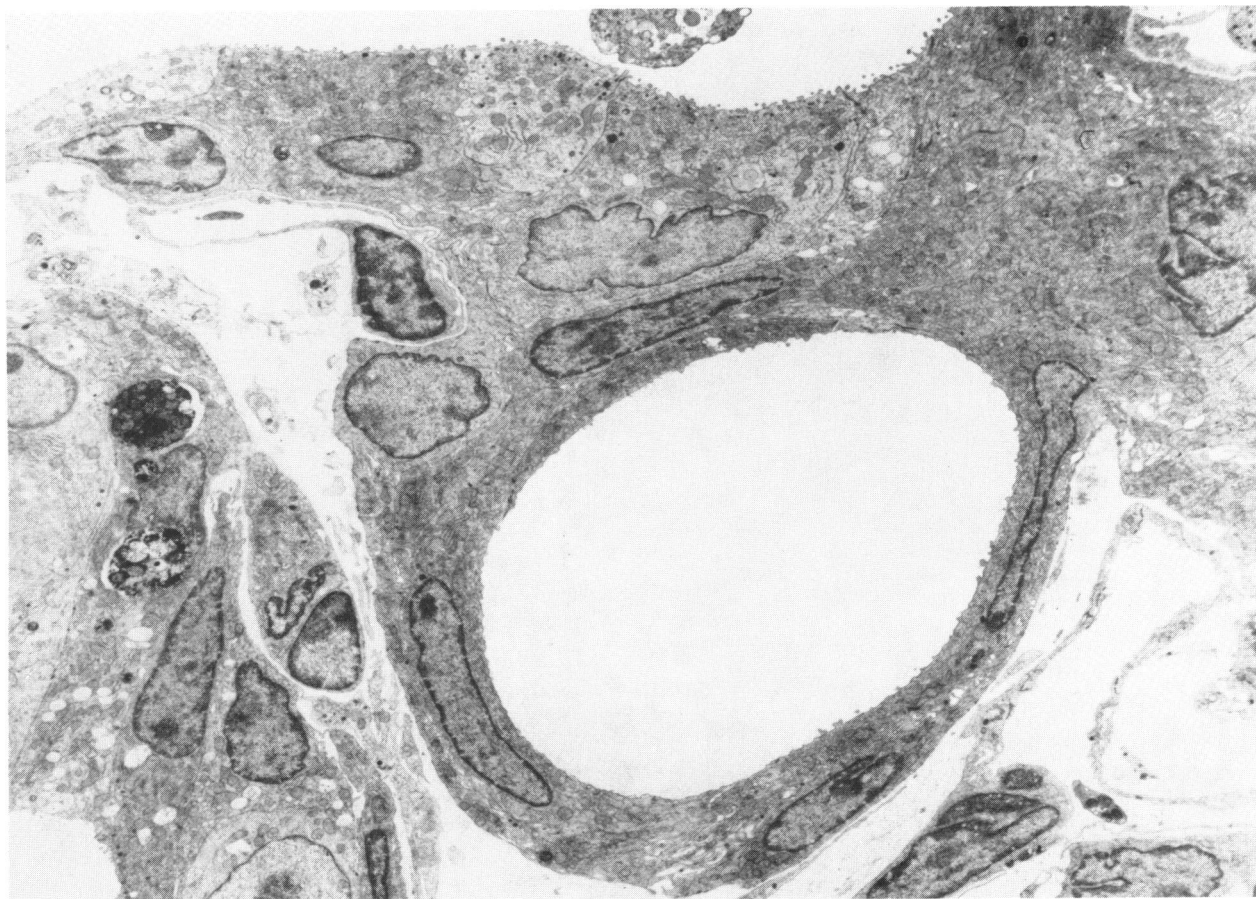

FIGURE 4. Electron micrograph of alveolar epithelium after 5 weeks bleomycin. Epithelial cells form a small tubular structure; cells have microvilli but no lamellar bodies  $\times 4000$ .

4). Many alveoli were lined by these tubular forms that resemble undifferentiated fetal epithelium and are also similar to the epithelial forms seen in the bleomycin-injured human lung. In some instances, alveoli were lined by flattened cells, some of which had cilia and resembled bronchiolar epithelium (Fig. 5). It may be argued that bronchiolar epithelial cells had "grown down" into the alveoli to repair the injury but the finding of these metaplastic forms in distal regions of the lung makes it likely that they were derived from alveolar epithelial cells, and, in fact, several intermediate cell forms were observed. This metaplastic pattern of epithelial response to injury may be related to the agent and severity of the injury, or to the fact that there is continuing insult from the drug in this case rather than the simpler "one-shot" gas exposure of  $O_2$  experiments, where a return to normal type 1 and 2 cell distribution was found (8).

#### Fibrosis

As stated above, at areas of type 1 cell necrosis, fibrin leaked through the injured epithelium into the alveoli. Subsequently there was invasion of this fibrin by fibroblasts which secreted collagen to produce intra-alveolar fibrosis; fibroblastic activity was also prominent within the pulmonary interstitium. The septal and intra-alveolar fibrosis became progressively more extensive and severe with time (Fig. 6). In animals that received a 20 mg/kg dose twice per week for 8 weeks, fibrosis was first observed 4 weeks later and progressed, becoming diffuse by 4-12 weeks, by which time the reactive hyperplasia and metaplasia of alveolar epithelium had also occurred.

In mice with the most severe pulmonary damage, fibrosis was observed in the alveolar spaces, in the alveolar septa and in peribronchial and perivascular regions. In animals where fibrosis

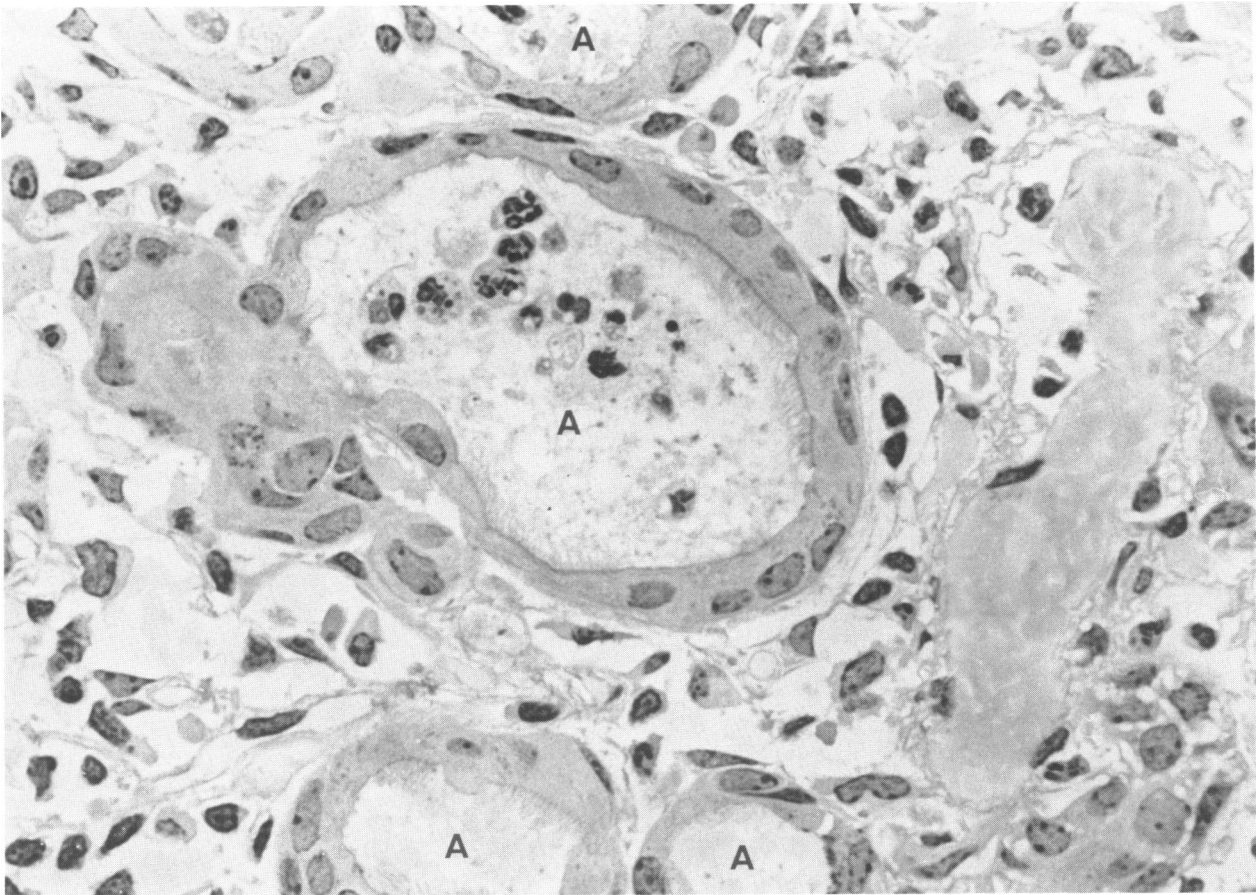


FIGURE 5. Many alveoli (A) are lined by flattened cells, some of which are ciliated. 1  $\mu$ m methacrylate section, H & E stain, after 5 weeks bleomycin.  $\times 1000$ .

was not so well developed, fibroblastic activity could be demonstrated in the walls of larger blood vessels, whereas there was little change in the alveolar walls. This brings the morphologic story full circle, since fibrosis was preferentially produced adjacent to the initial site of cell injury—the endothelium of larger vessels.

### Cytodynamic Study

Having used these morphologic techniques to study the pathogenesis of the pulmonary fibrosis and thus to identify the sites of cellular injury in the lung, a cytodynamic investigation was then undertaken to determine patterns of cellular renewal. Some preliminary data is now available, based on a group of mice injected with 20 mg/kg bleomycin, twice a week for 4 weeks. At weekly intervals during and after the treatment, three mice were injected with 2  $\mu$ Ci/g body weight of tritiated thymidine and sacrificed 2 hr later.

The lungs were fixed by inflation with glutaraldehyde, embedded in methacrylate, and 1  $\mu$ m sections prepared for autoradiography. These sections are large enough to allow labeled cell counts on a large number of cells and thin enough to allow precise cellular identification, in contrast to the thicker paraffin sections where this is seldom possible. By counting labeled alveolar cells per 1000 nuclei, it was found that there was a sharp increase in thymidine uptake by lung cells 4-8 weeks after the start of bleomycin injections.

From autoradiographs, a differential count of labeled cells was made and compared to controls at various stages of the reaction. The predominant labeled cells at the peak of DNA synthesis were found to be endothelial and epithelial. The increased number of cells in DNA synthesis and their anatomic location is a good indication of the site of antecedent injury where a reparative mechanism is underway. In this case, labeled endothelial cells were predominantly found in

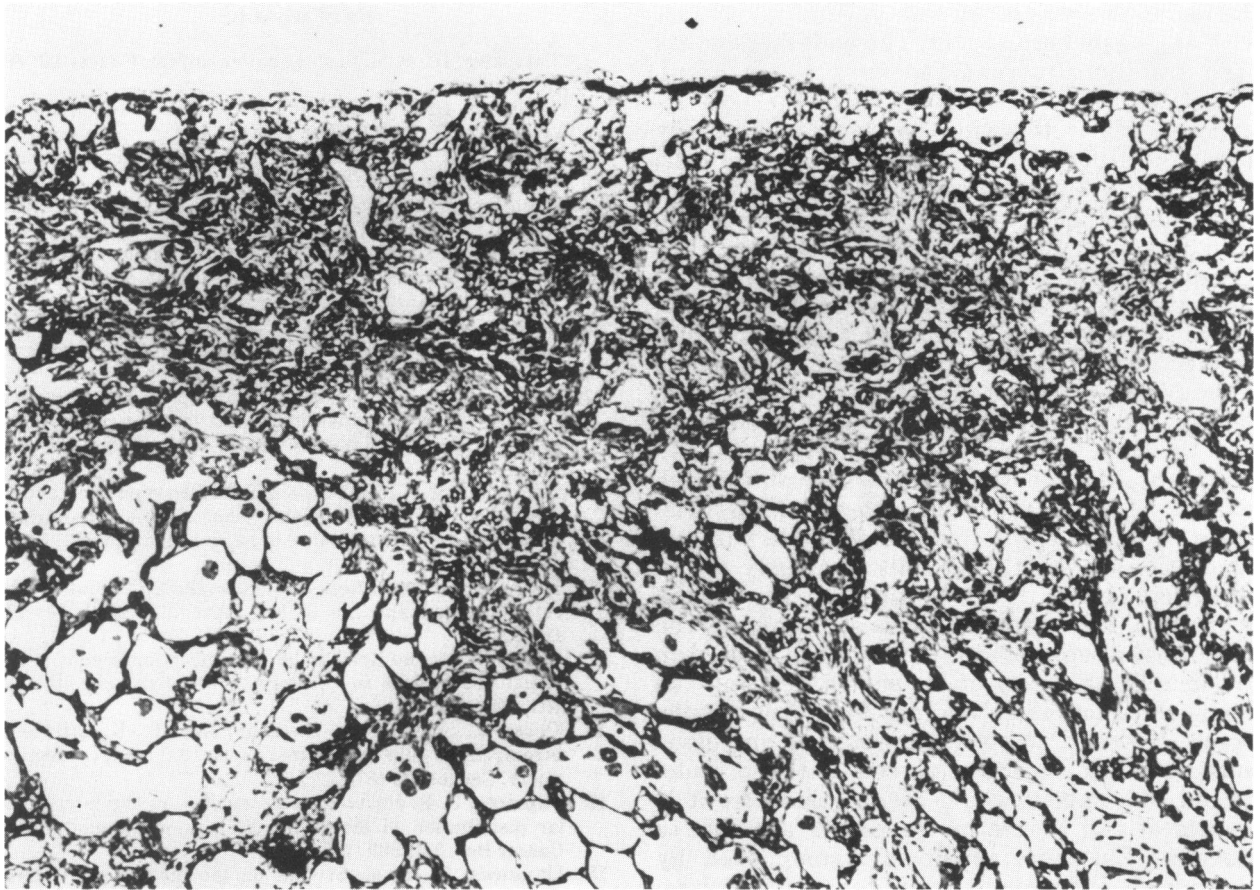


FIGURE 6. After 8 weeks bleomycin, showing diffuse septal and intraalveolar fibrosis 1  $\mu$ m methacrylate section (silver methenamine stain).  $\times 130$ .

larger vessels. Injection of colchicine may be used to arrest cells in metaphase and confirm that they are in mitosis at this time. Examining the epithelial cell population, many of the metaplastic cell types were labeled, indicating that these cells are synthesizing DNA. It is likely, therefore, that they do not all arise by a transformation mechanism, but that some, at least, are capable of division.

### Mechanism

The mechanism of bleomycin toxicity in the lung is not fully understood. Various *in vitro* studies have indicated effects of bleomycin on a variety of cell functions, mostly associated with the nucleus such as chromosomal aberration (10) or inhibition of cell division (11). By 2 hr after administration of  $^{14}\text{C}$ -labeled bleomycin, isotope was found at the cell membrane; by 4 hr, it reached the nuclear membrane. Necrotic cells had heavy cytoplasmic label (12). This is sup-

portive evidence for the current theory that cells contain varying amounts of an inactivation enzyme in the cytoplasm, and the cells with low amounts of this enzyme are most susceptible to injury by bleomycin. It has been shown in mice that squamous cell carcinomas readily controlled by bleomycin possess less inactivating enzyme than more resistant sarcomas (13).

In a study by Ohnuma (14), homogenates of various tissues were incubated with bleomycin, and drug inactivation was followed. Liver, intestine, spleen, plasma, kidney all contained more inactivation enzyme than skin and lung. This is the inverse of drug retention from *in vivo* studies of Umezawa (1), where bleomycin content was highest in lung and skin, the organs of lowest inactivation enzyme content.

It is possible, therefore, that the particular sensitivity of the pulmonary endothelium to bleomycin is related to a low level of this inactivating enzyme in these cells. The vast network of endo-

thelium in the lung is the cell type in first contact with any blood borne toxin. The endothelium has been traditionally regarded as a water proof, coagulation proof lining layer with transport activity. Recently this view has been modified by metabolic studies showing that endothelial cells bear surface enzymes and receptor sites, e.g., certain substances such as gastrin produced in the gut, appear to be inactivated in the lung (15). The questions then arise with a compound such as bleomycin: (a) does the lung have specific binding sites that remove the agent from the blood and so is selectively injured, or (b) as suggested above, is the compound generally toxic but other tissues have greater amounts of inactivating enzymes than the lung, which is then selectively damaged?

Injury to the endothelium usually results in the leakage of fluid and cells into the interstitial space. In many cases this is reversible with regeneration of endothelial cells and many of the bleomycin-injured lungs do not progress beyond endothelial damage with interstitial edema. The more critical epithelial injury may be related to the increasing levels of bleomycin crossing the damaged endothelium and reaching type 1 cells. Focal necrosis of this cell allows fibrin and blood constituents to reach the alveoli. If this is widespread, the animal would die. In this case it is multifocal and reparative processes are able to function. Epithelial repair is accomplished by hyperplasia and metaplasia of type 2 cells with accompanying alveolar and septal fibrosis. This is a fairly common response of the lung to continuing injury; similar responses have been observed clinically in diffuse pulmonary fibrosis or fibrosing alveolitis. It is possible, therefore, that the common initiating factor in these disease processes is the binding to, and subsequent injury of the endothelium, by agents it cannot metabolize.

## REFERENCES

1. Umezawa, H., et al. Studies on bleomycin. *Cancer* 20: 891 (1967).
2. Umezawa, H. Chemistry and mechanism of action of bleomycin. *Fed. Proc.* 33: 2296 (1974).
3. Rudders, R. A., and Hensley, G. T. Bleomycin pulmonary toxicity. *Chest* 63: 627 (1973).
4. Fleischman, R. W., et al. Bleomycin-induced interstitial pneumonia in dogs. *Thorax* 26: 675 (1971).
5. Adamson, I.Y.R., and Bowden, D. H. The pathogenesis of bleomycin-induced pulmonary fibrosis in mice. *Am. J. Pathol.* 77: 185 (1974).
6. Bowden, D. H., Adamson, I.Y.R., and Wyatt, J. P. Reaction of the lung cells to a high concentration of oxygen. *Arch. Pathol.* 86: 671 (1968).
7. Bowden, D. H., and Adamson, I.Y.R. Endothelial regeneration as a marker of the differential vascular responses in oxygen induced pulmonary edema. *Lab. Invest.* 30: 350 (1974).
8. Adamson, I.Y.R., and Bowden, D.H. The type 2 cell as progenitor of alveolar epithelial regeneration. A cytodynamic study in mice after exposure to oxygen. *Lab. Invest.* 30: 35 (1974).
9. Evans, M. J., et al. Renewal of alveolar epithelium in the rat following exposure to NO<sub>2</sub>. *Am. J. Pathol.* 70: 175 (1973).
10. Paika, K. D., and Krishan, A. Bleomycin-induced chromosomal aberrations in cultured mammalian cells. *Cancer Res.* 33: 961 (1973).
11. Desai, L. S., Krishan, A., and Foley, G. E. Effects of bleomycin on cells in culture: a quantitative cytochemical study. *Cancer* 34: 1873 (1974).
12. Fujimoto, J. Radioautographic studies on the intracellular distribution of bleomycin-<sup>14</sup>C in mouse tumor cells. *Cancer Res.* 34: 2969 (1974).
13. Umezawa, H., et al. Studies on the mechanism of anti-tumor effect of bleomycin on squamous cell carcinoma. *J. Antibiotics* 25: 409 (1972).
14. Ohnuma, T., et al. Microbiological assay of bleomycin: Inactivation, tissue distribution and clearance. *Cancer* 33: 1230 (1974).
15. Fishman, A. P., and Pietra, G. G. Handling of bioactive materials by the lung. *New Engl. J. Med.* 291: 884, 953 (1974).