



Subcutaneous fibrosarcoma in an aged guinea pig

Heather Steele

Abstract — A 9-year-old, female guinea pig was diagnosed with a subcutaneous fibrosarcoma overlying the ventral thorax. The mass was invasive within the subcutis without extension into surrounding structures or organ systems. Other findings included cystic ovaries, renal cortical cysts, nodular hyperplasia of the liver, and myocardial fibrosis with pulmonary hypertension.

Résumé — Fibrosarcome sous-cutané chez un cobaye âgé. Un diagnostic de fibrosarcome sous-cutané recouvrant le thorax ventral a été posé chez un cobaye femelle âgé de 9 ans. La masse envahissait le tissu sous-cutané, sans s'étendre dans les structures ou organes voisins. Les autres trouvailles comprenaient des kystes ovariens, des kystes du cortex rénal, une hyperplasie nodulaire du foie et une fibrose du myocarde avec hypertension pulmonaire.

(Traduit par Docteur André Blouin)

Can Vet J 2001;42:300–302

A 9-year-old, female guinea pig was presented with a 2-month history of a mass overlying the ventral thorax. The guinea pig had been with the current owner since it was 8 wk of age and was housed in a cage with a plastic tray bottom and wire sides and top. It was housed on cedar wood chips and fed a commercial pelleted alfalfa diet, in conjunction with fresh vegetables and fruits, and water from a sipper container. On presentation, the guinea pig was bright, alert, and eating and drinking normally. A large (5 cm × 4 cm × 3 cm), firm mass overlay the ventral thorax, but it was difficult to determine if it was adherent to the underlying muscles and ribs. Microscopic examination of a fine-needle aspirate of the mass, stained with Wright's-Giemsa stain, showed spindle-shaped cells with occasional multiple nuclei. These findings were consistent with a malignant mesenchymal tumor, most likely a fibrosarcoma. The owner declined to have the mass surgically removed because of the anesthetic risk associated with the age of the guinea pig.

A month later the guinea pig was presented again because the mass had further enlarged (8 cm × 6 cm × 6 cm) and had expanded into the right axillary region, making it difficult for the guinea pig to walk. The guinea pig had trouble moving to food and water but would still eat and drink if fed by hand. The owner elected to have as much of the mass as possible removed surgically. Isoflurane (AErrane Isoflurane USP; Janssen Ortho, Toronto, Ontario) was administered with a stepwise increase in concentration until 3.5% was reached for

induction, at which point the mask was tied in place and the isoflurane kept at 3% for the duration of the surgery. The ventral thorax was surgically prepared, and a single incision, 7 cm to 8 cm in length, was made directly over the mass. The skin was peeled from the surface of the mass and the mass was removed. The mass was nonadherent to the underlying muscle and bone structures and appeared to be well encapsulated. It had a single collection of blood vessels entering from the dorsal surface and did not bleed when it was pulled out; therefore, the vessels were not tied off. The skin overlying the mass was thin, and since much of it was redundant, it was removed. A single row of 8 simple interrupted sutures was made by using nonabsorbable material (4-0 Supramid; B. Braun — SM1 AG, Hünningen, Belgium). The guinea pig recovered quickly and was immediately active and interested in food and water.

Sections of the mass were sent for microscopic examination. There was a pleomorphic population of small spindle cells arranged in irregular whorls and bundles. The nuclei and nucleoli of the neoplastic cells were irregular and there were moderate numbers of bizarre multinucleate cells. Frequent mitotic figures were present (4/400X field). The tumor was surrounded by a thin, fibrous capsule and surgical removal was not complete in all sections submitted. The diagnosis was fibrosarcoma of moderate malignancy. A guarded prognosis was given because of the invasiveness and malignant appearance of the cells, and the likelihood that the tumor could recur locally or metastasize to other organs.

Two weeks later, the owner noticed a small (2 cm × 1 cm × 1 cm) nodule in the area of the previous mass. Within a month, the mass had grown to its original size; the skin overlying it remained thin. The owner noticed profuse bleeding from the mass, at which point the guinea pig was taken to the emergency clinic and euthanized. The body was frozen and later submitted for necropsy.

Western College of Veterinary Medicine, University of Saskatchewan, Saskatoon, Saskatchewan S7N 5B4.

Dr. Steele's current address is Brentwood Animal Hospital, 185 Bordze Ave., Sherwood Park, Alberta T8B 1M6.

Heather Steele will receive a copy of *Saunders Comprehensive Veterinary Dictionary* courtesy of Harcourt-Brace Canada.

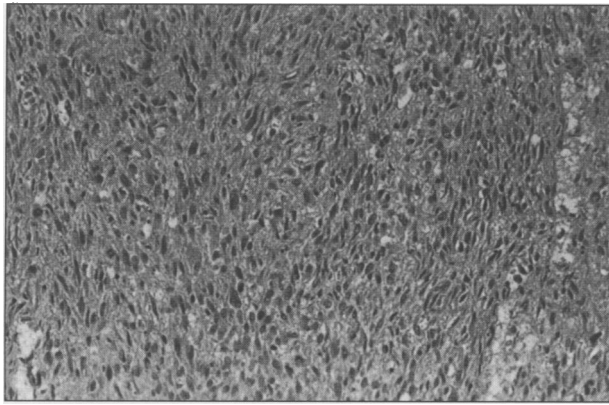


Figure 1. Subcutaneous fibrosarcoma in an aged guinea pig composed of spindle-shaped cells in a loose, collagenous matrix with evidence of occasional large, bizarre cells. There is evidence of anisocytosis and anisokaryosis in the fibroblast population. Hematoxylin and eosin stain.

On necropsy, the guinea pig was in good body condition with evidence of subcutaneous and internal fat stores. The main finding was a subcutaneous mass (8 cm × 6 cm × 4 cm in size and weighing 107.5 g) with the consistency of adipose tissue. There was a 1.5-cm opening in the skin overlying the mass, surrounded by clotted and dried blood. The mass was nonadherent to the overlying skin and the underlying muscle and bone structures; grossly, it had no obvious fibrous capsule. On microscopic examination, the mass consisted of spindle-shaped cells in a loose, collagenous matrix with evidence of occasional large bizarre cells (Figure 1). Anisocytosis was present; however, mitotic figures were uncommon in these sections. Other findings were multiple, bilateral, renal cortical cysts and single, bilateral, ovarian cysts with evidence of fibrosis of the ovaries. The liver had a roughened surface, which appeared to be nodular hyperplasia on microscopic examination. White, pinpoint lesions on the atria were found to be small areas of mature collagenous tissue with a single focus of lymphocytic infiltration in the myocardium. The lungs were dark in color with eosinophilic fluid throughout the parenchyma, likely a result of the euthanasia. At least one pulmonary artery had a thickened wall, suggesting pulmonary hypertension. These changes were attributed to the advanced age of the guinea pig.

Reports of spontaneous tumors in guinea pigs are uncommon in the literature. One reason may be that tumors are seldom seen in guinea pigs less than 3 or 4 y of age (1–5). In a study by Blumenthal and Rogers (5), the incidence of spontaneous tumors increased from 0.4% to 14.4% in guinea pigs over 3 y of age. This guinea pig was aged, so it was not surprising to see the development of a spontaneous tumor. Another possible reason for the low incidence of spontaneous tumors in guinea pigs may be that their serum and liver tissue contains L-asparaginase. L-Asparaginase is an enzyme that is thought to play a role as an antitumor enzyme by breaking down the asparagine that tumor cells require for growth (1,6).

The skin and subcutis have been estimated to be the location of neoplasms in 15% of all spontaneous tumors

in the guinea pig (1). Fibrosarcomas originating in the subcutis are rare but have been reported. A subcutaneous fibrosarcoma overlying the lower jaw and shoulder girdle was nonadherent to the overlying skin and had multiple smaller metastatic nodules under the axillary region, but no metastasis to any internal organs (7). A fibrosarcoma overlying the right foreleg was locally invasive into the ulna but not metastatic (8). Two fibrosarcomas, 1 overlying the dorsum of a male guinea pig that metastasized to the spleen and 1 on the chest wall that metastasized to lymph nodes, lungs, ovaries, adrenals, and the uterus, have been recorded (2), as has a fibrosarcoma overlying the angle of the jaw on the right side, which infiltrated the maxilla but did not metastasize to other organs (9).

Other reports of fibrosarcomas in guinea pigs involve a primary site other than the skin or subcutis. Blumenthal and Rogers (5) reported a uterine fibrosarcoma that remained confined to the serosa and did not metastasize. Kitchen, Carlton, and Bickford (3) reported a mixed mammary tumor that consisted of both fibrosarcoma and papillary adenocarcinoma cells, which metastasized to the lungs. They also reported a uterine fibroma that consisted of a mature cell population without evidence of mitosis. Leader (10) reported an osteogenic fibrosarcoma that involved the left femur, tibia, and fibula and metastasized to the lungs.

Studies using methylcholanthrene to induce tumors show that 20% of guinea pigs that develop tumors show evidence of metastasis, regardless of the tumor type (2). The most common sites of metastasis are the lungs, liver, spleen, adrenal glands, heart, and kidneys. Young guinea pigs also had faster tumor growth and greater risk of metastasis than did older guinea pigs with induced tumors. Whether spontaneous fibrosarcomas behave in the same way as induced fibrosarcomas is uncertain, because reports on spontaneous subcutaneous fibrosarcomas are limited in number. However, metastasis or local invasion of surrounding structures appears to be quite common with fibrosarcomas in guinea pigs, so it was surprising in this case that the tumor cells were quite anaplastic, without metastasis or invasion of surrounding tissues. If the mass had been removed more completely, perhaps the tumor's recurrence could have been prevented.

It was interesting to observe the other changes associated with aging: ovarian cysts and fibrosis are very common in older females and have been found in up to 80% of guinea pigs with tumors (4). The condition is usually bilateral and often of no clinical consequence to the guinea pig (11,12). Nodular hyperplasia of the liver is not commonly observed in aged guinea pigs, but is common in other domestic animals. The patches of atrial fibrosis and concurrent pulmonary hypertension were mild and likely of no clinical consequence.

Acknowledgments

The author thanks Drs. Gary Wobeser, Brenda Cross, and Colette Wheler, Western College of Veterinary Medicine, and Dr. Edwin Neufeld of the Southside Animal Hospital, Edmonton, for their help and guidance with this case.

CVJ

References

- Manning PJ. Neoplastic diseases. In: Manning JP, Wagner J, eds. *The Biology of the Guinea Pig*. New York: Academic Pr, 1976:212-225.
- Blumenthal HT, Rogers JB. Spontaneous and induced tumours in the guinea pig. In: Ribelin WE, McCoy JR, eds. *Pathology of Laboratory Animals*. Springfield, Illinois: Charles C. Thomas, 1967:183-209.
- Kitchen DN, Carlton WW, Bickford AA. A report of fourteen spontaneous tumours of the guinea pig. *Lab Anim Sci* 1975; 25:92-102.
- Papanicolaou GN, Olcott CT. Studies of spontaneous tumors in guinea pigs II — Tumors of the stomach and intestine. *Arch Pathol* 1942;34:218-228.
- Blumenthal HT, Rogers JB. Report of fourteen spontaneous guinea pig tumors with a review of literature. *Cancer Res* 1960;20:191-197.
- Wriston JC, Yellin TO. L-asparagine: A review. *Enzymology* 1973;39:185-248.
- Dickson, EC. Sarcoma occurring in a guinea pig. *Proc Soc Exp Biol Med* 1915;13:26-27.
- Wood, FC. A sarcoma in a guinea pig. *Proc New York Pathol Soc* 1916;16:1-6.
- Warren S, Gates O. Spontaneous and induced tumors of the guinea pig. *Cancer Res* 1941;1:65-68.
- Leader SA. Osteogenic sarcoma of the femur in a guinea pig. *Am J Cancer* 1937;29:546-550.
- Laber-Laird K, Swindel MM, Klecknell P. *Handbook of Rodent and Rabbit Medicine*. Oxford: Pergamon Pr, 1996:123, 132.
- Quesenbury KR. Guinea pigs. *Exotic Pet Medicine II. Vet Clin North Am Small Anim Pract* 1994;24(1):67-87.



PRODUCTS GROUP INTERNATIONAL, INC.


An ULTRASOUND Revolution...

SONOSITE 180Vet

Introducing the NEW SonoSite 180Vet (As seen in Forbes Magazine), a revolutionary, lightweight ultrasound system with high quality digital images that is ready to scan right out of the bag.

- Large or Small Animal
- NEW Broadband Electronic Probes
- Color Power & Directional Doppler
- 5.4 lbs. with Transducer
- Up to 100 Frames per second
- 5" TFT Color LCD
- Full measurement capability
- 120 image storage for off-line printing
- Cine review
- QWERTY Keyboard
- Lithium Ion Battery (rechargeable) or 110V

For all of your Veterinary Ultrasound needs please call:
800-336-5299



Honda
HS1201V



Honda
2000V



Vetson



Visit us on the web at:
www.productsgroup.com

303-823-6330 ph.
303-823-6339 fax