

# Congenital hepatoblastoma in a neonatal alpaca cria

Bruce C. Watt, A. James Cooley, Benjamin J. Darien

**Abstract** — A neonatal alpaca cria found to have minimal clinical abnormalities was diagnosed post-mortem with an epithelial-type hepatoblastoma with combined embryonal and fetal patterns, based on previously reported morphological features. Camelid neoplasia and domestic animal hepatoblastomas are very rare, with only a single case of congenital hepatoblastoma in a domestic animal previously reported.

**Résumé** — Hépatoblastome congénital chez un alpaca cria nouveau-né. Un diagnostic post-mortem d'hépatoblastome de type épithélial avec une combinaison de patrons embryonnaire et fétal, selon des critères morphologiques rapportés pour ce type de tumeur, a été posé chez un alpaca cria nouveau-né présentant des anomalies cliniques minimales. La néoplasie chez les camélidés et les hépatoblastomes chez les animaux domestiques sont très rares, un seul cas d'hépatoblastome congénital chez un animal domestique ayant été signalé à ce jour.

(Traduit par Docteur André Blouin)

*Can Vet J 2001;42:872-874*

A 6-hour-old, female alpaca cria was admitted to the Veterinary Medical Teaching Hospital (VMTH) at the University of Wisconsin. The cria's birth was uneventful, but upon examination by the owner, the cria was found to have angular forelimb deformities that precluded the neonate from standing. On admission, the cria weighed 7.0 kg; temperature (38.0°C), pulse (120 beats/min), and respiratory rate (20 breaths/min) were normal for that age. Mucous membranes were pink, capillary refill time was 2 s, and skin tent was within normal limits. No neurological abnormalities were evident and the cria was assessed as being bright, alert, and responsive. The packed cell volume (PCV) was 0.26 L/L, total protein 68 g/L, and blood glucose 6.49 mmol/L. Valgus angular limb deformity of the right and left carpi was evident, and estimated to be 15° in the left limb and 10° in the right limb. The right metacarpophalangeal joint had a valgus angular deformity of approximately 10°.

Each forelimb was bandaged from elbow to fetlock and plastic splints were fastened to the bandage to maintain the limbs in extension. After bandaging and splinting, the cria could stand easily and ambulate to a moderate degree. The cria was not able to rise from recumbency to standing without assistance. A complete blood cell count, blood chemistry and electrolyte analysis, and radiographs were not obtained at admission.

Because the cria was not able to stand, it had not nursed the dam. It was provided with colostrum (50 mL) in a bottle every hour and it readily nursed 5 times.

Department of Surgical Sciences (Watt), Department of Pathobiological Sciences (Cooley), Department of Biomedical Sciences (Darien), University of Wisconsin, Madison, Wisconsin 53706 USA.

Address correspondence to Dr. Bruce Watt.

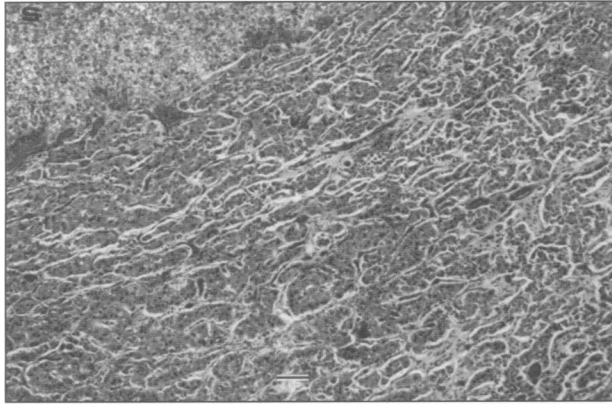
Dr. Watt's current address is 5906-16th Avenue West, Markham, Ontario L3P 3J3.

Reprints will not be available from the authors.

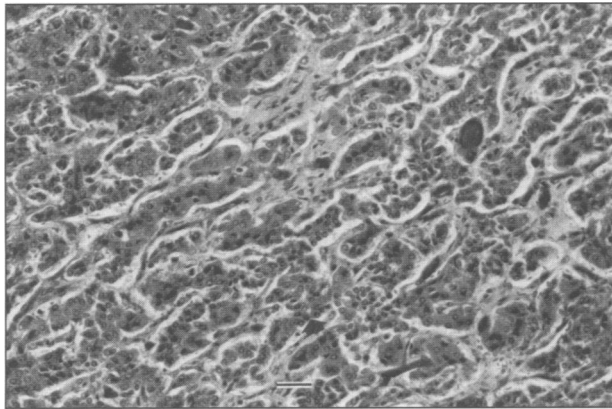
Prior to one feeding, it was found standing on its own accord, attempting to nurse the dam. At the time of the 6th feeding, the cria refused to nurse. Thirty minutes later, colostrum in a bottle was offered, but the cria again refused to nurse and would not attempt to remain standing when assisted. At this time, the cria's temperature was 37.4°C, pulse rate was 110 beats/min, and the respiratory rate was 70 breaths/min. The blood glucose was 4.88 mmol/L, PCV was 0.27 L/L, and total protein was 62 g/L. The cria died shortly after completion of this hematological analysis.

Radiographs of the forelimbs obtained postmortem revealed no abnormalities in bone density or shape. Carpal and metacarpophalangeal joint spaces were radiographically wider medially than laterally when the limbs were stressed to a valgus deformity. Necropsy of the cria revealed approximately 8 mL of a dark, yellow fluid in the abdominal cavity. The liver was markedly enlarged, extending far beyond the costal arch. The liver weighed 823 g (11.4% of body weight). The right lateral lobe was largely replaced by an irregular bulging, 11.5-cm × 8.5-cm × 7-cm mass that extended ventrally from the dorsal aspect of the lobe. The capsular surface was irregular and mottled yellowish tan to yellowish red. On the cut surface, part of the mass was a large cavity filled with blood; however, at the junction of the mass with the normal hepatic parenchyma, there were irregular, tan and gray, friable, coalescing nodules up to 3.5 cm in diameter. A thin layer of hepatic parenchyma marginated the periphery of the entire mass. Irregular, sometimes broad, trabeculae of fibrous connective tissue and bone partially subdivided the mass into multiple foci on cut surface. All other abdominal organs were within normal limits. The lungs were dark purple and moderately turgid. There was froth on cut surface and abundant froth in the trachea.

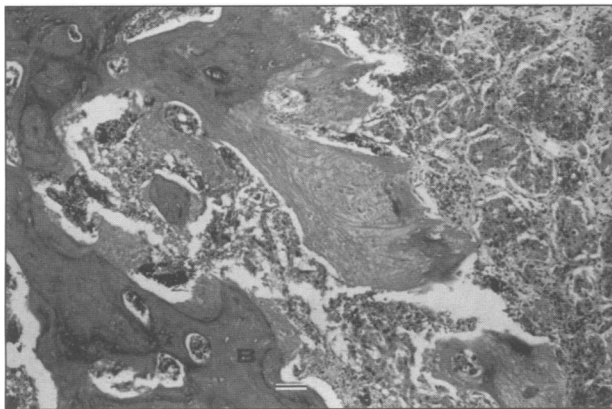
Several histological patterns were evident. The grossly visible peripheral nodules consisted of irregular lobules blending into areas of necrosis or cavitations filled with blood. The lobules were nonencapsulated from



**Figure 1.** Histologic section showing cords and sheets (S) of disorganized cells resembling fetal hepatocytes. Hematoxylin and eosin stain; bar = 50  $\mu$ m.



**Figure 2.** Histologic section showing cords of fetal-type hepatocytes interspersed with more densely cellular cords and nests of embryonal-type cells (arrow). Hematoxylin and eosin stain; bar = 50  $\mu$ m.



**Figure 3.** Histologic section showing broad irregular trabeculae of woven bone (B) abutting cords and nests of neoplastic epithelial cells. Hematoxylin and eosin stain; bar = 50  $\mu$ m.

the marginal normal hepatic parenchyma, but a clear line of demarcation could generally be distinguished. The predominant pattern was irregular and branching trabeculae of fetal-type hepatocytes (Figure 1), ranging from 2 to 4 or more cells thick. Sinusoidal channels separated these cords of densely packed cells, sometimes with small amounts of fibrosis in the space of Disse. The cells had mild to moderate nuclear and cellular pleomor-

phism. Nuclei were often open-faced and had a prominent nucleolus; cytoplasm was modest in amount and eosinophilic with occasional cytoplasmic vacuoles. Fewer than 10 mitotic figures were seen in each of 10 fields scanned at 40X magnification. In some foci, the trabecular pattern gave way to densely cellular sheets and pseudoacinar structures and, in some areas, cords or nests of small densely packed embryonal-type cells were interspersed amongst the somewhat larger fetal hepatocytes (Figure 2). The embryonal-type cells had scant, more basophilic cytoplasm. Rarely, there were small aggregates of small elongated or fusiform-type cells and, in multiple foci, broad branching trabeculae of woven bone with bone marrow in medullary spaces were intimately associated with the neoplastic epithelial cells (Figure 3). Thrombi in sinusoids and blood vessels were common within the tumor, as well as in the large foci of necrosis. No portal areas or bile ducts were present within the tumor. The hepatic parenchyma distal to the mass was largely within normal limits. The histological findings were consistent with a diagnosis of hepatoblastoma. The tumor was an epithelial type hepatoblastoma with combined embryonal and fetal patterns, consistent with a mixed hepatoblastoma with both epithelial and mesenchymal patterns. The epithelial component included both embryonal and fetal patterns.

Tumors reported in the liver of camelids include metastasized squamous cell carcinoma in a guanaco (1) and lymphosarcoma in a llama (2). We are not aware of any reported cases of hepatoblastoma in an alpaca or other camelid. Hepatoblastomas have been reported in dogs (3), horses (4–6), cattle (7), sheep (8), pigs (9), mice (10), and humans (11–14). Hepatoblastomas are classified histologically in humans as epithelial or mixed (epithelial and mesenchymal) (11). Epithelial pattern types include a fetal pattern, combined embryonal and fetal pattern, macrotrabecular pattern, and a small-cell undifferentiated pattern (11). Mixed epithelial and mesenchymal patterns are subdivided into those with or without teratoid features. Regardless, the mesenchymal component of mixed hepatoblastomas is also neoplastic and probably of the same origin as the epithelial component.

Hepatoblastomas are a primary hepatic neoplasm arising either congenitally or very early in life, usually in the first 2 to 3 y. The tumor was originally defined and subdivided into histologic types, based on morphologic criteria and the resemblance to the developing fetal liver from cases in children. More recently, strong positivity for alpha-fetoprotein in areas of the tumor with the fetal epithelial pattern, similar to the findings in the developing liver, has been identified immunohistochemically (14). The tumor often includes an admixture of mesenchymally derived tissues as well. However, cells resembling osteoblasts and located within an osteoid-like material have been shown to express epithelial-membrane antigen, cytokeratin, and alpha-fetoprotein, reflecting an epithelial origin (14). These findings support the theory of origin of the tumor from a pluripotential cell with predominant differentiation to embryonal and, subsequently, fetal-type cells, but with the potential for ductal or squamous differentiation

or osseous metaplasia. Since most hepatoblastomas in children are reported in those under 3 y of age, a genetic component is suspected.

Although hepatoblastomas have been found sporadically in several species, the very low number of non-human cases precludes any real comparative insight. Most comparisons are made to the condition in humans, since the entity is well recognized and the body of literature is greater. The hepatoblastoma in this alpaca cria occurred as a congenital neoplasm. A review in 1999 of the subset of congenital hepatoblastomas in humans found 40 published cases spanning the previous 32 y (12). The metastatic rate (13%) was not significantly different from that in hepatoblastomas arising in older children. Comparatively, no metastasis was present in this alpaca. The only other reported case of a congenital hepatoblastoma in a domestic animal was reported in an equine fetus (5). This tumor was also quite large and multinodular. Limited metastases were found in the tracheobronchial lymph node and in several myocardial and cerebral blood vessels. Gross and radiographic examination of this alpaca did not detect any associated anatomic anomalies. Such associated conditions occur in 5.5% of children with hepatoblastomas (11).

Hepatoblastomas are the most commonly occurring hepatic tumor in children and account for approximately 25% of pediatric hepatic tumors (11). Hepatic tumors, however, account for only 1% to 2% of all forms of childhood cancer (13) but are reported to represent over two-thirds of the malignant tumors of the liver in children (13). Congenital hepatoblastoma has a significant risk for systemic metastasis, without lung involvement, and a poorer outcome than with hepatoblastoma detected beyond neonatal age (12).

An association between genetic abnormalities and hepatoblastoma human neonates has been reported (13). Genetic abnormalities reported included trisomy of chromosome 20 or trisomy of chromosome 2, among others. Karyotyping was not performed in this case. Because the hepatoblastoma was present congenitally in the cria discussed here, the underlying etiology occurred in utero. Conversely, hepatoblastomas are more commonly evident postparturiently than congenitally in the human infants and in domestic animals in which they have been reported. Hepatoblastomas are inducible in mice in association with the interaction of diet, genetic strain, and known dietary carcinogens (10).

Previously, poor cure rates of less than 25% were reported for hepatoblastoma in children. Rates of 65% to 75% are now possible with a combination of surgical resection before or after chemotherapy, depending upon the initial tumor size (13). Chemotherapy or therapeutic surgical resection of hepatoblastomas has not been reported in domestic animals, obviating the comparison of treatment with human cases. (CV)

## References

1. Altman NM, Small JD, Squire RA. Squamous cell carcinoma of the rumen and thymic amyloidosis in a guanaco. *J Am Vet Med Assoc* 1974;165:820-822.
2. Fowler ME, Gillespie D, Harkema J. Lymphosarcoma in a llama. *J Am Vet Med Assoc* 1985;187:1245-1246.
3. Shiga A, Shirota K, Shida T, Yamada Y, Nomura Y. Hepatoblastoma in a dog. *J Vet Med Sci* 1997;59:1167-1170.
4. Cantile C, Arispici M, Abramo F, Campani D. Hepatoblastoma in a foal. *Equine Vet J* 2001;33:214-216.
5. Neu SM. Hepatoblastoma in an equine fetus. *J Vet Diagn Invest* 1993;5:634-637.
6. Prater PE, Patton CS, Held JP. Pleural effusion resulting from malignant hepatoblastoma in a horse. *J Am Vet Med Assoc* 1989;194:383-385.
7. Rao PR, Sriraman PK, Naidu NRG, Rao DS, Rao IS. Note on hepatoblastoma in a breeding bull. *Indian J Anim Sci* 1980;50:762-764.
8. Manktelow BW. Hepatoblastomas in sheep. *J Pathol Bacteriol* 1965;89:711-714.
9. Hayashi M, Ishihara R, Nishio O. Histopathological examination of spontaneous tumors in slaughtered animals. *Proc Annu Meet Jpn Cancer Assoc* 1979;38:103-108.
10. Nonoyama T, Fullerton F, Reznik G, Bucci TJ, Ward JM. Mouse hepatoblastomas: a histologic, ultrastructural, and immunohistochemical study. *Vet Pathol* 1988;25:286-296.
11. Stocker JT. Hepatoblastoma. *Semin Diagn Pathol* 1994;11:136-143.
12. Ammann RA, Plaschkes J, Leibundgut K. Congenital hepatoblastoma: a distinct entity? *Med Pediatr Oncol* 1999;32:466-468.
13. Raney B. Hepatoblastoma in children. *J Pediatr Hematol Oncol* 1997;19:418-422.
14. Abenoza P, Manivel JC, Wick MR. Hepatoblastoma: An immunohistochemical and ultrastructural study. *Hum Pathol* 1982;18:1025-1035.

## Comfortable accommodations

Over 30 years of manufacturing top quality cages!



- Quiet, warm and easy to clean
- Crafted using Formica® brand laminate
- Anodized aluminum gates provide security
- Resting bench
- Litter pan porthole
- Scratching post
- Cages may be divided



Ask us how you can save 33% on ready to assemble cages

**1-800-461-9972**  
**www.clarkcages.com**

Canada: Ontario [705] 497-8900  
USA: California [213] 689-9324  
Pennsylvania [215] 922-5564  
Texas [214] 744-5954