

Gastric Ulceration Following Experimentally Induced Hypoxia and Hemorrhagic Shock: *

In Vivo Study of Pathogenesis in Rabbits

PEKKA-T. HARJOLA, M.D., ARTO SIVULA, M.D.

From the Kemi Central Hospital, Kemi, Finland, and Department of Pathology, Section II, University of Helsinki, Finland

Part I. Experimental Gastric Ulceration

ACUTE ulcerations develop in the upper gastro-intestinal tract in many conditions. In 1842, Curling³ observed acute ulcerations in the duodenum associated with burns. Cushing⁴ described lesions of the upper gastro-intestinal canal after operations on the brain. Acute ulcerations have been encountered with other operations, trauma and various diseases.^{5, 6, 8, 15, 16, 19, 22} Recently, attention has been drawn to the relatively high incidence of acute gastro-intestinal complications, often accompanied by fatal hemorrhages, after thoracic and especially after cardiac surgery.^{1, 10, 11, 14, 20}

Acute ulcerations have been studied experimentally in conjunction with operations on the brain, burns and hemorrhage.^{5, 7, 12, 13, 18} Based on the clinical study of Harjola and Kerminen¹⁰ concerning abdominal complications after thoracic surgery we tried to produce experimental gastro-intestinal ulcerations in connection with thoracic operations by imitating features typical of these operations. The purpose was to evaluate factors associated with operative surgery in the pathogenesis of ulceration.

Methods

Female rabbits weighing 1,800 to 3,400 Gm. were used for the study. Animals were fasted for 24 hours before operation. Nem-

butal anesthesia was used. Tracheostomy was performed for controlled respiration. Arterial pressure was recorded by catheterization of the carotid artery. To produce hemorrhagic shock, blood was withdrawn from the artery into a heparinized 100-cc. syringe from which it was later returned. Arterial pressure was recorded electro-manometrically.

In another series, hypoxia was induced by closing the tracheal tube long enough to induce ventricular fibrillation. Normal cardiac function was restored by administration of oxygen, and the procedure was then repeated in 3 min. Twenty-four hours after the first measure, test animals were reanesthetized, laparotomy was performed and the stomach and intestines were removed and examined macroscopically. Biopsies from various parts of the intestines were performed and also from the liver, spleen, kidney and adrenal.

Auriculectomy and left lower lobectomy were the thoracic operations used. Hemorrhagic shock and hypoxia were combined as complications of thoracic surgery. The animals were distributed among six series.

Series 1. Left lower lobectomy on nine rabbits; five rabbits survived and were examined after 24 hours.

Series 2. Left auriculectomy on 24 rabbits; 11 survived and autopsy was performed after 24 hours.

Series 3. Left auriculectomy on 17 rabbits. Hypoxia resulting in ventricular fibrillation was induced twice. The first period

* Submitted for publication December 4, 1964.

Supported in part by a grant from the Finnish Cultural Foundation.

TABLE 1. *Incidence of Gastric Ulcerations and Petechiae in the Different Series*

Series	No. Animals	Gastric Changes in Per Cent	
		Pete- chiae	Ulcerations
1. Left lower lobectomy	5	0	0
2. Left auriculotomy	11	27	0
3. Left auriculotomy and hypoxia	11	27	0
4. Left auriculotomy and hypoxia and hemorrhagic shock	4	75	25
5. Left auriculotomy and hemorrhagic	8	88	38
6. Hemorrhagic shock	6	67	17

of hypoxia lasted an average of 1 min. 41 sec. and the second 1 min. 43 sec.; 11 rabbits survived and were examined.

Series 4. Left auriculotomy on 10 rabbits. Both hemorrhagic shock and hypoxia were induced. Shock was induced by rapidly drawing off blood until the arterial pressure dropped to less than a half its initial level. The average volume of blood withdrawn was 18 cc./Kg. and the same quantity was returned after 15 min. The average blood pressure variations were 120–51–109 mm. Hg. The first hypoxial period lasted an average of 2 min. 41 sec. and the second 2 min. 39 sec. Only four rabbits from this series survived.

Series 5. Left auriculotomy on 12 rabbits and hemorrhagic shock lasting 15 min. The average volume of blood withdrawn was 22 cc./Kg. and 21 cc./Kg. was returned. The average variations in arterial pressure were 107–45–104 mm. Hg. Four rabbits died. Eight survivors were examined after 24 hours.

Series 6. Hemorrhagic shock was induced in 22 rabbits without thoracotomy. Duration of shock was 15 min. and the average volume of blood withdrawn was 24 cc./Kg. The same quantity of blood was returned. The average blood pressure variations were 120–33–113 mm. Hg. Only six rabbits were alive 24 hours after operation.

Results

Petechiae and ulcerations were established in the gastric mucosa, as shown in Table 1. Fig. 1–3 illustrate typical gastric changes observed on gross examination. Microscopic examination of the changes showed that the petechiae consisted of intramucosal hemorrhages of different degrees. Hemorrhage sometimes extended throughout the mucosa (Fig. 4), sometimes in a circumscribed site between mucosa and muscularis mucosae (Fig. 5). The mucosa was necrotic in cases of ulceration. There was often a manifest hemorrhage between necrotic mucosa and muscularis mucosae (Fig. 6). Increased hyperemia in the mucosal capillaries was observed fairly frequently.

Microscopic changes, mostly moderate, were demonstrated in the liver. Mild hyperemia, swelling of liver cells and, in rare instances, small necrotic foci were encountered. Some sporadic slight changes indicative of stress in the kidney and the adrenals were seen on microscopy. There were no changes in the spleen, small or large intestine.

Discussion

Acute gastric lesions were produced in these experiments without abdominal intervention. Tracheostomy, lobectomy or, alternatively, auriculotomy was performed on the rabbits. The surgical maneuver alone seldom caused gastric changes. Deep hemorrhagic shock of short duration, only 15 min., proved a powerful factor in causing petechiae and ulcerations. Hypoxia did not appear to have such a pronounced

ulcer-producing effect. The high mortality in all experimental series shows that the measures performed constituted a fairly great strain on the animals and were stress inducing.

Acute gastric ulcerations have previously been experimentally provoked in many different ways. A generally typical feature of these ulcerations is that they do not resemble naturally occurring lesions. Therefore, the ulcers do not in themselves warrant conclusions regarding factors associated with operative stress on the pathogenesis of the changes. Rabbits have been employed as test animals, but restraint stress² and histamine-in-beeswax administration alone⁷ do not produce gastric ulcerations in rabbits. Burns do cause

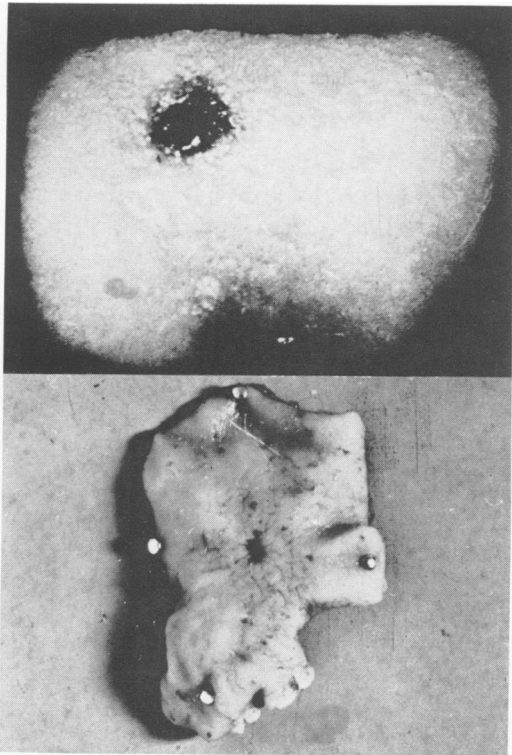


FIG. 1. (Top) Photograph of a solitary gastric ulceration 24 hours after left auriculectomy and hemorrhagic shock. The microscopic appearance is seen in Figure 6. (3×)

FIG. 2. (Bottom) A more advanced solitary ulceration in gastric mucosa seen on gross examination. (1×)

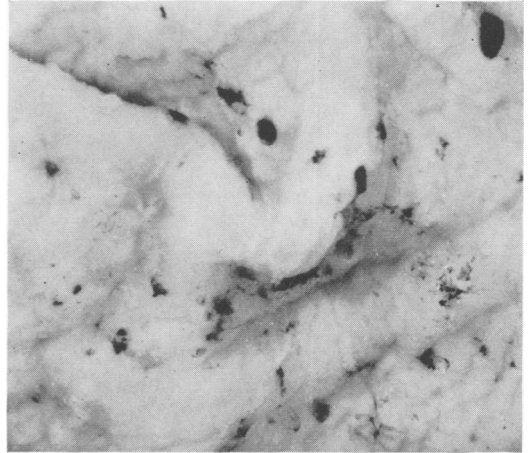


FIG. 3. Multiple lesions on gastric mucosa. Several hemorrhagic petechiae are seen. (2×)

ulcerations in rabbits and in studies of gastric lesions associated with burns, Friesen⁷ concluded that hemoconcentration is the factor causing gastroduodenal ulcer. It is hardly possible that the changes in the present study were caused by hemoconcentration. Rather, removal of blood from the test animals may have caused temporary hemodilution. Friesen noted the failure of blood pressure to fall appreciably after burning the animals. Because of this, he considered that shock plays no role in the genesis of mucosal changes in the stomach.

In the present study, hemorrhagic shock in particular appeared to cause these changes. Clinical studies generally mention only stress in the etiology of acute ulceration. Harjola and Kerminen⁹ noted that patients who developed gastrointestinal hemorrhage after thoracic surgery had often bled profusely during operation.

The importance of hemoconcentration stressed by Friesen might be based on the deceleration and obstruction of capillary flow in the gastric mucosa. The important role of short-term, rapidly corrected hemorrhagic shock in the present experiments suggests bypassing of the capillary network by arteriovenous anastomoses of the gastric mucosa as a protective reaction of the organism to an acute drop in blood pres-

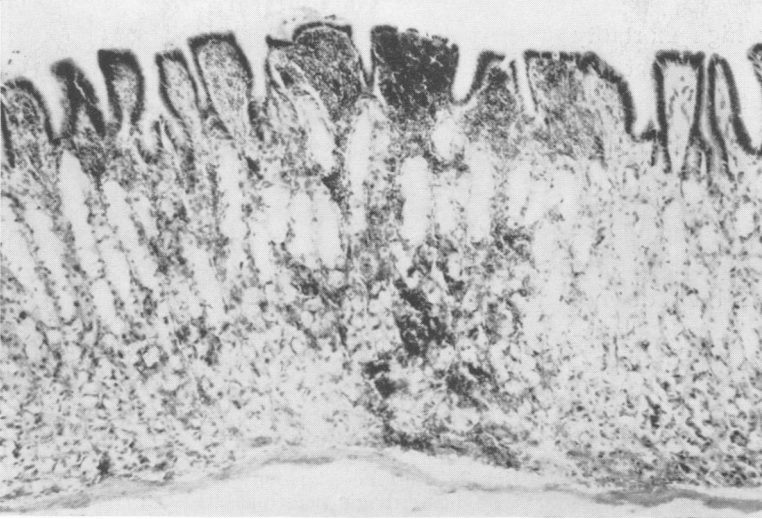


FIG. 4. Micrograph of an intramucosal gastric hemorrhage extending throughout the mucosa. (120 \times)

sure.²¹ The theory introduced by Palmer and Sherman¹⁷ concerning the pathogenesis of gastroduodenal ulcers was based on this thought. It is still uncertain, even in the shunt theory, what the final mechanism is that leads to ulceration. It may be hypoxia of mucosal cells. Lillehei and others¹³ concluded that posthemorrhagic shock, even of relatively short duration, promotes ulcer susceptibility through vasoconstriction of small blood vessels with localized anemic areas in the mucosa. However, it

may be, judging by histologic findings, that hemorrhage develops first between mucosa and muscularis mucosae, prevents nutrition of the mucosa and thus causes necrosis.

Summary (Part I)

The role of thoracic surgery plus hemorrhagic shock and hypoxia in the pathogenesis of acute gastric ulceration was studied in rabbits. Thoracic surgery by itself did not cause these changes regularly. When

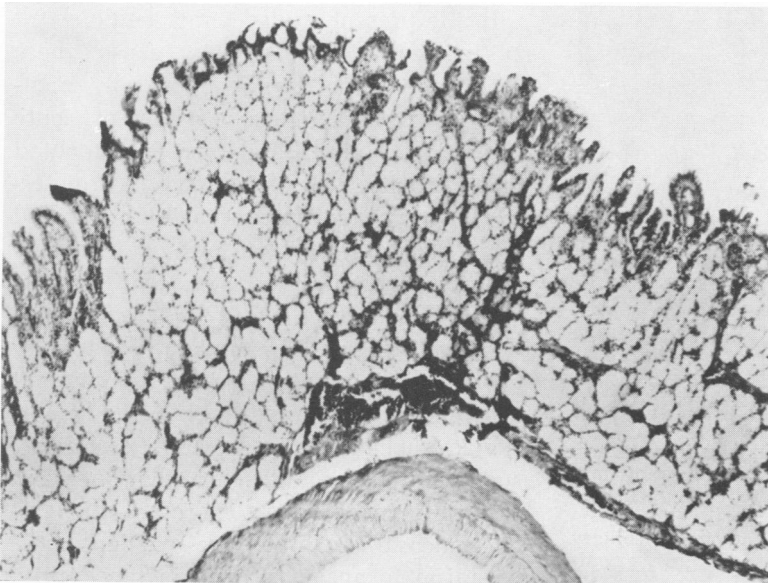
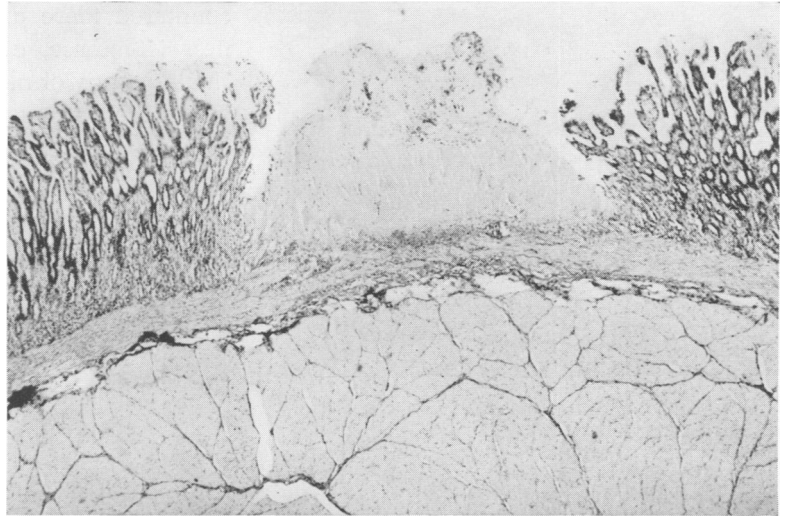


FIG. 5. An intramucosal gastric hemorrhage which is located principally between the mucosa and muscularis mucosae. (40 \times)

FIG. 6. Micrograph showing a gastric mucosal necrosis 24 hours after left auricectomy and hemorrhagic shock. Between the necrosis and muscularis mucosae is a hemorrhagic layer. (40×)



hemorrhagic shock lasting no longer than 15 min. was induced during the operation the majority of animals developed petechiae and ulceration in the gastric mucosa after 24 hours. Hypoxia provoked twice and resulting in ventricular fibrillation did not seem to have a notable effect on these changes. The pathogenesis of acute gastric ulceration is discussed.

Part II. Effects of Hemorrhagic Shock

In the first part of this study it was shown that a hemorrhagic shock of 15 min. duration was the most powerful factor causing gastric mucosal lesions.

To study the rate at which the changes appear, a method by which the gastric mucosa could be inspected during and after the shock was devised.

Methods

The abdominal cavity of rabbits anesthetized with Nembutal was opened, and the stomach exposed. A 5 to 6-cm.-long incision through the seromuscularis was made on the avascular line in the anterior wall of the stomach. The incision left the mucosa intact. The edges of the seromuscularis were retracted to expose the mucosa over an area of 1.5 to 2 cm. in width. This could be done with almost no bleeding.

Blood was withdrawn rapidly into a heparinized syringe until the arterial pressure dropped below 40 mm. Hg. Mucosal changes were followed throughout the shock period of 15 min., whereupon the blood was restored. The blood letting and restoration were repeated several times.

Results

Removal of a small quantity of blood (20 cc.), which reduced blood pressure by only 20 mm. Hg, caused slight but visible vasoconstriction in the mucosa and the appearance of sharply demarcated anemic spots 1 to 2 mm. in diameter (Fig. 7). In the middle of these spots a small dark point could often be seen. When sufficient blood (50-60 cc.) was removed the entire mucosa was anemic and displayed major shapeless patches, 1 to 2 cm. in diameter, in addition to the smaller spots which appeared earlier. The intensity of the changes increased during the 15 min. of shock.

When blood was restored intensive reactive hyperemia ensued and gradually expanding hemorrhages appeared in the center of the small white spots (Fig. 8 A-C). The larger, more diffuse pale patches disappeared in 1 to 2 min. and no hemorrhages appeared in them. The small spots also disappeared, but much more slowly,

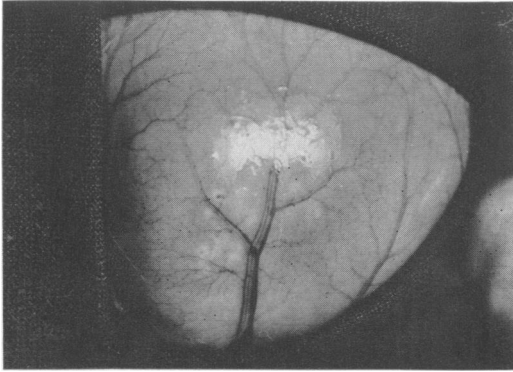


FIG. 7. Photograph of gastric mucosa seen from outside during the period of hemorrhagic shock. The mucosa is throughout anemic and the blood vessels are constricted. Shapeless white patches and small sharply demarcated white spots are seen on the mucosa. In the middle of some white spots a dark point can be seen. (2 \times)

in 5 to 10 min. Ten min. after restoration of blood volume only the hemorrhagic spots which had grown to 1 to 3 mm. in size were seen on the evenly red mucosa. After this, the same amount of blood was removed again and the changes recurred in the same places. New small sharply defined white spots appeared (Fig. 9). Restoration of blood volume was again followed by a hyperemic phase (Fig. 10). Some new hemorrhages appeared and old hemorrhages grew.

When the stomach was opened the mucosa showed the same hemorrhagic changes (Fig. 11) on its internal surface.

Discussion

Hypovolemia induced by removal of blood is reflected in intensive changes in the gastric mucosa. Observations *in vivo* reveal three kinds of change in the gastric mucosal circulation:

1. The mucosa generally becomes pale in consequence of general vasoconstriction.
2. Several large diffusely defined pale patches appear and disappear completely after restoration of blood volume. No hemorrhages appear in these patches.
3. Small clearly demarcated spots are en-

countered more uncommonly. Their paleness is intense, even after removal of a small quantity of blood. If the blood volume is restored rapidly these spots also disappear—but reappear in exactly the same

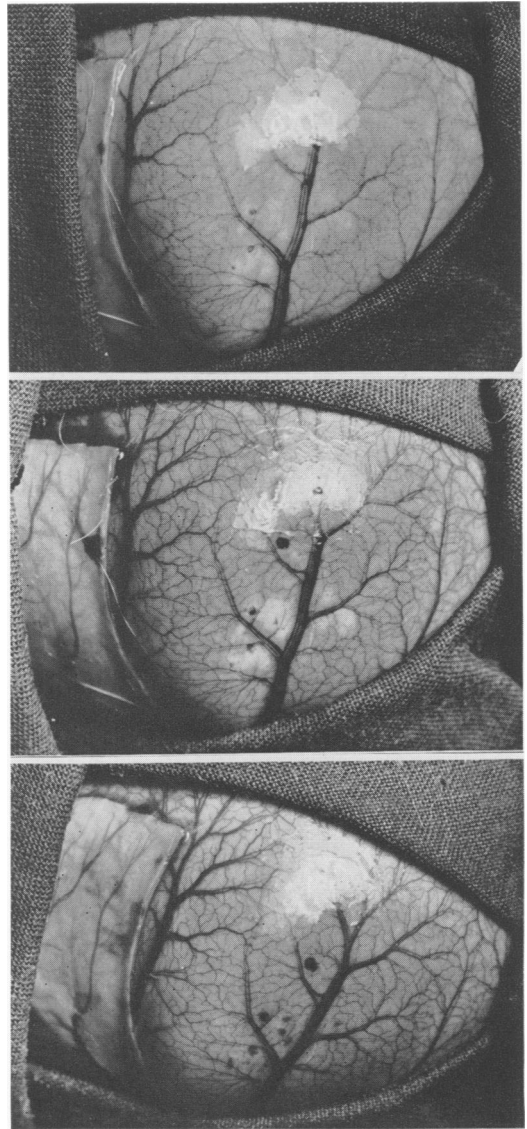


FIG. 8. During the return of the blood the vessels begin to fill and the color of the mucosa turns normal. The white patches disappear. In the middle of the white spots hemorrhages are seen to develop and the white spots disappear gradually. The changes proceed in the Figures A and B. In Figure C an equally hyperemic mucosa is seen, in which there are hemorrhages instead of the former white spots (2 \times). (Top to bottom: A, B, C).

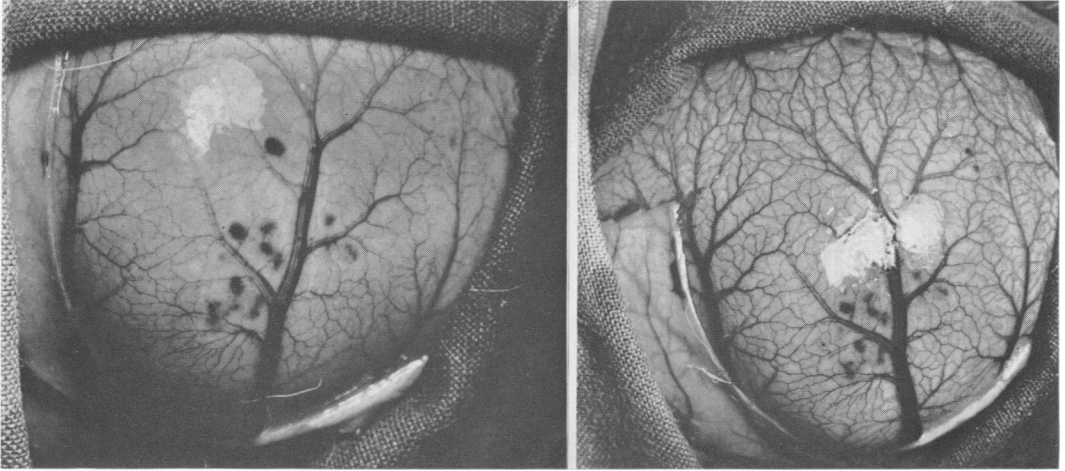


FIG. 9. (Left) When blood is withdrawn again new white spots appear and when blood is returned new hemorrhages appear in the middle of the white spots. The arrows indicate new small hemorrhages in the middle of the white spots. (2X)

FIG. 10. (Right) The state of reactive hyperemia after the second shock. The white patches and spots have disappeared and the hemorrhages increased in size and number. (2X)

place when blood is again removed, and after hypovolemia lasting 15 min. hemorrhages occur immediately after restoration of the blood.

Obviously the explanation of the pathogenesis of acute shock-induced changes in the gastric mucosa lies in these small, 1 to 2 mm., sharply defined white spots. Examination of the spots in different phases of the experiment gave the impression that decrease in blood volume stops circulation in the spots rapidly. It was noted that the spots appeared after only slight decrease in blood pressure. Evidently an anoxic tissue lesion develops inside the anemic spots during the shock phase and, through injury to capillaries, results in hemorrhage. The hemorrhages obviously constitute the point of origin of ulcerations.

It is interesting that the changes developed so rapidly and that hypovolemic shock of no longer than 15 min. sufficed to cause irreversible changes of such intensity.

The changes may be thought to originate in two different ways. Gelin⁹ demonstrated aggregation of red cells at the capillary level in association with shock. Such aggregation might account for the more ex-

tensive anemic patches the size, shape and location of which varied in successive phases of the shock. On the other hand, it may be the vasoconstriction claimed by Lillehei¹³ which results in small sharply demarcated spots which always appear at the same site when shock is repeated. It may also be that behind these spots is a certain regulatory mechanism linked with special structures of topical character. Arteriovenous anastomoses in the stomach wall described by Sherman and Neuman²¹

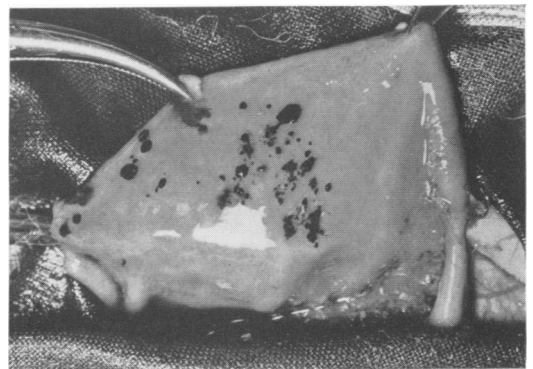

FIG. 11. The inner surface of the opened stomach. The same area is seen as in the previous figures. Note that the hemorrhages are larger and more numerous on the inner surface of the mucosa. (2X)

might be such a structural foundation. Based on this, a general theory of the genesis of gastroduodenal ulcers was introduced by Palmer and Sherman.¹⁷ Verification of this theory requires observation of the microcirculation of the gastric mucosa in shock.

Summary (Part II)

To study the rate at which the lesions in the gastric mucosa appear a method was created by which gastric mucosa could be inspected during and after shock.

Three kinds of changes were noted. During acute bleeding and shock of 15 min. duration: 1) gastric mucosa becomes pale in consequence of general vasoconstriction; 2) several large diffuse pale patches appear and disappear completely after the restoration of blood volume; 3) small sharply defined spots appear at the beginning of blood letting. Their paleness is very intense. Hemorrhages ensue in these spots after restoration of blood.

Obviously the explanation of the pathogenesis of acute shock lesions in the gastric mucosa lies in these small white spots. An anoxic tissue lesion develops inside the anemic spots during the shock and, through the injury to the capillaries, results in hemorrhage.

Acknowledgments

The authors would like to express appreciation to professor Olavi Peräsalo, M.D., Department for Thoracic Surgery, University of Helsinki, for kind encouragement and to professor Harald Teir, M.D., Department of Pathology, Section II, University of Helsinki, for valuable criticism and advice.

References

1. Berkowitz, D., Wagner, B. M. and Uricchio, J. F.: Acute Peptic Ulceration Following Cardiac Surgery. *Ann. Intern. Med.*, **46**:1015, 1957.
2. Brodie, D. A. and Hanson, H. M.: A Study of the Factors Involved in the Production of Gastric Ulcers by the Restraint Technic. *Gastroenterology*, **38**:353, 1960.
3. Curling, T. B.: On Acute Ulceration of the Duodenum in Cases of Burn. *Med.-Chirurg. Trans.*, **25**:260, 1842.
4. Cushing, H.: Peptic Ulcers and the Interbrain. *Surg. Gynec. Obstet.*, **55**:1, 1932.
5. Davis, R. A., Wetzel, N. and Davis, L.: Acute Upper Alimentary Tract Ulceration and Hemorrhage Following Neurosurgical Operations. *Surg. Gynec. Obstet.*, **100**:51, 1955.
6. Fletcher, D. G. and Harkins, H. N.: Acute Peptic Ulcer as a Complication of Major Surgery, Stress or Trauma. *Surgery*, **36**:212, 1954.
7. Friesen, S. R.: The Genesis of Gastroduodenal Ulcer Following Burns. *Surgery*, **28**:123, 1950.
8. Friesen, S. R., Merendino, K. A., Baronofsky, I. D., Mears, F. B. and Wangenstein, O. H.: The Relationship of Bone Trauma to the Development of Acute Gastroduodenal Lesions in Experimental Animals and in Man. *Surgery*, **24**:134, 1948.
9. Gelin, L.-E.: Studies in Anemia of Injury. *Acta Chir. Scand.*, **Suppl. 210**, 1956.
10. Harjola, P.-T. and Kerminen, T.: Akute Abdominalkomplikationen nach Thoraxoperationen. *Thoraxchirurgie*, **11**:473, 1964.
11. Hertzog, P. and Toty, L.: Complications abdominales graves en chirurgie thoracique. *Poumon*, **14**:477, 1958.
12. Keller, A. D.: Ulceration in the Digestive Tract of the Dog Following Intracranial Procedures. *Arch. Path.*, **21**:127, 1936.
13. Lillehei, C. W., Dixon, H. L. and Wangenstein, O. H.: Relation of Anemia and Hemorrhagic Shock to Experimental Ulcer Production. *Proc. Soc. Exp. Biol. Med.*, **68**:125, 1948.
14. Major, H.: Abdominelle Komplikationen nach Thoraxeingriffen. *Zbl. Chir.*, **86**:335, 1961.
15. McDonnell, W. V. and McCloskey, J. F.: Acute Peptic Ulcers as a Complication of Surgery. *Ann. Surg.*, **137**:67, 1953.
16. Mears, F. B.: Autopsy Survey of Peptic Ulcer Associated with Other Diseases. *Surgery*, **34**:640, 1953.
17. Palmer, E. D. and Sherman, J. L., Jr.: Hypoxia of Abnormal Physiologic Origin as the Final Common Pathway in Gastroduodenal Ulcer Genesis. *Arch. Intern. Med. (Chicago)*, **101**:1106, 1958.
18. Price, P. B., Hanlon, R., Longmire, W. P. and Metcalf, W.: Experimental Shock I. Effects of Acute Hemorrhage in Healthy Dogs. *Bull. J. Hopkins Hosp.*, **69**:327, 1941.
19. Risholm, L.: Acute Upper Alimentary Tract Ulceration and Hemorrhage Following Surgery or Traumatic Lesions. *Acta Chir. Scand.*, **110**:275, 1956.
20. Rotthoff, F., Konrad, R. M. and Willmann, K. H.: Akute Magen- und Zwölffingerdarmgeschwüre nach Thoraxeingriffen. *Langenbecks Arch. Klin. Chir.*, **290**:31, 1958.
21. Sherman, J. L., Jr. and Newman, S.: Functioning Arteriovenous Anastomosis in the Stomach and Duodenum. *Amer. J. Physiol.*, **179**:279, 1954.
22. Stevens, H., Guin, G. H. and Gilbert, E. F.: Gastrointestinal Ulceration and Central Nervous System Lesions. *Amer. J. Dis. Child.*, **106**:613, 1963.