

# Rerouting Arterial Flow to Relieve Ischemia: \*

## Femoro-Femoral, Axillary Femoral and Carotid-Carotid Artery Bypasses

W. DEAN WARREN, M.D., JOHN J. FOMON, M.D.

*From the Department of Surgery, University of Miami School of Medicine and Jackson Memorial Hospital, Miami, Florida*

ALMOST with the advent of modern vascular surgery, it was demonstrated that prostheses or grafts could be placed in other than the anatomic course of the bypassed or replaced artery and nourish an organ or part satisfactorily. Such detours, illustrated by DeBakey *et al.*,<sup>6</sup> usually have been forced by technical considerations. Recently, arterial flow has been rerouted in such fashion for other reasons. In 1960 McCaughan and Kahn<sup>10</sup> anastomosed the end of a prosthesis to the side of an external iliac artery, brought it across the abdomen extraperitoneally, passed it beneath the inguinal ligament and tunneled it subcutaneously to the side of the contralateral popliteal artery. In this patient they also joined the distal end of the divided deep femoral artery end-to-side to the prosthesis. Blood flowed satisfactorily. This route was chosen rather than a more extensive operation because of poor "run off" and questionable likelihood of success. Another patient's poor general condition was a factor in the choice of this procedure. Vetto<sup>22</sup> simplified the operation by performing femoro-femoral bypass for obstruction of a single iliac artery. In 1961 Lewis<sup>9</sup> anastomosed a prosthesis end-to-end to the left subclavian artery, brought it down under the skin of the thorax into the abdomen to the end of the transected distal abdominal aorta. This circuitous arrangement was

impelled by technical difficulties in repair of a dissecting aortic aneurysm. Blaisdell *et al.*<sup>1</sup> removed an abdominal aortic prosthesis because of infection and hemorrhage. Distal ischemia resulted. They sutured a prosthesis to the side of the descending thoracic aorta, brought it retropleurally and subcutaneously to the side of the left common femoral artery. A second prosthesis, connected end-to-side to the first, provided flow to the right common femoral artery. Later, Blaisdell and Hall<sup>2</sup> reported three patients who had axillary-femoral artery prosthetic bypasses. In two the indication was infection. In the third, because of cardiac arrest, abdominal incision and general anesthesia were avoided.

### Case Reports

Six patients had arterial bypass prostheses or grafts inserted in other than the usual arterial route (Fig. 1). Four had femoro-femoral crossover bypasses or some modification of this procedure. Three were prohibitive operative risks for more extensive operations and the fourth had an infection. The only axillary femoral bypass was also done because of infection. The sixth patient had carotid-carotid bypass in anticipation of resection of a neoplasm and attached carotid artery.

**Case 1. Crossover Prosthesis, Right Femoral to Left Common Femoral Artery.** This 50-year-old woman appeared 10 years older than her age. She had undergone many abdominal operations for

\* Submitted for publication January 15, 1965.

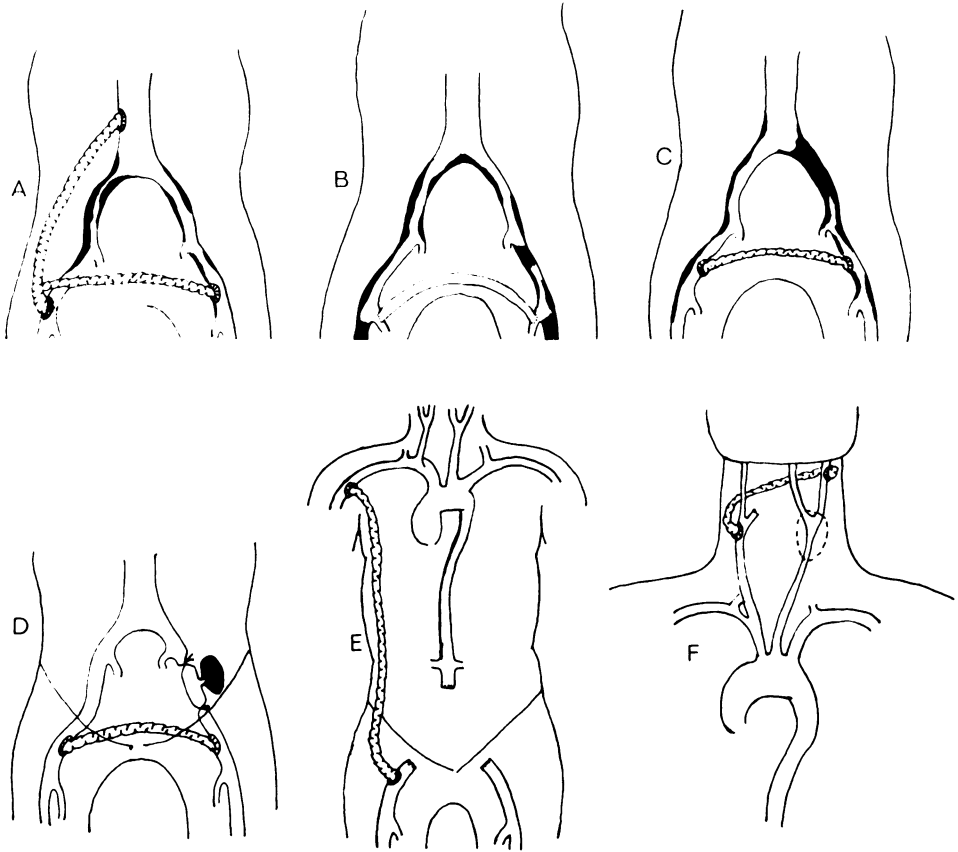


FIG. 1 A) Case 1. Crossover prosthesis, right femoral prosthesis to left common femoral artery. B) Case 2. Crossover autogenous saphenous vein graft, right to left deep femoral artery. C) Case 3. Crossover prosthesis, left to right common femoral artery. D) Case 4. Crossover prosthesis, right to left common femoral artery. E) Case 5. Ipsilateral prosthesis, right axillary to common femoral artery. F) Case 6. Crossover autogenous saphenous vein graft, right carotid bulb to left internal carotid artery.

causes unrelated to her present complaint. For 5 years she had progressive intermittent claudication of both lower extremities, more marked on the right. For several months she also had ischemia rest pain in the right leg which was intolerable. The right leg was cooler than the left. Both femoral pulses were diminished; and distal pulsations were not palpable. Translumbar aortogram (Fig. 2a) showed diffuse arteriosclerosis in the aorta and iliac arteries. At the origin of the right common iliac artery there was a partially occluding plaque. "Run off" x-ray films showed segmental occlusion of the right superficial femoral artery with reconstitution of the popliteal artery and distal vessels in the leg. On the left side there was diffuse arteriosclerosis but no block. Aorto-femoral bypass was performed on the right side. Symptoms were relieved, but after 2 months intermit-

tent claudication of the left lower extremity supervened. Translumbar aortogram (Fig. 2b) now showed a functioning prosthesis but there was complete occlusion of the left common iliac artery. The patient refused operation. During the subsequent 7 months severe rest pain developed in the left leg. Right femoral artery pulse was of good quality but other lower extremity pulsations were absent. Left femoral arteriogram showed patency of the vessels of that extremity. A prosthesis was anastomosed end-to-side to the prosthesis in the right inguinal area and tunneled subcutaneously above the pubes to the side of the left common femoral artery. The patient was relieved of symptoms and, at the time of writing, she has good femoral pulses on both sides but no pulses distally. Aortogram (Fig. 2c) shows the functioning crossover graft.

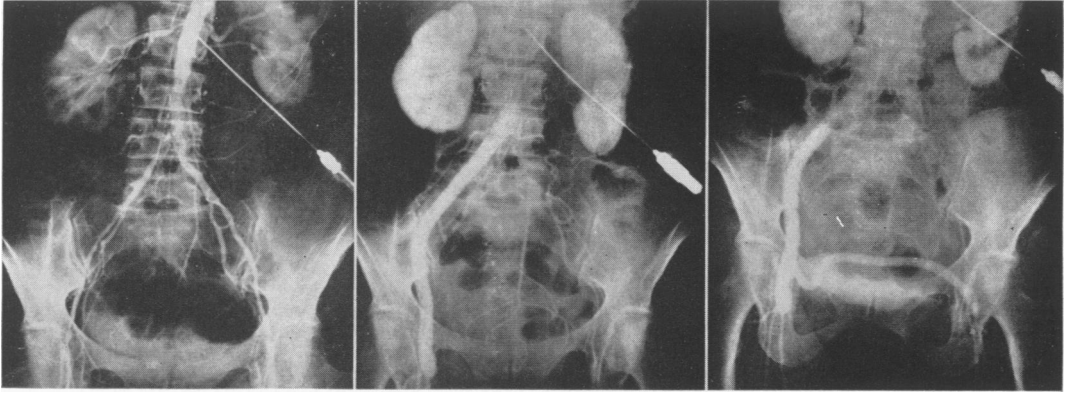


FIG. 2. Case 1. (Left). A translumbar aortogram showed diffuse disease with a high degree of partial segmental occlusion at the origin of the right common iliac artery. (Middle). The right aorto-femoral prosthesis is functioning but now there is a complete obstruction of the left common iliac artery. (Right). The crossover prosthesis from the right femoral prosthesis to the left common femoral artery is functioning well.

**Case 2. Crossover Autogenous Saphenous Vein Graft, Right to Left Deep Femoral Artery.** A fragile, 81-year-old woman with diabetes mellitus had been hospitalized 5 months previously because of dry gangrene of the left great toe. Both feet were ischemic. A moderately good femoral pulsation was palpable on the right. The contralateral pulse was barely discernible and none was present distally. Gangrene of the toe progressed proximally with accompanying cellulitis and pain. At operation both common and superficial femoral arteries were extensively calcified and arteriosclerotic. Only the deep femoral arteries were relatively normal and available for anastomosis without extensive endarterectomies. The distal end of an autogenous saphenous vein graft was sutured end-to-side to the right deep femoral artery. The vein was passed through a suprapubic, subcutaneous tunnel in the anterior abdominal wall and was anastomosed end-to-side to the left deep femoral artery. Following amputation of the left great toe, the stump healed promptly. Postoperative arteriogram showed a functioning prosthesis.

**Case 3. Crossover Prosthesis, Left to Right Common Femoral Artery.** For 6 months this 69-year-old man had progressive, unremitting, intermittent claudication of the right lower extremity and for 1 month had intolerable rest pain of the right foot and leg. On examination there was obvious ischemia in the area of pain. Pulses were absent in both lower extremities except for a moderately good pulsation in the left femoral area. Translumbar aortogram showed diffuse arteriosclerosis with complete occlusion of the origin of

the left common iliac artery. A prosthesis was tunneled subcutaneously cephalad to the pubis from one femoral artery to the other. At the time of writing, pulsations in the prosthesis remain vigorous. Rest pain has been relieved and exercise tolerance has returned.

**Case 4. Crossover Prosthesis, Right to Left Common Femoral Artery.** A 42-year-old woman had total abdominal hysterectomy and bilateral extraperitoneal pelvic lymphadenectomy for Stage I squamous cell carcinoma of the cervix. Her postoperative course was complicated by prolonged adynamic ileus, wound dehiscence and pulmonary atelectasis. Because of chills, fever, abdominal pain in the left lower quadrant, nausea and constipation, she was readmitted to the hospital. There was a firm, fixed, tender mass, 6 cm. in diameter, in the left lower quadrant. The mass was operated upon extraperitoneally and found to be an infected hematoma. Opening the retroperitoneal space apparently released tamponade and brisk hemorrhage from the left external iliac artery followed. The vessel was scarred and friable and, in the presence of infection, unsuitable for local reconstruction. It was ligated proximal and distal to the bleeding point. The wound was then closed. The left common femoral artery was then exposed and the end of a prosthesis was sutured to its side. The prosthesis crossed the abdomen in the subcutaneous tissue in the suprapubic area and was anastomosed end-to-side to the contralateral artery. Postoperatively the patient did well (Fig. 3). Three months later, at the time of writing, bilateral dorsalis pedis pulsations are palpable.

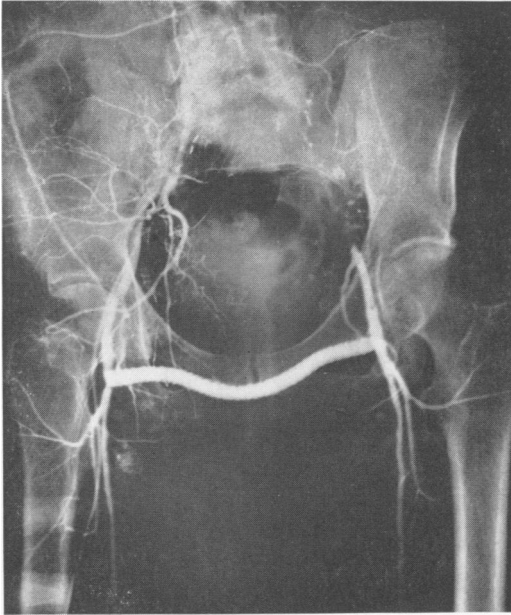


FIG. 3. Case 4. Infection in the area of the left external iliac artery prevented a bypass of other more direct vascularization of the left lower extremity. The right to left common femoral prosthesis functions well, both clinically and by aortogram.

**Case 5. Ipsilateral Prosthesis, Right Axillary to Common Femoral Artery.** Although this man was only 47 years old, an aortobilateral femoral bypass and bilateral lumbar sympathectomies were performed 3 years previously for ischemia of the lower extremities. Relief was transient and the bypass was revised 1 year later. After another year, 3 years after the initial operation, both legs were cool and the right foot was mottled and cyanotic without capillary filling. All pulsations were absent. The femoral arteries were exposed at operation. On the left a collection of cloudy fluid was encountered. Because the extremity was viable and subsequent infection was likely, the prosthesis was removed and plans for arterial reconstruction were abandoned. On the right side femoral arteriogram showed segmental occlusion of the superficial femoral artery with flow through the popliteal artery via a well-developed deep femoral artery. In the abdomen the prosthesis and the infrarenal aorta were found thrombosed and the prosthesis was adherent to the duodenum. Following removal of the prosthesis a defect in the duodenal wall was closed and endarterectomy of the aorta was performed. A new prosthesis was sutured end-to-end in the aorta and end-to-side in the right common femoral artery. Postoperatively the right leg was improved and the left unchanged. The patient developed fever in spite of precautions to

prevent infection, but 10 days later, at discharge, his temperature was normal. One month later daily fever recurred and was controlled with antibiotics. The diagnosis was right hydronephrosis and pyelonephritis. Two weeks later the patient was readmitted to the hospital because of upper gastrointestinal bleeding. The possibility that a fistula had formed between bowel and prosthesis prompted immediate operation. Intense retroperitoneal cellulitis necessitated removal of the functioning prosthesis and ligation of the aorta. The right femoral artery pulsation immediately disappeared and the right leg became ischemic although the left remained viable. Accordingly, a prosthesis was anastomosed end-to-side to the right axillary artery and led through a subcutaneous tunnel to the side of the right femoral artery. This bypass remained patent only for several hours. Two days later because of gangrene, an above-the-knee amputation of the right leg was performed. The patient died, following operation, from septicemia.

**Case 6. Crossover Autogenous Saphenous Vein Graft, Right Carotid Bulb to Left Internal Carotid Artery.** Nine months prior to admission this 59-year-old man had a left radical neck dissection and total laryngectomy performed for squamous cell carcinoma of the larynx. At the time of this admission, in the left side of the neck there was a hard, ovoid, 7-cm. mass intimately attached to a portion of the common carotid artery. Aspiration biopsy resulted in a diagnosis of squamous cell carcinoma. *En bloc* excision of the tumor and involved carotid artery was planned but even fleeting digital compression of the artery was not tolerated. To maintain left internal carotid artery flow following excision of the tumor, an autogenous saphenous vein graft was passed posteriorly around the neck in the subcutaneous tissue. The proximal divided end of the right external carotid artery was sutured to the end of the saphenous vein. The proximal end of the vein was anastomosed end-to-side to the left internal carotid artery. Postoperatively the patient was alert, moved his extremities and had no neurologic deficiency. During the night of the day of operation the patient had a stroke. Operation was not carried out for some 13 hours after the cerebral vascular occlusion. At the second operation there was an acute angulation of the vein at the point of anastomosis to the external carotid artery. The graft was thrombosed as was the left internal carotid artery. Flow was re-established after removal of the thrombus and revision of the anastomosis so that the end of the vein graft was sutured to the side of the right carotid bulb. However, the patient died 72 hours later from cerebral infarction.

### Discussion

Short-term results of unorthodox arterial bypasses in this and in other series<sup>1, 2, 10, 22</sup> have been good. Long-term results are not known, but when rerouting is done for technical reasons,<sup>4, 6, 14</sup> long-term improvement persists. Hemodynamics are not restored to normal. Wesolowski *et al.*<sup>24</sup> demonstrated that laminar flow was replaced by turbulence both in glass models and in dogs when branches came off at right angles. Szilagyi<sup>21</sup> found that while simple end-to-end arterial anastomosis did not decrease flow, end-to-side anastomosis decreased flow by as much as 60 per cent and bypass around a ligated artery diminished flow by as much as 50 per cent. Efficiency of flow could be improved by decreasing the angle of anastomosis. It may be that in each of the six cases reported here the undesirable but necessary wide angles of anastomoses converted laminar to turbulent flow. Although volume of flow to the affected extremity was increased in the survivors, it is probable that these bypasses did not provide maximum flow. In Cases 1, 2 and 3, normal flow could not be expected because of the arteriosclerosis. Another disadvantage is the possibility that flow to the "good" leg may be decreased by hemometakinesia<sup>5</sup> or by the situation seen in anomalous coronary arteries<sup>17, 18, 19</sup> and in the subclavian steal syndrome.<sup>11, 16</sup> Flow to the "good" leg may be reduced but this depends, among other things, on cardiac output and peripheral resistance.<sup>7</sup> There is experimental evidence indicating that flow to the "unaffected" extremity is decreased<sup>12, 15</sup> and contrarily that it may remain unchanged or even increase.<sup>20</sup>

Whatever the hemodynamics, clinical improvement in the four patients showed that the procedure has definite, if limited, indications. Before the use of bypasses, certain poor-risk patients were forced to accept amputation, with its mortality, as a lesser risk than the more extensive revasculariz-

ing operations. The other indication for bypass operations is infection. Although survival is possible after bilateral common carotid artery ligation,<sup>3</sup> unilateral ligation carries risk, especially in the elderly.<sup>13, 23</sup> At the University of Miami, replacement<sup>8</sup> is preferred to carotid artery ligation in operations for neoplasms of the neck. Carotid-carotid artery bypass was chosen in Case 6 because it was believed that cure was possible and because an ipsilateral bypass could not have been covered by soft tissue. Failure was probably a function of technic rather than of principle.

### Summary

Blood flow to an ischemic area may be re-established over a route other than that of the bypassed or replaced artery as has been done frequently for technical convenience. Similar unorthodox bypasses have been performed to lessen the magnitude of an operation in poor-risk patients or to avoid an area of infection. Although indications for such bypasses are limited, six cases are reported. In four rerouting was from one femoral area to the other. In three the hazard of a major operative procedure was the indication. In the fourth infection prevented an ilio-femoral bypass and only a femoro-femoral bypass was possible. In the fifth patient axillary-femoral bypass was done because of retroperitoneal infection. In the sixth carotid-carotid artery bypass was performed in anticipation of resection of the left common carotid artery. Although there is evidence that such bypasses disturb normal hemodynamics, patients surviving in this and other series had satisfactory revascularization.

### References

1. Blaisdell, F. W., De Mattei, G. A. and Gander, P. J.: Extraperitoneal Thoracic Aorta to Femoral Bypass Graft as Replacement for an Infected Aortic Bifurcation Prosthesis. *Amer. J. Surg.*, 102:583, 1961.
2. Blaisdell, F. W. and Hall, A. D.: Axillary-Femoral Artery Bypass for Lower Extremity Ischemia. *Surgery*, 54:563, 1963.

3. Catlin, D.: A Case of Carcinoma of the Larynx Surviving Bilateral Carotid Artery Ligation. *Ann. Surg.*, **152**:809, 1960.
4. Crawford, E. S., DeBakey, M. E., Morris, G. C., Jr. and Cooley, D. A.: Thrombo-Obliterative Disease of the Great Vessels Arising from the Aortic Arch. *J. Thor. Cardio. Surg.*, **43**:38, 1962.
5. DeBakey, M. E., Burch, G., Thorpe, R. and Ochsner, A.: The "Borrowing-Lending" Hemodynamic Phenomenon (Hemometakinesia) and Its Therapeutic Application in Peripheral Vascular Disturbances. *Ann. Surg.*, **126**:850, 1947.
6. DeBakey, M. E., Crawford, E. S., Cooley, D. A., Morris, G. C., Jr., Royster, T. S. and Abbott, W. P.: Aneurysm of Abdominal Aorta: Analysis of Results of Graft Replacement Therapy One to Eleven Years after Operation. *Ann. Surg.*, **160**:622, 1964.
7. Haddy, F. J.: Peripheral Vascular Resistance. *Amer. Heart J.*, **60**:1, 1960.
8. Keirle, A. M. and Altemeier, W. A.: Resection of the Carotid Arteries for Neoplastic Invasion with Maintenance of Circulation. *Amer. Surg.*, **26**:588, 1960.
9. Lewis, C. D.: A Subclavian Artery as the Means of Blood Supply to the Lower Half of the Body. *Brit. J. Surg.*, **48**:574, 1961.
10. McCaughan, J. J., Jr. and Kahn, S. F.: Cross-over Graft for Unilateral Occlusive Disease of the Iliofemoral Arteries. *Ann. Surg.*, **151**:26, 1960.
11. Mannick, J. A., Suter, C. G. and Hume, D. M.: The "Subclavian Steal" Syndrome: A Further Documentation. *J.A.M.A.*, **182**:254, 1962.
12. May, A. G., DeWeese, J. A. and Rob, C. G.: Effect of Sympathectomy on Blood Flow in Arterial Stenosis. *Ann. Surg.*, **158**:182, 1963.
13. Moore, O. and Baker, H. W.: Carotid Artery Ligation in Surgery of the Head and Neck. *Cancer*, **8**:712, 1955.
14. Morris, G. C., Jr., Crawford, E. S., Cooley, D. A. and DeBakey, M. E.: Revascularization of the Celiac and Superior Mesenteric Arteries. *Arch. Surg.*, **84**:95, 1962.
15. Reese, H. L., Cullen, M. L. and Beyer, F. D.: Local Shifting of Blood in the Lower Extremities. *J.A.M.A.*, **149**:821, 1952.
16. Reivich, M., Holling, H. E., Roberts, B. and Toole, J. F.: Reversal of Blood Flow Through Vertebral Artery and its Effect on Cerebral Circulation. *New Engl. J. Med.*, **265**:878, 1961.
17. Rowe, G. G. and Young, W. P.: Anomalous Origin of the Coronary Arteries with Special Reference to Surgical Treatment. *J. Thor. Cardio. Surg.*, **39**:777, 1960.
18. Sabiston, D. C., Jr., Neill, C. A. and Taussig, H. B.: The Direction of Blood Flow in Anomalous Left Coronary Artery Arising from the Pulmonary Artery. *Circulation*, **22**:591, 1960.
19. Sabiston, D. C., Jr., Pelargonio, S. and Taussig, H. B.: Myocardial Infarction in Infancy: The Surgical Management of a Complication of Congenital Origin of the Left Coronary Artery from the Pulmonary Artery. *J. Thor. Cardio. Surg.*, **40**:321, 1960.
20. Snell, E. S., Eastcott, H. H. G. and Hamilton, M.: Circulation in Lower Limb Before and After Reconstruction of Obstructed Main Artery. *Lancet*, **1**:242, 1960.
21. Szilagyi, D. E., Whitcomb, J. G., Schenker, W. and Waibel, P.: The Laws of Fluid Flow and Arterial Grafting. *Surgery*, **47**:55, 1960.
22. Vetto, R. M.: The Treatment of Unilateral Iliac Artery Obstruction with a Trans-abdominal, Subcutaneous, Femoro-Femoral Graft. *Surgery*, **52**:342, 1962.
23. Watson, W. L. and Silverstone, S. M.: Ligation of the Common Carotid Artery in Cancer of the Head and Neck. *Ann. Surg.*, **109**:1, 1939.
24. Wesolowski, S. A., Sauvage, L. R., Pinc, R. S. and Fries, C. C.: Dynamics of Blood Flow in Graft Disproportions and in Normal Blood Vessels. *Surg. Forum*, **6**:227, 1955.