Surgical Considerations in the Treatment of Aneurysms of the Thoraco-abdominal Aorta *

MICHAEL E. DEBAKEY, M.D., E. STANLEY CRAWFORD, M.D.,
H. EDWARD GARRETT, M.D., ARTHUR C. BEALL, JR., M.D.,
J. F. HOWELL, M.D.

From the Cora and Webb Mading Department of Surgery, Baylor University College of Medicine and The Methodist Hospital, Houston, Texas

THORACO-ABDOMINAL aneurysms, as defined here, involve primarily the upper segment of the abdominal aorta but usually extend proximally through the diaphragm to involve a variable portion of the descending thoracic aorta and distally to the bifurcation of the aorta or even beyond this level into the common iliac arteries. Such aneurysms are among the most serious and challenging forms of the disease, not only because of their extensive nature involving both body cavities and their relatively difficult anatomic accessibility, but also because the major arteries to the abdominal viscera—namely, the celiac, superior mesenteric, and renal arteries—arise from this segment of the aorta. This latter fact is perhaps the most significant surgical feature of these aneurysms owing to the potential danger of producing fatal ischemic damage to such vital structures as the kidneys, liver, and gastrointestinal tract as a consequence of temporary arrest of circulation to these organs during the period required to perform excision and graft replacement.

Our original surgical experience with four cases of this type of aneurysm was reported in 1956 [1] and demonstrated the feasibility of surgical treatment consisting of resection and graft replacement. Since that time, surgical management of an additional 38 patients with such aneurysms has provided sufficient experience to evaluate further the various surgical approaches to this problem and the results of surgical treatment. Accordingly, this report is concerned with certain significant observations derived from an analysis of our surgical experience with 42 cases of thoraco-abdominal aneurysms, with particular emphasis on technical considerations; studies on gastrointestinal, renal and hepatic function; and long-term results.

Clinical Material

Among the 42 patients in this series, males predominated by a ratio of eight to one (Fig. 1). The age distribution of these patients ranged from 20 to 68 years of age with the highest incidences occurring in the fifth, sixth and seventh decades of life (Fig. 1). Arteriosclerosis was the most common etiologic basis for the aneurysmal disease and syphilis was next in frequency, with respective incidences of 62% and 26% (Fig. 2). In the remaining patients, all of whom were in the younger age categories, the disease consisted of a dissecting aneurysm (Fig. 2).

Surgical Technic

As emphasized previously, there are two major considerations in extirpation of aneu-

* Presented before the American Surgical Association, Philadelphia, Pennsylvania, May 12–14, 1965.

Supported in part by U. S. Public Health Service Grants HE-05387, HE-03137, HE-05435.

rysms of this type, both of which are derived from the location and extensive nature of the lesion. The first of these is concerned with proper anatomic exposure, not only of the aneurysm and its major visceral branches, but also of the uninvolved segments of the aorta below the aneurysm in the abdominal cavity and above the aneurysm in the thoracic cavity. The second and most significant consideration is concerned with the potential ischemic damage to such vital organs as the kidneys, liver and gastrointestinal tract as a result of the necessity for temporary arrest of circulation to them during performance of the procedure. Although there may be considerable variation in the tolerance of different tissues to ischemia as a consequence of various factors such as age, pre-existing disease and collateral blood supply, the fact remains that in all of them there exist definite limits as to the duration of circulatory arrest that will permit subsequent survival. To overcome this problem, various methods have been employed, including hypothermia, but our experience suggests that the most satisfactory and effective method consists of the use of a temporary shunt to conduct blood around the occluded segment

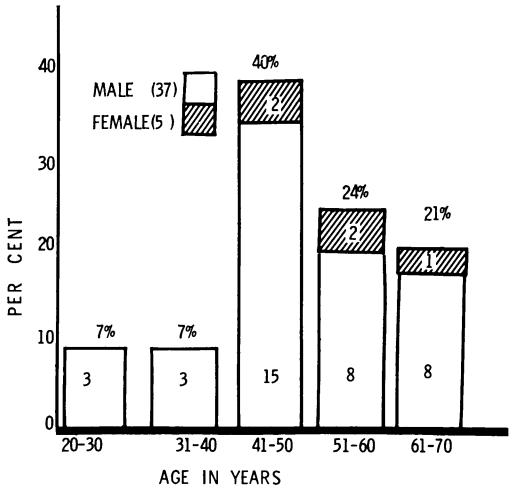

FIG. 1. Age distribution of 42 patients with aneurysm of the thoraco-abdominal aorta.

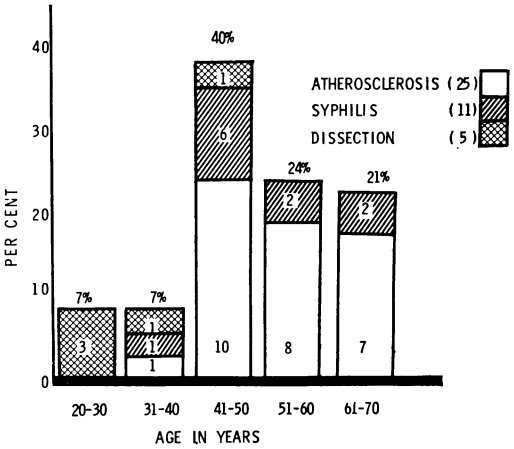

FIG. 2. Etiology of 42 cases of aneurysm of the thoraco-abdominal aorta.

and the performance of this procedure in a manner to reduce the period of circulatory arrest to well within the limits of tolerance.

In our early experience, this was accomplished by the use of a temporary bypass graft made of compressed polyvinyl sponge (Ivalon), attached by end-to-side anastomosis to the descending thoracic aorta proximal to the aneurysm and to the abdominal aorta distal to the aneurysm. This was followed by excision of the aneurysm and replacement with an aortic homograft, with stepwise restoration of continuity and circulation through the shunt and the graft replacement to the renal arteries, superior mesenteric and celiac arteries, respectively. Following completion of all of these anastomoses, including the final anastomosis of the proximal end of the aortic homograft to the distal end of the descending thoracic aorta, the temporary shunt was removed.

With the development of a satisfactory synthetic arterial replacement made of knitted Dacron, it became possible to modify this procedure in a manner designed to provide much greater flexibility in the operative approach and to achieve the desired objectives most expeditiously and effectively. This has been achieved through the ability to utilize the Dacron

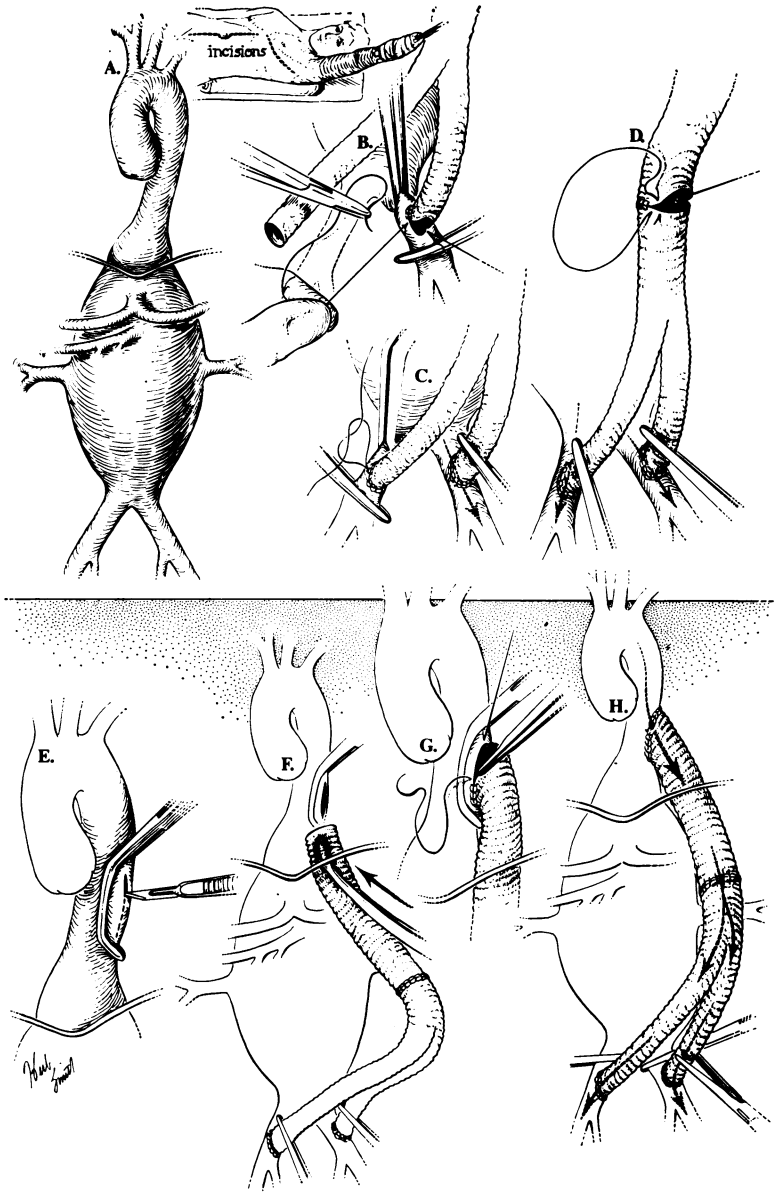

FIG. 3 A-H. Drawing of steps of operative technic in resection and graft replacement of aneurysm of the thoraco-abdominal aorta (see text).

tube, first as a temporary bypass graft to maintain circulation during performance of the procedure and subsequently as the permanent vascular replacement for the excised aortic segment. On the basis of these considerations and the experiences gained in the application of these principles, the following surgical procedure—with certain modifications—has evolved as currently the most satisfactory method of resection and graft replacement for these aneurysms.

In order to obtain adequate exposure, which is essential for such extensive aneurysms involving both body cavities, a left thoraco-abdominal approach was employed in our early experience. It subsequently was found that this could be done in the majority of cases by means of a separate midline abdominal incision and a left

anterolateral thoracotomy incision—which has the advantage of conserving time and reducing surgical trauma. The patient is placed in the supine position, with the left side of the chest slightly elevated and the left arm suspended from an overhead support (Fig. 3A). The peritoneal cavity is entered, first through a long midline incision, and, after adequate exploration to determine more precisely the extent and nature of the aneurysm, the abdominal aorta below the aneurysm is exposed. If the aneurysm extends to the bifurcation, the common iliac arteries are exposed to permit the attachment by end-to-side anastomosis of the limbs of a bifurcation Dacron graft (Fig. 3B). In cases in which there is an uninvolved segment of the abdominal aorta below the aneurysm, a tubular Dacron graft is attached to this segment of abdominal aorta by end-to-side anastomosis. Following completion of these anastomoses, distal flow is re-established by placing vascular clamps on the graft just proximal to the anastomoses (Fig. 3C). In cases in which a bifurcation graft is employed, a tubular Dacron graft of comparable size is attached by end-to-end anastomosis to provide sufficient length to extend to the thoracic cavity (Fig. 3D).

The left pleural cavity is then entered through an anterolateral incision in the sixth or seventh interspace, and the descending thoracic aorta proximal to the upper extent of the aneurysm is exposed. The proximal end of the Dacron graft in the abdomen is passed up through the left retroperitoneal gutter and through an opening made in the diaphragm near the aortic hiatus into the left pleural cavity; then the graft is attached by end-to-side anastomosis to the descending thoracic aorta, using a partial occluding clamp for this purpose (Fig. 3G). Following completion of this anastomosis, the vascular clamps are removed from the distal limbs of the graft and applied to the common iliac arteries proximal to the attachment of the graft; and the partial excluding clamp on the descending thoracic aorta is removed, thus establishing flow through the graft from the thoracic aorta proximal to the aneurysm to the common iliac arteries distal to the aneurysm (Fig. 3H). The celiac, superior mesenteric and renal arteries continue to receive blood flow through the aneurysm.

Knitted Dacron tubes of 8-mm. size are attached to the main Dacron thoraco-abdominal aortic graft by means of an end-to-side anastomosis, using a partial excluding clamp applied at appropriate sites for the renal arteries (Fig. 3I). The left renal artery then is divided between occluding clamps just distal to its origin from the aneurysm and attached by end-to-end anastomosis to its appropriate Dacron tube (Fig. 3K). After completion of this anastomosis, the occluding clamps on the left renal artery and the Dacron tube are removed, permitting restoration of blood flow into the left kidney. In a similar manner, the Dacron graft is attached to the right renal artery (Fig. 3L). While circulation is provided to both renal arteries through the Dacron grafts and to the celiac and superior mesenteric arteries through the aneurysm, a similar technic is employed to attach an 8- or 10-mm. Dacron tube to the thoraco-abdominal Dacron graft, following which it is attached by end-to-end anastomosis to the distal cut end of the superior mesenteric artery (Fig. 3M). An occluding clamp now is applied to the descending thoracic aorta just distal to the anastomosis of the Dacron graft, thus arresting circulation into the aneurysm. The celiac axis is then divided distal to the aneurysm and attached to a previously prepared side arm from the thoraco-abdominal aortic graft (Fig. 3N). Suture closure of the proximal cut end of the descending thoracic aorta distal to the proximal attachment of the graft, and the distal cut ends of the common iliac arteries proximal to the distal attachment of the graft, permits removal of these respective clamps (Fig. 3O).

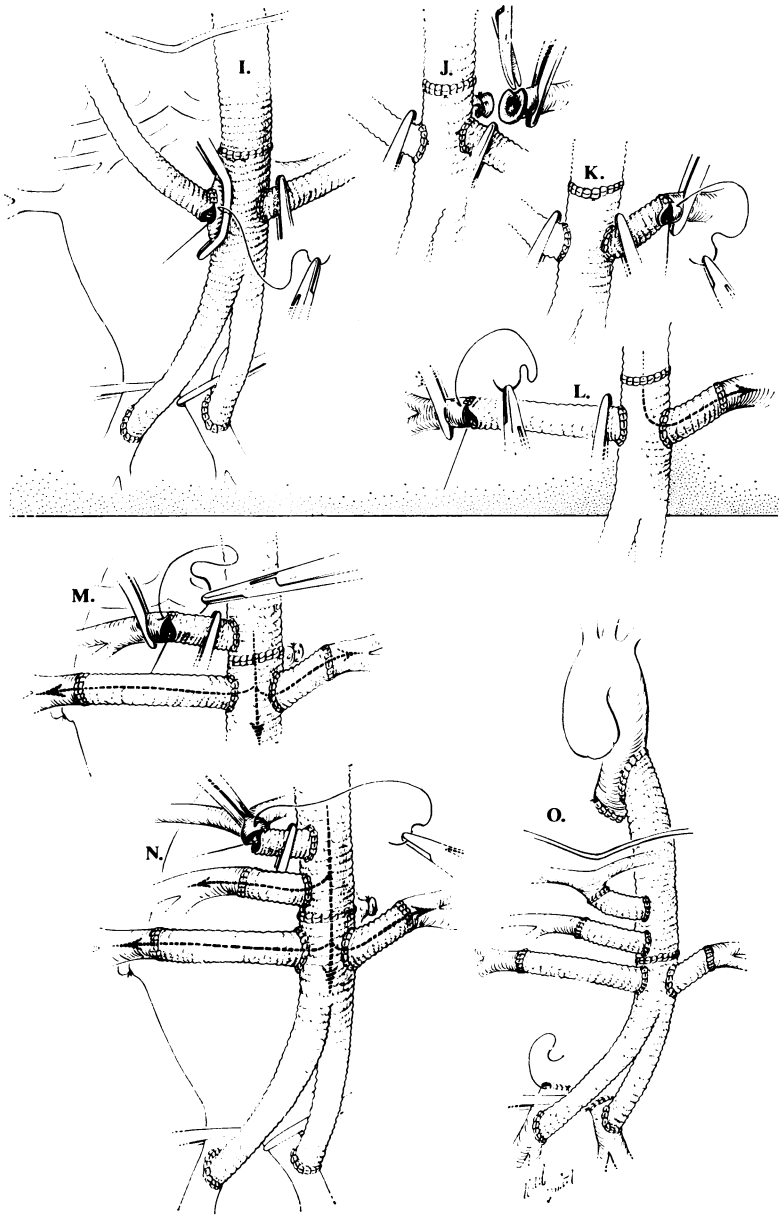

FIG. 3 I-O. Operative technic, continued.

With normal circulation being provided through the graft to all of the abdominal viscera and to the lower extremities, but arrested in the aneurysm, attention may be directed toward its extirpation. In some instances, the aneurysm may be excised by removing a portion at a time as the grafts are attached to the visceral arteries. In other instances, the aneurysm may be entered, evacuated and then treated by endoaneurysmorrhaphy. The posterior attachment of the aneurysm along the vertebral bodies often is quite dense, under which circumstances its outer wall is left attached and bleeding from ends of lumbar vessels controlled by oversewing with figure-of-eight sutures. If generalized oozing from the bed of the aneurysm is particularly

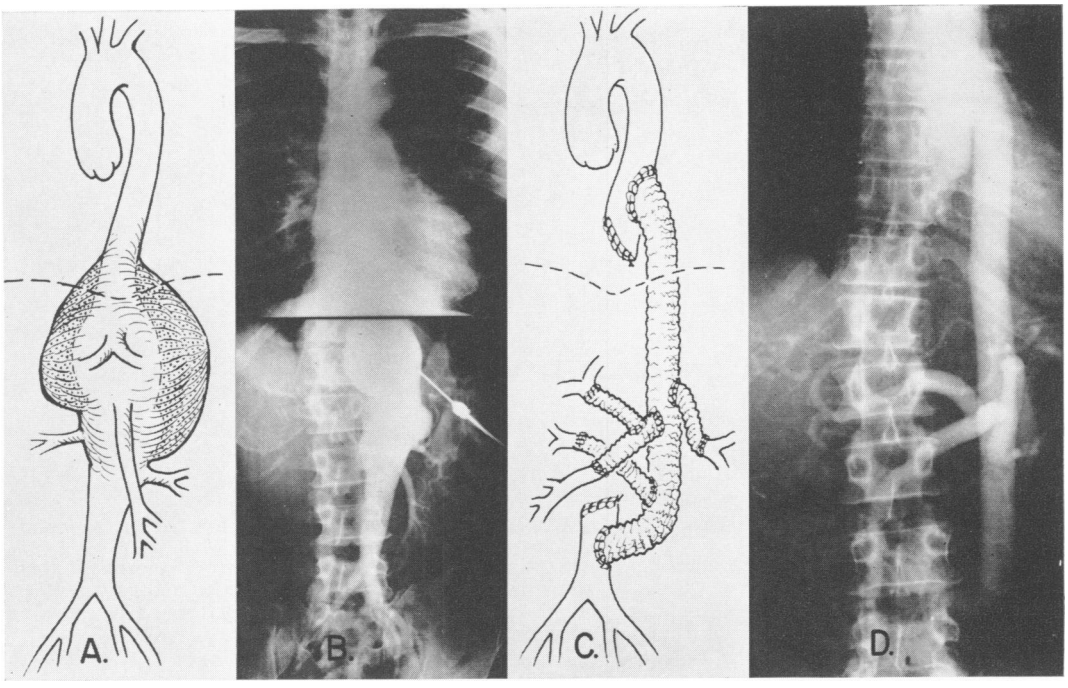

FIG. 4. A) Drawing; B) aortogram before opertion, demonstrating luetic thoraco-abdominal aortic aneurysm in a 49-year-old male; C) drawing showing method of resection and graft replacement; and D) aortogram after operation, demonstrating satisfactory function of thoraco-abdominal and visceral artery grafts. Patient remains well, 5 years after operation.

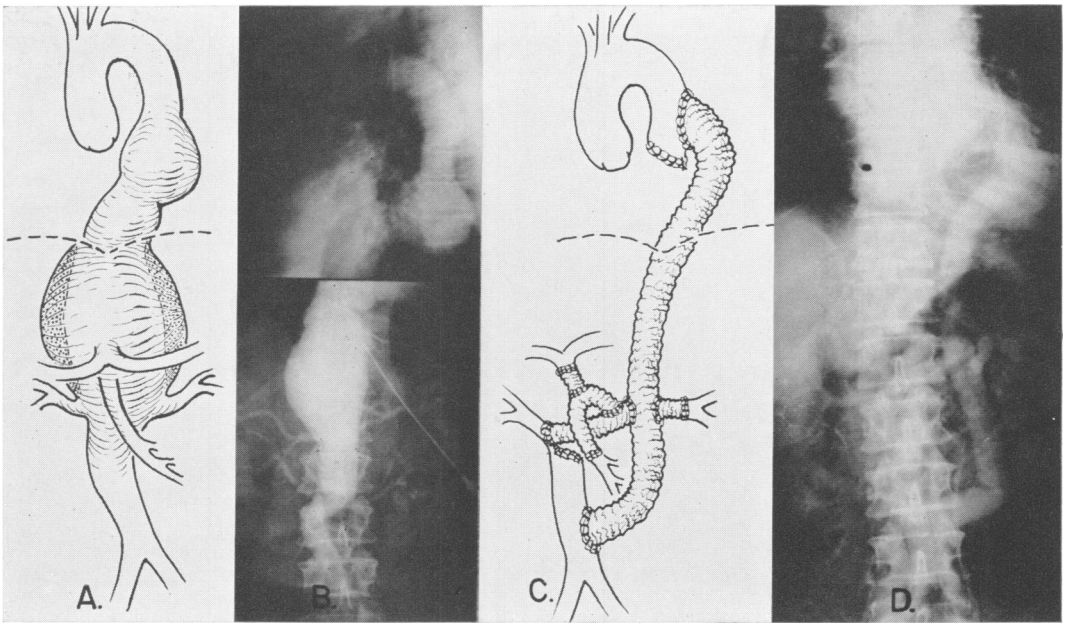

FIG. 5. A) Drawing; B) aortogram before operation, demonstrating arteriosclerotic thoraco-abdominal aortic aneurysm in a 54-year-old male, C) drawing illustrating method of resection and graft replacement; and D) aortogram after operation, showing satisfactory function of graft replacements. Patient remains well, 5 years after operation.

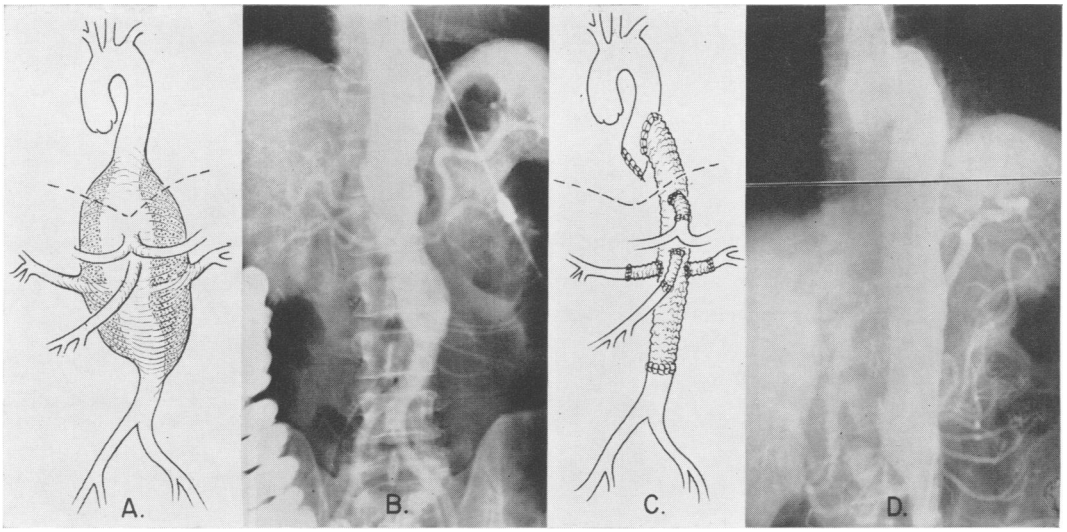

FIG. 6. A) Drawing; B) aortogram before operation, demonstrating arteriosclerotic thoraco-abdominal aortic aneurysm in a 42-year-old male; C) drawing illustrating method of resection and graft replacement with distal anastomosis, end-to-end, to abdominal aorta; and D) aortogram performed 7 years after operation, demonstrating satisfactory function of visceral replacement grafts.

brisk, this is controlled by oversewing and approximating the edges of the residual outer wall of the aneurysm behind the graft. When this is done, other viable tissue —such as omentum—can be used to surround the graft.

Numerous variations in these procedures are possible, such as distal attachment of

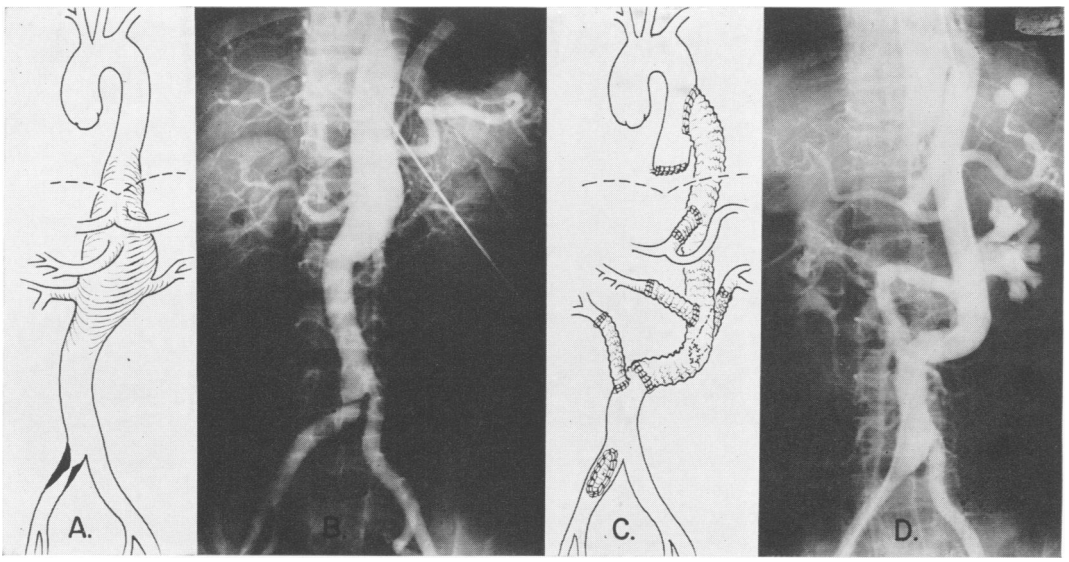

FIG. 7. A) Drawing; B) aortogram before operation, demonstrating dissecting thoraco-abdominal aneurysm in a 20-year-old male; C) drawing illustrating variation in technique of resection and graft replacement, with endarterectomy and patch graft angioplasty of right common iliac artery; and D) aortogram after operation, demonstrating satisfactory function of thoraco-abdominal and visceral artery grafts.

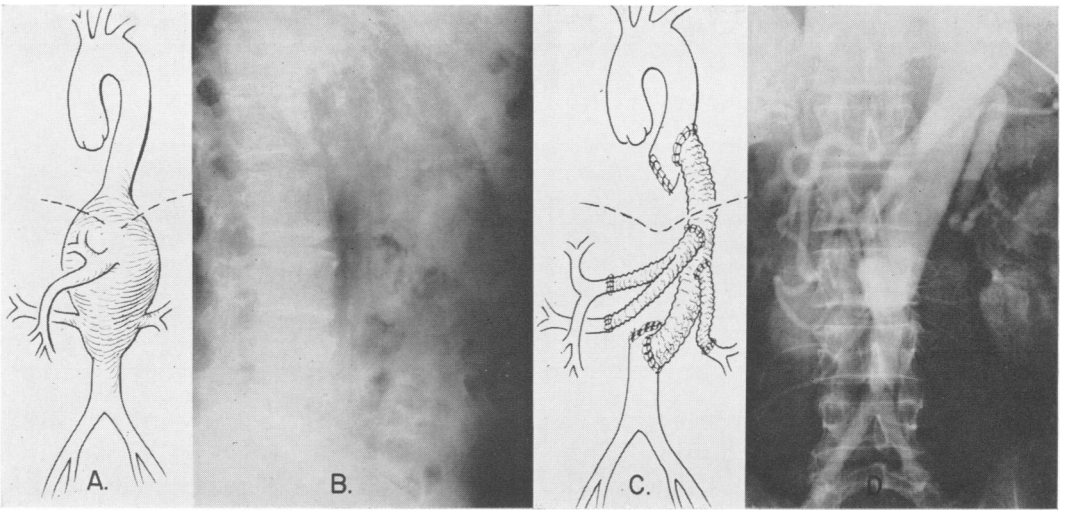

FIG. 8. A) Drawing; B) lateral roentgenogram of abdomen, showing large luetic thoraco-abdominal aneurysm in a 51-year-old male; C) drawing illustrating variations in technic, employing bifurcation graft for visceral artery replacement; and D) aortogram demonstrating satisfactory function of graft replacements. Patient remains well, 7 years after operation.

the graft to the lower abdominal aorta—rather than to the common iliac arteries—when the aneurysm does not involve the aortic bifurcation (Fig. 4–7). Under certain circumstances, a bifurcation graft may be attached to the main graft to provide sidearms to two major abdominal arteries rather than using a sidearm for each artery (Fig. 8). In some instances a surrounding cuff of the arterial wall, at the ostia of the visceral arteries arising from the aneurysm, may be provided to facilitate a larger and better anastomosis to the graft. Regardless of the specific technic employed, however, every effort should be made toward keeping periods of temporary circulatory arrest to the abdominal viscera at an absolute minimum. That this can be done by the principles of the technical procedure described above is well demonstrated by the fact that the average period of circulatory arrest to the abdominal viscera ranged from about 10 to 30 minutes, which is well within the limits of tolerance of ischemia to these organs. Also, blood replacement should almost be complete prior to wound closure. Otherwise, areas which appear dry at operation due to hypotension may result in postoperative hemorrhage once blood pressure returns to normal as blood replacement catches up with loss. Only by careful attention to details such as these, rather than dependence upon ancillary maneuvers such as hypothermia and use of mannitol, has successful performance of these rather complicated procedures been made possible.

Results

Among the 42 patients in this series, 11 (26%) died within 1 month following operation. Analysis of these early deaths indicates the significance of certain factors upon the risk of operation—including, particularly, age and associated cardiovascular disease. Thus, among the 19 patients in the sixth and seventh decades of life there were 7 deaths, an operative mortality of 37 per cent; whereas, among the 23 patients in the younger age categories, there were only four deaths, an operative mortality of 17 per cent.

The significance of associated cardiovascular disease is well illustrated by the fact that among the 16 patients with heart disease, with or without associated hyper-

TABLE 1. *Thoraco-abdominal Aneurysm: Associated Disease*

	No. Patients	Operative Deaths	
		No.	%
Heart disease	3	1	33
Heart disease + hypertension	8 } 16	3	38 } 44%
Heart disease + hypertension + renal disease	5	3	60
Hypertension	6	1	17
Liver disease	1	1	100
None	19	2	11
Total	42	11	26

tension and renal disease, there were seven deaths, an operative mortality of 44 per cent; whereas, among the 19 patients with no associated disease, there was an operative mortality of only 11 per cent (Table 1). Significant hypertension without associated heart disease was present in 6 patients, and there was one operative death in this group. It is of interest to note that in five of these patients there was severe renal artery stenosis which was corrected by the operation, resulting in relief of hypertension (Fig. 9).

Follow-up studies are currently available in all of the 31 patients who survived operation. There were four late deaths among these patients. A myocardial infarction, occurring 1 year after operation, accounted for one death. One patient died 4 years after operation of a ruptured aneurysm of the descending thoracic aorta which had developed in the segment above the previous resection. The other two patients succumbed to massive pulmonary hemorrhage from aortopulmonary fistula, 2 and 7 years, respectively, after operation.

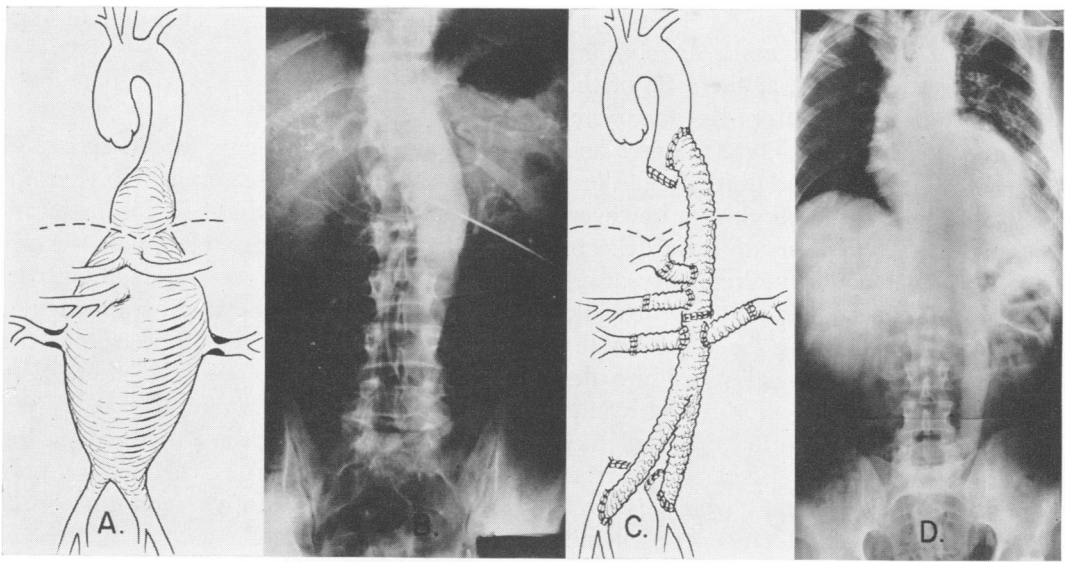

FIG. 9. A) Drawing; B) aortogram, before operation, showing large thoraco-abdominal aortic aneurysm with associated renal artery stenosis in a 38-year-old male; C) drawing illustrating technic of resection and graft replacement with correction of renal artery stenosis; and D) aortogram after operation, demonstrating satisfactory function of graft replacements. Patient remains well and normotensive, 2 years after operation.

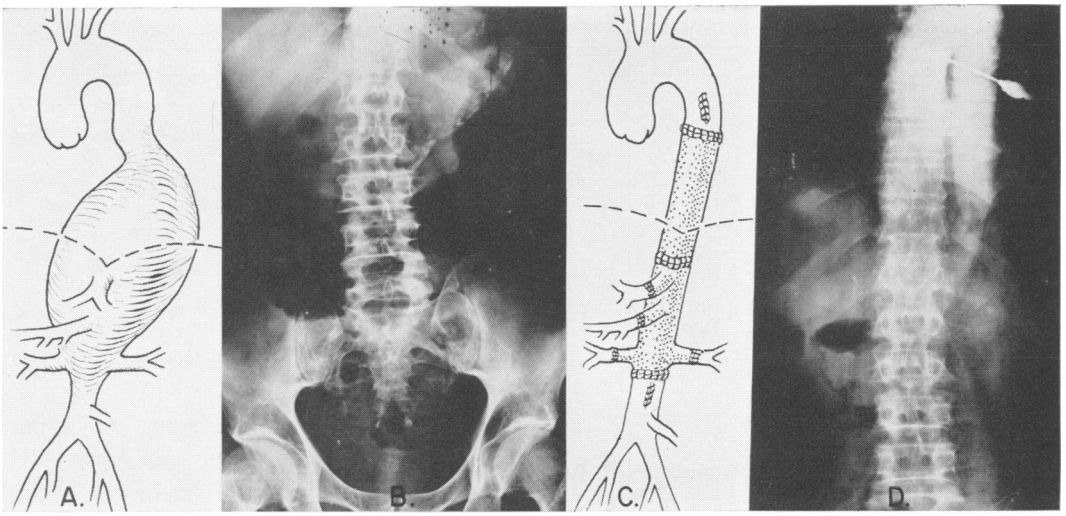

FIG. 10. A) Drawing; B) abdominal roentgenogram showing large arteriosclerotic thoraco-abdominal aortic aneurysm in a 65-year-old male; C) drawing illustrating technic of resection and homograft replacement, employing temporary thoraco-abdominal bypass; and D) aortogram after operation, demonstrating satisfactory function of graft replacements. Patient remains well, almost 10 years since operation.

The remaining 27 patients are alive and are leading normal lives. The longest follow-up period is almost 10 years. This patient, who has been examined regularly and upon whom an aortogram was recently performed, remains in excellent condition (Fig. 10). It would appear from this analysis that, once the patient recovers from operation, his chances of long-term survival and a relatively normal life expectancy are excellent (Fig. 11).

In our previous report on this subject, data concerned with preoperative and postoperative serial studies of renal, hepatic and gastrointestinal function were presented, showing a characteristic pattern of early depression of function immediately following operation, with progressive return to normal during the subsequent 10 days to 2 weeks. Further studies along these lines have confirmed these observations but have also demonstrated that—with refinements in the operative procedure, designed to minimize the period of circulatory arrest to these organs—this pattern of temporary depression of function is much less pronounced. Indeed, in some cases there is little or no significant change from the characteristic pattern of any major abdominal operative procedure. Moreover, follow-up functional studies along these lines, for periods extending up to 7 years after operation, reveal sustained normal function (Table 2, 3).

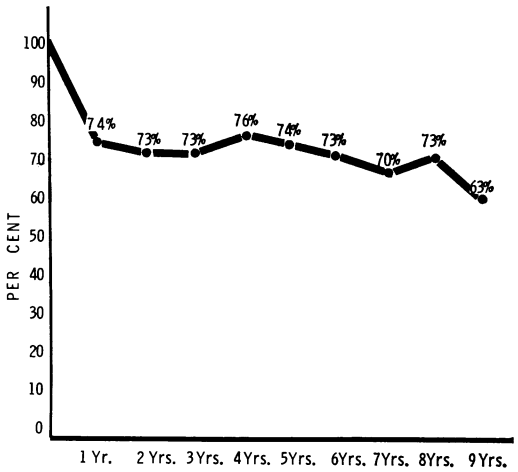

FIG. 11. Graph showing per cent survival rate in 42 patients with thoraco-abdominal aortic aneurysm treated by operation.

TABLE 2. *Thoraco-abdominal Aneurysm: Function Studies*

	Renal	Liver	Gastrointestinal
Preop.	BUN: 16 Urine: normal PSP: 30% 15 min. IVP: normal	CF: 1+ TP: 7.0 PRO: 80%	Normal function
Postop. (7 Yr.)	BUN: 15 Urine: normal PSP: 25% 15 min. IVP: normal	CF: 1+ TP: 5.5 PRO: 60%	Normal function

Summary

An analysis of the experience with the surgical treatment of 42 patients with aneurysm of the thoraco-abdominal aorta is presented. Emphasis is placed on technical considerations; follow-up studies of renal, hepatic and gastrointestinal function; and long-term results. Males predominated by a ratio of eight to one, with ages ranging from 20 to 68 years. The highest incidences occurred in the fifth, sixth and seventh decades of life. Arteriosclerosis was the etiology in 62 per cent, syphilis in 26 per cent and dissecting aneurysm in the remaining younger group of patients.

An operative technic—allowing minimal periods of temporary circulatory arrest to the abdominal viscera during resection and graft replacement—is described. A Dacron bypass graft is inserted from the descending thoracic aorta proximal to the aneurysm to the distal abdominal aorta or common iliac arteries below the aneurysm. The technic employs partial excluding clamps and end-to-side anastomoses. Dacron tube grafts are sutured end to side to the functioning thoraco-abdominal graft for replacement of both renal, superior mesenteric and celiac arteries. Each visceral artery is detached from the aneurysm and anastomosed to the appropriate Dacron tube graft, thus keeping the ischemic period to approximately 10 to 15 minutes for each organ. The aneurysm is removed after completion of visceral revascularization or in steplike fashion after each anastomosis. The descending thoracic aorta and abdominal aorta are oversewn, converting the thoraco-abdominal bypass with functioning visceral arteries into a permanent graft replacement.

TABLE 3. *Thoraco-abdominal Aneurysm: Function Studies*

	Renal	Liver	Gastro-intestinal
Preop.	BUN: 14 IVP: normal Urea clearance normal	CF: neg. Bil. 0.7 TT: 2.0 TP: 6.5 Alb. 4.5	Normal function
Postop. (7 Yr.)	BUN: 15 IVP: normal Urea clearance normal	CF: neg. Bil. 0.8 TT: 3.0 TP: 7.2 Alb. 4.5	Normal function

Among the 42 patients in this series, 11 (26%) died within 1 month. Factors such as age and associated disease contributed to the initial mortality. There were four late deaths among the surviving patients; the remaining 27 patients are alive, with the longest follow-up period almost 10 years. Studies of renal, hepatic and gastrointestinal function—up to 7 years after operation—reveal sustained normal function.

Reference

1. DeBakey, M. E., O. Creech, Jr. and G. C. Morris, Jr.: Aneurysm of Thoraco-abdominal Aorta Involving the Celiac, Superior Mesenteric, and Renal Arteries. Report of Four Cases Treated by Resection and Homograft Replacement. Ann. Surg., **144**:549, 1956.

Discussion

Dr. John Earle Connolly (Palo Alto, Calif.): I think that this is the most difficult vascular procedure next to aortic arch lesions. My personal experience only numbers two cases, but I have seen other patients not operated upon, so while this lesion is unusual I do not think it is rare.

One technical point that I learned in one case was the preservation of an island of tissue in the anterior aorta containing both the superior mesenteric artery and the celiac artery, and by taking a window out of the graft—the Dacron graft—and sewing this normal island in, we eliminated the separate anastomoses of the celiac and superior mesenteric vessels which shortened the time of the operation. I do not remember where I learned this modification—probably from one of Dr. DeBakey's articles.

I would like to show a follow up of a case of a thoraco-abdominal aneurysm that we think was the first successful operation. The patient was operated upon in 1954 by Dr. Sam Etheredge of Oakland, California, and reported in the *Journal of Surgery* in 1955. I had occasion to reexamine this patient a few weeks ago—it is now 11 years after the operation (slide) and this is the aortogram we obtained last week.

A homograft was used. It extended from where you see the upper arrow, which is at the diaphragmatic level, here, down to this area just below the renal arteries. As you can see there is very little evidence of the suture line; you can see the hepatic artery here—this is the celiac axis take-off and this is the superior mesenteric artery where it was anastomosed to the homograft.

This patient has continued to work as a laborer, and I think it substantiates the contention that Dr. DeBakey has made that these side arm anastomoses do stay open.

Although this is a homograft and there is some calcium in it, there is not a great deal of calcium. Both Dr. Etheredge and I would agree that the knitted Dacron graft is the prosthesis of choice now. Dr. Etheredge actually used a polyethylene shunt from just above the diaphragm down to just above the bifurcation of the aorta, and he tells me that he took the polyethylene graft home in the evening and heated it on the stove in the kitchen to make flanges on it so it would stay in the aorta when inserted in the middle of a purse string. We do not currently employ such a shunt but rather insert the Dacron graft in the manner described today.

Finally, I would like to pay tribute to Dr. DeBakey's enormous contributions and stimulus to all who are interested in aortic surgery.

Dr. Charles G. Rob (Rochester, N. Y.): We have had experience of approximately 20 cases, and I want to comment on one point. In three of our patients we found at the time of operation that both the celiac artery and the superior mesenteric artery were completely occluded in the wall of the aneurysm.

In one of these we were able to obtain a reconstruction of these vessels by going peripherally. In the other two we were not.

(Slide) I would like to show you a patient which we operated upon 10 years ago. This is the thoraco-abdominal aneurysm, and I would like you to note that there are no branches at the level where the celiac and superior mesenteric arteries should be.

(Slide) This is the operative field. You can see the aneurysm has been removed; here is the distal thoracic aorta; here is the abdominal aorta; the two renal arteries are clamped. No latent celiac or superior mesenteric arteries have been demonstrated. We reported this case at the time and the next slide shows the postoperative arteriogram of the prosthesis in position, and the next slide, the large inferior mesenteric artery which is a collateral to the whole alimentary tract.

Immediately after this operation we were naturally very worried because we thought that the intestine would slough. Well, he is alive today, a little over 10 years later, and I would like to mention that occasionally, in these abdominal aneurysms, three of 20 in our experience, the celiac and mesenteric arteries have been thrombosed in the wall of the thoraco-abdominal aneurysm.

If you are unable to reconstruct these two important arteries, it seems to be all right provided that they were previously occluded.