

# Resection of the Superior Mesenteric Vein and Replacement with a Venous Autograft During Pancreaticoduodenectomy: \*

## Case Report

BERNARD SIGEL,\*\* M.D., JAMES G. BASSETT, M.D.,  
DONALD R. COOPER, M.D., MARVIN R. DUNN, M.D.

*From the Departments of Surgery and Pathology, Woman's Medical College of Pennsylvania, Philadelphia, Pa.*

RESULTS of treating carcinoma of the pancreas by pancreaticoduodenectomy have been poor. While an underlying pessimism regarding this disease prevails, some effort has been made to improve results by extending the operative procedure introduced by Whipple. Resection of the superior mesenteric vein *en bloc* with a carcinoma of the head of the pancreas has been suggested and used as a means of extending resectability. The problem with such vein resection is how to re-establish splanchnic circulation, particularly when a long segment of vein has been removed. A number of measures have been tried in order to solve this problem. Acute ligation of the portal vein and *en bloc* resection was reported by Parsons<sup>12</sup> and Person (cited by Child *et al.*<sup>2</sup>) but in these instances the portal vein was already partially occluded by tumor. Child and associates<sup>3</sup> showed that the normal portal vein in man may be occluded acutely and permanently. However, because the portal pressure immediately after ligation is high, dissection at such time around the pancreaticoduodenal

region is associated with excessive hemorrhage. This increase in portal pressure, however, is transient. Consequently, Child and associates<sup>2</sup> performed an initial ligation of the portal vein and resected the vein with the tumor at a second operation 7 or 10 days later. Moore *et al.*<sup>10</sup> reported a patient in whom resection of a segment of the superior mesenteric vein was followed by primary anastomosis. He later mentioned a second patient in whom this was done. In a third patient in whom a lengthy segment of vein was involved by tumor, reanastomosis was impossible and a superior mesenteric vein to vena cava shunt was performed.<sup>11</sup>

The first superior mesenteric vein-vena cava anastomosis following vein resection *en bloc* with a carcinoma of the head of the pancreas was reported by McDermott.<sup>8</sup> While the immediate results of his two patients were gratifying, ammonia intoxication later developed leading to death of one of these patients 20 months postoperatively.<sup>9</sup> Hubbard<sup>6</sup> reported a similar experience with two patients. He concluded that superior mesenteric vein-vena cava shunting in the presence of a normal liver is not a satisfactory procedure because it leads to progressive hepatic insufficiency. This is associated with episodic stupor and coma,

\* Read before the Philadelphia Academy of Surgery, November 2, 1964.

\*\* Recipient of PHS Career Development Award, AM-K3-16,679.

hypoalbuminemia and extensive edema and, ultimately, death of the patient.

Reports of efforts to reconstruct the superior mesenteric-portal vein axis by grafting have been scarce, probably because of the frequent failures associated with grafts in the venous system and the need for a vessel larger than the saphenous vein which usually is used for autologous grafting. Daniel<sup>4</sup> had some success with inserting autologous iliac vein grafts in the superior mesenteric-portal vein axis of dogs. Japanese workers have used alcohol-preserved vein homografts following pancreaticoduodenal resection with removal of portions of the superior mesenteric and portal veins. Kikuchi<sup>7</sup> reported a patient in whom a homologous vein graft and polyethylene splint was used to bridge the defect. This patient died of shock 27 hours postoperatively. At autopsy, the common hepatic artery was found to be ligated and divided. The graft was patent. Asada *et al.*<sup>1</sup> reported two patients in whom survival was more prolonged. These patients died 18 and 124 days after operation of myocardial insufficiency and recurrent tumor, respectively. These grafts were patent at autopsy.

In December 1962 we encountered a situation which required reconstruction of the superior mesenteric vein. During a pancreaticoduodenectomy for carcinoma of the head of the pancreas, the superior mesenteric vein immediately below the pancreas was accidentally transected. Primary reanastomosis would have required tedious dissection of the vein from the tumor-bearing pancreas. It was believed that this procedure would be time consuming, would traumatize a long segment of vein (thus predisposing to thrombosis) and probably would leave tumor tissue on the vein wall. The choice of superior mesenteric vein to vena cava shunt was rejected because of the known ill-effects of performing such anastomosis in the presence of a normal liver and absence of portal hypertension.

Consequently, an autologous vein graft taken from the superficial femoral vein was inserted between the superior mesenteric vein just cephalad to the entry of the mid-colic veins and the origin of the portal vein. This report describes this use of an autologous vein graft to bridge a defect in the superior mesenteric vein and illustrates that this may be a feasible means of dealing with the vein defect following resection in tumor surgery.

### Case Report

A 58-year-old white woman was admitted to the Woman's Medical College Hospital on 12-12-62. Her chief complaint was jaundice and clay-colored stools. The patient dated the onset of her present illness to 1 month prior to admission. At that time she began to notice that her stools were becoming pale and her urine was at times dark. A dull right upper quadrant pain developed which radiated to her back. The patient denied any weight loss. Physical examination revealed an obese female. Mild icterus was present. The left breast had been surgically removed. Examination of the abdomen revealed no palpable organs or masses. The remainder of the examination was negative. The past history was significant in that the patient had undergone a left radical mastectomy for carcinoma of the breast in May 1962 at the same hospital. The pathologic diagnosis of that operative specimen was carcinoma of the breast with metastases to all of eight nodes examined.

*Laboratory Findings.* Hemoglobin was 13.1 Gm./100 ml.; hematocrit 38%; white blood cell count 6,300 with a normal differential; 2-hour post-prandial blood sugar 120 mg./100 ml.; blood urea nitrogen 14 mg./100 ml.; normal urine; prothrombin time 70%; alkaline phosphatase 14.3 units; transaminase SGO 76 units; transaminase SGP 105 units; bleeding time 1½ minutes; platelet count 230,000; and total bilirubin 4.45 mg./100 ml. (direct 2.25 mg.). X-ray examination of the chest was negative. An oral cholecystogram was attempted but did not show the gallbladder.

*Operation.* On 12-14-62 an operation was performed. The preoperative diagnosis was chronic calculous cholecystitis with choledocholithiasis. The peritoneal cavity was entered through a right subcostal incision. No calculi were present in a large distended gallbladder. The common bile duct was approximately 2.5 cm. in diameter. There was a firm mass palpable in the head of the pancreas.

There was no evidence of any tumor extension elsewhere in the abdomen. Palpation along the hepato-duodenal ligament revealed a small lymph node which was taken for biopsy. This proved to be negative for neoplasm. The duodenum was then mobilized and biopsy of paraduodenal tissue was also negative for neoplasm. Our impression was that the patient's primary disease was carcinoma of the head of the pancreas without distant metastases and we decided to perform a pancreaticoduodenectomy. The abdominal incision was enlarged across the midline to facilitate better exposure. Mobilization of the duodenum and pancreas was continued in an attempt to discern whether or not the superior mesenteric and portal veins were free of neoplasm. During this part of the dissection, the superior mesenteric vein was transected. After clamps were applied to the severed ends of the vein, the small intestine exhibited extreme hypermotility and loss of pulsations. The color of the bowel became dusky. A decision to use an autologous vein graft from the superficial femoral vein to bridge the defect in the superior mesenteric vein-portal vein axis was made and a second operating team entered the operation. While one team dissected out the ends of the vessels for the anastomosis, the second team obtained the vein graft from the right thigh. The vein graft measured 10 cm. in length. The graft was interposed, using a continuous silk suture technic, between the superior mesenteric vein immediately cephalad to the entry of the mid-colic vessel and the origin of the portal vein, immediately caudal to the entry of the splenic vein. Vascular clamps were then removed. Normal-color of the bowel returned immediately and the hyperperistalsis abated. Edema of the small intestine and the mesentery was evident at the end of the period of occlusion but this subsided by the time the abdomen was closed. Total occlusion time for the superior mesenteric vein was about 3 hours. The remainder of the operation was uneventful. The specimen was removed and reconstruction of the gastrointestinal tract consisted of an end-to-end pancreaticojejunostomy, end-to-side choledochojejunostomy and an antecolic-gastrojejunostomy (Fig. 1). The patient became moderately hypotensive toward the latter part of the period of superior mesenteric vein occlusion. A total of 10,000 ml. of whole blood was administered during the operation. In the immediate postoperative period, the patient's vital signs were stable. The patient exhibited paralytic ileus for about 2 weeks. During this time only occasional bowel sounds were heard. On the 13th postoperative day the patient began to experience some crampy abdominal pains which were associated with diarrhea. Stools were light brown in color

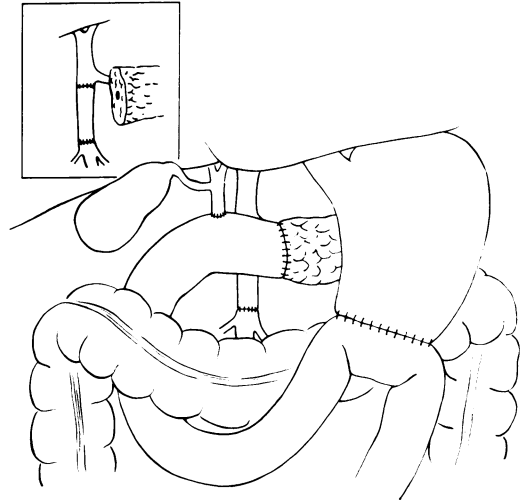


FIG. 1. Schematic representation of the vascular and gastrointestinal reconstruction following autologous vein graft during pancreaticoduodenectomy.

and semi-formed. Thereafter, she continued to improve and was discharged from the hospital on the 36th postoperative day.

*Pathology.* The tumor grossly and microscopically was characteristic of a primary adenocarcinoma of the pancreas. It did not resemble metastatic carcinoma from the breast. The tumor extended to the line of transection of the pancreas. Numerous microscopic foci of tumor were found in the adventitia of the superior mesenteric vein, probably within the lymphatics (Fig. 2, 3).

*Follow Up.* About 2 weeks following discharge, the patient experienced a single episode of melena. She refused hospitalization and no recurrence of bleeding occurred. The patient did well until about 1 year following this operation. In December 1963 an elevated blood sugar concentration was noted and she was placed on oral hypoglycemic medication. She developed anorexia, weight loss and diarrhea. The patient was readmitted to the hospital in March and May 1964. Her condition had markedly deteriorated and there was evidence of generalized metastases (divergence of left eye, left pleural effusion, subcutaneous nodules and osteolytic bone lesions). She was given continued estrogen therapy with marked subjective (but not objective) improvement of her clinical condition up to the present time (November 1964).

### Discussion

The prolonged ileus encountered in the postoperative course of this patient was

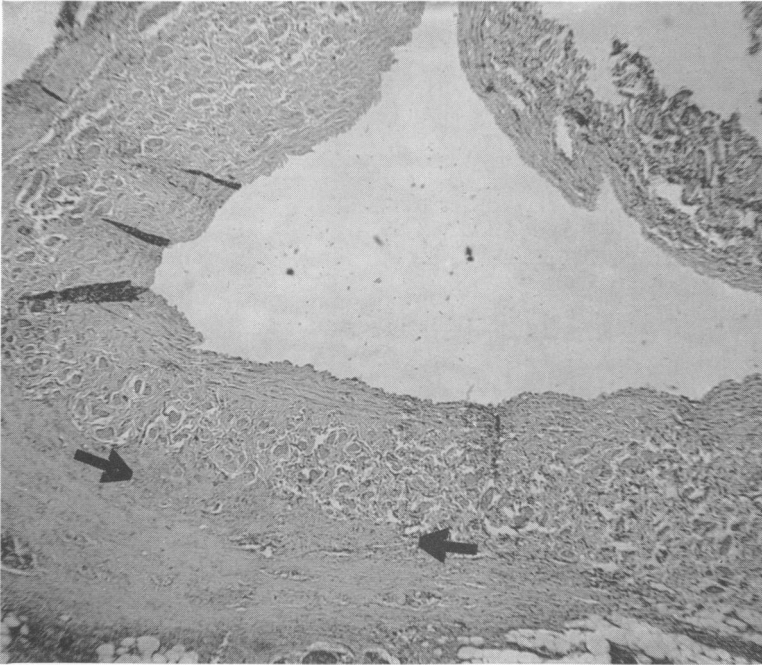

FIG. 2. Histologic section of the superior mesenteric vein showing infiltration of adventitia by carcinoma (between arrows). H & E  $\times 35$ .

probably related to the edema and congestion of the bowel resulting from prolonged occlusion of the superior mesenteric vein.

Transient gross blood in the stool soon after operation was not encountered as in Asada's patients.<sup>1</sup>

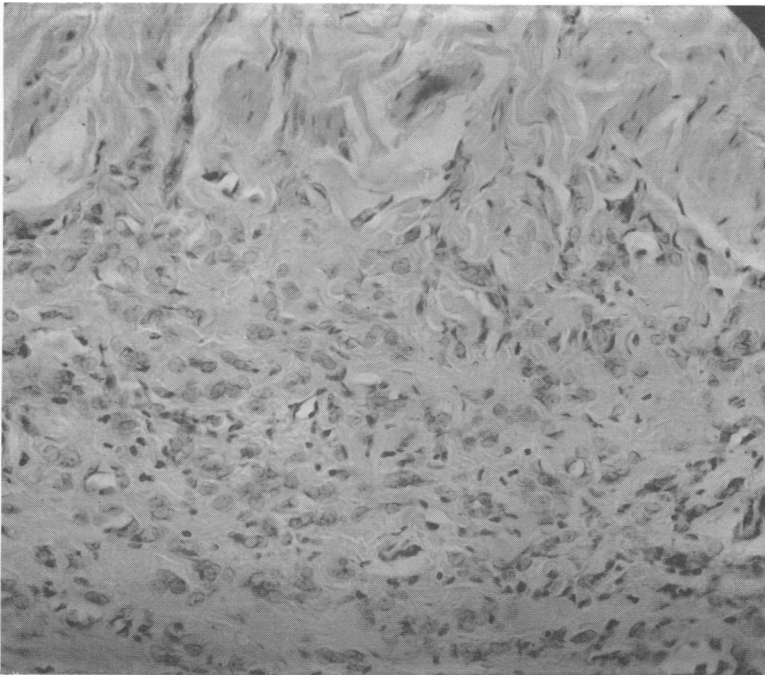


FIG. 3. Higher magnification from the area indicated by arrows in Fig. 2, showing carcinoma cells in the adventitia of the superior mesenteric vein. Muscle bundles of the vein wall are in the upper portion of the section. H & E  $\times 210$ .

It is interesting to speculate whether the graft has remained patent. Thrombosis of the graft may have occurred. However, if this happened, it probably was associated with a concomitant development of collateral channels thereby maintaining viability of the bowel.

A defect in the superior mesenteric-portal vein axis may be bridged by a suitably sized autologous vein graft. Fresh autologous grafts should be superior to homologous preserved tissue or to prostheses, although this question requires investigation. Asada<sup>1</sup> used portal vein homografts because of the need for relatively large caliber grafts. However, the superficial femoral vein appears to be of adequate size to serve as an autologous graft, as suggested by Daniel.<sup>4</sup>

Finally, Evans and Ochsner,<sup>5</sup> after a detailed study of the lymphatics of the pancreas, concluded "that only by extending the scope of the operative attack upon carcinoma of the head of the pancreas can any real hope for cure be entertained." This, they believe, should include resection of the superior mesenteric vein with reanastomosis or grafting. This report has illustrated that autologous vein replacement of the superior mesenteric vein is feasible. It appears, then, that further application and evaluation of this technic in tumor surgery of the pancreaticoduodenal region is warranted.

### Summary

The replacement of a segment of the superior mesenteric-portal vein axis by an autologous vein graft during pancreaticoduodenectomy is described. The rationale for this type of reconstruction is reviewed.

Further trial of pancreaticoduodenectomy with *en bloc* superior mesenteric vein resection for carcinoma of the pancreatic head with autologous vein grafting seems warranted.

### References

1. Asada, S., H. Itaya, K. Nakamura, T. Isohashi and S. Masuoka: Radical Pancreatoduodenectomy and Portal Vein Resection. Report of Two Successful Cases with Transplantation of the Portal Vein. *Arch. Surg.*, **87**:609, 1963.
2. Child, C. G., III, G. R. Holswade, R. D. McClure, Jr., A. L. Gore and E. A. O'Neill: Pancreatoduodenectomy with Resection of the Portal Vein in the Macaca Mulatta Monkey and in Man. *Surg. Gynec. & Obstet.*, **94**:31, 1952.
3. Child, C. G., III, R. F. Milnes, G. R. Holswade and A. L. Gore: Sudden and Complete Occlusion of the Portal Vein in the Macaca Mulatta Monkey. *Ann. Surg.*, **132**:475, 1950.
4. Daniel, W. W.: Bridging Defects in the Canine Portal and Superior Mesenteric Veins with Plastic Tubes and Vascular Grafts. A Preliminary Report. *Cancer*, **5**:1041, 1952.
5. Evans, B. P. and A. Ochsner: The Gross Anatomy of the Lymphatics of the Human Pancreas. *Surgery*, **36**:177, 1954.
6. Hubbard, T. B., Jr.: Carcinoma of the Head of the Pancreas: Resection of the Portal Vein and Portacaval Shunt. *Ann. Surg.*, **147**:935, 1958.
7. Kikuchi, S.: A Clinical and Experimental Study on the Management of Portal Vein during Pancreatoduodenectomy. III. Clinical Cases with Operation on the Portal Vein during Pancreatoduodenectomy. *Tohoku J. Exp. Med.*, **64**:143, 1956.
8. McDermott, W. V., Jr.: A One-Stage Pancreatoduodenectomy with Resection of the Portal Vein for Carcinoma of the Pancreas. *Ann. Surg.*, **136**:1012, 1952.
9. McDermott, W. V., Jr., R. D. Adams and A. G. Riddell: Ammonia Metabolism in Man. *Trans. Amer. Surg. Ass.*, **72**:297, 1954.
10. Moore, G. E., Y. Sako and L. B. Thomas: Radical Pancreatoduodenectomy with Resection and Reanastomosis of the Superior Mesenteric Vein. *Surgery*, **30**:550, 1951.
11. Moore, G. E. and B. Ure: One-Stage Pancreatoduodenectomy with Resection of the Superior Mesenteric Vein. *Surgery*, **35**:734, 1954.
12. Parsons, W. B.: Discussion of Child, C. G., III *et al.* *Ann. Surg.*, **132**:475, 1950.

### Addendum

The patient died of generalized metastasis on October 6, 1965 (34 months after operation). The vein graft was patent. Tumor extended from the retroperitoneum to the site of the vein graft. Microscopically, tumor cells were within the outer wall of the vein graft.