

Salvage of Severed or Near-Severed Arms

CREIGHTON A. HARDIN, M.D.

*From the Department of Surgery, University of Kansas Medical Center,
Kansas City, Kansas*

TRAUMA causing severance or near severance of limbs except for a bridge of skin, may require repair of bone, artery, vein, nerve and skin cover. The principles governing individual repair of specific injuries are not new. The surgical concept of immediate repair of all injured parts is gaining attention and application. Three such cases are reported emphasizing the principles of multiple injury repair.

Case Reports

Case 1. A 61-year-old man was admitted to the Medical Center on May 18, 1951 one hour after a shotgun blast carried away the medial aspect of his left upper arm. Profound shock was treated by transfusion of whole blood. His left forearm was pale, cold and pulseless. The bony substance was intact. There was a complete loss of median nerve function. Under general anesthesia, the wound was explored and debrided 2½ hours after injury. There was loss of 15 × 10 cm. of skin and underlying muscle tissue (Fig. 1), a

10-cm. segment of the brachial artery and a 3-cm. segment of the median nerve. All necrotic muscle and skin was debrided and a median neurorrhaphy was performed after excision of the severed nerve ends. The 10-cm. defect in the brachial artery was repaired with a 44-day-old frozen homograft. A pedicle skin flap was elevated from the chest wall to cover the wound. The bed of the laterally based flap on the chest wall was covered with split thickness skin grafts (Fig. 2). The flap was sutured to the defect in the arm to provide a viable cover of the arterial graft. The chest wall flap was partially sectioned on the 20th postoperative day and completely severed on the 26th day. Defatting and final revision of the graft was carried out on the 31st postoperative day (Fig. 3). Periodic physical examinations have been made up to the present time. Radial and ulnar pulsations are present. There was minimal edema postoperatively. Immediate and prolonged protective splinting and physical therapy were carried out postoperatively. After one year electrical testing re-

Submitted for publication January 11, 1967.

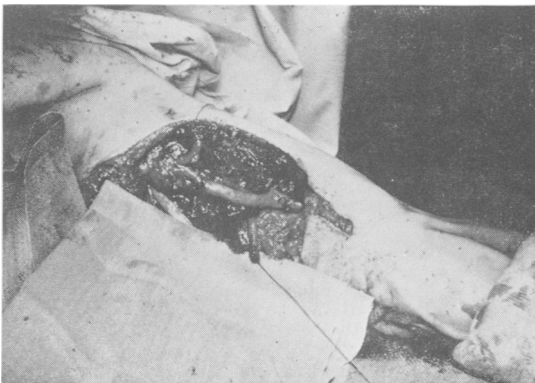


FIG. 1. Debrided wound. Brachial artery defect grafted with homograft. Severed tagged ends of median nerve repaired by neurorrhaphy.

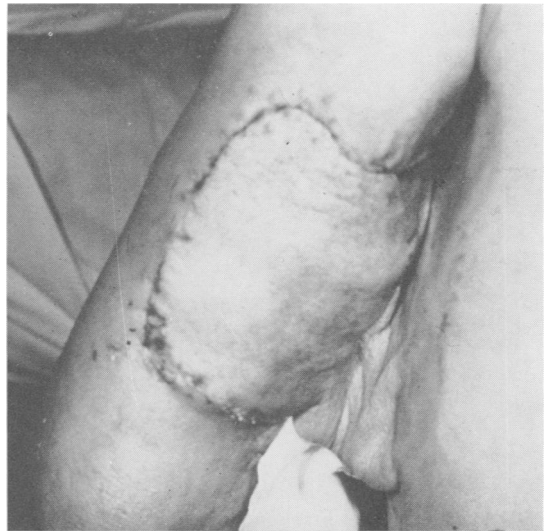

FIG. 2. Laterally based pedicle flap from anterior chest wall covered arterial homograft.

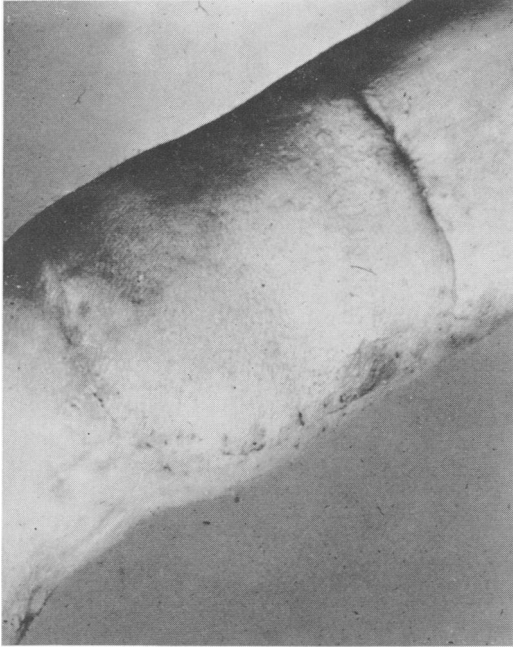

FIG. 3. Defatted and detached pedicle graft 31 days post-injury.

vealed only minimal median nerve regeneration and no improvement thereafter. The patient refused re-exploration of the median nerve. The residual defect is a complete motor and sensory median nerve paralysis 15½ years after injury.

Case 2. A 17-year-old girl was admitted on August 30, 1953. She was brought to the emergency room 15 minutes after an auto accident in which she had been thrown through the windshield. There were severe multiple injuries of her right arm (Fig. 4). A pressure dressing was applied to the axilla to control hemorrhage and intravenous whole blood given to combat shock. The right arm was pulseless. Median and ulnar

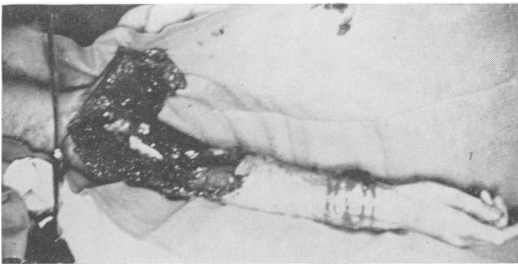


FIG. 4. Compound multiple injury upper and lower arm. Severance complete except for posterior strip of skin.

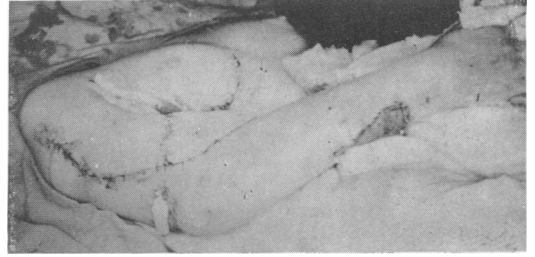


FIG. 5. Skin loss coverage to arm by lateral pedicle flap. Split skin grafts used to provide closure of forearm.

motor and sensory functions were present. There was no radial nerve sensation or motor power. X-rays showed a comminuted compound fracture of the right upper humerus and a compound fracture of the mid-ulna. Under general endotracheal anesthesia the contaminated wound was debrided and washed, removing dirt, paint, metal and glass, and bone fragments. Superficial tissue over the antecubital space and lower arm was lost over a 20×10 cm. area. Exploration of the wound at the humeral fracture site revealed intact median and ulnar nerves, and there was a 5-cm. defect in the radial nerve. The comminuted ends of the proximal and distal humerus were resected and the ends were brought together by a Lane bone plate. The pulseless but intact brachial artery was exposed from the axilla to the antecubital space and found to be in occlusive spasm two inches from the axillary fold. Heparin was injected into the distal brachial artery. An adventitial 1% procaine injection and a stellate block relieved the spasm and restored arterial flow and palpable pulses of the radial and ulnar artery. The ends of the brachial vein were ligated because of intervening loss of substance. The severed biceps brachii muscle was debrided and the muscle bellies were resutured. The distal forearm was explored through the site of the compound fractured ulna. All nerves and blood vessels were intact at this area. The following muscles and tendons were sutured in the arm and wrist: the flexor pollicis longus and brevis, the flexor profundus of the index and middle finger, the flexor carpi radialis, the extensor tendons of the index through the ring fingers, and the pronator quadratus which was reattached. The tissue loss of the arm and antecubital space was replaced by an abdominal pedicle flap, measuring 10×20 cm. The bed of the donor area of the flap was covered with a split thickness skin graft (Fig. 5). Edema of the forearm required a split thickness skin graft for closure of the incisions. The hand was placed on a universal hand splint in the functional position. Whole

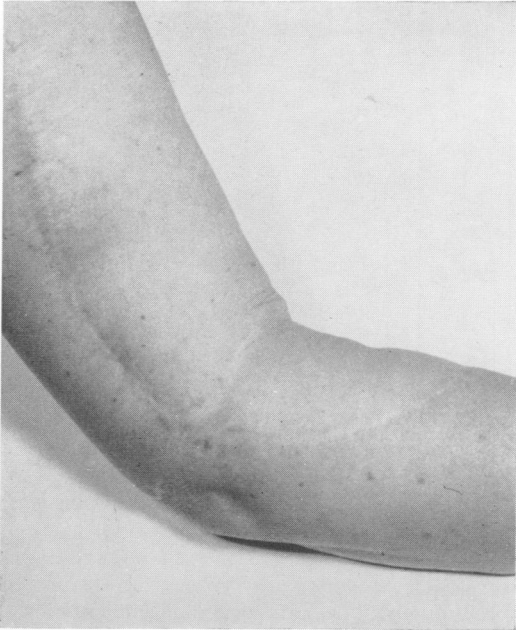

FIG. 6. Appearance of arm 18 months postinjury. Defatting and revision of pedicle flap.

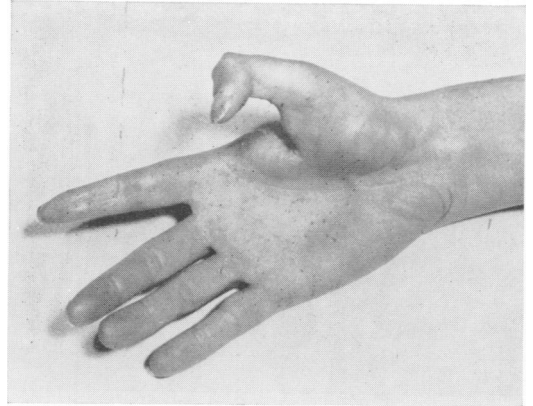


FIG. 7. Distal phalanx of thumb fixed at 45°. Complete extension of fingers.

blood transfusion, antibiotic drugs, tetanus antitoxin and polyvalent gas gangrene serum were given. Two weeks later under local anesthesia the base of the abdominal flap was severed. All wounds healed without infection. The arm was elevated to minimize edema. Six months postoperatively all edema had disappeared in the arm and forearm. One year postoperatively the patient could actively flex and extend the wrist. One and a half years later the pedicle flap was defatted (Fig. 6). A Thompson bone block was placed to provide better opposition of the thumb and index finger and a tendon was transferred to provide active flexion to the middle finger. Two and a half years after injury a bone graft was inserted because of nonunion of the ulna and the scar was revised. Restricted voluntary flexion of the index finger was present. Six years after injury the web between the thumb and index finger was deepened and covered with split graft and an attempt was made to bring the thumb more into a position of function. Examination 13 years and 3 months after injury revealed intact arterial circulation with no edema of the arm or hand. There was complete return of radial nerve function and a full range of flexion and extension of the wrist. The residual defect was primarily in the thumb and index finger. The distal phalanx of the thumb was ankylosed at 45 degrees (Fig. 7). There was complete extension and flexion of the ring, middle and little

finger. There was active flexion of the index finger, the distal interphalangeal joint to 90 degrees, and proximal interphalangeal joint to 10 degrees (Fig. 8). The index finger had been amputated at the metacarpal phalangeal joint. Fine hand movements are performed between the thumb, middle, ring and little fingers.

Case 3. A 32-year-old man was admitted to the Medical Center on March 14, 1963. Six hours prior to admission he had been accidentally shot in the right upper arm with a 12-gauge shotgun containing 00 buckshot (Fig. 9). Emergency local treatment consisted of suture of the brachial artery and vein. Blood pressure was 70/50 mm./Hg. 1,000 cc. of whole blood and 500 cc. of Dextran were given for shock and the patient was admitted

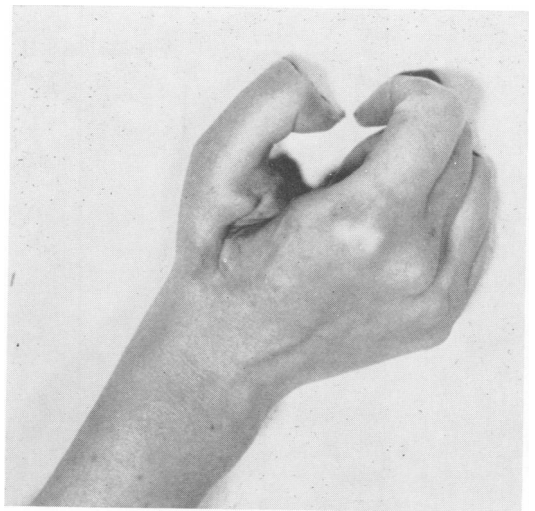

FIG. 8. Restricted flexion of index finger to oppose thumb. Subsequent amputation of index finger.

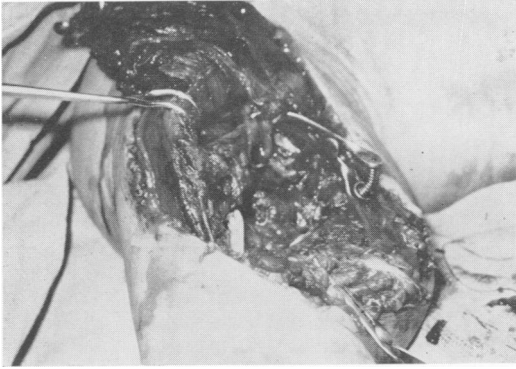


FIG. 9. Compound wound of soft tissue, nerves, vessels, bone. Arm attached posteriorly by bridge of skin.

to the Medical Center. His blood pressure was 120/70, he was cool, his skin was moist and he had tachycardia, and hemoglobin was 67%. Pre-operative examination showed motor and sensory loss of the median and ulnar nerves but intact radial nerve sensation. X-ray of the right humerus showed a comminuted compound fracture of the midshaft of the right humerus (Fig. 10). Chest X-rays showed no damage to intrathoracic structures. Under general endotracheal anesthesia ex-

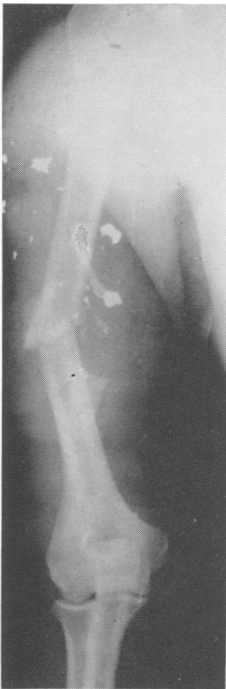

FIG. 10. Compound fracture of humerus with metallic fragments.

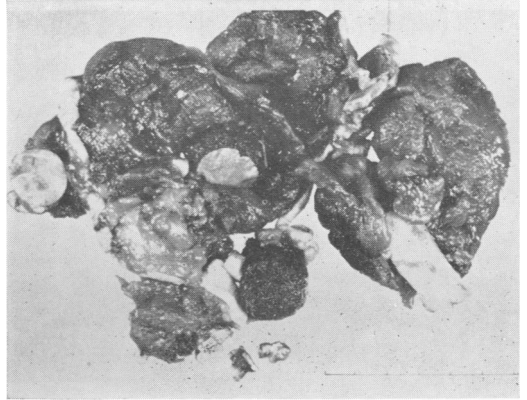

FIG. 11. Debrided tissue, bone and foreign bodies.

ploration of the right upper arm and axilla was performed. There was a superficial and deep tissue loss measuring 13×17 cm. over the upper medial arm with a posterior axillary wound of exit bleeding profusely. The arm was attached posteriorly by a strip of skin. The severed proximal brachial artery was identified, secured with a bulldog clamp and heparin was injected proximally. In a wide debridement of necrotic muscle bone fragments, shot wadding, dirt and metal were removed (Fig. 11). The brachial vein was identified proximally, clamped with a bulldog clamp and heparin was injected. The proximal and distal severed ulnar and median nerves were identified. There was a 10-cm. gap in the substance of the ulnar nerve and an 8-cm. gap in the median nerve. All bony fragments were removed. The humerus was shortened. The distal humerus was sharpened and impacted into the proximal marrow cavity and fixed with two stainless steel screws (Fig. 12). The median nerve was cut across with a razor blade and sutured with interrupted 7-0 black silk. It was necessary to mobilize the ulnar nerve from the medial olecranon groove anteriorly to gain length. The damaged portion of the ulnar nerve was excised and nerve ends were sutured with 7-0 black silk. The proximal and distal severed brachial artery was excised for a distance of 2.5 cm. The distal brachial artery was flushed with normal saline and heparin and allowed to drain through the severed distal brachial vein. End to end suture of the brachial artery was done with interrupted 7-0 black silk suture restoring blood flow through the arm. Bleeding points in the muscles, now bleeding freely, were controlled by clamp and ligature. Venous reconstruction was done with 7-0 black silk suture. A thorough exploration of the axilla was done, all foreign material and dead muscle were removed. Drains were placed through the axilla and poste-

riorly through the wound of exit. The remaining biceps muscle was rotated over the repaired artery and nerve site and sutured with 2-0 chromic suture. A full drum of skin was cut from the right lower quadrant of the abdomen and applied over the arm area of skin loss. Multiple small incisions were made in the skin graft for drainage. The arm was fixed by a Valpeau's bandage over the anterior abdominal wall with 90 degree flexion at the elbow. A universal hand splint was applied to the wrist and fingers to maintain the position of function. Postoperative treatment included a booster dose of tetanus toxoid, penicillin and chloromycetin. There was a good take of the grafted site and the donor area was healing. The postoperative course was afebrile. The patient was discharged 12 days after injury (Fig. 13). Electromyogram 5 months later showed no ulnar or median nerve function. Gradually median nerve function returned. Three years and 8 months postinjury there is solid humeral bony union, good radial and ulnar pulses and no edema of the arm. There is no ulnar sensory or motor nerve function. The radial nerve is intact. Median motor nerve function is present. The patient can actively flex the tips of his fingers to the distal palmar crease and fully extend. He is

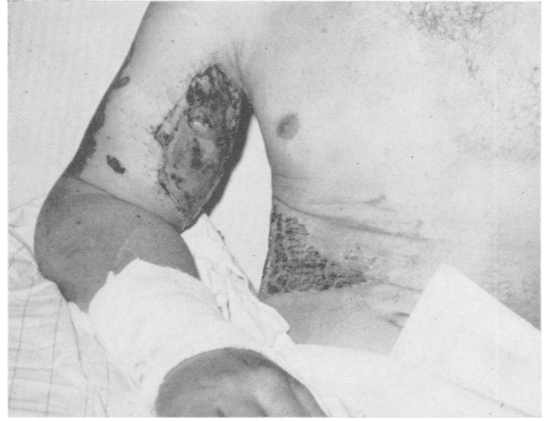

FIG. 13. Shortened arm at 12 days post-injury. Donor and skin grafts healing.

employed as a truck driver. He has residual hand pain relieved by stellate block, but he refused sympathectomy.

Discussion

Bone Injury. Shortening of the fractured bone simplifies repair of nerves and blood vessels. Fixation by plate, impaction, or screw can be selected by conditions at the time of injury. Firm bony fixation is mandatory to prevent disruption of vessel and nerve sutures. Bone shortening makes possible a single suture line of artery, vein and nerves as necessary. Vein grafts to bridge arterial defects should not be needed. The ease of primary nerve suture is evident and should call for a reappraisal of primary versus secondary nerve suture under the conditions presented.

Debridement. All necrotic skin, muscle, bony or foreign fragments must be removed. Damaged ends of arteries should be resected beyond the site of intimal injury to prevent thrombosis. Retrograde based skin flap produced by trauma should be excised and suitable cover provided.

Pedicle and Split Thickness Skin Graft. Wide and proper debridement will usually leave deeper vital structures exposed. Immediately fashioned thoracic pedicle flaps of proper fitted dimensions provide viable cover to sites of vascular repair. Viable cover insures lack of infection and danger

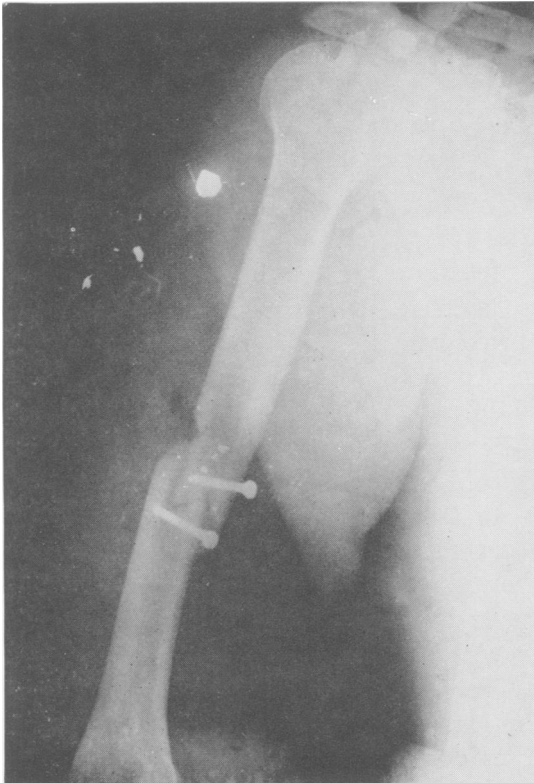


FIG. 12. Humeral shortening by bone impaction—screw fixation.

from delayed hemorrhage. Split skin grafts should be used when a suitable bed exists. Traumatic tissue edema may require split skin grafts to close distal exploratory incisions.

Vascular Injuries. The anatomical site of wounding short of complete severance may determine distal tissue viability. Systemic shock and tissue perfusion may contribute to tissue damage. The maximum allowable time from injury to restoration of vascular flow has not been accurately defined. References to this factor in cases of isolated arterial interruption vary from 8 to 12 hours.^{2, 5, 7, 8} Experimental evidence of limb replantation has shown serious damage after 5 to 6 hours.⁴ It would seem the time interval should be less in elderly patients.

Distal arterial patency should be demonstrated by operative arteriography. A clinical observation of arterial spasm should be objectively proven. The distal veins should be cleared with perfusion of heparin and saline¹⁰ and/or Fogarty catheter.

Foreshortening of the arm or forearm should preclude the need for vessel grafts. Vessel continuity can then be established with primary end-to-end vascular anastomosis. Cooling of injured tissue reduces edema, nerve and muscle damage. Freezing of tissue is to be avoided because of cellular disruption.^{1, 4} Prophylactic fasciotomy may be required to close fascial spaces and prevent pressure necrosis from edema. The vessels should be reexplored prior to wound closure when circulation is inadequate.

Protective Splinting. The hand and arm should be splinted in the position of function. Overstretching of the paralyzed muscles should be prevented. Each joint should be moved daily through the possible active range.

Nerve Injury. Nerve regeneration is the most serious limitation in surgical repair of a severed or near-severed limb. The fol-

lowing series of nerve repairs are reviewed:

Seddon¹³ reported secondary repair of nerve injuries in the British forces during World War II. Delayed return of median motor nerve function at a high and intermediate level was 7% in 234 cases, and sensory median nerve return in 9% of 337 cases. In a low level of section median motor nerve function was restored in 13% of 324 cases and a sensory median return in 16% of 327 cases.

Radial nerve repair was successful in 37% of 187 cases at a high or intermediate level. Ulnar motor nerve function returned in 5% of 391 cases at a high level and 5% of 391 cases at a low level. Sensory ulnar return in 383 cases was reported as poor.

The critical length of nerve defect in the above series of peripheral nerve repairs was 7 to 9 cm. for the median nerve; radial 5 to 7 cm., and ulnar 6 cm. The blood supply of the nerves is probably compromised in a more extensive mobilization and results in an impaired supply.

Önne¹¹ in a smaller series reported recovery of sensibility and sudomotor activity in the hand after nerve suture in 32 median, 17 ulnar and 22 digital nerves. These nerve repairs were in the distal arm, a site with a greater expectancy of return of function.

Complete regeneration of sensibility occurred in 13 cases under 11 years of age; in 5 median, 4 ulnar and 4 digital nerve sutures.

Recovery of sensation in general decreased with the age of the patient. The 3- to 6-year age group showed excellent regeneration. The 20- to 31-year age group showed varied recovery but poor prognosis. Beyond this age all median and ulnar nerve repairs were poor except for digital nerves.

There were no advantages in return of function after median and ulnar nerve sutures done primarily or secondarily. Ideal conditions for good nerve repair set forth by this group are well recognized but are

not always present in injured patients. These conditions include a clean transection, injury distal to middle of the forearm, little residual restriction of mobility, no infection, a time interval in secondary nerve repair of not more than 6 months between injury and suture, no tension at suture line, operation by experienced personnel, and a 5 year follow up.

Malt, *et al.*⁹ reported replantation of the upper arm in two patients. In one, at 20 months after repair median and ulnar nerve function returned. At 8 months in the other case radial function returned but median and ulnar nerve function were not reported.

Herksman, *et al.*⁶ successfully restored an amputated hand at the wrist. Delayed median and ulnar nerve repairs were done. Follow up at 2 years showed adequate motor return and protective palmar sensation but poor sensation in the finger tips.

Williams *et al.*¹⁴ reported a right upper arm severance for which median and ulnar nerve repairs were done 3 months post-injury and radial nerve repair done 6 months after injury. Follow up at one year showed protective sensation to the wrist. Distal finger sensation was present but not considered protective.

Metabolic Acidosis. A contributing factor in limb replantation and crushed tissue with shock may be metabolic acidosis. In those instances of shock which are not related to measured blood loss, metabolic acidosis may indicate tissue anoxia and approaching cell death. Experimental use of THAM (Tris hydroxymethyl amino methane buffer) increased limb survival in pseudoamputation and crush injury. A secondary effect of protective renal perfusion was also noted.¹²

Summary

The limiting factor in repair of severed or near-severed extremities is return of neurofunction. Bone, artery, vein and skin coverage seem to be adequately performed. The more distal the severance in a younger patient the more likely are return of motor and protective sensation. Selected patients, after a properly performed surgical repair, may benefit by replantation of a useful upper extremity.

References

1. Collins, H. A. and Jacobs, J. K.: Acute Arterial Injuries Due to Blunt Trauma. *J. Bone Joint Surg.*, 43A:193, 1961.
2. De Bakey, M. E. and Simeone, F. A.: Battle Injuries of the Arteries in World War II. *Ann. Surg.*, 123:534, 1946.
3. Eiken, O., Nabseth, D. C., Mayer, R. F. and Deterling, R. F.: Limb Replantation. *Arch. Surg.*, 88:54, 1964.
4. Hamel, A. L. and Moe, J. H.: Effect of Total Ischemia on Hind Limbs of Dogs Subjected to Hypothermia. *Surgery*, 55:275, 1964.
5. Hardy, E. G. and Tibbs, D. J.: Acute Ischemia in Limb Injuries. *Brit. Med. J.*, 1:1001, 1960.
6. Herksman, H., Lafer, D. J. and Shafton, G. W.: Successful Replantation of an Amputated Hand. *Ann. Surg.*, 163:137, 1966.
7. Hughes, C. W.: Acute Vascular Trauma in the Korean War. *Surg. Gynec. Obstet.*, 99:91, 1954.
8. Jahnke, E. J. and Howard, J. M.: Primary Repair of Major Arterial Injuries. *Arch. Surg.*, 66:646, 1953.
9. Malt, R. A. and McKann, C. F.: Replantation of Severed Arms. *JAMA*, 189:716, 1964.
10. Mehl, R. L., Paul, H. A., Shorey, W. D., Scheewind, J. H. and Beattie, E. J.: Patency of Microcirculation in the Traumatized Amputated Limb. A Comparison of Common Perfusates. *J. Trauma*, 4:495, 1964.
11. Örne, L.: Recovery of Sensibility and Sudomotor Activity in the Hand after Nerve Suture. *Acta. Chir. Scand.*, Suppl. 300, 1962.
12. Paul, H. A., Mehl, R. L., Scheewind, J. H. and Beattie, E. J.: Shock in Replantation and Crush Syndrome. A Comparison of the Clinical Evolution and Results of Treatment. *J. Trauma*, 5:349, 1965.
13. Seddon, H. J.: War Injuries of Peripheral Nerves. *Brit. J. Surg.*, 2:325, 1949.
14. Williams, G. R.: Replantation of Amputated Extremities. *Ann. Surg.*, 163:788, 1966.