Abdominosacral Resection of Sacrococcygeal Chordoma

S. Arthur Localio, M.D., Kenneth C. Francis, M.D., Paul G. Rossano, M.D.

From the Departments of Surgery and Orthopedics, New York University School of Medicine, New York City

Sacrococcygeal chordoma, an uncommon tumor of the fetal notochord, presents in the sacral hollow or occasionally posteriorly. The tumor may arise in either sex at any age but is more frequent in men in the fifth decade.[8] Growth is leisurely and may span a period of years. Symptoms are produced by displacement and compression rather than by infiltration of contiguous structures. Pain in the low back, sacrum, and coccyx is early and persistent. As the tumor proliferates and encroaches on the sacral foramina, root neurophathies and bladder and rectal sphincter incompetence become evident. Bone destruction, a soft tissue mass and anterior displacement of the rectum (Fig. 1, 2) are the characteristic radiographic signs. At surgery, bone destruction is apt to be more extensive than was evident from roentgenograms. Digital examination of the rectum reveals a somewhat lobulated, homogenous resilient posterior rectal mass (Fig. 3). Diagnosis is frequently late and there may be a history of prior treatment for neurologic, orthopedic or urologic disorder.

The literature records four instances of long-term survival without recurrence among 198 sacrococcygeal chordomas.[4, 7, 8, 11, 13, 15, 16] This tumor, thought by many to remain a local disease, is reported to have had distant metastases in 10% [11] to 16.6% [13] of cases. Ponte and Francis [15] summarized experience at the Memorial Hospital and failed to report a long-term good result. MacCarty *et al.*,[13] recommend posterior local excision limited to the lower three sacral segments followed by radiation therapy. These authors indicate that resection above S3 with inevitable destruction of the pudendal nerve would be complicated by urinary and rectal sphincter incontinence and lumbar spine instability. Butler [1] in a report of a single case sug-

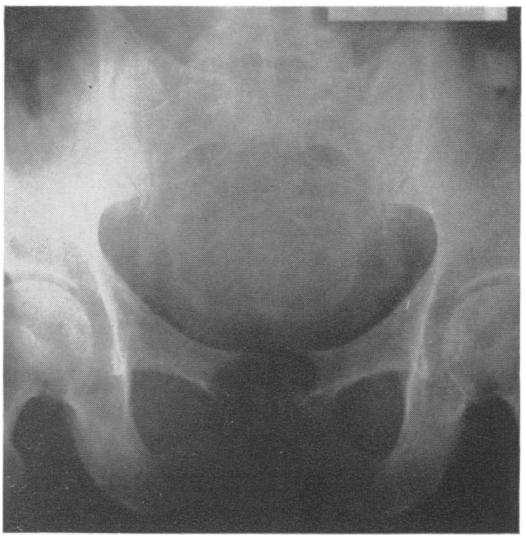

Fig. 1. Case 3. Preoperative: Destruction of lower sacral segments.

This project was supported in part by a Community Cancer Demonstration Project Grant from the PHS.

Presented at the Annual Meeting of the American Surgical Association, May 11–13, 1967, Colorado Springs, Colorado.

gests abdominal exploration prior to local excision to assess the local extent of tumor and the possibility of rectal involvement. This recommendation was based on an earlier one of Mixter and Mixter [14] who, in a single unoperated case, proposed preliminary colostomy followed by radical posterior resection of the sacrum and coccyx with preservation of the third sacral root.

The prohibitive recurrence rate with prolonged terminal disability, the inaccessibility of the tumor and difficulty of determining its extent solely by the posterior approach, and the technical problems of *en bloc* removal without spillage of tumor and injury to the rectum, led us to explore alternative methods of surgical extirpation.

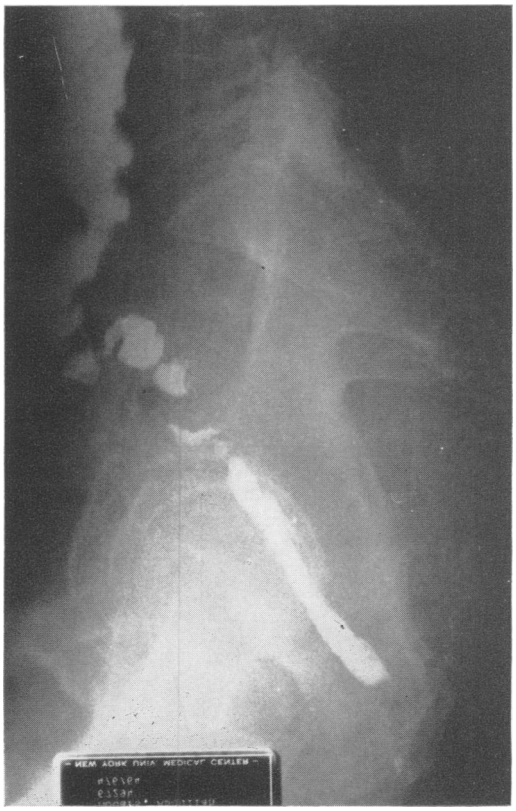

FIG. 2. Case 2. Preoperative: Lateral view of pelvis showing destruction of the lower sacral segments and anterior displacement of the rectum.



FIG. 3. Case 3. Chordoma and resected sacrum.

Method

The abdomen is approached through a left paramedian incision from symphysis to umbilicus and the cavity explored. The peritoneum of the left lumbar gutter is incised and the colon mobilized from left to right; the left ureter is identified. The peritoneum of the cul-de-sac is incised and the rectosigmoid at the level of L5-S1 dissected anteriorly and to the right exposing the upper limits of the tumor in the sacral hollow. The dissection of the rectum anterior to the tumor is continued cauded to the level of the levators and the lateral extension of the tumor visualized. The middle sacral vessels and lateral sacral veins, more prominent than usual, are controlled with suture ligatures. The colon is replaced in its usual position and the abdomen closed. The patient is now placed prone and a transverse incision made across the buttocks at level of S4. The lower flap is raised below the coccyx and the upper flap to L5. The rectococcygeal ligament is sectioned, the rectum dissected anteriorly, and the previously opened presacral space entered, and the lower limit of the tumor visualized.

With the rectum safely displaced and the limits of the tumor in the sacral hollow

in all planes accurately determined, sacral resection may proceed. The lateral sacral ligaments are incised. With a sharp osteotome, the sacroiliac articulations are divided at a level previously determined by abdominal exploration. The sacrum is now transected at this level and lifted from the field. Bleeding may be copious and difficult to control until the sacrum has been removed. No attempt is made to preserve sacral nerves below the level of transection. The posterior wound is closed tightly around a #32 sump drain.

We have carried out the above procedure in five patients with minor modifications.

Case Reports

Case 1. B. S., a 65-year-old woman presented in 1962 with history of multiple surgery for sacrococcygeal chordoma, and recurrent sacral and posterior thigh paresthesias and pain. Partial resection of the sacrum by posterior approach for chordoma was performed in 1957. In 1959 and 1960 she was reoperated upon for recurrences. Eighteen months following her last operation and 6 months prior to admission she noted recurrence of sacral and perineal pain and a recurrent mass at the operative site.

On examination there was a 6-cm. extrarectal mass adherent to the left posterior lateral rectal mucosa. Roentgenograms demonstrated resection of the coccyx and fifth sacral segment; the first four sacral segments were intact. Barium enema demonstrated anterior displacement of the rectum.

The patient was operated upon in two stages 4 days apart. Abdominal mobilization of colon with resection of portion of rectum and proximal colostomy was performed and 4 days later the sacrum was resected to the level of S1. Postoperatively there was return of micturition and cystometrograms performed 2 months following surgery revealed good emptying of the urinary bladder with residual urine of 10 cc. The patient has done well without evidence of recurrence, and we plan closure of colostomy. On the basis of our present experience, we believe that surgery can be performed in one stage without the need of proximal colostomy.

Case 2. A. M., a 65-year-old Iranian man, was admitted in April 1964, with complaints of sacral and posterior thigh pain of a year's duration. Rectal examination revealed a 10-cm. mass in the sacral hollow. Roentgenographic studies demonstrated anterior rectal displacement by a mass destroying the coccyx and sacral segments up to S4.

A combined abdominosacral resection was performed with sacral resection through the lower portion of the third sacral segment. The patient had an uneventful postoperative course and on discharge on the 33rd postoperative day, he had adequate voluntary rectal sphincter control and urinary continence. He has no evidence of recurrence and 2 years post-surgery has normal urinary function and anal sphincter control.

Case 3. I. C., a 58-year-old man, was admitted in November 1965, with a history of an enlarging mass in the sacrococcygeal area. The mass, present at the time of hemorrhoidectomy 4 months prior to admission, had increased in size and was painful and tender. There was no evidence of neuropathy or sphincter disturbance. Rectal examination revealed an 8-cm. mass in the sacral hollow and a 2-cm. posterior protuberance over the midsacrum. Roentgenograms demonstrated a presacral mass involving the S3 to S5 segments and causing anterior rectal displacement.

The patient was operated upon by the abdominosacral approach and sacral resection including the second segment was performed. Postoperatively there were several temporary episodes of urinary and fecal incontinence. He was discharged on the 35th postoperative day with adequate bowel control and was able to void with the aid of abdominal musculature contraction. Four months post-surgery the patient was readmitted for urinary retention. Study at this time revealed a somewhat hypotonic bladder (Fig. 4) and prostatic hypertrophy. He was treated by transurethral resection. He continues to have satisfactory bowel control; micturition occurs at will. On rare occasions, there is slight urinary incontinence associ-

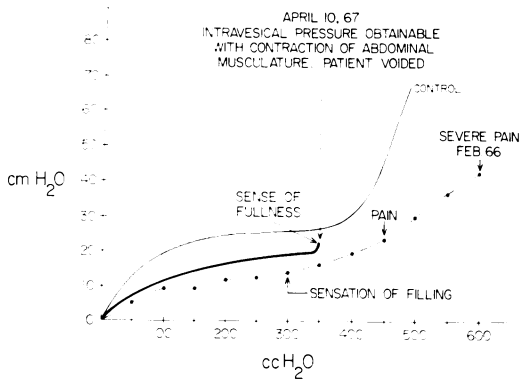

FIG. 4. I. C. Case 5. Cystometrogram. A month post-resection of chordoma, and one year thereafter.

ated with coughing or heavy lifting. Cystometrogram 16 months post-surgery shows hypotonicity of the bladder (Fig. 4). Voiding is adequate and initiated by contraction of the abdominal wall musculature. There is voluntary rectal sphincter activity, and no evidence of recurrence.

Case 4. A. C., a 68-year-old man, was admitted with a chief complaint of pain in the sacral region and right buttock. Onset of the pain was approximately 2½ years prior to admission and was followed shortly thereafter by urinary incontinence. He was evaluated and admitted to another hospital a year later. An ileal conduit was created with exteriorization of the urinary flow for uncontrollable incontinence. Shortly thereafter, the patient noted the onset of paresthesias and pain in the right buttock and right posterior thigh. He was able to walk and there was no history of weakness. Prior to admission exploratory laparotomy was performed at another hospital where a sacral tumor was noted and a biopsy and histopathologic examination confirmed the diagnosis of chordoma. He was referred to the New York University Hospital. Physical examination on admission revealed a firm, rubbery presacral mass impinging on the posterior rectum. Neurologic examination presented hyperalgesia along the inner surface of the right buttock and on both sides of the coccyx, and a marked hyperesthesia on the hairy areas of the right inner buttock. There was voluntary contraction of the rectal sphincter with good motor unit output in this area. An excretory urograph showed a normal collection system on the left side with a moderate hydronephrosis and moderate hydroureter on the right. Bone survey was unremarkable. Preoperative liver scan was normal.

Abdominosacral resection at the S2 level was bloody and the patient required 17 pints of blood. The immediate postoperative course was satisfactory. On the third postoperative day, the temperature spiked to 103° without chills or other systemic indications of septicemia. Blood cultures were negative and the patient was placed on antibiotics. Spiking temperature curve continued. On the fifth postoperative day cultures of the urine and blood at the time of temperature spike were reported to contain a gram negative rod of the aerobacter group. Appropriate antibiotics were administered with amelioration of fever. On the fourteenth postoperative day, the patient's affect and sensorium became noticeably diminished. On the eighteenth postoperative day, the patient was in nitrogen retention and renal acidosis. He complained of tightness in the chest with difficulty in breathing. Cardiac arrest occurred and he could not be resuscitated. Autopsy revealed bilateral pyelonephritis. There was no residual evidence of tumor. During life, this patient had satisfactory rectal sphincter control.

Case 5. R. S., a 58-year-old woman, was admitted with complaints of pain and numbness over the sacral area and loss of sphincter control. Two years previously, the patient had had a laryngectomy for sarcoma of the larynx. She was well for 18 months and 6 months prior to entry noted progressive pain over the secrum and buttocks, associated with numbness over the perineum, vagina and anterior thighs. Rectal sphincter disturbances were progressive, with intermittent lack of control. On rectal digital examination, there was a lobulated resilient extrarectal mass in the sacral hollow. Roentgenographic studies revealed a bony lesion of the sacrum, anterior displacement and extrinsic pressures on the rectosigmoid, and myelographic evidence suggestive of an epidural mass of the cauda equina.

At operation a 10-cm. mass of tumor with its upper limit at S2 was identified and removed by abdominosacral approach, with sacral resection through the S2 segment. The report of the pathologist was chordoma. The patient did well for the first 4 postoperative weeks. Bladder function was satisfactory after the second week, rectal incontinence ceased, and the patient was able to walk. At the fourth week there were periods of confusion and aphasia, and at the sixth week a left hemiparesis developed. At the tenth week a soft tissue mass developed in the left temporoparietal region. Eleven weeks post-surgery, the patient died. Autopsy revealed brain and visceral metastases; there was no residual evidence of sacral tumor. The final diagnosis of the pathologist was metastatic sarcoma with the larynx as the primary site. Review of the sacral histology resulted in a change of diagnosis from chordoma to sarcoma. Although the diagnosis was missed and the sacral resection was of dubious value, we include this patient because with sacral resection through S2, she manifested postoperative satisfactory urinary and rectal sphincter function.

Results

Of the five patients reported, Case 5 was mistakenly diagnosed and the patient succumbed with cerebral metastases 11 weeks post-surgery. Patient 4 died 17 days after surgery of uremia associated with an ileal bladder performed 2½ years previously for the control of urinary incontinence. This is an operative death. In the three long-term survivors and two short-term survivors,

lumbar spine support was not a problem. Rectal sphincter function was adequate in four patients. The fifth has a colostomy but has voluntary sphincter activity. Satisfactory bladder function was established in four patients, one of these a short term survivor (11 weeks). The fifth patient had an ileal bladder. One patient required transurethral prostatic resection 4 months postsurgery. Of the four sacral resections for chordoma, three are alive without recurrence (1, 2, and 3 years). The fourth was an operative death. All survivors have returned to their preoperative duties.

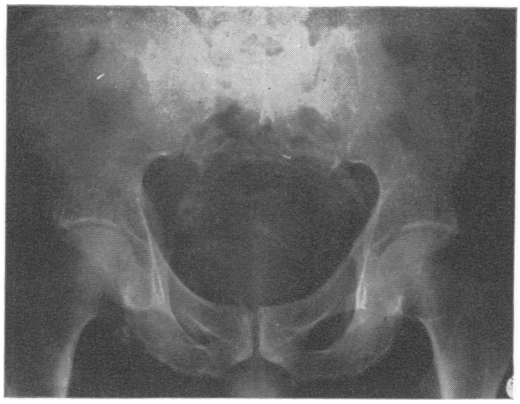

FIG. 6. Sacral secretion Case 2. One year postsurgery showing bone regeneration.

Discussion

Our present experience indicates that radical extirpation of sacrococcygeal chordoma with the object of cure can be done as high as the S1, S2 interspace without interference with lumbar spine stability (Fig. 5, 6) and with satisfactory anal sphincter and urinary bladder function. The abdominosacral approach has made it possible to accomplish *en bloc* resection of the tumor without spillage or injury to the rectum. Copious bleeding during sacral resection has been troublesome and in the future we plan to modify the operation for better control of blood loss and more accurate transection of the sacrum. During the past year one of us [12] has approached midportion rectal tumors by a simultaneous two team combined abdominal and posterior approach, with coccygeal resection with safer low rectal anastomosis. The lateral position avoids the necessity of turning the patient after abdominal mobilization of the colon. This is an outgrowth of the suggestion of Donaldson *et al.*[5] We believe that this approach (Fig. 7) with the patient in the lateral position affords adequate mobilization of the colon and exposure of the tumor in the sacral hollow. Midsacral vessels and lateral sacral veins can be secured and in addition, tapes may be passed about the common iliac vessels for temporary occlusion during the course of sacral resection. The sacrum may be approached in the lateral position by either a vertical or transverse incision. Finally, the abdominal team can guide the level of osteotomy of the sacrum. When the specimen is removed, the common iliac vessels can be released individually for more accurate and leisurely hemostasis.

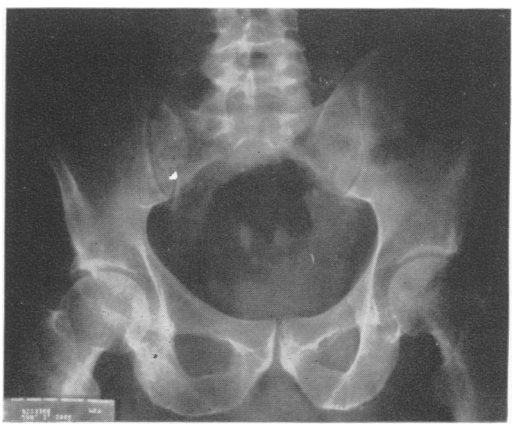

FIG. 5. Case 3. Postoperative sacral resection.

Currently accepted theories regarding micturition as proposed by Emmett *et al.*[6] and Hinman [9] no longer recognize the hypothesis of dual antagonistic innervation of the bladder. These authors state that the sympathetic nervous system "has no influence on the initiation, maintenance or inhibition of urination." In the light of pres-

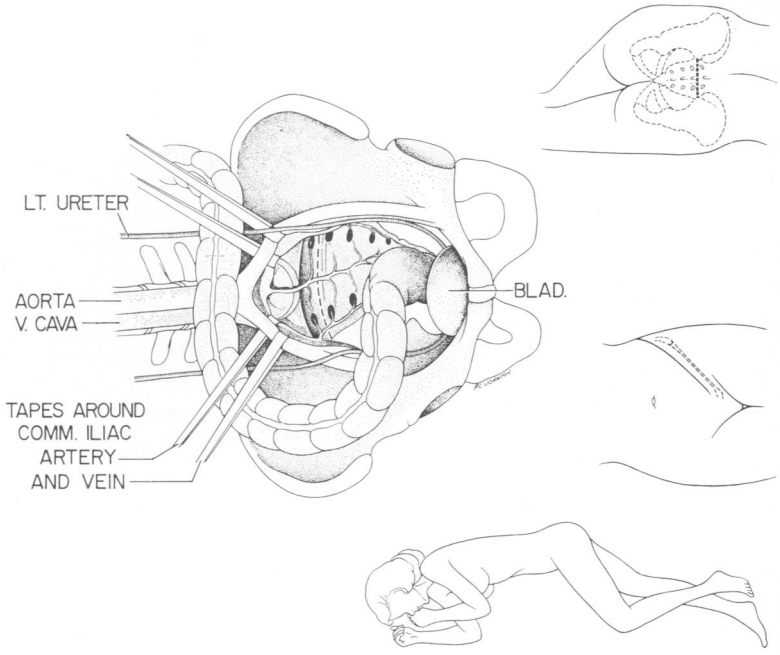

FIG. 7. Simultaneous abdominosacral approach with patient in lateral position.

ent-day thinking, the requirements for emptying the bladder are a normal vesical neck, an intact lower sacral reflex arc with intact sacral chord segments S2 through S5 and a competent urethral sphincter.

It is thought that as the bladder distends, afferent proprioceptive impulses via the pelvic nerve (parasympathetic) enter the cord through sacral segments S2 to S4. These impulses proceed to higher brain centers via the spinothalamic and gracilis tracts. The desire to void is recorded and efferent impulses proceed downward through the corticoregulatory tracts and motor impulses reach the urinary bladder via the pelvic nerve through the S3, S4, S5 segments. It would appear therefore, that aside from the necessity of maintaining the afferent and efferent pathways from higher brain centers to the lower sacral segments in order to facilitate conscious micturition, the integrity of the sacral segments S2, S3, S4, S5 must be maintained along with the uninterrupted pelvic and pudendal nerves. All our patients with an intact urinary bladder have had S3, S4, S5 sacrificed and three have had S2 sacrificed and in all voluntary micturition has occurred. In four patients with intact rectum three have had sacrifice of S2 through S5 and one had S2 preserved and all achieved rectal sphincter activity.

Studies by Campbell [2] and Jackson *et al.*,[10] on patients with myelomeningocele, in whom the sacral segments are obliterated indicate that contraction of the bladder and subsequent micturition may well be affected through alternate pathways carried by sympathetic inervation to the bladder. The latter pathways originate from the thoracic and upper lumbar segments and emerge via the hypogastric nerve to the bladder and proximal urethra.

Case 3, with resection through S2, has a hypotonic bladder but he has a cerebral representation of fullness on the cystometrogram at 350 ml. (Fig. 4). Campbell [3] suggests that this conscious recognition of fullness necessary to avoid overflow and the initiation of micturition by contraction of the abdominal musculature is carried by somatic afferent fibers that travel with

adrenergic efferent fiber in the sympathetic chain. Theoretically, this would provide an alternate afferent pathway for perception of bladder and rectal sphincter sensation to the high brain centers in the absence of the second through the fifth sacral roots bilaterally. This same pathway is utilized by the paraplegic who develops bladder automaticity. We suggest that our patients, who are continent, have automatic bladders. Integrity of the interstitial neural plexus of the bladder and rectal sphincters musculature which is sensitive to stretch or pressure with straining is the myoneural mechanism whereby our patients are able to void when they perceive bladder or rectal fullness. In addition, the integrity of S1 is maintained and although this root is not thought to be involved in the act of micturition, the observed results suggest reinvestigation of this theory.

Summary

Abdominosacral resection for cure of sacrococcygeal chordoma is suggested. Improvement of technic are discussed.

Resection of sacrum through S2 in this short series is compatible with satisfactory anal sphincter and bladder function.

References

1. Butler, E. C. B.: Chordoma of the Sacrum. Proc. Roy. Soc. Med., **44**:3, 1951.
2. Campbell, J. B.: Neurosurgical Treatment of Bladder and Bowel Dysfunction Resulting from Development of Sacral Neural Axis. Clin. Neurosurg., **8**:133, 1962.
3. Campbell, J.: Personal communication, 1967.
4. Cappell, D. F.: Chordoma. J. Path. Bact., **31**: 797, 1928.
5. Donaldson, G. A., Rodkey, G. V. and Glenn, E. B.: Resection of the Rectum with Anal Preservation. Surg. Gynec. Obstet., **123**:571, 1966.
6. Emmett, J.: Physiology of Micturition. *In* Campbell's Textbook of Urology, Vol. 1. Philadelphia, W. B. Saunders Co., 1965, p. 130.
7. Fletcher, E. M., Woltman, H. W. and Adson, A. W.: Sacro-Coccygeal Chordomas, A Clinical and Pathological Study. Arch. Neurol. Psychiat., **33**:283, 1935.
8. Gentil, F. and Coley, B. L.: Sacro-Coccygeal Chordoma. Ann. Surg., **127**:432, 1948.
9. Hinman, J.: Innervation of the Bladder. *In* Campbell's Textbook of Urology, Vol. 1. Philadelphia, W. B. Saunders Co., 1965, p. 30.
10. Jackson, I. J. *et al.:* Urinary Incontinence in Myelomeningocoeles Due to Tethered Spinal Cord and its Surgical Treatment. Surg. Gynec. Obstet., **103**:618, 1956.
11. Littman, L.: Sacro-Coccygeal Chordoma: Reviewed Presentation of 3 Additional Cases. Ann. Surg., **137**:80, 1953.
12. Localio, S. A. and Stahl, W.: Personal communication, 1967.
13. MacCarty, C. S. *et al.:* Sacro-Coccygeal Chordoma. Surg. Gynec. Obstet., **113**:551, 1961.
14. Mixter, C. G. and Mixter, W. J.: Surgical Management of Sacro-Coccygeal and Vertebral Chordoma. Arch. Surg., **41**:408, 1940.
15. Ponte, A. and Francis, K. C.: Il cordoma. Archivio Putti, **18**:1, 1962.
16. Stewart, M. J. and Morin, J. E.: Chordoma: A Review. J. Path. Bact., **29**:40, 1926.

Discussion

Dr. Eugene M. Bricker (St. Louis): Mr. Chairman, I'd like to congratulate Drs. Localio and Francis on a worthwhile study of a very difficult lesion. I'm not qualified to speak about a very important aspect of their paper, that which concerns the height to which sacral resection can be carried, and the degree of disability that will result. However, I would like to talk about the lesion for just a moment and to present a 15-year survivor, since they are extremely rare.

It's difficult to understand why the diagnosis of this lesion isn't made a little earlier, so that the extended type of resection that Dr. Localio has described is not necessary. I have a patient, a Missouri physician, who in 1952 presented with paroxysmal rectal pain, and was found to have a little tumor at the level of the sacrococcygeal junction posterior to the rectum. He had been advised to have a biopsy of this lesion through the rectum because it seemed so accessible.

One of the points I would like to make is that I think a reason for the poor results following resection of this tumor is that it is too often biopsied or inadequately resected through the rectum, as I have noted on several occasions. With this important first attempt tumor cells are implanted in such a manner that subsequent adequate resection of recurrence is almost impossible and the rectal wall is always involved.

(Slide) This patient presented a tumor which we could feel, and instead of a biopsy at the