


M. Sadat-Ali



S. M. Al-Awami

WIND-SURFING INJURY TO AXILLARY ARTERY

M. SADAT-ALI, MD, BS, DOrth, FICA* and S. M. AL-AWAMI, MD†

Depts. of Orthopaedic and General Surgery†, King Fahd University Hospital, King Faisal University, PO Box 2208, Al-Khobar, Saudi Arabia 31952*

INTRODUCTION

Injuries to arteries and their clinical complications are well known (Rich and Spencer, 1978). Such injuries are however rare in sports (McFadden and Ochsner, 1981 and Williams and Sperryn, 1976). Although cases have been reported sporadically about such injuries (Kostianen and Orava, 1983; Madigan and McCampbell, 1981 and Pinkerton et al, 1977). We add here a report of axillary artery injury as a result of wind-surfing.

CASE REPORT

A 30-year-old athletic man was referred to our hospital with a history of numbness, pain and pallor of the right upper limb of two weeks duration. Prior to this he recalls falling several times on his abducted right shoulder while wind-surfing. His general health was good and he was not a smoker.

Examination showed the right upper limb was pale and cold compared with the left. There were no ulcers nor were there signs of external trauma to the right axilla or upper limb. Sensation was reduced from the middle of the arm and the muscle power was of grade III (Medical Research Council of UK grading). The pulses of the right radial, brachial and axillary arteries were absent. The carotid and subclavian vessels were palpable. The peripheral pulses of the left upper limb were present and normal.

His investigations revealed red blood cell count 5.27×10^{12} per litre, haemoglobin 16.5 g per dL, white cell count 9.5×10^9 per litre, prothrombin time 11 seconds and partial thromboplastin time 28 seconds (control) was 24 seconds. Serum electrolytes and urine examination were normal. A chest radiograph did not reveal any abnormality. An arteriogram showed a complete block of the right axillary artery at its distal part (Fig. 1). A transverse arteriotomy and thrombectomy was carried out using a Fogarty embolectomy catheter. At operation it was found the vessel was blocked by a thrombus. The thrombus was firm and had started to organise. It was removed without any difficulty. On the operating table adequate flow through the distal segment of the artery was confirmed visually and by palpation. Post-operatively the flow in the vessel was confirmed by Bi-Directional Doppler Velocimeter (SONICAID). The recovery of the patient was

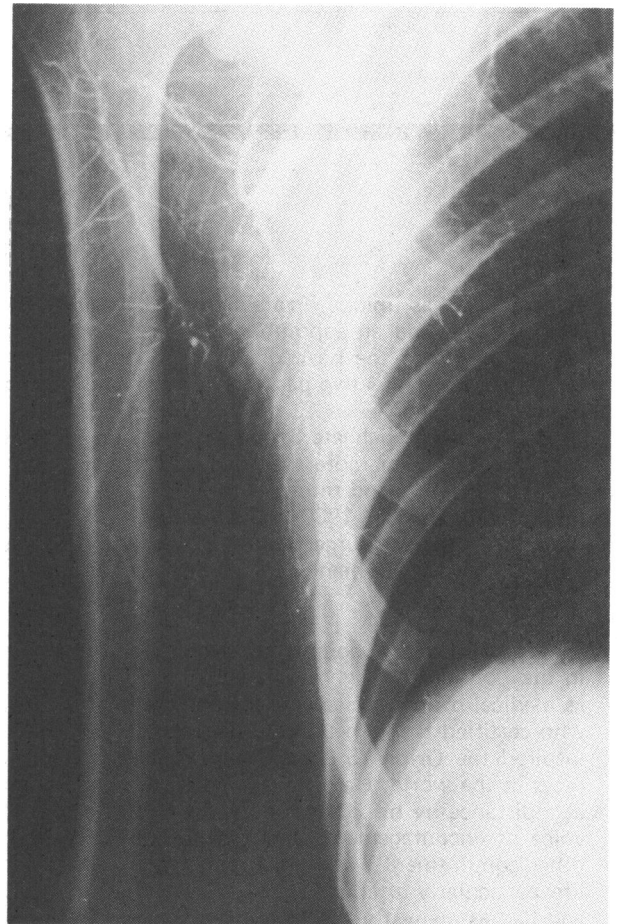


Fig. 1: An arteriogram showing complete block of distal part of axillary artery.

complete. The patient has been followed up for twelve months and remains symptom free.

DISCUSSION

“Upper extremity thrombosis” has been known for over a century. The cause of the thrombosis is attributed to malrotation of upper limb in strenuous exercise (Demeter et al, 1982). Damage to the endothelium by a direct blow to an artery can trigger thrombus formation (Pitney, 1981). Repeated trauma

**To whom all correspondence and requests for reprints should be addressed*

to the same vessel can lead from initial vascular spasm to thrombosis. Such vascular trauma, although rare, has been reported (Buckhout and Warner, 1980 and Lowrey et al, 1976).

Our patient who was in an excellent state of health had repeated falls in water on the abducted right arm. This happened whilst wind-surfing. This led to direct trauma to the axillary artery with subsequent thrombosis. On the basis of the arteriographic findings an arteriotomy with thrombectomy was performed. This led to early, uneventful recovery and early return to sports. Kostianen and Orava, 1982 reported that the thrombosed arteries recanalised in 8 weeks (in two patients out of three), with vasodilator drugs and avoidance of sports. If the arteries fail to recanalise spontaneously then the sportsman will have a limb with compromised circulation which will not sustain strenuous activity. Moreover the delay may lead to permanent tissue changes. An aggressive attitude in such cases is indicated and justified.

ACKNOWLEDGEMENT

We thank Dr. Mustapha Hassan Badi, FRCSI, PhD, for his help in the management of the patient.

References

- Buckhout, B. C. and Warner, M. A., 1980 "Digital perfusion of handball players. Effect of repeated ball impact on structures of the hand". *Am.J.Sports Med.* 8: 206-207.
- Demeter, S. L., Pritchard, J. S., Piedad, O. H., Cordasco, E. M. and Taheri, S., 1982 "Upper extremity thrombosis: etiology and prognosis". *Angiology* 33 (11): 743-748.
- Kostianen, S. and Orava, S., 1983 "Blunt injury of the radial and ulnar arteries in volley ball players. A report of three cases of the antebrachial. 'Palmar Hammer Syndrome' ". *Brit.J.Sports Med.* 17 (3): 172-176.
- Lowrey, C. W., Chadwick, R. O. and Waltman, E. M., 1976 "Digital vessel trauma from repetitive impacts in baseball catchers". *J.Hand Surg.* 1: 236-238.
- McFadden, P. M. and Ochsner, J. L., 1981 "Javelin injury to the subclavian artery". *Am.J.Sports Med.* 9 (6): 400-404.
- Madigan, R. R. and McCampbell, B. R., 1981 "Thrombosis of popliteal artery in a jogger". *J.Bone and Surg.* 63A: 1490-1492.
- Pinkerton, J. R. Jr., Macgee, E. E. and Romine, K. G., 1977 "Traumatic aneurysm of the intra thoracic left carotid artery with cerebral embolisation". *J.Trauma* 17 (12): 975-977.
- Pitney, W. R., 1981. *Venous and Arterial Thrombosis. Evaluation, Prevention and Management.* Churchill Livingstone: Edinburgh, London.
- Rich, N. M. and Spencer, F. C., 1978 "Vascular trauma". W. B. Saunders Co.: Philadelphia.
- Williams, J. G. P. and Sperry, P. N., 1976. *Sports Medicine*, 2nd Edition. Edward Arnold: London.

OBITUARY

Harold Burton Lee, TD, MB, BS, FRCS 1909-1985

Harold Lee was unique. Professionally he was an Orthopaedic Surgeon who had a special interest in children and as well as Barts had an appointment as medical officer in charge of the now closed Alexandra Hospital, Luton (mainly caring for TB of the hip) for 12 years and then consultant to Notley Hospital. However his name is probably much better known for his two passions, running and singing.

After leaving Highgate School for Barts he joined Orion Harriers and the United Hospitals Hare and Hounds and ran in all for Orion for more than 50 years. He took up running seriously "to cure" a knee injury gained playing football, qualified in 1933 and returned to Barts as Chief Assistant to the Orthopaedic Department in 1936. Being a TA Officer he was called up in 1939 and served with the RAMC for six years in West Africa, France and India, mainly he said "humdrum routine surgery but with six weeks of hectic 'MASH' operating on Allied and German battle casualties in vast numbers in Normandy in the Summer of 1944." He was mentioned in despatches and held the rank of Lieutenant Colonel.

After the war he completed several marathons and in 1947 came 13th in the AAA marathon and received 3rd place in the London to Brighton Race in 1951, the first year it was run. He served running indefatigably as an official both as medical officer and eventually President of the Road Runners Club and more recently was one of the two measurers who certified that the London Marathon was indeed the full distance and slipped into the Thames while doing so. He inspired the Orion 15 Cross-Country Race and helped it to develop into one of the best known "real" cross-country races in the world. Harold was known throughout the world as just "Harold" or "Doc Lee" and was easily recognised at a distance by his Dormobile and two small dogs from whom he was inseparable, and from closer to by his booming voice of encouragement or criticism "You look too happy you are not really trying", or just "Well done". Harold's other commitment was his voice - singing, first attempted on a very slow boat to West Africa but another half of his life particularly after retirement. A member of the Gregorian Association, he died as President of the Madrigal Choir and had as many friends from his singing as from his running. He is quoted as saying his idea of heaven was to run a marathon in the morning and sing Bach's B minor Mass in the evening. Harold had a gift for making friends and setting an example of commitment to his activities which would be impossible to follow.

Harold Lee joined BASM in 1957. He had a particular interest in the environmental problems of marathon races. He retired in 1975 and died after a long illness in St. Bartholomew's Hospital earlier this year.

Harold died with no relatives to survive him but left some funds for a large memorial party which was attended by a large number of his friends.

D. S. Tunstall Pedoe