The Preperitoneal Approach and Prosthetic Buttress Repair for Recurrent Hernia

The Evolution of a Technique

LLOYD M. NYHUS, M.D., F.R.C.S. (HON., ENG), F.R.C.S.I. (HON.) F.A.C.S.,
RAYMOND POLLAK, M.B., F.R.C.S. (ED.), F.A.C.S., C. THOMAS BOMBECK, M.D., F.A.C.S.,
and PHILIP E. DONAHUE, M.D., F.A.C.S.

From the Department of Surgery, University of Illinois College of Medicine at Chicago, Chicago, Illinois

Repair of recurrent groin hernias is associated with a high incidence of repeat recurrences (2–19%). Reported herein is a 10-year experience of the management of recurrent groin hernias through the use of the preperitoneal approach with the addition of a reinforcing prosthetic mesh buttress. Two hundred and three recurrent groin hernias in 195 patients (192 men, three women) were treated between July 1975 and October 1986. The preperitoneal approach to the inguinal region was performed under regional anesthesia to define the nature of the recurrent hernia. Initial experience in a randomized trial between the use of local endogenous tissue repair *versus* endogenous repair with a prosthetic polypropylene mesh buttress demonstrated superiority of the latter in reducing repeat recurrences of anatomically defined direct or combined recurrent hernias. Pure indirect and femoral recurrences did not mandate mesh reinforcement. Long-term follow-up was available for 115 hernias (56%) in 102 patients (52.3%) over a period of 6 months to 10 years. Eight patients had repeat recurrences a mean of 30 ± 22 months after repair. Six recurrences (four direct, two indirect) occurred in an early experience, when no mesh was used. Two recurrences (one indirect and one lateral to the mesh) representing 1% of all hernias (1.7% of those followed-up) have occurred after routine use of the mesh buttress, with the last re-recurrence seen in December 1982. Three ventral hernias (1.5%) occurred at the wound of entry, but none have occurred since placement of the mesh was modified to cover this wound. There were five (2.5%) wound infections and one (0.5%) hydrocele with no re-recurrences. It is concluded that the preperitoneal approach to recurrent groin hernias, together with the appropriate use of a reinforcing mesh buttress, is safe, allows anatomic definition of the hernial defect, and is followed by few repeated recurrences. The evolution of this approach during the last 10 years has made it the procedure of choice for the management of all recurrent groin hernias at the University of Illinois College of Medicine.

THE REPAIR OF RECURRENT GROIN HERNIAS is technically demanding and associated with a high incidence of repeated recurrences (2–19%) in selected series.[1-3] We adopted the preperitoneal approach to the inguinal region for all recurrent groin hernias repaired during the past 12 years. This approach was used to facilitate anatomic definition and to minimize subsequent recurrences of the hernia. Incorporation of a prosthetic mesh buttress to strengthen the repair is a novel addition to the preperitoneal approach for the management of all recurrent groin hernias.

We report a 10-year experience of the management of recurrent groin hernias through the use of the preperitoneal approach with the addition of a reinforcing prosthetic mesh buttress. Our results suggest that this approach to the management of recurrent groin hernias is associated with minimal morbidity and few repeat recurrences.

Materials and Methods

We evaluated 203 recurrent groin hernias present in 195 patients (192 men, three women) treated at the University of Illinois and Veterans Administration West Side Hospitals from July 1975 to October 1986. In 20 patients (9.8%), the hernia had recurred more than once. Two patients had hernias appear after a deep and superficial groin dissection. At the initiation of the study, two patients had the recurrence repaired from an anterior approach, thus leaving 201 hernias available for study.

The preperitoneal approach to the inguinal region was performed under regional anesthesia in most patients, as originally described by Nyhus et al.[4-6] No perioperative antibiotics were used. Direct visualization at operation revealed 120 direct recurrences (59%), 69 indirect recurrences (34%), eleven combined direct and indirect recurrences (5%), and three recurrences of femoral hernias (1%).

Reprint requests and correspondence: Lloyd M. Nyhus, M.D., Department of Surgery, University of Illinois, College of Medicine at Chicago, Box 6998 (M/C 958), Chicago, IL 60680.

Submitted for publication: March 22, 1988.

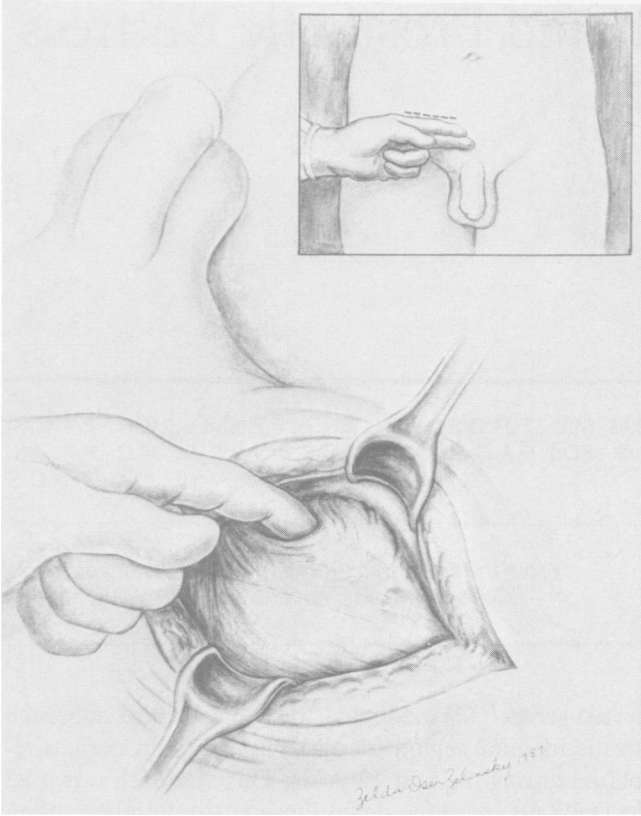

FIG. 1. Preperitoneal approach. Incision is made two fingerbreadths *above* the symphysis pubis. The lateral aspect of the incision must be above the internal abdominal ring. The position of internal ring may be estimated by palpation of the external inguinal ring.

The initial use of the mesh buttress was based on several operative judgmental factors, including the number of previous repairs, the size of the defect, and the apparent strength of the local tissues. Early in our experience, in 1975, we began a prospective, randomized study of anatomic repair, using the local endogenous tissues as opposed to anatomic repair with a prosthetic mesh buttress, both of which were carried out by the preperitoneal approach. A sequential analysis of early recurrence rates in the prospective study demonstrated the superiority of the prosthetic mesh buttress in reducing repeat recurrences. This fact forced a change to be made in the earlier methods, to placement of a polypropylene mesh buttress in all anatomically defined direct and combined recurrent inguinal hernias. Pure indirect recurrences and femoral recurrences did not mandate mesh reinforcement unless the previously described preconditions in the endogenous tissues were also in evidence.

Operative Technique

The transverse abdominal incision is made about two fingerbreadths above the symphysis pubis; its lateral aspect should be above the internal abdominal ring (Fig. 1). The preperitoneal space is entered after the endoabdominal fascia is incised. The inferior epigastric vessels are divided as needed. Sharp and blunt dissection bring the posterior inguinal wall into view, and the hernial sac is seen to project through the inguinal wall. The sac is then reduced and ligated (for indirect and femoral hernias).

An anatomic repair of a direct hernia using endogenous tissues involves the approximation of the transversalis fascia to the iliopubic tract or the Cooper ligament. Direct defects are closed with 0 polypropylene suture, care being taken that good fascial edges are encompassed. Indirect hernial defects are closed medial to the spermatic cord, two to four sutures being placed between the anterior crus of transversalis fascia at the internal abdominal ring and iliopubic tract posteriorly. Femoral hernial defects are closed with two or three sutures placed between the Cooper ligament below and the iliopubic tract above. A relaxing incision is made as necessary in the anterior rectus sheath as part of the anatomic repair.[5]

After closure of the recurrent hernial defects, a piece of polypropylene (Marlex, C. R. Bard, Inc., Billerica, MA)

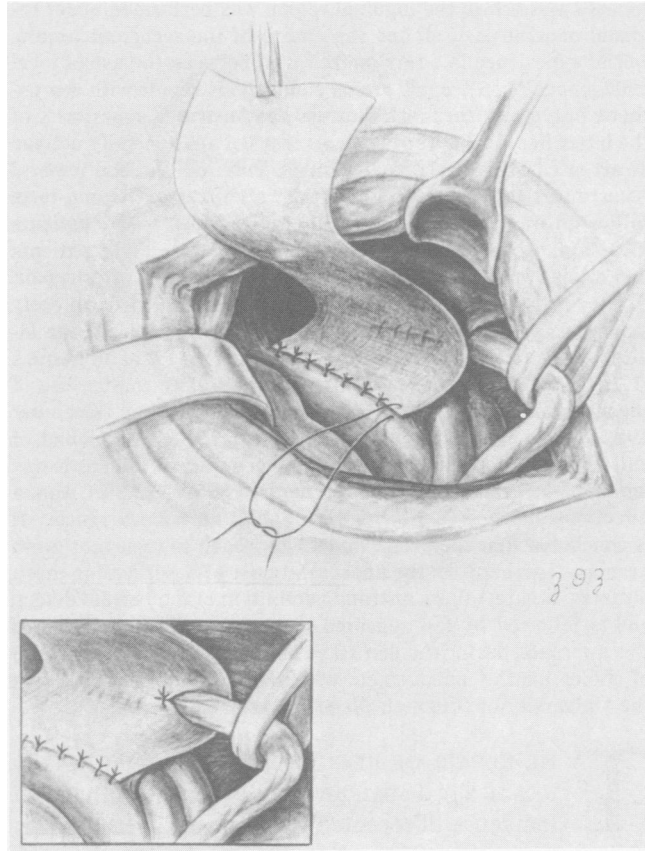

FIG. 2. Polypropylene (Marlex) mesh prosthesis is sutured to the Cooper ligament with 0 polypropylene suture material after the inguinal wall defect has been repaired. The mesh may be tailored to fit lateral structures (inset).

mesh is cut. Ordinarily, the size of the mesh is 10 × 4 cm. The Cooper ligament is visualized, and the mesh is sutured to it with 0 polypropylene suture material (Fig. 2). When the repair is of a recurrent indirect hernia, the spermatic cord should be incorporated into the mesh. The mesh is then simply folded over the fascial repair and tacked to the posterior inguinal wall with 000 polypropylene suture (Fig. 3). Fortunately, the polypropylene mesh may be tailored to fit the area that is to be covered. Finally, the mesh is sutured beneath the abdominal wound of entry to buttress this closure, as well (Fig. 4). The abdominal wall is then closed in layers in a standard manner.

Long-term follow-up information (obtained by clinical visit or telephone inquiry) on 115 hernias (56%) in 102 patients (52.3%) was available. The length of the follow-up period ranged from 6 months to 10 years.

Results

Eight patients had repeat recurrences for a mean of 30 ± 22 months after the repair. Early in our experience, six recurrences occurred in patients in whom no mesh had been used (four direct, two indirect). These represented 3% of all hernias and 5% of those for which follow-up data were available. Two recurrences took place in patients in whom mesh had been placed (one indirect and one lateral to the mesh itself). These represented 1% of all hernias and 1.7% of those for which follow-up information was available. The last known repeat recurrence was seen in December 1982. There were no re-recurrences after we adopted the routine placement of the prosthetic mesh buttress to bolster the anatomic repair. Other complications included five superficial wound infections (2.5%) with no recurrences and one hydrocele (0.5%). Three ventral hernias occurred at the wound of entry (1.5%), but none have appeared after we modified the placement of the mesh and the suture material used to close this wound (*i.e.*, discontinued using silk and began using monofilament polypropylene suture).

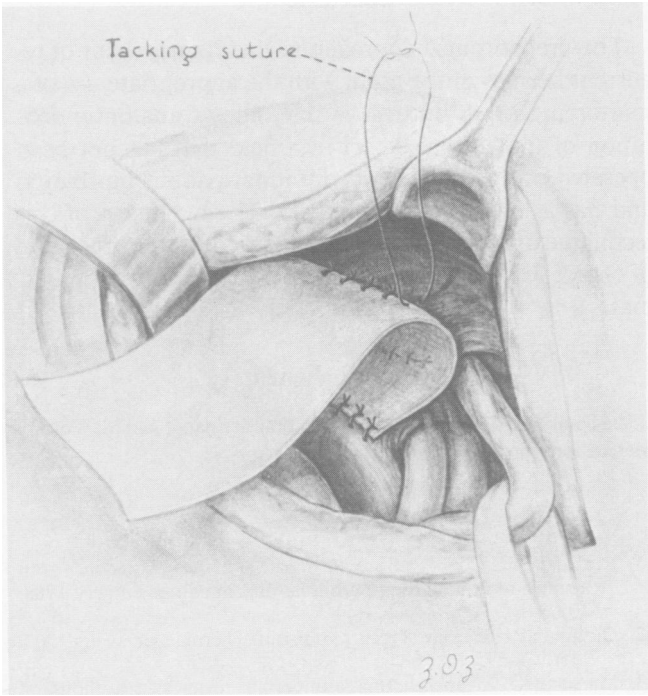

FIG. 3. The mesh is tacked to the posterior inguinal wall above the repair of the recurrent hernial defect with 000 polypropylene suture.

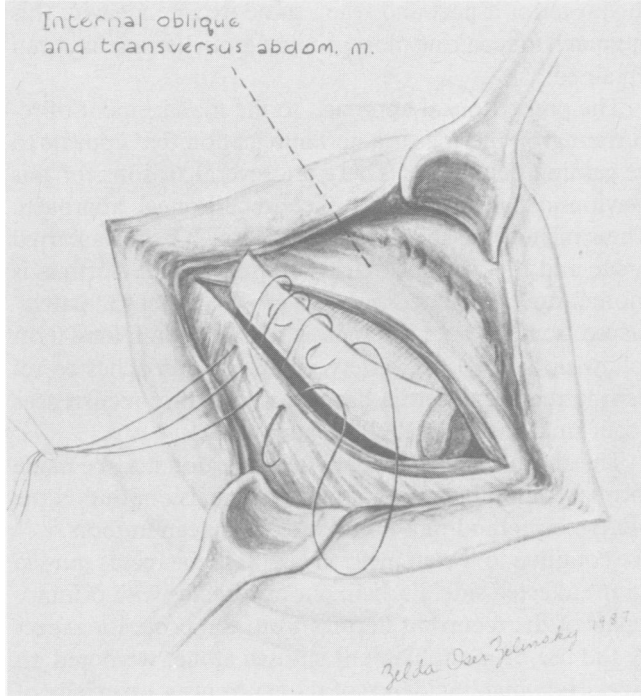

FIG. 4. The Marlex polypropylene mesh is finally sutured under the abdominal wound before closure. The abdominal wound is closed in layers.

Discussion

The preperitoneal approach to the management of all hernias of the groin has been controversial since this technique first became popular in 1959.[6] Thus, although we have found it difficult to emulate the outstanding results achieved with the Shouldice repair of primary inguinal hernias,[7] we have found that, in terms of rate of hernia recurrence during a long-term follow-up period, the preperitoneal technique compares favorably with other types of primary repairs of groin hernias. The technique is especially successful when the operating surgeon is familiar with the anatomy of the inguinal region as viewed from

the posterior aspect and when some experience with this approach to repairing most primary groin hernias has been obtained.[8,9]

The preperitoneal approach to the management of recurrent groin hernias is a new application that appears to be gaining popularity. There are several reasons for this newfound enthusiasm for the preperitoneal approach. These include the ability to dissect through fresh unscarred tissue and the concept that, anatomically, the buttress is more properly situated than the prosthetic mesh "patch" placed from the anterior approach. In addition, long-term follow-up study of a variety of other approaches to repairing recurrent hernia has revealed that re-recurrences occur in as many as 19% of patients.[1-3]

The approach to the preperitoneal region may be made through a midline or a Pfannenstiel incision, and is the preferred method of a number of European authors.[10-12] We continue to use an incision lateral to the rectus muscle on the affected side. Early in our experience with primary repair of the recurrent hernias from the posterior aspect by the use of monofilament sutures alone, we noted an excessively high incidence of re-recurrences, especially of direct hernias. Because we believed that these recurrences were not related primarily to technical inadequacy of the repair, but were caused by a combination of the aging process and disturbed collagen metabolism,[13] we turned to the use of a reinforcing prosthetic mesh buttress repair to provide additional support and strength to the repair. Earlier problems encountered with placement of the mesh (the one indirect recurrence of the hernia as well as the ventral hernias at the wound of entry) have disappeared with placement of the mesh lateral to the spermatic cord and covering the wound of entry. Since the adoption of these newer techniques in 1982, no recurrences were seen in the short- to medium-term, the overall re-recurrence rate being 1.7% for patients seen at follow-up examinations. This experience was mirrored by a number of extensive European studies in which a prosthetic mesh buttress was placed in the preperitoneal position, without, however, direct repair of the hernial defect itself.[11,12]

Greenburg[8] and Read[14] of the United States have reported similar results with the preperitoneal approach to the repair of recurrent inguinal hernias—a 9.4% and a 4.3% incidence of recurrence, respectively. Little use, however, was made of a prosthetic mesh buttress in those latter two series. When mesh was used, the buttress was applied to reinforce the closed hernial defect, or when this could not be accomplished, to form the posterior wall of the inguinal canal itself. It could be argued, on the basis of our data, that routine use of the posterior mesh buttress would have eventuated in even lower recurrences rates for the patients of both Greenburg and Read.

Factors believed to result in recurrent groin hernias include missed hernias, low ligation of the sac, method of hernia repair, the type of suture used, placement of sutures under tension, wound infections, and advanced age.[1,15,16] These facts, together with the viewpoint that recurrence may result from a localized mesenchymal metabolic defect with abnormalities in collagen synthesis and breakdown,[13] have reinforced our view that something more than direct approximation of the weakened posterior wall of the inguinal region should be applied to the repair if repeated recurrences are to be avoided. In this context, therefore, the use of a prosthetic mesh buttress to strengthen the repair of recurrent hernias seems not only justified, but desirable. Of extreme interest are the results of European studies in which the prosthetic mesh buttress is placed in the preperitoneal position without the need for direct approximation of the native attenuated transversalis fascia.[11,12] No recurrences have been observed in these series after short-term follow-up periods. Other authors, however, favor the selective use of the prosthetic mesh buttress, and have achieved comparable results with the use of the native tissues to effect a repair.[8,9,14] We believe that our approach offers the best of both circumstances: the proximate cause of the hernial recurrence is attacked directly and repaired with endogenous tissues, and at the same time, the risk of repeated recurrences is obviated by the skillful placement of the prosthetic mesh buttress in the preperitoneal position.

Conclusion

The preperitoneal approach to the management of recurrent hernias of the groin with the appropriate use of a reinforcing mesh buttress is safe, allows anatomic definition of the hernial defect in a field that has not been operated on, is followed by minimal patient morbidity, and has a low re-recurrence rate. The evolution of this technique over the last 10 years has made it our procedure of choice for the management of all recurrent groin hernias.

Acknowledgments

We thank Ms. Catherine Judge for editorial assistance and Ms. Patricia Merced for typing the manuscript.

References

1. Rutledge RH. Cooper's ligament repair: a 25-year experience with a single technique for all groin hernias in adults. Surgery 1988; 103:1–10.
2. Quillinan RH. Repair of recurrent inguinal hernia. Am J Surg 1969; 118:593–595.
3. Marsden AJ. Inguinal hernia, a three-year review of two thousand cases. Br J Surg 1962; 216:384–394.

4. Nyhus LM, Condon RE, Harkins HN. Clinical experience with preperitoneal hernial repair for all types of hernia of the grcin. Am J Surg 1960; 100:234–244.
5. Nyhus LM. The preperitoneal approach and iliopubic tract repair of inguinal hernia. *In* Nyhus LM, Condon RE, eds. Hernia, 3rd ed. Philadelphia: JB Lippincott Company, 1989; 154–177.
6. Nyhus LM, Stevenson JK, Listerud MB, Harkins HN. Preperitoneal herniorraphy: a preliminary report in fifty patients. West J Surg Obstet Gynecol 1959; 67:48–54.
7. Glassow F. The Shouldice hospital technique. Int Surg 1986; 71: 148–153.
8. Greenburg AG. Revisiting the recurrent groin hernia. Am J Surg 1987; 154:35–38.
9. Malangoni MA, Condon RE. Preperitoneal repair of acute incarcerated and strangulated hernia of the groin. Surg Gynecol Obstet 1986; 162:65–67.
10. Rosenthal D, Walters MJ. Preperitoneal synthetic mesh placement for recurrent hernia of the groin. Surg Gynecol Obstet 1986; 163: 285–286.
11. Rignault DP. Preperitoneal prosthetic inguinal hernioplasty through a Pfannenstiel approach. Surg Gynecol Obstet 1986; 163:465–468.
12. Van Damme JPJ. A preperitoneal approach in the prosthetic repair of inguinal hernia. Int Surg 1985; 70:223–226.
13. Peacock EE Jr, Madden JW. Studies on the biology and treatment of recurrent inguinal hernia. II. Morphological changes. Ann Surg 1974; 179:567–571.
14. Read RC. Recurrence after preperitoneal herniorraphy in the adult. Arch Surg 1975; 110:666–671.
15. Pietri P, Gabrielli F. Recurrent inguinal hernia. Int Surg 1986; 71: 164–168.
16. Postlethwaite RW. Recurrent inguinal hernia. Ann Surg 1985; 202: 777–779.