
Clinicohistopathologic and Immunohistochemical Studies of Intrapancreatic Development of Carcinoma of the Head of the Pancreas

AKIMASA NAKAO, M.D., TOHRU ICHIHARA, M.D., TOSHIKI NONAMI, M.D., AKIO HARADA, M.D., TAKASHI KOSHIKAWA, M.D.,* NOBUO NAKASHIMA, M.D.,† HIROSHI NAGURA, M.D.,‡ and HIROSHI TAKAGI, M.D.

Clinicohistopathologic and immunohistochemical studies of intrapancreatic development of duct cell carcinoma of the head of the pancreas to the body and tail were done in 34 cases in which total pancreatectomy accompanied by portal vein resection were performed from July 1981 to June 1987. In studies of hematoxylin and eosin (HE) staining, intrapancreatic development from the head to the body or tail was observed in 14 cases of 34 cases (41.1%). Multicentricity or skip development was observed in two of 14 cases. However, by using immunostaining of carcinoembryonic antigen (CEA), carbohydrate antigen 19-9 (CA19-9) and DUPAN2, small cancer nests surrounded by dense fibrous connective tissues could be easily and accurately diagnosed, and finally, in 25 of 34 cases (73.5%), intrapancreatic continuous development from the head to body or tail was observed. The intrapancreatic development correlated with portal invasion and perineural invasion of carcinoma, hardness of body and tail, obstruction of the main pancreatic duct, and irregular pancreaticogram. The intraoperative quick immunostaining on the cryostat sections, together with HE staining, is useful to determine the intrapancreatic development of the carcinoma. The indication of total pancreatectomy or pancreatoduodenectomy for carcinoma of the head of the pancreas can be determined by these results.

THE INDICATION for total pancreatectomy (TP) or pancreatoduodenectomy (PD) for pancreatic head carcinoma has not yet been clarified. It is important to diagnose the intrapancreatic development of pancreatic head carcinoma to the body and tail before or during the operation. Usually pancreatic head carcinoma has severe chronic pancreatitis by the obstruction of the main pancreatic duct due to carcinoma invasion, so it is difficult to find small cancer nests in dense fibrous connective tissue of the body and tail. To solve this problem, clinicohistopathologic and immunohistochemical studies of intrapancreatic development of duct cell car-

From the Second Department of Surgery, the First Department of Pathology, the Department of Laboratory Medicine,† and Research Institute for Disease Mechanism and Control,‡ Nagoya University School of Medicine, Nagoya, Japan*

cinoma of pancreatic head to the body and tail were performed in 34 cases of TP.

The relationship between pre- or intraoperative clinical findings and the intrapancreatic development of pancreatic head carcinoma was also studied.

Materials and Methods

Ninety-six operations for pancreatic cancer were performed from July 1981 to June 1987 at the second Department of Surgery, Nagoya University School of Medicine, and in 61 of these cases, radical pancreatectomy was carried out (Table 1). Of 52 resected cases of pancreatic head carcinoma, 35 patients have undergone TP and 17 have undergone PD. Of the TP cases, 34 were duct cell carcinomas and one was an islet cell carcinoma. Twenty-five of the 34 patients who had duct cell carcinoma of the pancreatic head of TP accompanied by portal vein resection were men, and nine were women. The mean age of these 34 patients was 61 years.

Ten per cent formalin was injected promptly into the main pancreatic duct of surgically resected specimens, after which x-ray studies of the pancreaticogram were done. After 7 days of fixation of specimens by 10% formalin, specimens were sectioned into 5-mm thicknesses based on general rules of the Japan Pancreas Society.¹ Seven or more sections were prepared from one block. After being deparaffinized, these sections were stained with HE. All histologic typing of pancreatic carcinomas were based on the criteria of the Japan Pancreas Society.¹ Intrapancreatic development of the carcinoma (DVL) is has three patterns:

Reprint requests and correspondence: Akimasa Nakao, M.D., Second Department of Surgery, Nagoya University School of Medicine, 65 Tsurumai-cho, Showa-ku, Nagoya 466, Japan.

Submitted for publication: June 27, 1988.

TABLE 1. Resectability Rate of Pancreatic Cancer Patients from July 1981 to June 1987

Location	Patients	Operation	Resection	Resectability rate
Head	80	76	52 (46)	68.4%
Body and tail	18	17	8 (5)	47.0%
Whole	3	3	1 (1)	33.3%
Total	101	96	61 (52)	63.5%

Number of portal vein resections given in parentheses.

1) no evidence of intrapancreatic development of the carcinoma from the primary tumor mass (-), 2) evidence of continuous development of the carcinoma from the primary tumor mass (+c), and 3) evidence of skip development of the carcinoma from the primary tumor mass (+s).

Immunohistochemistry

The adjacent deparaffinized sections were stained by the indirect immunoperoxidase methods, as previously described.^{2,3}

The following antisera were used: 1) anti-CEA (DAKO, Kyowa Medex, Tokyo, Japan), previously absorbed with perchloric acid extract of human spleen at 1:200 dilution;² 2) anti-CA19-9 (Centocor, Toray-Fuji Bionix, Tokyo, Japan),⁴ diluted to 1:200; 3) anti-DUPAN2 (DAKO, Kyowa Medex, Tokyo Japan),⁵ diluted to 1:400.

Clinical Classification

Clinical findings were classified in terms of maximum tumor size (T), lymph node involvement (N), invasion to the portal vein (V), endoscopic retrograde pancreaticogram (ERP), pancreaticogram of the body and tail of

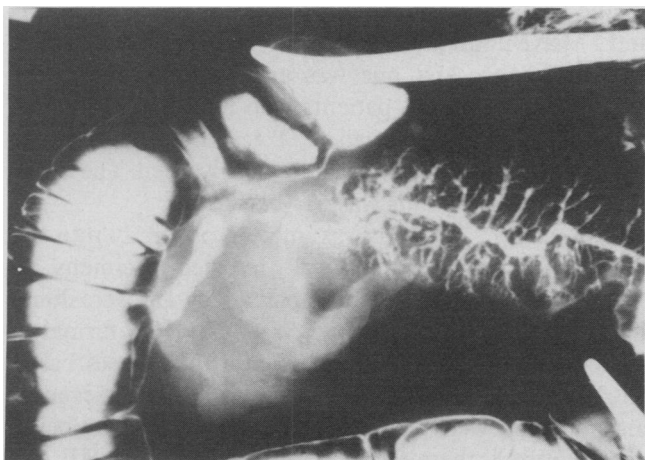


FIG. 1. Regular pattern of pancreaticogram. The main pancreatic duct is obstructed, but a relatively smooth main pancreatic duct with well-visualized branches is observed.

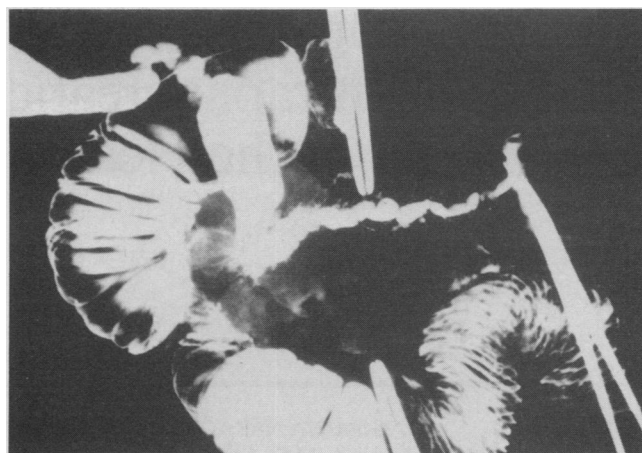


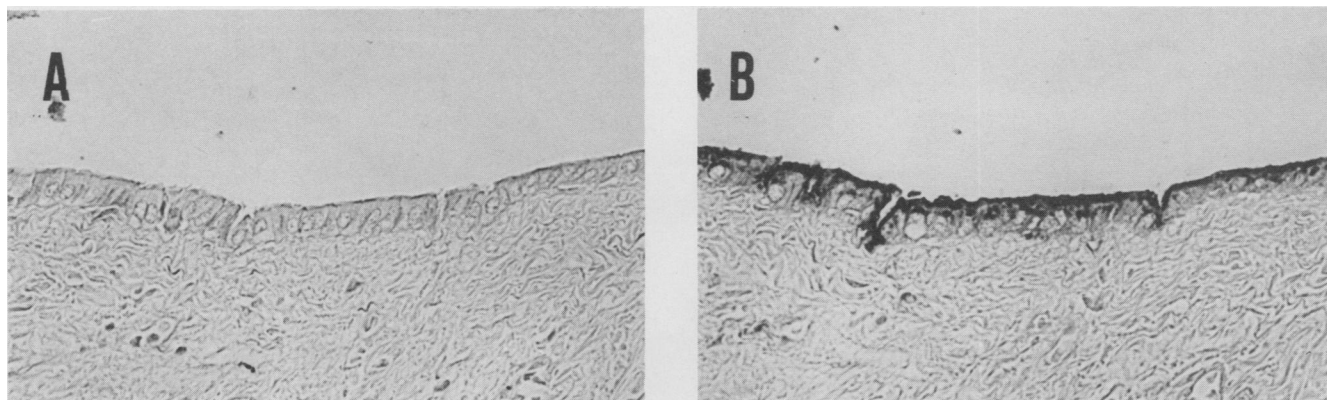
FIG. 2. Irregular pattern of pancreaticogram. The main pancreatic duct is obstructed, and irregular beaded pattern of main pancreatic duct with decrease of branches is observed.

specimens and hardness of the body and tail of the pancreas. Maximum tumor size was classified into four grades; 0–2 cm (T₁), 2.1–4 cm (T₂), 4.1–6 cm (T₃) and more than 6 cm (T₄). The carcinoma invasion to the portal vein was also classified into four grades; no evidence of carcinoma invasion to the portal vein (V₀), suspicious of carcinoma invasion to the portal vein (V₁), evidence of carcinoma invasion to the portal vein (V₂) and severe carcinoma invasion to the portal vein with stenosis or obstruction (V₃). ERP was classified by Ohashi et al.⁶ as narrowing or obstruction of main pancreatic duct (I), Wirsung's duct obstruction (IIA), Santorini's duct obstruction (IIB), polypoid or mucinous carcinoma in the markedly dilated main pancreatic duct (III), and no involvement of main pancreatic duct (IV). Pattern of the pancreaticogram of the pancreatic body and tail was classified into regular pattern (R) and irregular pattern (I). Regular pattern means smooth or regular beaded main pancreatic duct with well-visualized branches (Fig. 1). Irregular pattern means irregular beaded or rigid contour main pancreatic duct with decrease or absence of branches (Fig. 2). Hardness of the body and tail of the pancreas was classified into three group: soft (S), elastic hard (E) and hard (H).

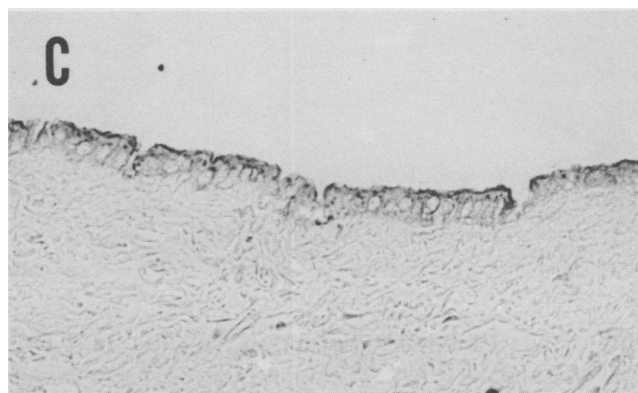
The correlation between clinical finding and intrapancreatic development of the pancreatic head carcinoma into the body and tail was studied.

Results

The authors have already reported on the relationship between the classification of duct hyperplasia based on Kozuka's classification⁷ and the localization pattern of CEA, CA19-9³ and DUPAN2.⁸ In normal pancreatic ducts, CEA is negative (type-N) or localized faintly on the apical surface (type-A, Fig. 3A) and CA19-9 (Fig. 3B)



FIGS. 3A-C. CEA, CA19-9, and DUPAN2 in normal pancreatic ducts. CEA (A) is negative and CA19-9 (B) and DUPAN2 (C) are localized on apical surface of the cells and in the supranuclear regions of the cytoplasm as fine granules.



and DUPAN2 (Fig. 3C) are localized on apical surface of the cells and in the supranuclear regions of the cytoplasm as fine granules [cytoplasmic type with polarity, type-C(+)]. In some papillary hyperplasia, CEA is demonstrated at the apical surface and in the cytoplasm near apical membrane [type-C(+)]. In atypical or malignant cells, these antigens were localized over the entire surface and cytoplasm (cytoplasmic type without polarity, type-C(-); see Figure 4). In most malignant glands, they were distributed diffusely in the surrounding stroma adjacent to the basal surfaces of the cells and in the phagocytes, in addition to the type-C(-) staining pattern (stromal type, type-S; see Figure 5). Type-S was restricted to cancer cells. If more than one of these three antigens showed the characteristics of the staining pattern in the sections of the specimen of cancer cells as described above, we diagnosed the specimen as "cancer positive tissue."

Pathologic diagnosis, clinical classification, and intrapancreatic development of carcinoma from the head to body or tail of 34 cases of duct cell carcinoma of the pancreatic head of TP with portal vein resection are summarized in Table 2.

In the observation of HE-stained tissue sections of these 34 cases, the intrapancreatic carcinoma development from the head to the body or tail was observed in 14 of 34 cases (41.2%), and skip development was observed in two of

14 cases. However, by immunostaining, small cancer nests surrounded by dense fibrous connective tissues could be easily detected (Fig. 6) and intrapancreatic continuous carcinoma development from the head to the body or tail was observed in 25 of 34 cases (73.5%) and no skip development was observed (Table 2).

The relationship between carcinoma development and clinical findings was observed in portal invasion, obstruction of main pancreatic duct, irregular pancreaticogram, and hardness of the body and tail (Table 2). These cases had commonly severe perineural invasion of carcinoma in the intra-pancreatic nerves or peripancreatic nerve plexus.

Discussion

A number of authors have reported that intrapancreatic development of pancreatic head carcinoma beyond the transection line of a usual Whipple procedure is observed in 2.4–36% of cases.⁹⁻¹⁹ The incidence of multicentricity or skip development was reported as being between 0–33%. Usually, by the obstruction of the main pancreatic duct due to carcinoma invasion, pancreatic head carcinoma has severe chronic pancreatitis, so it is sometimes difficult to differentiate severe inflammatory lesions from the malignancy glands. But we have already reported on

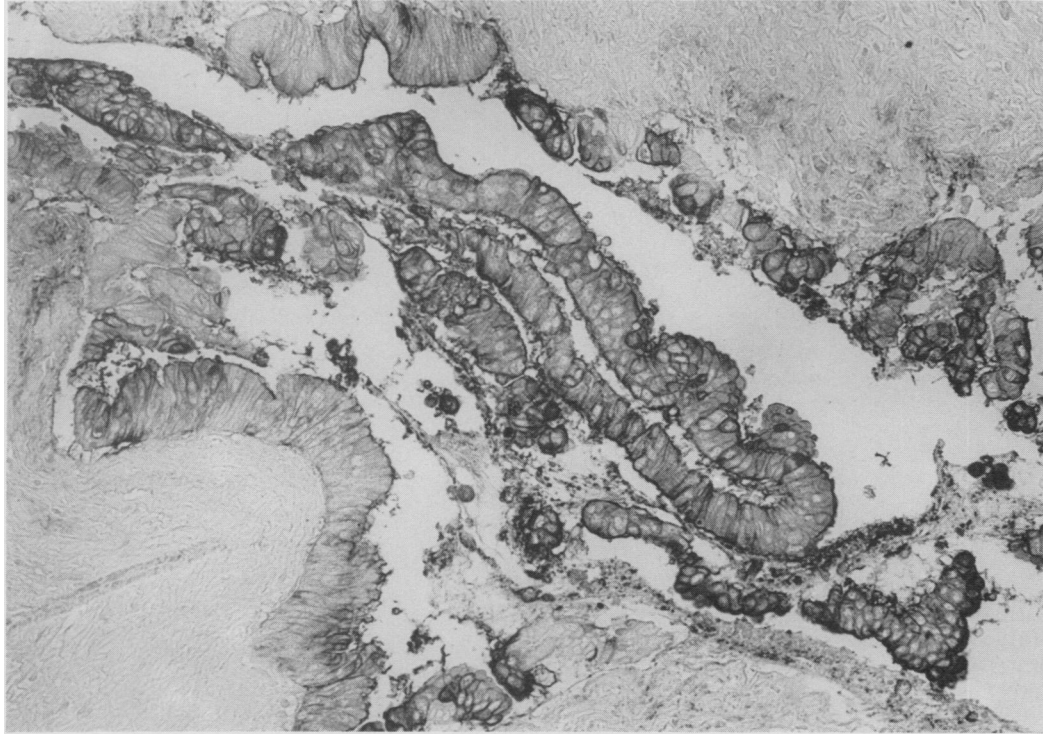


FIG. 4. CEA in atypical hyperplasia. CEA is localized over the entire surface and in the cytoplasm.

immunohistochemical localization patterns of CEA, CA19-9³ and DUPAN2⁸ in pancreatic duct epithelium and the stromal staining was restricted to the carcinoma glands. Therefore it has become easy to detect small cancer

nests in dense fibrous connective tissues of the body and tail. However, CA19-9 has the disadvantage of becoming negative in Lewis^a negative cases.³ Nevertheless, DUPAN2 was well-stained even in CA19-9 negative cases⁸ and im-

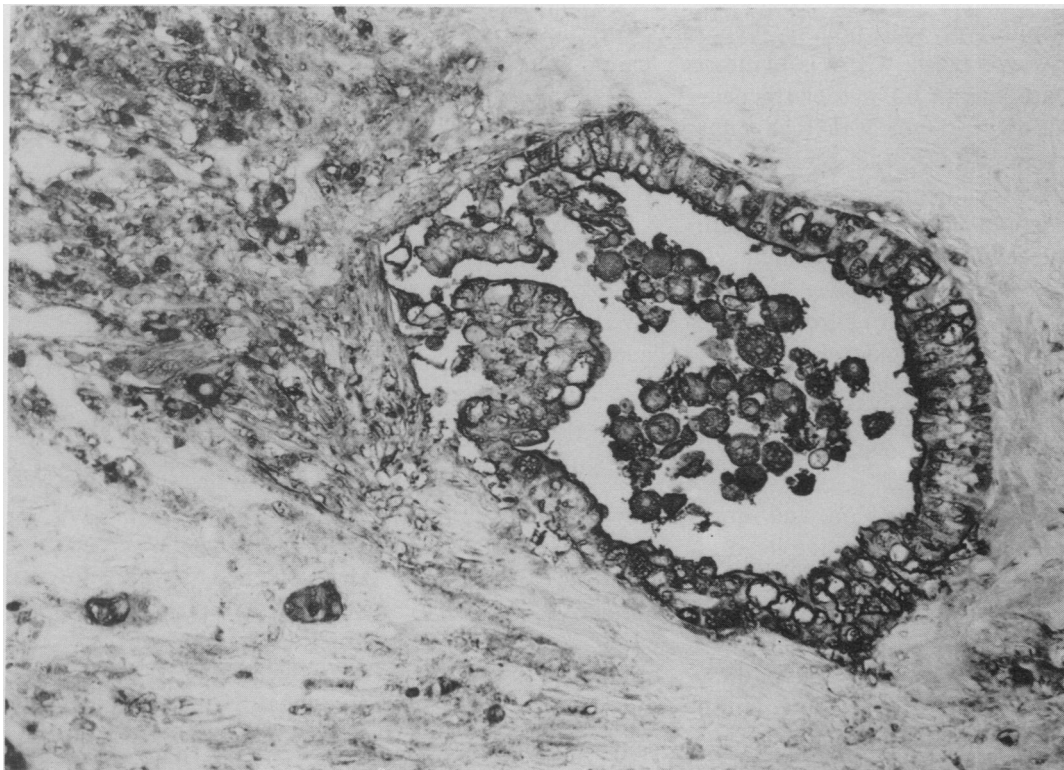


FIG. 5. CA19-9 in malignant glands. CA19-9 is distributed not only over the entire surface and cytoplasm of the carcinoma cells, but also diffusely in the surrounding stroma adjacent to their basal surfaces and in the phagocytes.

TABLE 2. 34 Cases of Duct Cell Carcinoma of the Head of the Pancreas of Total Pancreatectomy

Patient No.	Sex	Age	Histology	T	N	V	ERP	Pancreaticogram	Hardness	dvl	
										HE	IS
1	M	47	tub., mod.	2	+	2	I	I	H	+c(t)	+c(t)
2	F	64	pap-tub.	3	-	2	I	R	H	-	+c(t)
3	F	63	tub., poor.	3	+	3	I	I	H	+s(t)	+c(t)
4	M	68	tub., poor.	3	+	0	I	R	E	-	-
5	F	62	tub., well	2	+	2	IIB	R	E	-	-
6	M	75	tub., mod.	3	-	1	I	R	E	-	-
7	M	59	tub., poor.	3	+	3	I	I	H	-	-
8	M	61	tub., well	3	+	2	I	I	E	-	+c(b)
9	M	53	pap-tub.	2	+	0	IIB	R	E	-	-
10	M	55	pap-tub.	2	-	2	I	R	E	-	-
11	F	60	tub., mod.	2	+	2	I	I	H	-	-
12	F	63	tub., mod.	3	+	0	I	I	H	-	+c(t)
13	M	64	tub., well	2	+	3	I	I	E	+c(b)	+c(b)
14	M	55	pap.	3	+	1	III	I	S	+c(b)	+c(b)
15	F	49	tub., well	2	+	0	I	I	E	-	+c(b)
16	M	74	tub., mod.	2	+	1	IIA	R	S	-	-
17	M	52	tub., mod.	2	+	2	I	I	H	+s(b, t)	+c(t)
18	M	51	tub., mod.	3	+	3	I	I	H	+c(t)	+c(t)
19	M	61	tub., mod.	3	+	1	IIB	I	E	+c(b)	+c(b)
20	M	58	tub., well	2	+	3	I	I	H	+c(b)	+c(t)
21	M	50	tub., well	3	-	1	I	I	E	-	-
22	M	72	tub., well	3	-	3	I	I	E	-	+c(t)
23	M	65	tub., mod.	3	+	2	I	I	H	+c(t)	+c(t)
24	M	55	tub., mod.	3	+	1	I	R	E	-	-
25	M	55	tub., well	3	-	3	I	I	H	+c(t)	+c(t)
26	M	67	tub., mod.	3	+	3	I	I	H	+c(t)	+c(t)
27	M	70	tub., mod.	3	+	2	I	I	E	-	+c(b)
28	F	62	tub., well	2	+	2	I	I	H	+c(t)	+c(t)
29	M	70	pap-tub.	2	-	1	I	I	H	+c(t)	+c(t)
30	F	59	tub., mod.	2	+	1	I	I	E	-	+c(t)
31	M	63	tub., mod.	2	+	2	I	I	E	-	+c(b)
32	F	67	tub., mod.	4	+	3	I	I	H	+c(t)	+c(t)
33	M	69	tub., mod.	3	-	3	I	I	H	+c(t)	+c(t)
34	M	54	tub., mod.	3	+	3	I	I	H	+c(b)	+c(t)

tub = tubular adenocarcinoma; pap = papillary adenocarcinoma; well = well differentiated type; mod = moderately differentiated type; poor = poorly differentiated type; HE = hematoxylin and eosin staining; IS

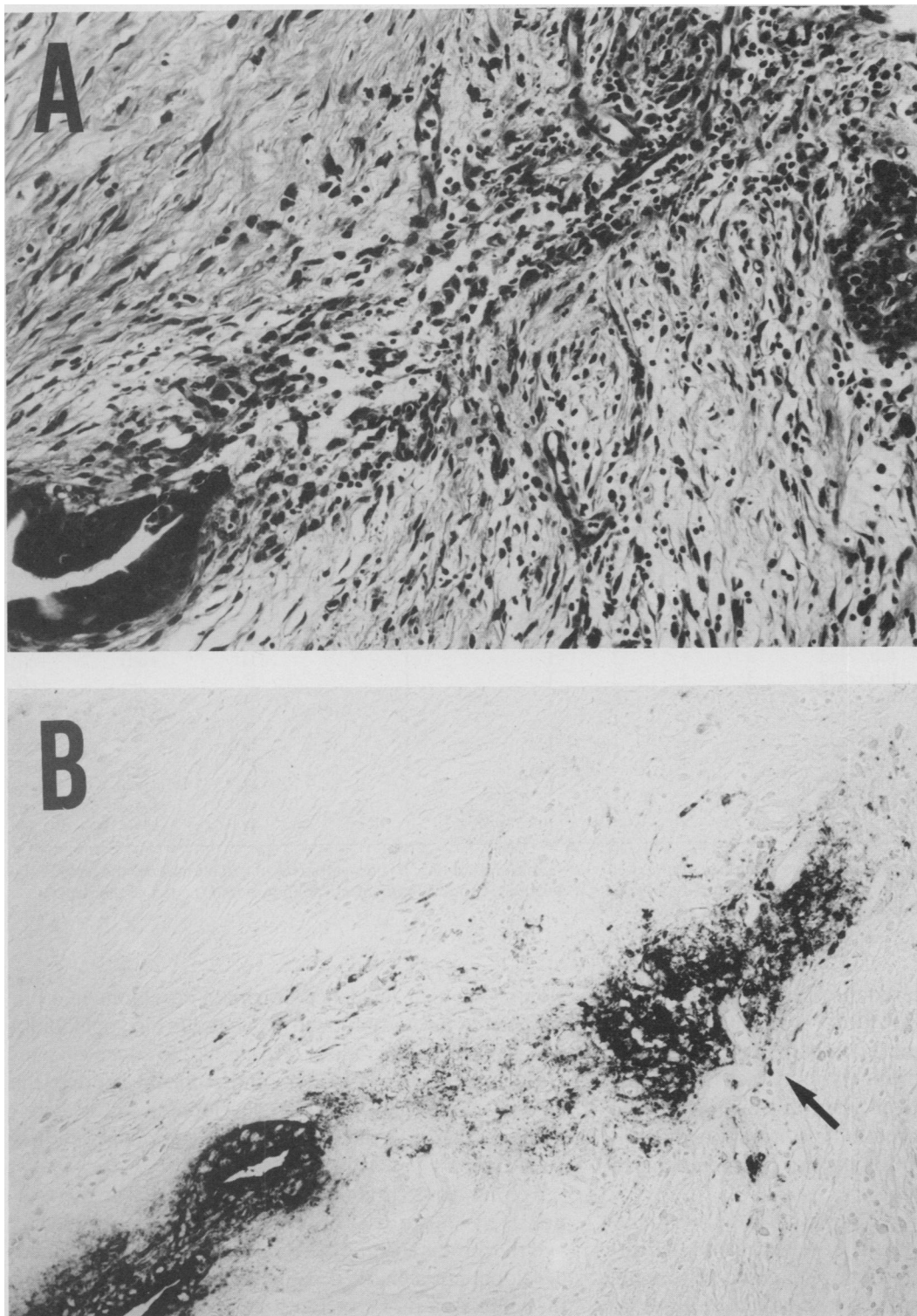
= immunostaining; b = development of carcinoma into the body of the pancreas; t = development of carcinoma into the tail of the pancreas.

munohistochemically showed no cross reactivity with Lewis^a. On the other hand, CA19-9 was usually positive in a DUPAN2 negative case. Thus, combined use of both antigens seems to act complementarily to each other. CEA is also useful because almost all pancreatic duct carcinoma tissues can be stained as stromal type, as reported previously in CEA immunostaining pattern in carcinomas of gastrointestinal (G.I.) tracts.²⁰⁻²²

Using the conventional HE staining method, we found two cases of skip development; however, using the immunostaining method, these cases were observed as being continuous. Moreover, the incidence of cancer development detected actually increased from 41.2% to 73.5%, and skip development was not observed when the immunostaining method was used. There have been many reports on the multicentricity or skip development of the pancreatic cancer^{9-12,14-18}, but it seems to us that intrapancreatic development in those cases might not have been capable of being detected with HE stained findings

alone. Our high incidence of cancer development from the head to the body and tail is due to the high operability rate using extended radical operations²³ to advanced pancreatic carcinoma. And our results do not support the view that multicentric or skip development of the carcinoma of the head of the pancreas occurs relatively frequently.

For surgeons, it is important to make clear the relationship between pre- or intraoperative clinical findings and the intrapancreatic cancer development. If the cancer development is clarified before or during the operation, the indication of TP or PD for the pancreatic head carcinoma can be determined. Medical technology for the diagnosis of pancreatic cancer has progressed remarkably, but it is difficult to diagnose the intrapancreatic cancer development before the operation. In our department, ultrasonography (US), computed tomography (CT), ERP, percutaneous transhepatic bile duct drainage (PTBD) for the patients with obstructive jaundice, and celiac and su-



FIGS. 6A and B. (A) In the HE-stained section, it is difficult to point out malignant lesions, but in the adjacent immunostained section of CA19-9 (B), the strong immunoreactivity of CA19-9 in the small group of malignant cells and their surrounding stroma (type-S) can be easily detected (arrow).

perior mesenteric angiography have been performed routinely for the pancreatic cancer patients before the operation and the portography and pancreaticography by the puncture of the main pancreatic duct of the body and tail during the operation. By the retrospective studies of these

clinical findings, main pancreatic duct obstruction, portal invasion, hardness of the body and tail, and irregular pancreaticogram had the relation to cancer development from the head to body and tail. Therefore these clinical characteristics are helpful in deciding the indication of TP or

PD for the pancreatic head carcinoma. But the definitive diagnosis of cancer development is done by the rapid intraoperative conventional HE staining of frozen sections at the line of resection. Sometimes diagnosis of their development to the body and tail is hard to evaluate by fibrosis and sparse malignant cell density. Moreover, frozen sections have poorly preserved tissue structure as compared to the usual formalin fixed paraffin-embedded permanent sections, and this makes the suitable judgment more difficult. So we have recently developed quick immunostaining,²⁴ using the same antibodies on the frozen sections, and this, in addition to rapid intraoperative conventional HE staining, will provide important information.

In summary, by the immunohistochemical staining using CEA, CA19-9 and DUPAN2 in addition to conventional HE staining, the intrapancreatic development of the pancreatic head carcinoma from the head to the body and tail can be diagnosed more precisely. From our data, the degree of incidence with skip development of pancreatic cancer seems to be negligible. And the intrapancreatic cancer development from the head to body and tail can be generally diagnosed by the clinical findings such as hardness of the body and tail with main pancreatic duct obstruction, portal invasion, and irregular pancreaticogram by the intraoperative puncture of the main pancreatic duct. But the definitive diagnosis can be made more precisely by the intraoperative quick immunostaining, in addition to rapid intraoperative conventional HE staining. The indication of TP or PD can be determined by these results.

Acknowledgments

The authors are grateful to the staff doctors in the hospitals affiliated with the Second Department of Surgery, Nagoya University School of Medicine, for their generosity and cooperation during the course of this study.

References

1. Japan pancreas Society. General Rules for Cancer of the Pancreas, 3rd ed. Tokyo: Kanehara Shuppan, 1986.
2. Tsutsumi Y, Nagura H, Watanabe K. Immunohistochemical observations of carcinoembryonic antigen (CEA) and CEA-related substances in normal and neoplastic pancreas. *Am J Clin Pathol* 1984; 82:535-542.
3. Ichihara T, Nagura H, Nakao A, et al. Immunohistochemical localization of CA19-9 and CEA in pancreatic carcinoma and associated diseases. *Cancer* 1988; 61:324-333.
4. Koprowski H, Steplewski Z, Mitchell K, et al. Colorectal carcinoma antigens detected by hybridoma antibodies. *Somatic Cell Genet* 1979; 5:957-972.
5. Metzgar RS, Gaillard MT, Levine SJ, et al. Antigens of human pancreatic adenocarcinoma cells defined by murine monoclonal antibodies. *Cancer Res* 1982; 42:601-608.
6. Ohashi K, Maruyama M, Yokoyama Y, et al. New classification of ERCP findings of pancreatic cancer. *Gastroenterology* 1981; 8: 1241.
7. Kozuka S, Sassa R, Taki T, et al. Relation of pancreatic duct hyperplasia to carcinoma. *Cancer* 1979; 43:1418-1428.
8. Suzuki Y, Ichihara T, Nakao A, et al. High serum levels of DUPAN2 antigen and CA19-9 in pancreatic cancer: correlation with immunocytochemical localization of the antigens in cancer cells. *Hepatogastroenterology* 1988; 35:128-135.
9. Collins JJ Jr, Craidhead JE, Brooks JR. Rationale for total pancreatectomy for carcinoma of the pancreatic head. *New Engl J Med* 1966; 74:599-602.
10. Plaim MB, Remine WH. Further evaluation of total pancreatectomy. *Arch Surg* 1975; 110:506-512.
11. Fortner JG, Kim DK, Cubilla A, et al. Regional pancreatectomy: en bloc pancreatic, portal vein, and lymph node resection. *Ann Surg* 1977; 186:42-50.
12. Ihse I, Lilja P, Arnesj B, et al. Total pancreatectomy for cancer: an appraisal of 65 cases. *Ann Surg* 1977; 186:675-680.
13. Matsui Y, Aoki Y, Ishikawa O, et al. Ductal carcinoma of the pancreas. Rationale for total pancreatectomy. *Arch Surg* 1979; 114: 722-726.
14. Tryka AF, Brooks JR. Histopathology in the evaluation of total pancreatectomy for ductal carcinoma. *Ann Surg* 1979; 190:373-381.
15. Edis AJ, Kiernan PD, Taylor WF. Attempted curative resection of ductal carcinoma of the pancreas. Review of Mayo Clinic experience, 1951-1975. *Mayo Clin Proc* 1980; 55:531-536.
16. Cooperman AM, Herter FP, Marboe CA, et al. Pancreatoduodenal resection and total pancreatectomy: an institutional review. *Surgery* 1981; 90:707-712.
17. Piorkowski RJ, Blievernicht SW, Lawrence W Jr, et al. Pancreatic and periampullary carcinoma: experience with 200 patients over a 12-Year period. *Am J Surg* 1982; 143:189-193.
18. van Heerden JA. Pancreatic resection for carcinoma of the pancreas: Whipple versus total pancreatectomy—an institutional perspective. *World J Surg* 1984; 8:880-888.
19. Klöppel G, Lohse T, Besslet K, Rucket K. Ductal adeno-carcinoma of the head of the pancreas: incidence of tumor involvement beyond the Whipple resection line. Histological and immunocytochemical analysis of 37 total pancreatectomy specimens. *Pancreas* 1987; 2:170-175.
20. Ahnen DJ, Nakane PK, Brown WR. Ultrastructural localization of carcinoembryonic antigen in normal intestine and colon cancer: abnormal distribution of CEA on the surface of colon cancer cells. *Cancer* 1982; 49:2077-2090.
21. Nagura H, Tsutsumi Y, Shioda Y, Watanabe K. Immunohistochemistry of gastric carcinomas and associated diseases: novel distribution of carcinoembryonic antigen and secretory component on the surface of gastric cancer cells. *J Histochem Cytochem* 1987; 31:193-198.
22. Hamada Y, Yamamura M, Hioki K, et al. Immunohistochemical study of carcinoembryonic antigen in patients with colorectal cancer: correlation with plasma carcinoembryonic antigen levels. *Cancer* 1985; 55:136-141.
23. Nakao A, Kondo T, Mori Y. A new technique of radical pancreatectomy by Anthron® bypass catheter of portal vein. *Artificial Organs* 1983; 7(A):109.
24. Ichihara T, Nakao A, Sakamoto J, et al. An application of the immunoperoxidase method for rapid intraoperative pathological diagnosis of pancreatic cancer. *J Surg Oncol* (in press).