

## Comment

The pathophysiology of alveolitis is often uncertain, and several mechanisms have been implicated. We consider the most likely cause in this case to have been a hypersensitivity reaction to amiodarone, similar to those reported for nitrofurantoin, hexamethonium, busulphan, and many other drugs. Other possibilities considered were rheumatoid interstitial lung disease, collagen vascular disease, or an autoimmune disorder. Rheumatoid factor and antinuclear factor were, however, not detected, and the immunoglobulin concentration was normal. There was no other evidence of collagen vascular disease. Early viral pneumonia may sometimes present this picture but viral serological findings were normal.

Amiodarone, initially introduced for angina, is now recognised as a useful antiarrhythmic agent which acts by slowing conduction velocity.<sup>1</sup> Its half life is long, and a plateau of drug accumulation may not be reached for over a month. Reported side effects include heart block, corneal microdeposits, alteration of thyroid function, photosensitivity, potentiation of anticoagulants, and, rarely, neuropathic symptoms.<sup>2,3</sup> Most are infrequent but corneal change in adults receiving long-term treatment is common.<sup>4</sup> That a pulmonary reaction may occur after the administration of amiodarone was proposed by Rotmensch *et al.*<sup>5</sup>

The absence of other identifiable causes of the alveolitis in this case, its close temporal relations to amiodarone, and its rapid response to corticosteroids strongly suggest that amiodarone was the cause. Furthermore, the manufacturers of amiodarone (Labaz) have received at least five separate reports of similar associated pulmonary reactions in Britain in addition to a similar number in the USA. The Committee on Safety of Medicines has received four reports, including the present one.

<sup>1</sup> Singh BN, Vaughn-Williams EM. The effect of amiodarone, a new anti-arrhythmic drug, on cardiac muscle. *Br J Pharmacol* 1970;**39**:657.

<sup>2</sup> Marcus FI, Fontaine GH, Frank R, Grosogeat Y. Clinical pharmacology and therapeutic applications of the antiarrhythmic agent amiodarone. *Am Heart J* 1981;**101**:480.

<sup>3</sup> Rees A, Dalal JJ, Reid PG, Henderson AH, Lewis MJ. Dangers of amiodarone and anticoagulant treatment. *Br Med J* 1981;**282**:1756.

<sup>4</sup> D'Amico DJ, Kenyon KR, Ruskin JN. Amiodarone keratopathy, drug-induced lipid storage disease. *Arch Ophthalmol* 1981;**99**:257-61.

<sup>5</sup> Rotmensch HH, Liron M, Tupilski M, Laniado S. Possible association of pneumonitis with amiodarone therapy. *Am Heart J* 1980;**100**:412-3.

(Accepted 16 September 1981)

### Killingbeck Hospital, Leeds LS14 6QU

S A RILEY, MB, CHB, senior medical house officer  
S E WILLIAMS, MD, MRCP, senior medical registrar  
N J COOKE, BSC, MRCP, consultant physician

## Epileptiform seizures and electroencephalographic abnormalities as manifestations of digoxin toxicity

Poisoning by cardiac glycosides may give rise to neurological side effects, particularly headache, malaise, drowsiness, confusion, and psychosis.<sup>1</sup> Convulsions may complicate acute massive digoxin overdosage, but only a single case report,<sup>2</sup> of a patient in whom plasma digoxin concentration was not measured, directly relates epilepsy and electroencephalographic abnormalities to the clinical syndrome of chronic digoxin toxicity. We describe a patient who developed epileptiform seizures and electroencephalographic abnormalities in association with digoxin poisoning confirmed by measurements of plasma digoxin concentration. Electroencephalographic abnormalities and epileptiform activity persisted while the plasma digoxin concentration remained in the toxic range and resolved only when the concentration returned to therapeutic values.

### Case report

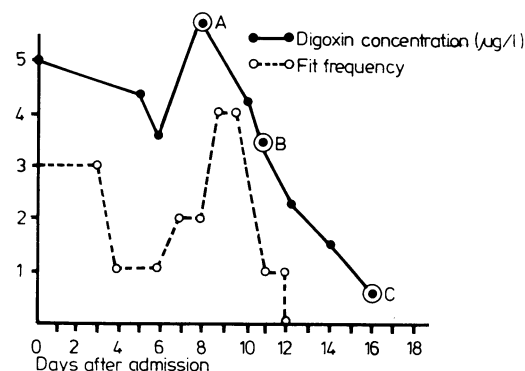
A 64-year-old woman with angina, atrial fibrillation, and rheumatic valvular disease presented with features typical of digoxin toxicity including bradycardia, xanthopsia, nausea, and vomiting. She also complained of "funny turns," which had first occurred during the week before admission. In hospital these were observed to have a fairly constant pattern of clouding

of consciousness, total disorientation, lip-smacking, and coarse tremor of all limbs. Initially the episodes occurred about five times daily, each lasting three to five minutes. Her prescribed treatment comprised digoxin 0.1875 mg daily, which was immediately withdrawn, and sublingual glyceryl trinitrate, which she was allowed to take as required.

Plasma digoxin concentration was 5.0 µg/l, confirming toxicity. Despite the withdrawal of prescribed digoxin and in the presence of only mild renal impairment (creatinine clearance 33 ml/min; serum potassium concentration 4.2 mmol(mEq)/l) the plasma digoxin concentration declined only to 3.4 µg/l after one week (figure), during which time she continued to have epileptiform episodes. Electroencephalography showed spike and wave activity and a generalised slow wave pattern consistent with a metabolic/epileptiform process.

Epileptiform episodes continued and plasma digoxin concentrations rose to 5.8 µg/l. Occult digoxin consumption was the obvious explanation, and a search of her property showed that her glyceryl trinitrate bottle contained two different types of white tablet, most being digoxin 0.25 mg. Once or twice daily she had been taking sublingual digoxin to relieve her angina.

Removal of this digoxin "treatment" resulted in a satisfactory fall in digoxin concentrations, a reduced frequency of epileptiform events and normal electroencephalographic appearances (figure).



A Rhythmic spike and wave activity at 2-2½ cycles/s  
Sensitivity: 70 µm/cm

B Episodes of paroxysmal delta activity  
Sensitivity: 70 µm/cm

C Improvement towards normality  
electromyographic activity superimposed on cerebral rhythms  
Sensitivity: 50 µm/cm

Profile of plasma digoxin concentration and frequency of observed daily fits with associated electroencephalographic appearances at 5.8 µg/l (A), 3.6 µg/l (B), and 0.7 µg/l (C).

### Comment

Toxicity occurs in about 20% of adult patients taking maintenance digoxin treatment<sup>3</sup> and is usually associated with plasma digoxin concentrations of 2.0-4.0 µg/l.<sup>4</sup> Convulsions may complicate acute intoxication with non-therapeutic doses of digoxin, and epileptiform activity may also be a feature of the clinical syndrome of chronic digoxin toxicity. In our patient the electroencephalographic disturbance was maximal when the plasma digoxin concentration exceeded 5.0 µg/l, and the gradual improvement in the electroencephalogram coincided with the fall in plasma digoxin concentration, as did the frequency of observed epileptiform episodes. There is thus sufficient reason to suspect that digoxin poisoning induced epileptiform activity in this patient; interestingly, the encephalographic disturbance featured slow spike and wave activity comparable with that reported previously.<sup>2</sup>

Digoxin enters the central nervous system, where it may be measured in the cerebral cortex and choroid plexus,<sup>5</sup> and we postulate that the inhibition of Na<sup>+</sup>/K<sup>+</sup> adenosinetriphosphatase activity induced by cardiac glycosides will interfere with the function of all

electrically excitable tissue, including neurones. This may be a dose-dependent phenomenon, however, the patient usually presenting with the more typical neurological features before a sufficiently toxic concentration is achieved. Additionally the brain of the elderly or "arteriosclerotic" patient may possibly be predisposed to the development of digoxin-induced convulsions; the previous case report described a 72-year-old man.

Transient cerebral ischaemic episodes may, therefore, only partially account for the blackouts seen in elderly patients taking digoxin, and we recommend that, even when there is no gross disturbance of cardiac rhythm, the serum digoxin concentration be measured to exclude digoxin neurotoxicity.

- 1 Goodman LS, Gilman (eds) A. *Digitalis and allied cardiac glycosides*. In: *The pharmacological basis of therapeutics*. 5th ed. New York: Macmillan Publishing Co, 1975:653-82.
- 2 Douglas EF, White PT, Nelson JW. Three per second spike-wave in digitalis toxicity. *Arch Neurol* 1971;**25**:373-5.
- 3 Lely AH, van Enter CHJ. Non-cardiac symptoms of digitalis intoxication. *Am Heart J* 1972;**83**:149-52.
- 4 Sarangi A, Tripathy N, Lall D, Patnaik BC, Swain AK. Study of serum digoxin status in digitoxicity by radioimmunoassay. *Am Heart J* 1980;**99**:289-93.
- 5 Bertler A, Anderson KE, Wethrell G. Concentration of digoxin in choroid plexus. *Lancet* 1973;ii:1453.

(Accepted 15 September 1981)

**Department of Materia Medica, University of Glasgow, Stobhill General Hospital, Glasgow G21 3UW**

D J KERR, MB, CHB, house physician (present appointment: senior house officer in medicine, Western Infirmary, Glasgow)

H L ELLIOTT, MB, MRCP, lecturer

W S HILLIS, MB, FRCP, senior lecturer

## "Home brew" compared with commercial preparation for enteral feeding

Enteral feeding is the most appropriate route for administering protein and energy to malnourished patients when the gastrointestinal tract is capable of normal absorption.<sup>1</sup> The enteral route is safer and considerably cheaper than total parenteral nutrition.<sup>2</sup> Enteral feeding is well tolerated provided it can be delivered by continuous slow nasogastric or nasoduodenal infusion, thereby avoiding the problems of hyperosmolar diarrhoea and the reluctance by some convalescent patients to take a liquid diet by mouth. Commercially available enteral solutions are expensive, however, and it has been argued that a liquid diet of similar protein and energy content can be prepared by most diet kitchens. We compared a blenderised diet based on milk albumin hydrolysate, Caloreen, and Prospal ("home brew") with a commercially available enteral preparation containing the same protein and calorie content (Isocal) in 28 patients requiring nutritional treatment after major gastrointestinal surgery. Method of treatment was determined by numbered randomisation cards.

### Patients, methods, and results

Any patient unable or unwilling to take nutrients by mouth after a major gastrointestinal operation associated with complications was admitted to the study. Patients who required jejunostomy feeds or intermittent positive pressure ventilation were excluded. Indications for feeding included: gastrectomy complicated by wound dehiscence; abscess or a duodenal fistula (n = 8); reconstructive gastric operations in patients malnourished before operation (n = 10); resection for colorectal carcinoma complicated by fistula or abscess (n = 6); and resection for inflammatory bowel disease associated with intra-abdominal sepsis (n = 4). Nutritional treatment was given for at least seven days by fine-bore nasogastric tube positioned under radiographic control. During the first 48 hours the tube feed was diluted and administered at increasing volume until the patient was able to tolerate the full strength solution at a rate of 125 ml per hour.<sup>3</sup> Fifteen patients received Isocal and 13 the "home brew" (table). Diarrhoea occurred in nine patients, two after Isocal, but one had antibiotic-associated colitis and the other a pelvic abscess. Two of the seven patients with diarrhoea receiving the "home brew" had a pelvic abscess but in the remaining five patients the intestinal disturbance was so severe that the enteral feeding had to be discontinued.

### Comparison of commercial feed and "Home Brew" enteral feeding

	Commercial feed (Isocal) (n = 15)	"Home brew" (n = 13)
Severe diarrhoea	2	7
Pelvic abscess	1	2
Antibiotic associated colitis	1	
Infected solution		4
No cause identified		1
Obstructed fine bore tube		6

Cultures of the solutions in these patients yielded yeasts in three and *Staphylococcus aureus* in one. Intermittent obstruction of the fine-bore tube was a problem in six patients who were given the "home brew" but in none receiving Isocal.

### Comment

Our observations cast doubt on the safety and efficacy of liquid diets prepared in hospital. Contamination by yeasts and staphylococcus occurred at weekends when the materials had been prepared earlier and stored on the wards. Fine-bore feeding tubes often became obstructed by the locally prepared solutions and in some patients the fine-bore tube had to be replaced by a conventional nasogastric tube, which was unpleasant for the patients. The study was discontinued because the nurses found the locally prepared solutions difficult to administer at a constant rate of infusion, and because of the risks of infection observed in the study. We believe, therefore, that commercially available liquid diets are safer and easier to handle if fine-bore enteral feeding is to be used for patients requiring nutritional support after major gastrointestinal operations.

<sup>1</sup> Russell RI. Elemental diets. *Gut* 1975;**16**:68-79.

<sup>2</sup> Blackett RL, Bakran A, Bradley LA, Halsall A, Hill GL, McMahon MJ. A prospective study of subclavian vein catheters used exclusively for the purpose of intravenous feeding. *Br J Surg* 1978;**65**:393-5.

<sup>3</sup> Sagar S, Harland P, Shields R. Early postoperative feeding with elemental diet. *Br Med J* 1979;i:293-5.

(Accepted 6 October 1981)

### The General Hospital, Birmingham B4 6NH

M R B KEIGHLEY, MS, FRCS, consultant surgeon/reader in surgery

BARBARA MOGG, AIMS, research technician

SANDRA BENTLEY, SRN, research nurse

CAROLINE ALLAN, SRN, ward sister

## Gastrointestinal haemorrhage and benoxaprofen

Benoxaprofen is a non-steroidal anti-inflammatory agent similar to naproxen and ibuprofen but which has a lower incidence of gastrointestinal disturbance<sup>1</sup> and produces less gastric microbleeding.<sup>2</sup> During three months three patients who had been receiving benoxaprofen were admitted to a general medical unit with gastrointestinal haemorrhage associated with peptic ulceration.

### Case reports

*Case 1*—A 76-year-old woman was admitted three weeks after starting benoxaprofen 600 mg daily for osteoarthritis, mainly in her right leg. She had no past history of dyspepsia and no family history of peptic ulceration. Within a week of taking the drug she began to feel nauseated and on the day of admission had a large haematemesis. She was seriously ill and the haemoglobin concentration was 8.0 g/dl. Endoscopy showed multiple ulcers in the duodenum and a large gastric ulcer. Despite resuscitative measures, including blood transfusion, she deteriorated further; abdominal films showed pneumoperitoneum. At an emergency operation the duodenal ulcer was seen to have perforated and the peritoneal cavity contained 2 l of bile-stained fluid. The perforation was sealed but she failed to improve and died on the eighth postoperative day.

*Case 2*—A 76-year-old woman was admitted six weeks after starting benoxaprofen 600 mg daily for osteoarthritis. She had no past history of dyspepsia. Within two weeks of taking the drug she complained of nausea