

## SHORT REPORTS

## Screening and counselling of school-leavers for the carrier state of hereditary anaemias

Antenatal diagnosis of genetic diseases has sharpened interest in the discovery of symptomless carriers under childbearing age. This is true of the haemoglobinopathies and may well spread to other conditions. In the past attempts at population screening have met with a mixed reception and involved both technical and counselling problems.<sup>1-4</sup>

A pilot study was carried out as part of the normal health education given to schoolchildren in the fifth form, mostly 16-year-olds. These young adults were old enough to understand the counselling and also close to the onset of childbearing age. The counselling could be done individually in a familiar school atmosphere and reinforced during classes on health education.

## Subjects, methods, and results

An inner city comprehensive school in Luton was chosen because of its high proportion of children of immigrant families. A class of 124 was given a talk after an introduction by the head teacher. Forms were given to each child asking for the ethnic origin of each parent, whether they were cousins, whether there was a family history of severe anaemia, and requesting parental consent to examine a blood sample. The children were selected for screening on the basis that one or both parents belonged to an ethnic group at risk of haemoglobinopathy and glucose-6-phosphate dehydrogenase deficiency.

## SCREENING FOR HAEMOGLOBINOPATHIES

A 4-ml sample of venous blood was obtained for Coulter Model S profile, screening for glucose-6-phosphate dehydrogenase deficiency, haemoglobin electrophoresis, and blood group analysis. A sickle test and fetal haemoglobin estimation were performed on selected specimens. Three additional specimens were assayed for ferritin. Specimens from two Asian girls who complained of pain in their legs were tested for biochemical confirmation of rickets.

The results of screening are given in the table. From the total of 124, 80 subjects were selected for counselling and 50 attended. Of these, 18 boys and 11 girls were Asians, three-quarters of the Asian group attending for counselling. Nine boys and six girls were West Indians, only one-third of this ethnic group attending. Two subjects were Chinese, three Italian (two boys and one girl), and one was of mixed Italian and Greek origin.

## COUNSELLING

The haematological abnormalities which were found in a quarter of the group could be divided into acquired abnormalities, treatment of which could be beneficial, and inherited abnormalities, which were harmless to the individual but of genetic significance (see table).

## Haemoglobinopathies found by screening of 124 schoolchildren of different ethnic origins

Diagnosis	No of subjects	Ethnic origin
Sickle-cell trait .. .. .	2	Negro
HbC trait .. .. .	1	Negro
HbE trait .. .. .	1	Asian
$\alpha$ -thalassaemia trait .. .. .	4	Asian
$\beta$ -thalassaemia trait .. .. .	0	
Glucose-6-phosphate dehydrogenase deficiency	2	Negro
Iron deficiency .. .. .	2	Negro (1), Asian (1)
Macrocytosis .. .. .	1	Asian*
Total .. .. .	13	

\*This girl and her sister also had adolescent rickets.

Counselling was given in the school medical room by one of us (EHL). Each person was seen individually (except on one occasion when two girls asked to be seen together) and was told that he or she was a carrier of a trait, emphasising that this would cause no symptoms. The possibility of the disease state existing in 1 in 4 children was illustrated by a simple diagram of two parents who were carriers. The techniques of antenatal diagnosis were explained and a short written account of the verbal counselling was

given to each child to take home for future reference and for the information of the parents. In addition, the children took home the laboratory result, which they were instructed to give to their family doctor. Glucose-6-phosphate dehydrogenase deficiency was explained and a list of drugs to be avoided handed to the relevant subjects. Those with iron deficiency anaemia were given dietary advice and told to go to their family doctor for treatment.

All except one girl accepted the counselling well. They seemed to understand the genetic implications and the help that was available. The remainder of the class were not told who the affected people were. The girl (of West Indian origin) who was upset by the information became surly and withdrawn; she was already known to be a dull difficult girl with an unhappy home background.

## Comment

We think this screening and counselling service could be integrated into the general health education programme in schools where there are large numbers of children of non-English origin, since the cost is small. The factors necessary to make the service work are enthusiasm from the school doctor and health education teacher and a helpful haematology laboratory at the district general hospital. We also recommend that all Asian girls could be screened biochemically for subclinical adolescent rickets.

We wish to thank Mrs V Mitchell-Rawles, OBE, head teacher, Beech Hill High School, Luton, for her help.

Further details of laboratory technique can be obtained from Dr D S Thompson and those of counselling and organisation from Dr E de H Lobo.

<sup>1</sup> Whitten CF. Sickle cell programming, an imperiled promise. *N Engl J Med* 1973;288:318-9.

<sup>2</sup> Silvestroni E, Bianco I. Screening for thalassaemia. *Lancet* 1975;ii:1100.

<sup>3</sup> Modell B, Ward RHT, Fairweather DVI. Effect of introducing antenatal diagnosis on reproductive behaviour of families at risk for thalassaemia major. *Br Med J* 1980;280:1347-50.

<sup>4</sup> Stuart J, Schwartz FCM, Little AJ, Raene DN. Screening for abnormal haemoglobulins: a pilot study. *Br Med J* 1973;iii:284-7.

(Accepted 8 February 1982)

## Luton and Dunstable Hospital, Luton

E DE H LOBO, FRCP(E), DCH, consultant paediatrician  
D S THOMPSON, MB, MRCPATH, consultant haematologist

## Aplastic anaemia associated with fenoprofen

Fenoprofen is a widely prescribed non-steroidal anti-inflammatory propionic acid derivative used for osteoarthritis, rheumatoid arthritis, and ankylosing spondylitis. Reported haematological side effects include agranulocytosis,<sup>1,2</sup> thrombocytopenia,<sup>3,4</sup> and pure red-cell aplasia.<sup>5</sup> We report two cases, one fatal, of aplastic anaemia associated with fenoprofen.

## Case reports

*Case 1*—A 71-year-old woman was admitted to hospital with a two-week history of malaise, palpitations, dyspnoea, spontaneous bruising, and epistaxis and, for 48 hours, also haematuria and melaena. Ten months before admission she had noticed pain and stiffness in the fingers, wrists, shoulders, and knees and begun with fenoprofen 600 mg thrice daily; this was continued until admission. Other medications received in the time included paracetamol, dihydrocodeine, aspirin, and intra-articular hydrocortisone. On admission she was anaemic and feverish. There were petechiae over the forearms and legs and bleeding ulcers on the buccal mucosa. The liver was palpable 2 cm below the costal margin and the rectum contained melaena. There was no lymphadenopathy and the spleen was not palpable. Investigations showed haemoglobin concentration 5.7 g/dl, leucocyte count  $0.6 \times 10^9/l$  ( $600/mm^3$ ), neutrophils 15%, and platelet count  $10 \times 10^9/l$  ( $10\,000/mm^3$ ). Sternal bone marrow aspirate and iliac trephine biopsy showed hypocellular marrow with no red-cell or neutrophil precursors and no megakaryocytes. Tests for anti-nuclear factor, rheumatoid factor, and LE cells gave negative results. Plasma urea and electrolyte concentrations were normal. Despite vigorous treatment

with packed cells and platelet transfusions, oxymetholone, and antibiotics, she died 10 days after admission. Necropsy showed extensive haemorrhage into the brain, oesophagus, stomach, and bronchi.

**Case 2**—A 55-year-old woman was admitted with a two-week history of dyspnoea and excessive bruising. She had had seropositive rheumatoid arthritis for five years, for which she had been treated with prednisolone 2.5 mg daily for 18 months and fenopropfen 600 mg thrice daily for 14 months before admission. The only other medication was thyroxine, which she had taken for 18 years. On admission she was anaemic with generalised bruising and purpura. Haemoglobin concentration was 7.5 g/dl, leucocyte count  $3.3 \times 10^9/l$ , and platelet count  $5.0 \times 10^9/l$ . Bone marrow aspirate and trephine biopsy showed almost complete absence of red-cell precursors and megakaryocytes. Neutrophil precursors were present in greatly reduced numbers. Result of the latex test for rheumatoid arthritis was positive, but the test for antinuclear factor gave a negative result. Blood urea and results of liver function and Ham tests were normal. Fenopropfen was stopped and oxymetholone 300 mg daily begun. In the first month two separate transfusions of four units of packed red cells were required. During the next five months her haemoglobin concentration and leucocyte count progressively rose to within the normal range and remained normal when oxymetholone was stopped. There was only partial recovery of her platelet count to  $50 \times 10^9/l$ , usual after recovery from aplastic anaemia. Rechallenge with fenopropfen was not attempted.

### Comment

Other propionic acid derivatives have been associated with aplastic anaemia and possibly all such drugs are capable of causing this potentially fatal complication. In the cases described it seems that the aplastic anaemia was associated with fenopropfen.

We can find no other published case reports of aplastic anaemia associated with fenopropfen, but eight further cases (six fatal) are known to the Committee on the Safety of Medicines. In two of these (one fatal) the clinical circumstances suggested that fenopropfen was probably responsible for the blood dyscrasia. In the other six cases (five fatal) the adverse reaction was only possibly related to fenopropfen, as other drugs that also could have caused the aplastic anaemia had been prescribed.

We acknowledge the help of the Committee on the Safety of Medicines.

Requests for reprints should be addressed to: Dr R M Pearson, Harold Wood Hospital, Romford, Essex RM3 0BE.

- Simon SD, Kosmin M. Fenopropfen and agranulocytosis. *N Engl J Med* 1978;299:490.
- Treusch PJ, Woelke BJ, Leichtman D, Tucker R. Agranulocytosis associated with fenopropfen. *JAMA* 1979;241:2700-1.
- Simpson RE, Goldstein DJ, Hjelte GS, Evans ER. Acute thrombocytopenia associated with fenopropfen. *N Engl J Med* 1978;298:629-30.
- Katz ME, Wang P. Fenopropfen associated thrombocytopenia. *Ann Intern Med* 1980;92:262.
- Weinberger KA. Fenopropfen and red cell aplasia. *J Rheumatol* 1979;6:475.

(Accepted 27 January 1982)

Department of Medicine, Victoria Hospital, Worksop, Nottinghamshire S80 2BN

M ASHRAF, MB, senior house officer

R M PEARSON, MRCP, consultant physician (now at: Harold Wood Hospital, Romford, Essex RM3 0BE)

Department of Haematology, Derbyshire Royal Infirmary, Derby DE1 2QY

D A WINFIELD, MRCPATH, consultant haematologist

## Hypernatraemia after treatment of hydatid

We report a case of hypernatraemia presenting as septicaemia after removal of a hydatid cyst.

### Case report

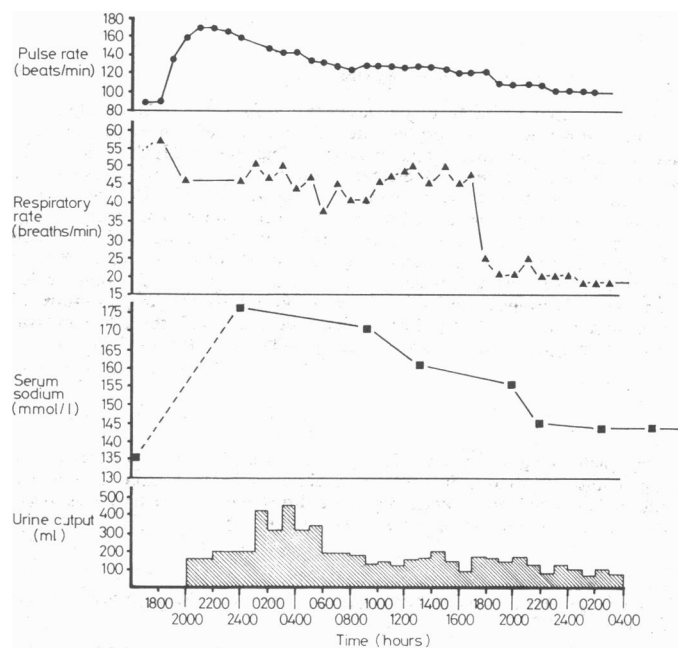
A 44-year-old man was admitted to hospital for removal of a hydatid cyst (5 cm diameter) from the liver. He had developed septicaemia a fortnight before admission and received antibiotics and dopamine infusion. At operation, however, he was symptom free and blood culture grew no patho-

gens. He had normal liver function and no evidence of hydatid disease anywhere else. The cyst was located ultrasonically beneath the surface of the right lobe of the liver. At laparotomy the area was carefully surrounded with packs before the cyst was aspirated. The cavity was then irrigated four times with 500 ml of 30% saline, followed immediately each time by careful suction aspiration. A drain was inserted before the wound was closed.

The operation lasted two and a half hours, and he recovered consciousness immediately afterwards. He had some pain, for which 0.6 mg buprenorphine was given intramuscularly. He became comfortable and mildly drowsy, with a systolic blood pressure of 110 mm Hg, heart rate 90 beats/min, and temperature 36.7°C. Forty-five minutes later his pulse rate rose to 140 beats/min and systolic blood pressure dropped to 90 mm Hg, with a central venous pressure of 22 cm H<sub>2</sub>O and a respiratory rate of 56 breaths/min; his urine output was 150 ml in the first hour. Two hours later his pulse rate had risen to 175 beats/min and his temperature to 38.3°C; blood pressure and respiration rate remained unchanged. He became semiconscious, responding only to painful stimuli.

He was transferred to the intensive care unit with a presumptive diagnosis of septicaemia. Blood was taken for culture, and he was given gentamicin, flucloxacillin, and metronidazole. Blood culture was later reported sterile. At this stage central venous pressure was 2 cm H<sub>2</sub>O and he was transfused with one unit of blood, 500 ml Haemaccel, and one litre of dextrose in saline. Results of chest x-ray examination were normal, while blood-gas analysis showed a hydrogen ion concentration of 50 nmol/l (pH 7.30), carbon dioxide pressure 3.5 kPa (26 mm Hg), oxygen pressure 10.3 kPa (77 mm Hg), and base excess -12 mmol(mEq)/l, supporting the diagnosis of septicaemia leading to acidosis. Serum sodium concentration was 176 mmol(mEq)/l. The infusion was therefore changed to 5% dextrose, in volume to balance the urine output, which remained around 250 ml/hour with no diuretics.

During the next 24 hours he was given 8 l of fluids and had a urine output of 5.4 l. His pulse, blood pressure, and respiration returned to normal and he was rousable. His urinary sodium concentration was 196 mmol(mEq)/l, and he excreted about 1000 mmol sodium over the first 30 hours. The figure gives details of the course of the condition.



Course of condition in patient studied.

Conversion: SI to traditional units—Sodium: 1 mmol/l = 1 mEq/l.

### Comment

This patient, who did not have any problems during or immediately after the operation, suddenly developed tachycardia and hyper-ventilation 45 minutes after operation. Septicaemia was suspected and he was treated accordingly. Hypernatraemia was not considered until the electrolyte results were available.

Thirty per cent saline is a recognised scolecocidal agent,<sup>1</sup> which has no reported complications and it has been used successfully in this hospital. Direct communications between hydatid cavities and biliary radicals are well documented.<sup>2</sup> We suggest that the cause of the hypernatraemia in this patient was absorption of 30% saline (about 200 ml) into the circulation via the duodenum.

Hypernatraemia causes cellular dehydration and leads to delirium and loss of consciousness. Clinical signs and symptoms are not well recognised, usually being masked by accompanying conditions<sup>3</sup> that