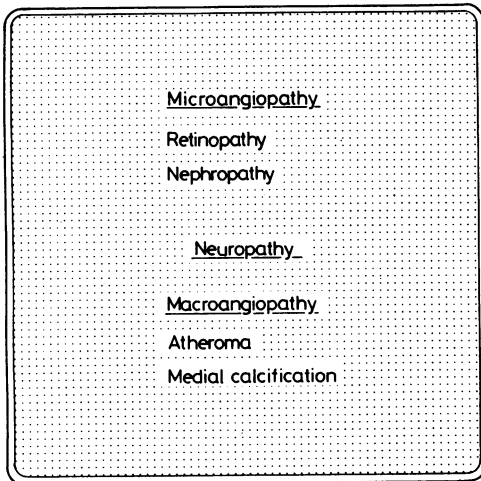


# ABC of Diabetes

PETER J WATKINS

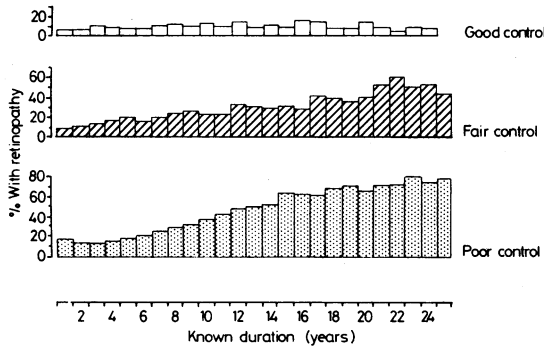
## DIABETIC COMPLICATIONS: RETINOPATHY



Patients with longstanding diabetes may develop complications affecting the eyes or kidneys (microvascular complications), nerves or major arteries.

The major arteries are affected by diabetes in two ways. Coronary artery disease is commoner in diabetics than in non-diabetics, especially young women with diabetes of long duration, in whom the prevalence of this disorder approaches that of men; this contrasts with the differential prevalence in non-diabetics, it being much commoner in men. The disease is otherwise no different from that seen in non-diabetics. There is also a very high prevalence of medial arterial calcification (Monckeberg's sclerosis) in longstanding diabetics, especially those with neuropathy. Its functional importance is uncertain.

### Pattern of microvascular complications

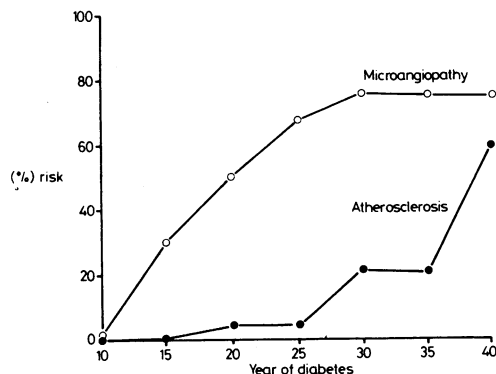


Adapted from Pirart J. *Diabete et Metabolisme* 1977, 3: 97-107, fig 10

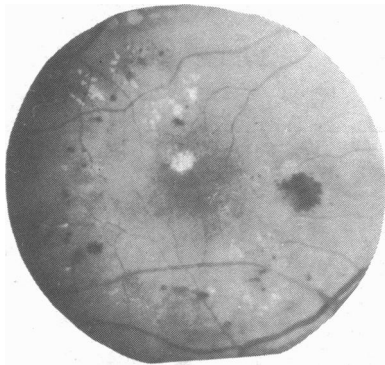The cause of the microvascular complications is not understood, but the most important influence is probably the quality of diabetic control over many years. There may also be a genetic influence, which can be detected in identical twins and in those non-insulin dependent diabetics positive for the chlorpropamide alcohol flush, who appear to be relatively spared. Fortunately not all diabetics develop these complications, and probably as many as a fifth are spared altogether even after 40 or 50 years of diabetes.

Curiously, both retinopathy and neuropathy may occur in isolation, but serious nephropathy is always accompanied by retinopathy and usually by neuropathy as well.

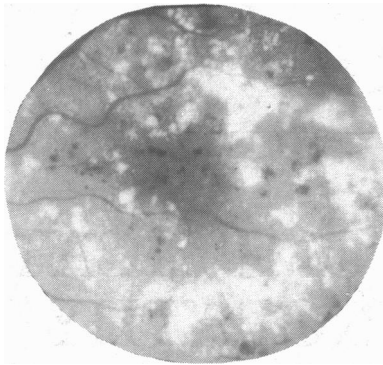
### Retinopathy



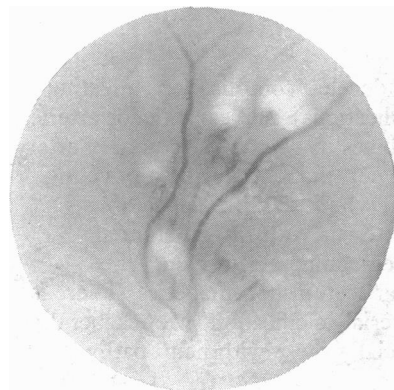After 20 years of diabetes about 80% of patients will have retinopathy. In many cases this is a mild background retinopathy which changes little over the years. Rather unpredictably, however, changes may develop which threaten vision, generally from macular disease or vitreous haemorrhage. Since treatment is now available which can prevent blindness, it is essential to identify the lesions which are amenable to treatment before vision deteriorates.



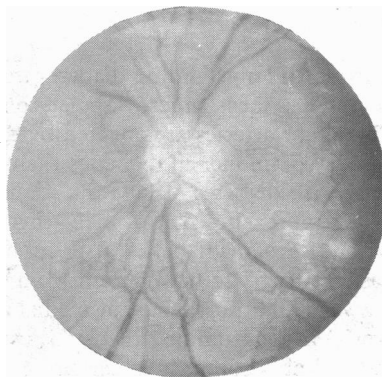
Background retinopathy: exudates encroaching on macula.



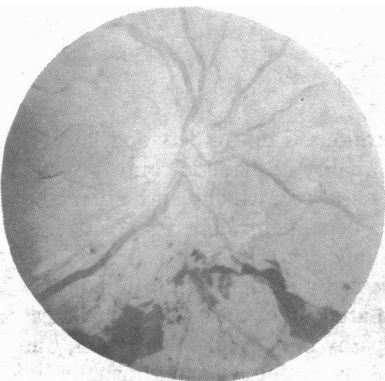Severe exudate retinopathy.



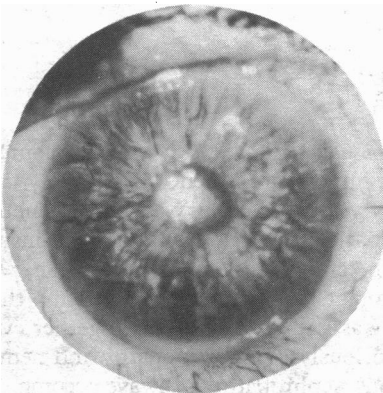
Cotton wool spots.



Disc new vessels.



Preretinal haemorrhages.



Rubeosis iridis.

### Background retinopathy

*Microaneurysms* appear as tiny red dots and represent small capillary aneurysms or bulges. They are abnormally permeable but by themselves not harmful.

*Haemorrhages* appear as small (dot) and large (blot) red spots on the retina. They are harmless unless they occur on the macula itself, when they can severely impair vision.

*"Hard" exudates*—These are yellow-white discrete patches which often occur in rings around leaking capillaries. They may coalesce to form extensive sheets of exudate. They cause blindness only when they occur in the macula.

*Maculopathy*—If hard exudates advance on to the macula vision gradually declines and blindness eventually develops. Macular oedema also causes blindness: it may develop quite rapidly. Its recognition is difficult, but its presence is suggested by a grey discoloration at the macula.

### Preproliferative lesions

Ischaemia of the retina probably predisposes to the development of dangerous formation of new vessels. An ophthalmologist should be consulted at this stage. The lesions are: (a) multiple cotton wool spots, which are indistinct and relatively large pale lesions, representing areas of capillary closure; (b) multiple large blot haemorrhages; (c) venous beading, loops, and reduplication; (d) arterial sheathing; and (e) atrophic-looking retina.

### Proliferative retinopathy

If there are peripheral new vessels the risk of serious vitreous haemorrhage is small, but new vessels on the disc are likely to develop. New vessels on the disc commonly bleed, causing preretinal haemorrhages and blindness from vitreous haemorrhage.

### Advanced diabetic eye disease

The signs of advanced diabetic eye disease are: vitreous haemorrhage; fibrous tissue, which may shrink and cause retinal detachment; and rubeosis iridis and glaucoma—new vessels spread to the anterior chamber and affect the iris (rubeosis iridis). If the new vessels obstruct the outflow from the anterior chamber a most painful form of glaucoma occurs, sometimes requiring enucleation.

## Causes of blindness in diabetics

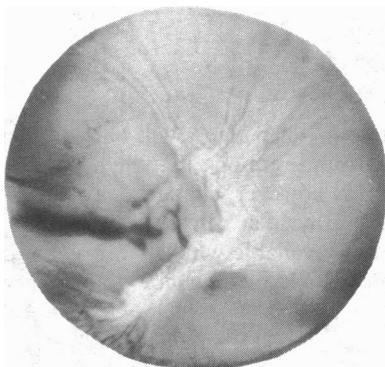
After 30 years of diabetes, about 7% of patients are blind: there are in all about 8000 registered blind diabetics in England and Wales, most being over 60 years old.

*Vitreous haemorrhage* from new vessels occurs suddenly, painlessly, and without warning, and blindness rapidly develops. Some clearing of the haemorrhage is likely over the following weeks but recovery of vision becomes progressively less likely after repeated haemorrhage.

*Maculopathy*—Exudates or oedema that directly affect the macula cause blindness. The onset is gradual over weeks or months, during which vision gradually deteriorates.

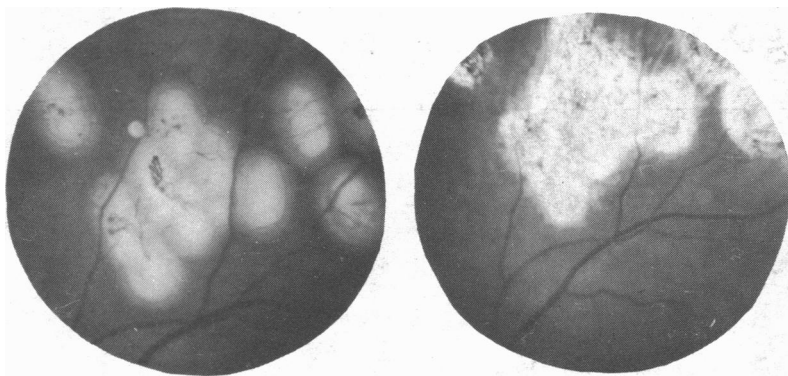Glaucoma and retinal detachment are other causes of blindness in diabetic retinopathy.

*The lens*—Lens opacities or cataracts probably develop more often in diabetics than in non-diabetics. There is a very rare form of rapidly developing cataract which occurs in some young patients.



Advanced eye disease with fibrosis.

## Prevention of blindness

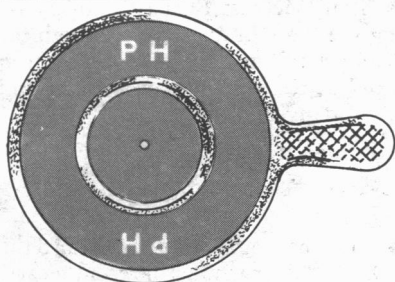
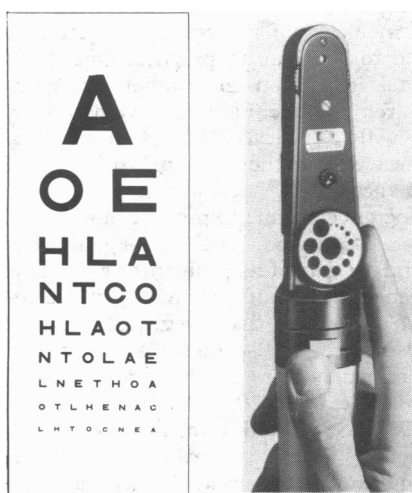


After a few days. Photocoagulation scars. After a few months.

Retinopathy needs to be actively sought by physicians because if it is detected early enough blindness can be prevented by light coagulation with xenon arc or argon laser. The indications for photocoagulation are: (a) the presence of new vessels on the disc. Sometimes new vessels peripheral to the disc are treated as well, especially if they become preretinal, because they often herald the development of vessels on the disc; (b) the development of maculopathy either by exudates or oedema: this should be treated when visual acuity begins to decline—that is, a decrease of one or two lines on the Snellen chart. Once visual acuity is less than 6/36 the treatment is of no value.

Surgical treatment of blindness, including vitrectomy, will not be discussed here.

## Clinical examination of the eyes



Routine examination of the fundi should be performed on all diabetics: the pupils should be dilated and examined, preferably in a darkened room. Pupils should not be dilated if there is any suspicion of glaucoma. Tropicamide (Mydracil) eye drops are recommended because the pupils recover from their action in two or three hours without the need for reversal with pilocarpine eye drops.

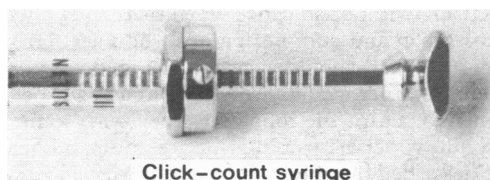
The fundi of all new diabetics should be examined. Ideally, visual acuity should be tested and a retinal examination performed each year. Examinations may be performed less often in short-term symptomless diabetics without known retinopathy. Once retinopathy is present examinations should be performed every 6 to 12 months or more often if indicated. If the dates and results of eye examinations appear in a prominent place in the records, it becomes a simple matter to decide on the date of follow-up examinations.

If the visual acuity is declining, exudates are encroaching on the macula, cotton wool spots (or other preproliferative changes) or early new vessels are present, frequent eye examinations are required and consultation with an ophthalmologist is essential.


It is simple to test visual acuity, and this should become a routine practice in diabetic clinics. Some clinics have arranged for annual visual tests (and sometimes fundal examination as well) to be undertaken by local ophthalmic opticians or ophthalmic medical practitioners willing to collaborate in this form of assessment. This scheme is very promising and could become an important part of diabetic care.

Refraction may be performed by viewing the testing chart through a "pin hole" if patients have not brought their glasses.

## The blind diabetic



Click-count syringe



Once blind, the patient should register with the local authority because some amenities and a little financial help are available. Rehabilitation is available for suitable patients at the Royal National Institute for the Blind centre at Torquay, and some blind diabetics are helped by guide dogs. Printing in Braille is valuable but many diabetics cannot read it because of the impairment of fine sensation in their fingers. For insulin injections a preset syringe is available, but even more valuable is the click-count syringe (Hypoguard Ltd, Ipswich, Suffolk), in which each palpable click corresponds to a single mark on the syringe. Urine tests can be performed using Diastix together with a Hypotest instrument, which gives an audible signal corresponding to the amount of glycosuria.

I thank Mr G W G Davies and Mr C Clements for their help in obtaining photographs of diabetic retinopathy. The photographs of the click-count syringe and Hypotest meter are reproduced by permission of Hypoguard Ltd. The third illustration is reproduced, with permission, from *Kidney International* 1974;6:55.

Dr Peter J Watkins, MD, FRCP, is consultant physician, Diabetic Department, King's College Hospital, London.