

## PAPERS AND SHORT REPORTS

## Pulmonary hypertension and fenfluramine

J G DOUGLAS, J F MUNRO, A H KITCHIN, A L MUIR, A T PROUDFOOT

### Abstract

**Pulmonary hypertension developed in two women who had been taking fenfluramine for over eight months for weight reduction. On withdrawing the drug symptoms and electrocardiographic evidence of pulmonary hypertension disappeared in both cases. In one patient, however, the evidence recurred after rechallenge with fenfluramine.**

**These findings are strong evidence that fenfluramine may cause pulmonary hypertension. Hence any patient taking the drug should report immediately any deterioration in exercise tolerance.**

### Introduction

Fenfluramine is an anorectic drug widely prescribed for obesity. Adverse effects include dry mouth, drowsiness, lethargy, nausea, diarrhoea, nightmares, and depression, particularly after sudden withdrawal.<sup>1,2</sup> Aminorex fumarate, which is chemically related, has been associated with pulmonary vascular hypertension<sup>3,4</sup> but there are no reports implicating fenfluramine. We describe two patients in whom pulmonary hypertension was associated with fenfluramine.

### Case 1

A 26-year-old nurse presented in May 1975 with a two-month history of increasing breathlessness and tiredness. She had had two episodes of exertional syncope together with mild exertional chest

pain and by the time of admission was unable to walk more than 50 m on the flat. In 1964 and 1969 she had been admitted for diarrhoea secondary to chronic ulcerative pancolitis and since then had received courses of iron for recurrent anaemia. For nine months before admission she had been taking fenfluramine 160 mg daily, having completed an 18-month course only six months before the start of the second course. One month before—that is, about four weeks after her symptoms began—she had also started an oral contraceptive (norethisterone 1 mg and mestranol 0.05 mg per tablet). She had not taken any oestrogen or progesterone preparation before.

On admission she weighed 61 kg and had bilateral ankle oedema. Jugular venous pressure was raised 3 cm and a right ventricular heave was noted. The pulmonary second sound was greatly accentuated, and a soft ejection systolic murmur was audible at the lower left sternal edge. The electrocardiogram showed right axis deviation with P pulmonale and changes compatible with right ventricular hypertrophy and strain (fig 1). A chest x-ray picture showed prominence of the main pulmonary arteries but the heart shadow was normal. Lung volume measurements were normal but the  $TC_{10}$  was reduced to  $5.01$  mmol/min/kPa ( $14.96$  ml/min/mm Hg) (predicted normal  $8.79 \pm 1.44$  mmol/min/kPa;  $26.24 \pm 4.30$  ml/min/mm Hg). A perfusion lung scan using  $^{99m}Tc$  macroaggregates and a ventilation scan using  $^{133}Xe$  were normal. Right heart catheterisation showed the pulmonary artery pressure to be raised at 50/20 (mean 32) mm Hg, but the mean "wedge" pressure was only 9 mm Hg. Pulmonary angiography showed slight enlargement of the main pulmonary arteries with possible exaggerated tapering of the pulmonary vasculature but with no abrupt vessel cut-off.

Fenfluramine and the oral contraceptive were stopped and she was given thiazide diuretics. Three weeks later her symptoms had disappeared and she was able to go dancing. The pulmonary second heart sound was less accentuated and no cardiac murmurs were audible. One year after presentation her chest x-ray picture had returned to normal and the electrocardiogram was within normal limits (fig 1). Repeat right heart catheterisation showed a pulmonary artery pressure of 19/5 (mean 11) mm Hg.

### Case 2

A 45-year-old housewife weighing 98.4 kg was referred for weight reduction in August 1978. One year before she had been given fenfluramine and lost 4.5 kg without obvious ill effects. She had regained weight, however, despite simple dietary restriction. Systematic inquiry and clinical examination showed nothing abnormal, blood pressure was 130/80 mm Hg, and a chest radiograph and electrocardiogram (fig 2) were normal. The serum thyrotrophin concentration

Medical Unit, Eastern General Hospital, Edinburgh EH6 7LN

J G DOUGLAS, MRCP, medical registrar

J F MUNRO, FRCPED, consultant physician

Cardiology Unit, Western General Hospital, Edinburgh EH4 2XU

A H KITCHIN, FRCPED, consultant cardiologist

Royal Infirmary, Edinburgh EH3 9YW

A L MUIR, FRCPED, consultant physician

A T PROUDFOOT, FRCPED, consultant physician

was raised at 16 mU/l and she had circulating thyroid antibodies. Thyroxine was started and increased to 0.2 mg daily, together with a carbohydrate-restricted diet. She did not lose weight, however, and by April 1979 weighed 100.2 kg. Fenfluramine was then prescribed and increased to 120 mg daily, and by October her weight had fallen to 90.7 kg. In December—35 weeks after starting fenfluramine—she noticed increased exertional breathlessness and palpitations, and by January 1980 she was unable to walk further than 20 m on the flat.

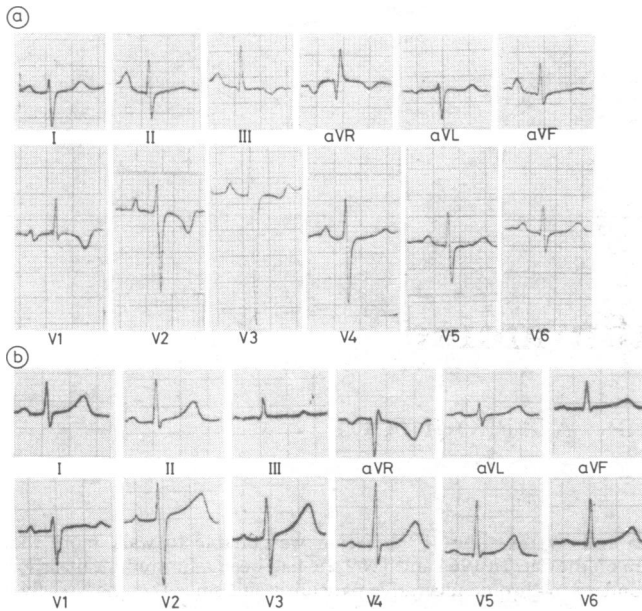


FIG 1—Case 1. Electrocardiograms (a) during treatment with fenfluramine (May 1975) and (b) one year later (May 1976).

Results of physical examination were normal apart from a blood pressure of 160/110 mm Hg. The electrocardiogram showed pronounced P pulmonale with T-wave inversion across V1-5, indicating acute right heart strain with no evidence of right ventricular hypertrophy (fig 2). The chest x-ray picture showed cardiomegaly. Fenfluramine was stopped, cardiac catheterisation three days later showed a pulmonary artery pressure of 56/28 (mean 37) mm Hg, and right ventricular pressure was 55/8-14 mm Hg. Left ventricular pressure was also raised (190/16-18 mm Hg), and left ventricular angiography was normal with an ejection fraction of 57% and no evidence of mitral regurgitation or regional dyskinesia. To establish whether the pulmonary arterial hypertension was associated with increased pulmonary vascular resistance or was a passive response to raised left atrial pressure (measured direct 26/16 (mean 18) mm Hg) cardiac output was measured by indocyanine-green indicator dilution.<sup>5</sup> Values averaged 3.42 l/m, giving a pulmonary vascular resistance of 5.5 units, or 440 dyn-s-cm<sup>-5</sup> (normal 67±23). Arterial blood gas tensions breathing air and <sup>99m</sup>Tc macroaggregate perfusion lung scan were normal.

Within six weeks of stopping fenfluramine the patient's exercise tolerance was normal and the electrocardiogram showed normal P waves with appreciable reduction of the right ventricular strain pattern (fig 2). Her mild systemic hypertension was treated with bendrofluzide and she remained well.

By March 1980 her weight had risen to 96.6 kg. The possible dangers of reinstating fenfluramine were discussed with the patient and her husband, and with their consent fenfluramine 80 mg daily was restarted and she was told to report immediately any deterioration in exercise tolerance. Six weeks later she again developed exertional breathlessness and palpitations and stopped fenfluramine. Within two days her symptoms had disappeared. Two weeks later an electrocardiogram (fig 2) showed tall P waves and T-wave inversion across V1-4. Within four weeks these changes were resolving and continued to do so. At repeat catheterisation 34 weeks after stopping fenfluramine pulmonary artery pressure was 40/20 (mean 30) mm Hg, right ventricular pressure 47/10-16 mm Hg, and left ventricular pressure 145/10-20 mm Hg. Cardiac output had risen to 4.20 l/m and pulmonary vascular resistance, though still raised, had fallen to 2.4 units, or 190 dyn-s-cm<sup>-5</sup>.

## Discussion

In 1967 the incidence of progressive pulmonary vascular hypertension suddenly increased in Switzerland, Germany, and Austria.<sup>3</sup> Out of 40 patients studied in Basle, 32 had been taking a newly released anorectic drug, aminorex fumarate,<sup>4</sup> and the absence of the usual causes of pulmonary vascular disease suggested that the pulmonary hypertension was drug induced. The incidence of the disease closely followed sales figures for the drug, and aminorex was withdrawn. A similar association has been suggested for the related compound chlorphentermine,<sup>5</sup> and pulmonary hypertension has been reported in two obese patients taking phenformin<sup>7</sup> and six women taking oral contraceptives.<sup>8</sup> Fenfluramine is chemically

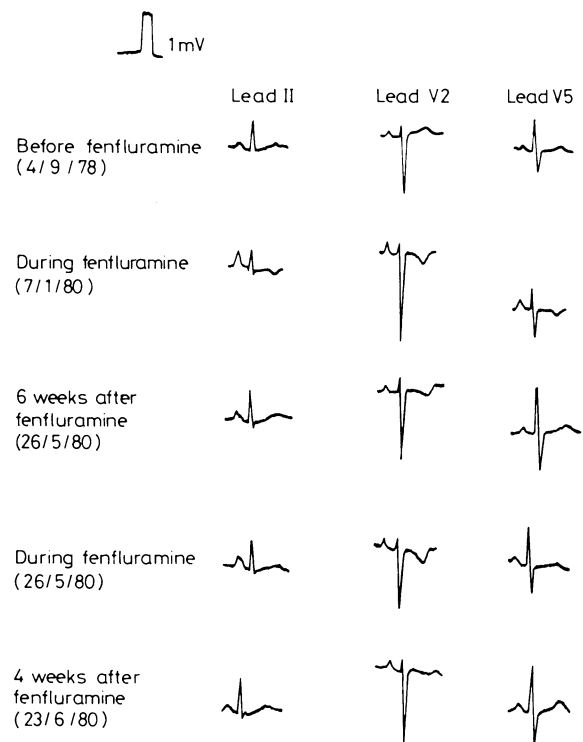


FIG 2—Case 2. Electrocardiograms recorded before, during, and six weeks after fenfluramine and again during and four weeks after restarting the drug.

related to the other anorectic agents and, like aminorex and chlorphentermine, raises pulmonary diastolic pressure when infused acutely into dogs.<sup>9</sup> There are no reports of fenfluramine causing pulmonary hypertension in man, and six patients receiving the drug for up to three months had normal pulmonary artery pressures.<sup>10</sup>

Primary pulmonary hypertension is a progressive disorder which is usually fatal in two to eight years. Reports of unexplained reversal are rare.<sup>11</sup> In our first patient, who was not obese, the circumstantial evidence strongly implicated fenfluramine. Her symptoms predated taking the oral contraceptive, though the process may have been accelerated by its introduction. She had no evidence of thromboembolic disease, and reversal of the pulmonary hypertension coincided with the administration of a diuretic and withdrawal of fenfluramine.

In the second patient, who also developed pulmonary hypertension while taking fenfluramine and improved on stopping the drug, we could not incriminate fenfluramine with certainty. Pulmonary arterial hypertension may be due to increased pulmonary vascular resistance or may be a passive response to raised left atrial pressure, with normal or even low

pulmonary vascular resistance, as in many cases of mitral regurgitation. In this case pulmonary vascular resistance was greatly increased. While this could be due to an effect of fenfluramine on the pulmonary vessels, it might also be explained as a secondary effect of left ventricular failure due to the mild systemic hypertension present. Increased left ventricular end-diastolic pressure to 25 mm Hg or more is often accompanied by modest increases in pulmonary vascular resistance (200-300 dyn-s-cm<sup>-5</sup>).<sup>12</sup> In this patient, however, pulmonary vascular resistance was greatly increased (440), with a left ventricular end-diastolic pressure of only 18 mm Hg. Also, despite effective treatment of the hypertension with a diuretic she again developed symptoms and electrocardiographic evidence of pulmonary hypertension on rechallenge with fenfluramine. This evidence suggests that the reversible component of her pulmonary hypertension was due to fenfluramine.

Fenfluramine is an effective antiobesity agent with mild hypoglycaemic properties.<sup>13 14</sup> Hence, particularly when given to obese diabetics, drug treatment may be recommended for more than six months. Administration for six months produces weight loss in many patients but on drug withdrawal a gain in weight is the rule.<sup>15</sup> The hazards of prolonged use of fenfluramine remain to be evaluated. Pulmonary hypertension is the most serious to date, and we recommend that patients taking fenfluramine should be advised to report immediately any deterioration in exercise tolerance.

We thank Mrs J Troup and Mrs M Murray for secretarial help. Requests for reprints should be addressed to: Dr J G Douglas, Medical Unit, Eastern General Hospital, Seafeld Street, Edinburgh EH6 7LN.

## References

- Gagnon MA, Bordileau JW, Tetreault L. Fenfluramine: study of its central action through the effect on sleep. *International Journal of Clinical Pharmacology*, 1969;1:74-82.
- Steel JM, Briggs M. Withdrawal depression in obese patients after fenfluramine treatment. *Br Med J* 1972;iii:26-7.
- Gurtner HP, Gertsch M, Salzmann C, Sherrer M, Stucki P, Wyss F. Häufen sich die primär vasculären Formen des chronischen Cor pulmonale? *Schweiz Med Wochenschr* 1968;98:1579-89, 1695-707.
- Follath F, Buckart F, Schweizer W. Drug-induced pulmonary hypertension? *Br Med J* 1971;ii:265-6.
- Barratt-Boyes BG, Wood EH. Cardiac output and related measurements and pressure values in the right heart and associated vessels. *J Lab Clin Med* 1958;51:72-90.
- Paepre K. Hypotonie und Appetitzügler. *Ärztliche Praxis* 1970;22:1397.
- Fahlen M, Bergmar H, Helder G, Ryden L, Wallentin I, Zettergren L. Phenformin and pulmonary hypertension. *Br Heart J* 1973;35:824-8.
- Kleiger RE, Boxer M, Ingham RE, Harrison DC. Pulmonary hypertension in patients using oral contraceptives. *Chest* 1976;69:143-7.
- Engelhardt A, Kroneberg G, Stoepe K, Stötzer H. The effects of acute and chronic administration of sympathomimetic substances on the systemic and pulmonary circulation. *Proceedings of the European Society for the Study of Drug Toxicity* 1970;11:110-7.
- Prime FJ. Dangers of certain appetite suppressants. *Br Med J* 1969;iii:177.
- Bourdillon PDV, Oakley CM. Regression of primary pulmonary hypertension. *Br Heart J* 1976;38:264-70.
- Grossman W, Braunwald E. Pulmonary hypertension. In: Braunwald E, ed. *Heart disease*. Philadelphia: Saunders, 1980:841.
- Wales JK. The effect of fenfluramine on obese, maturity-onset diabetic patients. *Curr Med Res Opin* 1979;6, suppl 1:226-35.
- Turtle JR, Burgess JA. Hypoglycaemic action of fenfluramine in diabetes mellitus. *Diabetes* 1973;22:858-67.
- Hudson KD. The anorectic and hypotensive effect of fenfluramine in obesity. *J R Coll Gen Pract* 1977;27:497-501.

(Accepted 20 July 1981)

# Antibiotic use in otitis media: patient simulations as an aid to audit

D MARK CHAPUT DE SAINTONGE, N R HATHAWAY

## Abstract

Diagnostic and prescribing practices in otitis media vary, and audit is difficult because doctors may not see comparable cases. Seven general practitioners took part in a pilot study to discover if simulated patients evoked the same diagnostic and treatment responses as real patients. Forty-eight patients entered the study over three weeks and provided data for two simulations; one included the doctor's description of the ear and the other a photograph instead. Each doctor was shown the two sets of simulations and asked to state his diagnosis and treatment. The diagnoses each doctor reached agreed significantly with those reached on the simulations of the same patients. The decisions to prescribe antibiotics also showed good agreement.

Doctors' judgments on the simulations of each other's patients, however, were significantly different, and five or six cases could be identified as the cause of the disagreement.

This method of comparing clinical judgments is simple and standardised, and it could be used for peer review or self-assessment.

## Introduction

Doctors differ widely in their antibiotic prescribing practices.<sup>1</sup> In otitis media, for example, anything from 25%<sup>2</sup> to 90%<sup>3</sup> of cases are given antibiotics. Uncertainty about the diagnosis and lack of agreement on the important prognostic features makes audit difficult. Differences in choice, frequency, and cost of antibiotic prescribing between doctors might reflect only differences in the patients treated; even within a single practice partners see different sorts of patients and uniformity of prescribing might be quite inappropriate. Peer review of individual cases may solve this problem but is almost invariably retrospective and requires access to all the relevant patient data; few patient records are, or will ever be, adequate in this respect. It is impractical for each of a group of doctors to see the same patients, though they could then compare decisions made on the same clinical data. This pilot study examines the related but simpler solution of using patient simulations.

Departments of Clinical Pharmacology and Therapeutics, St Bartholomew's Hospital Medical School and London Hospital Medical School, London E1 2AD

D MARK CHAPUT DE SAINTONGE, PHD, MRCP, senior lecturer

Department of Medical Electronics, St Bartholomew's Hospital, London EC1A 7BE

N R HATHAWAY, BS, medical statistician