

Intravenous immunoglobulin in juvenile dermatomyositis – four year review of nine cases

A Sansome, V Dubowitz

Abstract

Juvenile dermatomyositis is difficult to treat, compounded by complications of the disease itself as well as side effects of treatment. The mainstay of pharmacological management is corticosteroids, to which the disease is usually very responsive, but steroids have well established short and long term side effects. Refractory cases may be resistant to steroids or patients may become dependent on high doses, with relapse in clinical disease precipitated by reduction. Over-treatment with steroids and too rapid a reduction are common errors. Various second line agents have been used with success in complex or refractory cases, including cyclophosphamide, methotrexate, and cyclosporin.

Intravenous immunoglobulin has been tried in the management of autoimmune diseases, either as an alternative to cytotoxic treatment or as a steroid sparing agent. The reported benefit in a number of childhood illnesses, including juvenile dermatomyositis, prompted this clinical trial in some of our more refractory cases.

Over the past four years, nine children attending a dermatomyositis clinic have been treated with intravenous immunoglobulin. The two main indications were failure of conventional treatment and severe side effects from previous treatment, principally corticosteroids. All nine were still on treatment with various permutations of prednisolone, azathioprine, and cyclosporin. All nine showed clinical improvement at some point in their treatment with intravenous immunoglobulin. Of eight children on concurrent prednisolone, the dose could be reduced in six and kept the same in two.

(*Arch Dis Child* 1995; 72: 25–28)

Keywords: intravenous immunoglobulin, juvenile dermatomyositis, drug treatment.

Juvenile dermatomyositis presents with a classical triad of symptoms: weakness, rash, and misery. Many children will respond well

to corticosteroid treatment. A starting dose of 1 mg/kg/day is used, gradually tapering off over 6–12 months, once a response has occurred. High dose steroids have no benefit over this low dose regimen and carry a risk of significant morbidity, including osteoporosis, myopathy, hypertension, gastrointestinal symptoms, and obesity.^{1,2} Even with low dose steroids there may be significant complications.

Further immunosuppression may be required in patients with refractory disease. Azathioprine has been a valuable agent in juvenile dermatomyositis (dose 2.5 mg/kg/day). Although it is rather slow in action,^{3,4} it has relatively few side effects. Its main benefit has been to allow a reduction in steroid dose. Low dose cyclosporin (starting dose 4 mg/kg/day) has proved a useful additional treatment in refractory juvenile dermatomyositis.⁵ It acts principally by T cell suppression. The main side effect is on the kidney, but with careful monitoring this is uncommon.

Some children require additional immunosuppression when disease symptoms remain uncontrolled, and have responded to methotrexate or cyclophosphamide. Plasmapheresis has also been used on rare occasions, but it is not a recommended treatment.⁶

The use of immunoglobulin in adults with polymyositis and dermatomyositis has shown promising results in steroid sparing and appears to be a safe alternative to cytotoxic treatment.⁷ More recently, a controlled trial of high dose intravenous immunoglobulin in 15 adults with treatment resistant dermatomyositis showed convincing improvement in muscle strength in nine of 12 treated individuals and minor improvement in two, as compared with none of the placebo group.⁸

There has been reported benefit in paediatric autoimmune disorders, particularly Kawasaki disease^{9–11} and systemic juvenile arthritis.¹² With the relative rarity of juvenile dermatomyositis, clinical trials of intravenous immunoglobulin have so far been uncontrolled and largely anecdotal.^{13,14} It has produced some benefit in a few children with persistent disease or complications of standard treatment (table 1).

In a trial of five children by Lang *et al*, a dose of 1 g/kg immunoglobulin was given for two days each month for nine months.¹³ All five children showed improvement in muscle strength and skin rash, and their dose of prednisolone was reduced or stopped. Barron *et al* reported two small trials, one using 1 g/kg for two days and the second using 0.4 g/kg for four days each month for six months.¹⁴ Again, all children showed some improvement in

Department of Paediatrics and Neonatal Medicine, Royal Postgraduate Medical School, Hammersmith Hospital, Du Cane Road, London W12 0NN
A Sansome
V Dubowitz

Correspondence to: Dr Sansome.

Accepted 1 September 1994

Table 1 Summary of recent trials using intravenous immunoglobulin as a treatment for juvenile dermatomyositis

	No of patients	Dose regimen	Improvement
Lang and Murphy ¹³	5	1 g/kg for 2 days each month for 9 months	5
Barron <i>et al</i> ¹⁴			
Trial 1	6	1 g/kg for 2 days each month for 6 months	6
Trial 2	6	0.4 g/kg for 4 days each month for 6 months	6

Table 2 Myometry scores before and after immunoglobulin infusion in nine patients. The mean myometry score is taken from five muscle groups: neck flexors, right and left knee extension, shoulder abduction, hip flexion, and hip abduction. Accurate measurements before and after infusion were achieved in 20 of the 33 courses

Patient No	Immunoglobulin infusion	
	Before	After
1	39.4	49.3
2	54.8	55.1
	38.4	41.6
	37.4	44.8
	29.3	24.8
	24.8	36.8
3	55.4	67.2
	34.7	36.5
4	14.2	17.2
	17.2	17.9
	18.8	19.4
	42.7	44.1
5	35.5	34.8
	55.9	38.6
	48.5	55.1
	7.2	8.4
6	7.0	7.5
	62.1	75.0
7	99.9	111.4
8	73.1	67.8
9		

muscle strength. In all six children in the first trial the dose of prednisolone was either reduced or stopped altogether, while in the second, five of the six were able to reduce the dose. These promising results prompted our longer term clinical trial of intravenous immunoglobulin in selected cases.

Patients and methods

All nine patients selected for intravenous immunoglobulin treatment had been on prednisolone at some stage during their illness and eight of the nine were still on it. Two patients were on prednisolone, azathioprine, and cyclosporin; two on prednisolone and azathioprine, three on prednisolone and cyclosporin, and one each on prednisolone or cyclosporin alone.

The indications for giving intravenous immunoglobulin were relapse on previously effective treatment (four children), weakness despite high dose treatment (two children), or inability to reduce the steroid dose without relapse (three children).

Initially a dose of 2 g/kg intravenous immunoglobulin was given over three days. This was later spread to 2 g/kg over five days given as five slow bolus infusions overnight thus allowing mobilisation and physiotherapy during the day, as immobilising these children can lead to the development of contractures or functional loss.

We used Sandoglobulin (Sandoz) as our source of immunoglobulin, as dictated by the hospital pharmacy supply. The half life of Sandoglobulin is long, about 22 days.¹⁵ It was felt most appropriate, therefore, not to give treatments more frequently than at intervals of four weeks. If the child was clinically improving, a treatment course would not be repeated routinely, but withheld until the clinical condition dictated a need for additional treatment.

Of the nine patients receiving intravenous immunoglobulin, the age of onset of the dermatomyositis ranged from 1.9 to 11.0 years

(mean age 7.8 years). The age range at which intravenous immunoglobulin was given was 8.5 to 11.9 years with a mean age of 10.6 years.

Most patients were over a year into their illness, ranging from 11 months from the initial presentation to five and a half years, with the exception of one patient who had a late relapse at 10 years after initial illness. The mean time from onset of disease to treatment with immunoglobulin was 2.8 years.

Two children had received drugs additional to the standard triple treatment. One had cyclophosphamide alone, the other received methotrexate followed by cyclophosphamide. The latter child suffered neutropenia while on cyclophosphamide; other side effects were related to corticosteroids. All the children on corticosteroids had experienced some side effects, particularly cushingoid features with weight gain. Three developed hypertension requiring treatment, six developed osteoporosis, four growth suppression, and one avascular necrosis of the femoral head.

ASSESSMENT OF MUSCLE FUNCTION

All children given intravenous immunoglobulin were formally assessed on the day before infusion and on one occasion within two weeks after infusion. Myometry, using a hand held Penny and Giles myometer, was performed in 32 muscle groups. The best reading of three attempts was taken. The results of myometry have been collated and are simplified to total the score in five muscle groups for this assessment: neck flexors, right and left knee extension, shoulder abduction, hip flexion, and hip abduction. The motor ability score of 20 functions on a two point scale¹⁶ and, when feasible, a walking time for 28 feet (8.5 m) was assessed on each clinical visit. Due to the wide geographical distribution of the patients and consequent long journeys, they were not all formally assessed after every treatment. In some cases a subjective report of their progress had to be taken when they could not attend personally for review. This would be their perceived improvement in strength, change in rash, and general mood.

Results

The number of courses given to individual children varied according to their clinical condition and ranged from one, in a girl who tolerated intravenous treatment very poorly, to six, with a mean of four. The time interval between treatments also varied with the severity of the condition, ranging from four to 10 weeks (mean 5.5 weeks). Most of the children required repeat treatment at 4-6 week intervals.

A total of 33 courses of immunoglobulin were given in the nine children. Of these we have formal before and after treatment assessment in 20 courses (table 2). In these 20 there was improvement in 16. In these 20 paired assessments, the mean myometry score in the five selected muscle groups showed an improvement of 2.85. Using the Wilcoxon

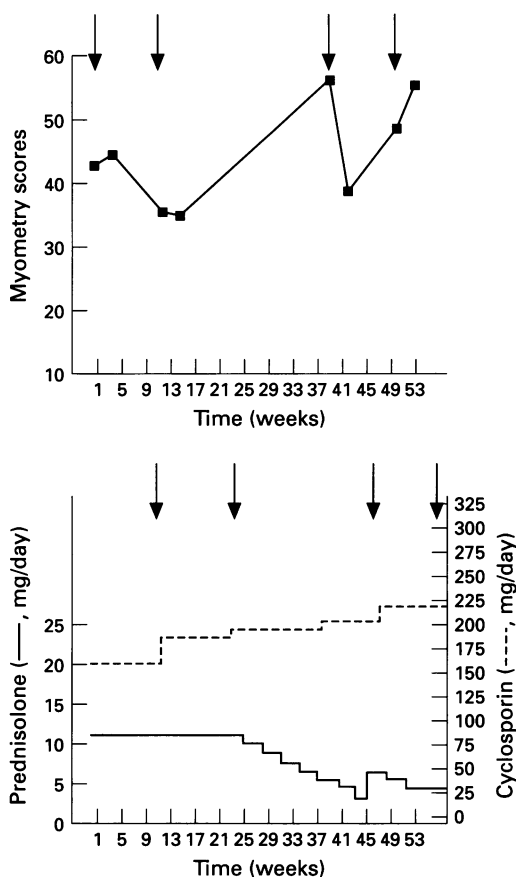


Figure 1 Mean myometry score of the five muscle groups during the treatment period in patient 5 is shown above the treatment regimens. The arrows indicate episodes of relapse at which time a dose of immunoglobulin is given. This patient illustrates the variability in response to immunoglobulin treatment.

signed rank test this results in a significant p value of 0.033. The response to successive treatment courses is illustrated by patient 5 (fig 1). A child's perceived improvement correlated very well with improvement in myometry, motor ability score, and walking time. Of the 13 courses not objectively measured there was a subjective improvement in 10 as reported by both child and parents.

Four children, patients 2, 5, 7, and 8, responded very well to some of the courses of immunoglobulin with up to 50% improvement in myometry scores. However, in one or sometimes two treatments they only had a minimal improvement or even deterioration. There seemed to be no common factor or way of predicting an individual response. It did not depend on the cause of their relapse or the time interval between doses (fig 2).

As a result of intravenous immunoglobulin infusion in the four children with relapses on high dose treatment, one child, on cyclosporin and prednisolone, was maintained on the same steroid dose despite relapse, two children on triple treatment had their dose of prednisolone slowly reduced (fig 3), and the fourth child, on cyclosporin alone, avoided restarting steroids.

In the two children who were weak on their current treatment, one girl on high dose prednisolone made marked clinical improvement and the prednisolone dose could be reduced. The other boy on cyclosporin

and prednisolone (previously treated with methotrexate and cyclophosphamide) made slight clinical improvement and from being confined to a wheelchair, could be mobilised to taking a few steps with support.

Two of the three children who had relapses with any reduction in prednisolone dose before the use of intravenous immunoglobulin were able to reduce the dose by 20% in one and by 50% in another after treatment courses. One had to be kept on the same dose after a single treatment of intravenous immunoglobulin. Despite showing improvement of strength after her first course, this girl tolerated the intravenous cannula very badly and was reluctant to have a second course.

SIDE EFFECTS

Many children complained of a mild headache after treatment with the initial dose of 2 g/kg given over three days. This was severe in four of the nine after one course or more. Two suffered diarrhoea after treatment, one severe nausea, and one fever.

As with the variability in clinical response, we found that side effects may occur after one course of treatment but not another. In general side effects did not correlate with the clinical response. However, we subsequently found that on an attenuated regimen of 2 g/kg spread over five days instead of three none of these side effects occurred.

Discussion

The aetiology of juvenile dermatomyositis remains unknown, although infectious agents have been identified as potential precipitating causes.¹⁷ The fact that the disease shows an association with particular HLA class I and II antigens, and that specific autoantibodies have been found, suggest that juvenile dermatomyositis has an immunological basis. It was on the strength of this, and the action of immunoglobulin in other autoimmune disorders, that its potential use was established.

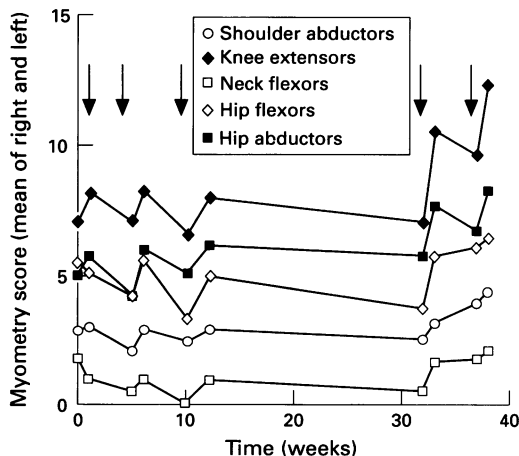


Figure 2 A more detailed illustration of patient 5. The arrows indicate a relapse, at which time immunoglobulin treatment was initiated. The mean myometry scores before and after immunoglobulin in the five muscle groups show a relatively similar trend. The actual degree of improvement varies with each dose.

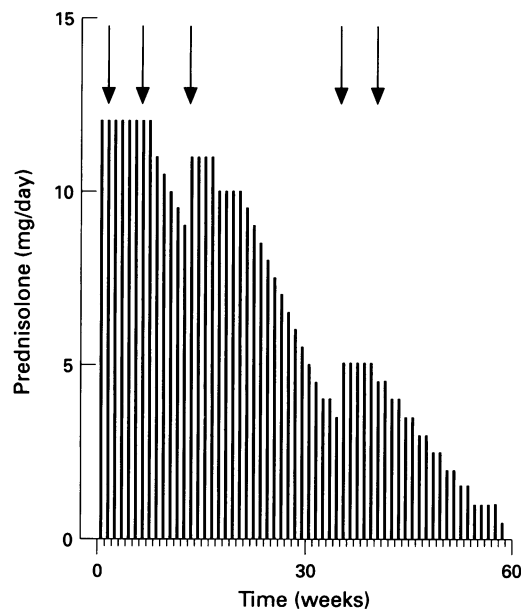


Figure 3 Patient 5: this child had been on prednisolone treatment for six years since the onset of her dermatomyositis; for three years the dose was around 10 mg/day. Intravenous immunoglobulin (treatment indicated by arrows) modified a relapse and subsequently allowed tapering of the prednisolone dose completely.

Intravenous immunoglobulin has many effects on immunological function, but the actual mechanism of action is unknown. There have been various hypotheses as to its therapeutic effect. These have included the inhibition or binding of activated complement to target cells¹⁸ and reduced complement deposition,¹⁹ therefore modifying complement mediated tissue damage. There may be a wider effect on antibody production, the rise in immunoglobulin concentrations after treatment causing down regulation of immunoglobulin production.²⁰ It has also been suggested that antibodies in intravenous immunoglobulin may neutralise autoantibodies in the patient.²¹ Other potential mechanisms of immunomodulation and inhibition of cytokine secretion has also been proposed.²²

Whichever the mechanism of action, our results suggest that intravenous immunoglobulin has some influence on the course of disease in some selected cases of juvenile dermatomyositis. However, the response has been inconsistent and unpredictable, both between patients and also between courses in the same patient. This may possibly be due to variation in the donor pools of different batches of intravenous immunoglobulin.

We found the side effects too frequent and severe for the children to tolerate the intensive three day course, so would recommend the five day regimen (using the same total dose of 2 g/kg), which reduced the incidence of headache, nausea, and gastrointestinal disturbance.

The use of immunoglobulin has been of value in the management of children with

juvenile dermatomyositis, particularly in a role of steroid sparing and as an alternative to immunosuppression. On the available data we would not at present recommend it as a first line of treatment, but still prefer low dose (1 mg/kg/day) prednisolone for induction of remission in view of its consistent effectiveness.

It is difficult to assess, in a single centre, the overall application of intravenous immunoglobulin in view of the limited number of new cases seen each year. Many patients referred to our tertiary centre have already had an initial treatment course of prednisolone, often at a higher dose than we would recommend. A multicentre trial would undoubtedly throw more light on the overall possibilities of therapeutic management, including the use of immunoglobulin as an adjunct to established regimens.

- Dubowitz V. Treatment of dermatomyositis in childhood. *Arch Dis Child* 1976; **51**: 494-500.
- Miller G, Heckmatt JZ, Dubowitz V. Drug treatment of juvenile dermatomyositis. *Arch Dis Child* 1983; **58**: 445-50.
- Jacobs JC. Methotrexate and azathioprine treatment of childhood dermatomyositis. *Pediatrics* 1977; **59**: 212-8.
- Bunch TW, Worthington JW, Combs JJ, Illstrup DM. Azathioprine with prednisolone for polymyositis. *Ann Intern Med* 1980; **92**: 365-9.
- Heckmatt JZ, Saunders C, Hasson N, et al. Cyclosporin in juvenile dermatomyositis. *Lancet* 1989; **i**: 1063-6.
- Miller FW, Leitman SF, Cronin ME, et al. Controlled trial of plasma exchange and leukapheresis in polymyositis and dermatomyositis. *N Engl J Med* 1992; **326**: 1380-4.
- Cherin P, Herson S, Wechsler B, et al. Efficacy of IVGG therapy in chronic refractory polymyositis and dermatomyositis. *Am J Med* 1991; **91**: 162-8.
- Dalakas MC, Illa I, Dambrosia JM, et al. A controlled trial of high dose intravenous immunoglobulin infusions as treatment for dermatomyositis. *N Engl J Med* 1993; **329**: 1993-2000.
- Furusho K, Nakano H, Shinomiya K. High dose intravenous gammaglobulin for Kawasaki disease. *Lancet* 1984; **ii**: 1055-8.
- Newburger JW, Takahsaki M, Burns JC. The treatment of Kawasaki syndrome with intravenous gamma globulin. *N Engl J Med* 1986; **315**: 341-7.
- Barron KS, Murphy DJ Jr, Silverman ED, et al. Treatment of Kawasaki syndrome: a comparison of two dosage regimens of intravenous immune globulin. *J Pediatr* 1990; **117**: 638-44.
- Silverman ED, Laxer RM, Greenwald M, et al. Intravenous gammaglobulin therapy in systemic juvenile rheumatoid arthritis. *Arthritis Rheum* 1990; **33**: 1015-22.
- Lang B, Murphy G. Treatment of dermatomyositis with intravenous globulin. *Am J Med* 1991; **91**: 169-72.
- Barron K, Sher M, Silverman E. Intravenous immunoglobulin therapy: magic or black magic. *J Rheumatol* 1992; **19** (suppl 33): 94-7.
- Morell A, Schurch B, Ryser D, et al. In vivo behaviour of gammaglobulin preparations. *Vox Sang* 1980; **38**: 272-83.
- Scott OM, Goddard C, Dubowitz V. Quantitation of muscle function in children: a prospective study in Duchenne muscular dystrophy. *Muscle Nerve* 1982; **5**: 291-301.
- Bowles NE, Sewry CA, Dubowitz V, Archard LD. Dermatomyositis and coxsackie B virus infection. *Lancet* 1987; **i**: 1004-7.
- Kissel JT, Mendell JR, Rammohan KW. Microvascular deposition of complement membrane attack complex in dermatomyositis. *Arch Neurol* 1991; **48**: 26-30.
- Dalakas MC, McCrisky S, D'Ambrosia JM, et al. high-dose intravenous immunoglobulin (IVIg) in the treatment of dermatomyositis (DM): a double-blind placebo-controlled trial. *Neurology* 1993; **43**: A356-7 (abstract).
- Ballou M, White W, Desbonnet C. Modulation of in vitro synthesis of immunoglobulin and the induction of suppression activity by therapy with intravenous immune globulin. *J Allergy Clin Immunol* 1989; **84**: 595-602.
- Ross F, Kazatchkine MD. Antidiotypes against autoantibodies in pooled normal human polyspecific Ig. *J Immunol* 1989; **143**: 4104-9.
- Ronda N, Hurez V, Kazatchkine MD. Intravenous immunoglobulin therapy of autoimmune and systemic inflammatory diseases. *Vox Sang* 1993; **64**: 65-72.