

THE DISTRIBUTION AND PHYSIOLOGICAL ACTION  
OF THE SUPRARENAL MEDULLARY TISSUE IN  
PETROMYZON FLUVIATILIS. BY J. F. GASKELL,  
*Beit Memorial Research Fellow.*

(*From the Laboratory of Pathology, St Bartholomew's Hospital.*)

THE presence, in the greater part of the vertebrate kingdom, of tissues corresponding to those of the mammalian suprarenal cortex and medulla, has been long established. In certain groups of fishes however nothing definite was known until the publication of the investigations of Giacomini. He established the presence of similar tissues in these groups, thus completing the evidence for their universal presence throughout vertebrates. The groups investigated by Giacomini were firstly the Cyclostomes<sup>1</sup> as represented by the Lampreys (*Petromyzon marinus*, *P. planeri*) and its larval form Ammocœtes; secondly the Teleosts<sup>2</sup>, as represented by the Eel (*Anguilla vulgaris*), the Pike (*Esox lucius*) and other freshwater forms; and finally the Ganoids<sup>3</sup>, as represented by the Sturgeon (*Acipenser sturio*). In all these different forms he was able to show the presence of two separate diffusely scattered systems of tissue, corresponding respectively to the medulla and cortex of the mammalian suprarenal. He relied on histological methods only in his investigations, using the reaction to potassium bichromate to identify the tissues corresponding to the suprarenal medulla, and a difference of staining reaction in osmic preparations to identify the tissue corresponding to the suprarenal cortex.

The present investigation was undertaken to determine whether the identity of the chrome staining tissue with adrenal tissue could be substantiated by physiological methods.

Since, during this investigation, the distribution of the tissues described by Giacomini has been confirmed, a short account of their

<sup>1</sup> Giacomini. *Monit. Zool. Ital.* XIII. p. 143. 1902.

<sup>2</sup> *Ibid.* XIII. p. 183. 1902.

<sup>3</sup> *Ibid.* xv. p. 19. 1904.

distribution may first be given. Giacomini's chief investigation was made on *P. marinus*. He however established an almost identical distribution in *P. planeri* and in *Ammocetes*. In the present investigation *P. fluviatilis* was used, as it was the more easily procurable. The only difference of the distribution in the two animals is that the tissues in question are more scanty in the smaller animal *P. fluviatilis*; their regional distribution is essentially the same in both animals. The diffuse nature of the distribution of the chrome staining substance is morphologically of much interest, as it so closely corresponds with the earliest distribution of the chrome staining tissues in the mammalian embryo. The researches of Kohn<sup>1</sup> in the mammal have shown that the tissue appears early in embryonic life, and extends from the cervical region to the sacral, having a most diffusé distribution ventrally and laterally to the aorta. It is not till birth that the concentration into masses takes place, so as to form the suprarenal medulla, the carotid gland and the organ of Zuckerkandl, at the bifurcation of the aorta. The latter organ shortly afterwards disappears, a process which has also occurred earlier with many of the scattered nodules of chrome tissue originally present.

In *P. fluviatilis* both tissues are widely distributed. The chrome staining substance is found in every segment from the second branchial to nearly the end of the post-anal region. The cortical substance extends nearly as diffusely. The tissue corresponding to the suprarenal cortex consists of scattered islets, very often composed of only two or three cells, which lie in the tissue round the cardinal veins on their lateral and ventral aspects (Fig. 1 *c.t.*). Some groups of these lie between the aorta and the veins and so may come into contact with the chrome staining substance, whose distribution is about to be described. The tissue does not extend into the branchial region, but extends caudally as far as the chrome staining substance does, that is to say nearly to the end of this region.

It is also associated with two other organs, the pronephros lying at the bottom of the pericardial sac, and the kidney proper. Nodules are scattered throughout the pronephros, and similar islets obtain relation to the kidney proper as they lie round the main kidney veins, where these run into the organ.

Giacomini relied on the different appearance of these cells in osmic preparations to differentiate them from the cells containing neutral fat among which they lie.

<sup>1</sup> Kohn. *Arch. f. Micr. Anat.* Bd. LXXI, S. 263. 1903.

The distribution of the chrome staining substance will be first described in the region of the kidney proper, and then the variations which occur in other regions will be mentioned. Giacomini identified the tissue both by the chrome reaction and also by the deep staining of the cell protoplasm with hæmatoxylin and hæmalum. He worked with tissue fixed in Fleming's fluid and embedded in paraffin. The present work has been done with material fixed in formol Müller solution, embedded in gelatine, and examined unstained or stained very lightly, so as not to obscure the chrome reaction; or embedded in paraffin, cut serially and stained with hæmatoxylin, the cells being identified by the deep staining of their protoplasm.

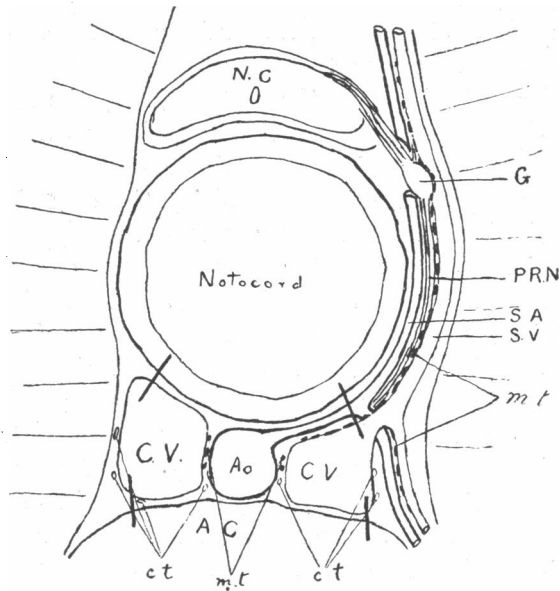


Fig. 1. Diagram to show the distribution of the chrome staining tissue *m.t.* and the method of obtaining tissue for extraction. The walls of the cardinal veins were cut through at the points indicated by the short thick lines, and the central mass was dissected from the notochord.

*A.C.* abdominal cavity. *A.O.* aorta. *C.V.* cardinal veins. *N.C.* nerve cord. *S.V.* segmental vein. *S.A.* segmental artery. *P.R.N.* posterior root nerve. *G.* posterior root ganglion. *c.t.* suprarenal cortical tissue. *m.t.* chrome staining tissue.

The chrome staining tissue is distributed in a thin layer seldom more than one cell thick lying in the walls of the cardinal veins and their large branches (Fig. 1 *m.t.*). The tissue is only separated from the lumen of the vein by the endothelial layer; it often appears to

bulge into the lumen to some extent. It does not lie uniformly all round the wall of the vein but appears as groups of cells always situated on that side of the vein on which the artery lies, so that it always lies between the vein and artery. It lies external to the well developed median and adventitial walls of the arteries themselves. Where the artery and vein are applied closest to one another the tissue is absent, being grouped in the wall of the vein on each side of this point of contact. It is possible that its true relations are more with nerve and vein, rather than with artery and vein, though the latter is the relation that Giacomini holds to be most important.

To make the regional distribution shown in Fig. 1 clear it is first necessary to mention the distribution of the spinal nerves. The two roots, the anterior and posterior, are entirely separate, and alternate more or less with one another.

The anterior root arises from the ventral part of the cord, and runs out laterally till it reaches and is closely applied to the base of the somatic muscles. It divides into two main branches extending dorsally and ventrally over the muscles and supplying them. It is not accompanied in its distribution by any other structure.

The posterior root on the other hand arises from the dorsal aspect of the cord and runs out to a ganglion (Fig. 1 *G.*) of fair size in this region, which is applied most closely to the segmental vein (*S.V.*). The segmental artery also (*S.A.*) lies in close relationship to the ganglion. The main posterior root nerve, peripheral to the ganglion, lies in most intimate contact with this vein and artery, and is apparently distributed with the various vascular branches throughout the body; its main trunk runs down with the segmental artery and vein to the point of origin of the latter from the cardinal vein. The finer details of the peripheral distribution have not been worked out, as they are unimportant as regards the main mass of chrome staining tissue. The segmental artery and vein running round the notochord are therefore in intimate contact with the posterior root nerve and its ganglion. In all the segments so far observed the nerve lies between the artery and vein, so that the connection between vein and nerve is necessarily more intimate than that between vein and artery.

The chrome staining tissue (*m.t.*) lies in scattered clumps in the loose tissue on the internal aspect of the cardinal vein (*C.V.*) between it and the aorta ( *Ao.*). It here may come into contact with an occasional nodule of cortical substance. It is present however in much greater quantity on the dorsal aspect of the vein, at the place where the

segmental artery passes between the vein and the notochord. The chrome tissue is in greatest quantity on each side of the point of closest contact of artery and vein. It also spreads in considerable quantity all the way up the segmental vein, as this vein runs up round the notochord, accompanying the segmental artery. In this region it lies only on that aspect of the vein which faces the segmental artery, and Giacomini considers that this is its most important relationship; but, as has been already suggested, the relation appears to be even more intimate with the posterior root nerve. The relation of the chrome staining tissue with the posterior root ganglion is also a most intimate one; as Giacomini says, "the chromaffin cells appear to lie right against the ganglion cells of the spinal ganglion." Here also they lie in intimate contact with the segmental vein, which is closely applied to the ganglion.

Further scattered chrome staining cells lie in the walls of the dorsal branches of the segmental vein, as these run up past the lateral line nerve. Some also lie in the ventral branches which arise from the segmental vein near its origin, and run ventrally and laterally from here.

The main distribution of the chromaffin tissue in each segment is therefore between the cardinal vein and aorta, and along the segmental veins as these run dorsally round the notochord. The chrome staining tissue in the former situation may, as already mentioned, come into contact with islets of cortical tissue. The latter tissue is not found along the segmental vessels, but lies mainly ventral and lateral to the cardinal vein; thus differing considerably in distribution from the more dorsally situated chrome staining tissue. The question of the occurrence of ganglion cells in this region will not be discussed in this paper.

The variations of distribution in other regions of the body may now be briefly mentioned.

*Posteriorly.* In the caudal region, beginning 2 cm. in front of the anus, the two cardinal veins coalesce into one, and come to lie ventral to the caudal artery. The chrome staining tissue now lies on the dorsal aspect of the vein, between it and the artery. It extends nearly to the end of the caudal region.

*Anteriorly.* In the pre-renal region, between the pericardium and the apex of the kidney, the arrangement is similar to that in the renal region, and the tissue is present in greater quantity.

In the cardiac region, the posterior cardinal veins become fused into a single curved sinus lying ventrally and laterally to the aorta.

The chrome staining tissue lies thickly in the dorsal wall of the sinus as it curves round the aorta. The coeliac artery runs through the sinus obliquely, and is covered by a sheath of chrome staining substance.

In the precardiac, or branchial region, the chrome staining tissue lies in the walls of the segmental veins as these run round the notochord, but the tissue is very scanty. It is only seen in the wall of the jugular vein where the segmental artery branches over it. It here comes into relation with the pneumogastric nerve. The tissue is found as far forward as the second branchial segment.

The chrome staining tissue is therefore distributed extremely diffusely throughout the body, and is always in close relation to the large veins and arteries, and probably also to the posterior root nerves. Its distribution does not correspond with that of the cortical substance; the two only chance to come into contact with one another.

In order to obtain an extract of these chrome staining cells to test their effect on the blood-pressure of the cat, a dissection indicated by the lines in Fig. 1 was made. The abdominal cavity was first cleared of its contents and well sponged out with Ringer's solution. The artery and veins, which appeared clearly on its dorsal wall, were as far as possible cleared of blood by syringing out with the same. The veins were then cut through laterally, and the aorta, with the ventral, internal, and dorsal walls of the veins, was dissected off from the notochord. The tissue was thus removed in one piece from the whole length of the abdominal cavity. The vessels from three or four specimens were then ground up with sand in a small amount of Ringer's solution. After standing for a short time, the extract was filtered through glass wool, and the filtrate was made up to such a volume that 1 c.c. corresponded with each animal used. The extract thus prepared was used for injection. The sinus tissue was also extracted by removing the whole heart and treating this in a similar way. The actual injections were carried out by Dr T. R. Elliott, who was so kind as to give me the benefit of his assistance and experience in this matter.

It was found that these extracts raised the blood-pressure in the cat in a manner identical with adrenalin; the curves obtained could be matched, in the same experiment, by the injection of a proper dose of the drug.

Fig. 2 A gives the curve obtained by the injection of 1 c.c. of an extract of the vessels of two specimens; the extract having been made

up to 2 c.c. The injection was therefore equivalent to the pressor substance obtained from one specimen. Fig. 2 B was obtained in the same experiment by the injection of one-thousandth of a milligram of adrenalin (Parke, Davis). The extract was also boiled and gave an identical result. The rise of blood-pressure is equivalent to a rise of about 8 mm. of mercury, the pressure rising from 60 mm. to 68 mm. The average of seven experiments on various cats gave a rise of about 7.5 mm. at an average pressure of 70 mm., the results obtained being very constant.

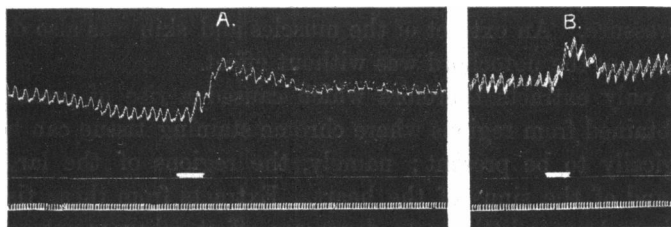


Fig. 2.

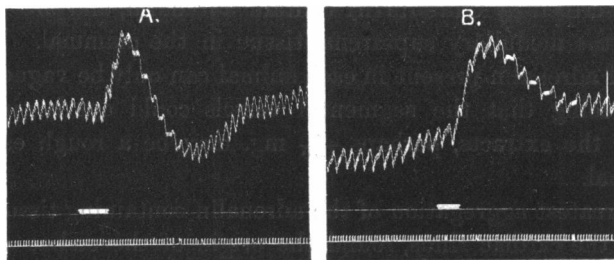


Fig. 3.

Fig. 3 A shows the curve obtained by the injection of 1 c.c. of an extract of two hearts in 2 c.c. Ringer's solution. Fig. 3 B was obtained by the injection of  $\frac{1}{200}$  mg. of adrenalin. As much sinus tissue as possible was removed with the heart in preparing this extract. The rise of pressure is equivalent to an increase of 12 mm. of mercury, from 62 mm. to 74 mm. A second experiment with this extract gave an identical result. A further experiment, in which little sinus tissue was taken away with the heart when preparing the extract, gave a rise of only about 4 mm. of mercury, from 89 mm. to 93 mm. It is therefore probable that the pressor substance is contained mostly in the sinus tissue.

The fall of pressure occurring after the rise is probably due to the effect of the other tissues, namely, the ventricular walls and the serum contained in them. No such effect is to be observed from the extract of the vessels.

Extracts of other tissues were also injected, having been prepared in the same way. Extracts of the kidney, liver, cord and brain were strongly depressor and extremely toxic, the blood-pressure falling rapidly and continuously; no permanent recovery being possible by the further administration of adrenalin. The blood serum, though having no immediate effect, also caused a gradual and irrecoverable fall in the blood-pressure. An extract of the muscles and skin was also depressor. An extract of the notochord was without effect.

The only extracts therefore which caused a rise of pressure were those obtained from regions where chrome staining tissue can be shown histologically to be present; namely, the regions of the large blood vessels and of the sinus of the heart. Extracts from these tissues are not toxic and cause little or no depressor effect, whereas extracts of all other tissues are both depressor and extremely toxic.

It is therefore justifiable to conclude that the chrome staining tissues described by Giacomini contain adrenalin, and are the homologues of the medullary suprarenal tissue in the mammal. The actual amount of adrenalin present in each animal can only be vaguely guessed at, but seeing that the segmental vessels could not be included in preparing the extracts, perhaps  $\frac{1}{100}$  mg. may be a rough estimate for each animal.

The greatest aggregation of the adrenalin containing tissue is in the region of the cardiac sinus, round the origin of the cœliac axis, as has been shown both histologically and physiologically. This recalls the earliest appearance of chrome staining tissue in the mammalian embryo, as described by Kohn<sup>1</sup>, namely, in the region in front of the aorta just below the diaphragm, the region where the cœliac axis comes off from the aorta.

#### CONCLUSIONS.

(1) The distribution of chrome staining tissue in *P. fluviatilis*, as described by Giacomini, is confirmed. The tissue is spread very widely throughout the body, and is in intimate relation with the large veins.

<sup>1</sup> *Loc. cit.*



(2) The tissue has relations with the large arteries also, and perhaps a still more intimate one with the posterior root nerves, which are intimately connected with the arteries and veins.

(3) Extracts of the regions in which this tissue lies, namely the walls of the aorta and cardinal veins, and the sinus region of the heart, cause a rise of blood-pressure in the cat, which can be matched by measured adrenalin injections.

(4) The extracts of all other tissues gave depressor effects.

(5) The chrome staining tissue of *P. fluviatilis* is therefore identical with the medullary substance of the mammalian suprarenal gland.