

CHOLEDOCHUS CYST °

Case Report with Brief Comment

CHARLES E. DAVIS, JR., M.D.

NORFOLK, VA.

FROM THE DEPARTMENT OF SURGERY AND GYNECOLOGY, BECKLEY HOSPITAL, BECKLEY, W. VA.

THE GREAT RARITY of the condition known as choledochus cyst or idiopathic cystic dilatation of the common bile duct as judged by the paucity of reports in the literature, should make the report of a single case diagnosed preoperatively and successfully treated by primary anastomosis to the intestinal tract of some interest. Its relative infrequency is manifested by the fact that Judd and Greene⁵ at the Mayo Clinic were able to find only one case despite a review of 17,381 biliary tract operations covering a period of 19 years. Likewise, Smith¹² at the Presbyterian Hospital in New York, collected only two choledochus cysts from 757,000 admissions to that institution. Numerous excellent reviews of the literature pertaining to this condition are to be found, notably those of McWhorter⁸ in 1924, Zininger and Cash¹⁴ in 1932, and, more recently, of Shallow *et al.*¹¹ in 1943. The latter group were able to collect only 175 cases, and Smith could find only 181 cases in the literature. McLaughlin⁷ is of the opinion that the total number is certainly less than 200. According to Blocker *et al.*,² Lavenson credited Vater in 1723 with finding the first choledochus cyst. Clark⁴ remarks that the first case report was made by Todd in 1817, and Saint¹⁰ states that Neugebauer, in 1924, was the first to diagnose a case preoperatively. Since that time diagnosis still remains uncommon. Berkley¹ reported a diagnostic error of 98% in reviewing 53 cases. Many authors, particularly Zininger and Cash,¹⁴ Morley⁹ and Ladd and Gross,⁶ feel that the high mortality associated with this condition results primarily from failure to recognize the true pathologic condition either preoperatively or at the time of surgery, and therefore failure to institute or an undue delay in instituting anastomosis between the intestine and the biliary tract. The etiology of this condition remains obscure, although many hypotheses have been advanced, practically all of them dealing with some developmental anomaly either of formation or of growth.^{9, 11, 14}

CASE REPORT

E.R.S., Hospital No. 123963, 5-year-old white male, was first admitted to the Surgical Service of the Beckley Hospital on May 7, 1947, with the major complaints, as given by his mother, of intermittent abdominal pain, occasional slight jaundice, alcoholic stools, abdominal mass, low-grade fever, and episodes of nausea and vomiting, these symptoms having repeatedly occurred with increasing intensity since the age of two years.

History of Present Illness and Previous Admissions.—According to the mother, the patient was the fourth of five normally born children, and the first two years of his life had been quite uneventful. At the age of three, however, he began to complain occasionally of right upper quadrant pain, this being noticed most often following the ingestion of food. The pain was described as being cramplike, doubling the child up during the more severe episodes. At about the same time the mother observed that his skin and

* Submitted for publication, June, 1948.

sclera were frequently yellow. The symptoms described above became more marked, and at about the age of four a mass was discovered in the right upper quadrant for the first time. The mother stated that the mass fluctuated considerably in size from day to day. Alcoholic stools began to be noticed, usually occurring following episodes of fever associated with enlargement of the mass and the appearance of jaundice. These symptoms continued, and he was first hospitalized on the Pediatric Service of this institution on May 13, 1946, when the abdomen was found to be distended and there was a large palpable mass in the right upper quadrant, the latter being interpreted as an enlarged gallbladder. His temperature was 100.4 on admission. Laboratory studies revealed a fragility test with no increase in hemolysis, an icterus index of 53, and a red blood count of 3.9 million with a hemoglobin of 56% (photoelectric); the white blood count was normal; the van den Bergh test showed a reaction of the immediate obstructive type; and urinalysis was negative except for a biliuria. A flat roentgen-ray film of the abdomen revealed what was thought to be a large mass in the right upper quadrant. A cholecystogram failed to reveal any gallbladder shadow, leading to the roentgenographic diagnosis of a probable pathologic gallbladder. On conservative therapy the jaundice declined and the fever subsided; and as these improved, his abdominal complaints disappeared. In view of his improvement the patient was discharged from the hospital, a diagnosis of acute catarrhal jaundice having been made.

Following discharge from the hospital, he was asymptomatic for approximately four weeks and then again began to have the same type of attacks. His mother noticed that the mass apparently was becoming larger very gradually and tended always to be present to some extent, even between acute episodes. On April 29, 1947, he was readmitted on the Pediatric Service for further study. At that time his temperature was 100.6, and he was clinically slightly icteric. A mass was present in the right upper quadrant, somewhat larger than on the previous admission and this time was interpreted as an enlarged liver. The mass was slightly tender on palpation. On this admission the icterus index was 23, and again the van den Bergh reaction was of the immediate obstructive type; urinalysis was negative; stool examination revealed no bile; red blood count was 4.36 million with a hemoglobin of 81% and a color index of .94; there was a leukocytosis of 15,500 with an essentially normal differential count. Again on symptomatic treatment he became afebrile and the mass in the right upper quadrant receded somewhat. He was discharged, a diagnosis of acute hepatitis having been made. He was readmitted to the hospital on the Surgical Service one week later for further investigation.

Past Medical History. Not remarkable.

Previous Operations. Uneventful tonsillectomy and adenoidectomy in October, 1946.

Family History. Irrelevant except for the fact that a paternal uncle died at the age of nine, reputedly with "yellow jaundice and gallstones."

Physical Examination:

General Appearance. On this admission the child was well nourished and well developed with a definite icteric tinge to the skin and the sclera. Temperature, 99.

Head, eye, ear, nose and throat. Negative.

Lungs. Clear to palpation, percussion and auscultation.

Heart. No arrhythmia, murmurs or enlargement were detected.

Abdomen. The superficial veins of the abdomen, as well as of the lower chest, were unusually prominent. The abdomen was slightly distended. A very large mass could be felt and seen in the upper abdomen extending approximately three fingerbreadths below the costal margin on the right and extending down somewhat less on the left. Beneath this mass on the right a second tumefaction could be felt extending well below the umbilicus and out into the right flank. The upper, larger mass was firm, moderately tender, and

was interpreted as liver. The lower mass had a cystic consistency and could be moved slightly, particularly in the transverse axis. The spleen was not palpable. Normal peristaltic sounds were heard on auscultation of the abdomen. No spasm or rebound tenderness were present. The costovertebral angles were negative.

Rectal Examination. Negative.

Remainder of physical examination negative.

Laboratory Findings:

Blood. Red blood count, 4 million with a hemoglobin of 80%; serology on two occasions, negative; clotting time, 4 min. 25 sec.; bleeding time, 1 min.; reticulocyte count, 1.5%; prothrombin time, normal.

Blood Chemistry. Admission icterus index, 35; urea nitrogen, 7 mg.%; fragility test revealed hemolysis beginning in a dilution of .34% and incomplete in a dilution of .26%; cephalin flocculation test, negative.

Urinalysis. Negative except for ++++ biliruria.

Stool Examination. Negative for bile.

Roentgen-ray Findings:

Chest and Abdomen. Flat film of the abdomen showed a great increase in density of the right upper and mid-abdomen. The lower half of the right kidney was outlined and was apparently of normal size, shape and position. From this film a roentgen-ray diagnosis of a large mass of the right upper and mid-abdomen was made. Roentgen-ray examination of the chest was negative.

Intravenous Pyelogram. No abnormalities of the urinary tract were visualized.

Gastro-intestinal Series. This showed marked displacement anteriorly and to the left of the first and second portions of the duodenum, apparently by a large extrinsic mass. Fourth-hour examination showed downward and medial displacement of the first portion of the transverse colon.

Preoperative Course in the Hospital.—The patient's temperature varied considerably during this period of observation, there almost always being slight fever, but recordings as high as 101 were made on several occasions. He was treated with glucose infusion, as well as a high-caloric, high-carbohydrate, and high-protein diet and was given large amounts of vitamin K daily. The low-grade jaundice varied considerably from day to day but subsided gradually, and the patient was icterus-free by the time surgery was performed. Episodes of severe abdominal pain occurred frequently, causing the child to cry bitterly. These attacks occurred most often immediately after meals. The cystic mass was found to change in size as much as 3-4 centimeters from day to day, a general regression in size occurring as his icterus subsided. Coincident with his general improvement and the decrease in icterus, one got the unmistakable impression that the mass had become much smaller.

A diagnosis of choledochus cyst was made and the patient prepared for laparotomy.

Operation.—Exploratory laparotomy; aspiration and biopsy of choledochus cyst; biopsy of liver; choledochocystoduodenostomy. (May 17, 1947.)

Anesthesia. Ether.

The abdomen was opened through a mid right-rectus incision. Upon opening the abdomen, the lower mass described previously was found to consist of a large, yellowish-tinged, tense, spherical, cystic structure covered with a veil-like layer of posterior peritoneum (see Figure 1). Just above this and extending bilaterally across the abdomen well beneath the costal margins, the diffusely enlarged liver could be seen, this apparently representing the firmer upper mass palpated preoperatively. The liver was of normal color but was somewhat granular in appearance. Jutting out from beneath the right margin of the liver and wedged between it and the cystic mass beneath was an extremely large, tense, thick-walled gallbladder, the latter appearing to be on top of the cyst. The duodenum had been greatly displaced and distorted and, instead of being in the usual

CHOLEDOCHUS CYST

position, was actually extremely anterior and to the left of the midline. It was greatly flattened out and ribbonlike, being drawn tightly over the anteromedial aspect of the cyst and conforming to the contour of the latter. The pylorus was quite far anterior and was also displaced somewhat to the left. The right transverse colon had been displaced downward and the hepatic flexure, downward and mesially. Although fairly well fixed,

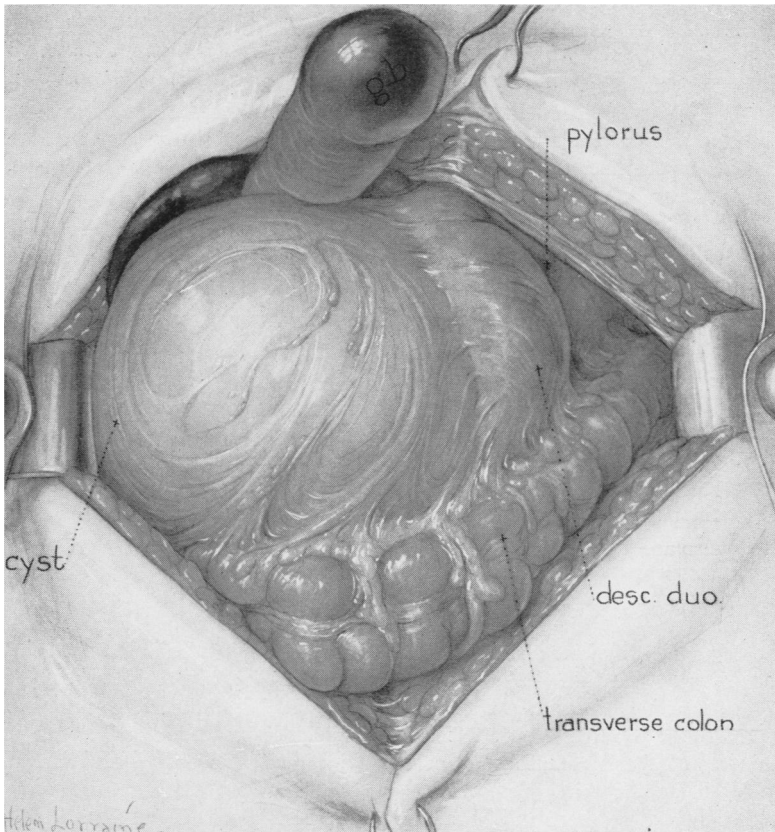


FIG. 1.—Artists' conception of the operative findings. The liver edge and the tense gallbladder can be seen beneath the right costal margin. The displacement of the transverse colon is also noted, as well as the marked anteromedial displacement of the duodenum and the pylorus.

the mass was found to be moderately movable in a transverse axis. The cystic duct was slightly enlarged in caliber and was found to empty into an apparently normal common hepatic duct just above the origin of the cystic mass. The common duct distal to the cyst appeared to be slightly enlarged on palpation but was otherwise negative. A number of soft hyperplastic lymph nodes were discovered in the region of the head of the pancreas, and there was a marked mesenteric lymphadenopathy. The small bowel was situated predominantly in the lower abdomen and to the left of the midline. Other than abnormalities resulting from displacement, the large and small intestines were negative. The head of the pancreas was displaced medially and anteriorly. The kidneys were normal in position and size on palpation, as was the spleen. Extensive dissection about the mass was not carried out nor were the extrahepatic biliary passages probed, inasmuch

as many previous authors have advised limited exploration once the operative diagnosis has been made in order to prevent unnecessary shock.

The posterior peritoneum overlying the cyst was incised, revealing the cyst wall to be quite thick. Using a tuberculin syringe and a hypodermic needle, several cubic centimeters of thin yellow bile were aspirated from the cyst. The abdomen was then carefully packed off with moist laparotomy pads and a trocar attached to a suction apparatus was introduced into the cyst. Seven hundred cubic centimeters of golden yellow bile were removed. A culture from this material was taken. Interestingly enough, as the bile was aspirated from the cyst, the gallbladder, which had previously been extremely tense, collapsed markedly. In view of the recommendations of other authors, notably Ladd and Gross, it was felt advisable to attempt immediate anastomosis between the cyst and duodenum without excision, either partial or total, of the former. The duodenum, because of its displacement, lay in an ideal position for a side-to-side anastomosis with the cyst. A biopsy of the cyst wall was obtained at this point, the wall being approximately 3 mm. in thickness, following which an anastomosis was effected. The stoma was situated in the first portion of the duodenum about one inch distal to the pylorus.

Following a complete change of gowns, gloves and drapes, a small biopsy was taken from the liver edge, the defect being closed with fine silk sutures. The wound was then closed in layers, using interrupted silk throughout.

During the operation the patient was given 500 cc. of whole citrated blood. He withstood the operation extremely well and returned to the ward in good condition.

Postoperative Course.—Almost immediately after operation the patient began to pursue a very stormy and hectic course. Unexplainable cyanosis was particularly troublesome during the first three or four days, making the administration of nasal oxygen imperative. Shortly after reacting from the anesthetic, the child began to vomit copious amounts of bile, necessitating the intermittent use of Wangensteen suction for seven or eight days. A marked tachycardia prevailed during most of the first postoperative week, and the temperature reached a peak of 102.6 on the fourth and fifth days; thereafter it began to subside. The skin sutures were removed from the wound on the sixth postoperative day, when the wound showed little evidence of normal healing. Abdominal pain was unusually severe and followed each attempt to take nourishment for many days. Parenteral supplementation consisting of Hartman's solution, 5% glucose, plasma, amigen, and blood were employed. Massive vitamin therapy, particularly large amounts of vitamin C and the B complex, and penicillin intramuscularly were also administered. Blood chloride on the third postoperative day was reported 525 mg.%. On the same day a red count was reported as 5.05 million with a hemoglobin of 112%, revealing some hemoconcentration. Moderate abdominal distention prevailed despite the use of the suction apparatus. On the eighth postoperative day, following a paroxysm of sudden vomiting, the wound disrupted throughout its entire length with evertion of small intestine. Sterile towels were immediately applied by the resident who was on the floor, and then the patient was taken to the operating room. His general condition was fair despite separation of the wound with protrusion of small intestine. A cannula was placed in the long saphenous vein, and he was given 250 cc. of plasma and the same amount of whole blood. It was noticed at the time of wound closure that the silk sutures were still intact, but there was no evidence of healing having occurred despite the postoperative administration of what had been thought to be adequate protein and large amounts of vitamin C. Following wound dehiscence with resultant evisceration, his course continued to be stormy, there being almost a persistent temperature to 100°. He gradually became able to take food, although for some weeks the ingestion of food caused some abdominal distention associated with cramplike abdominal pain. Normal-colored bowel movements were noticed on the tenth postoperative day. The silver wire sutures inserted at the time of secondary closure were removed on the twelfth postoperative day, when the wound had healed cleanly. Recovery of strength and weight was slow but progressive, and the

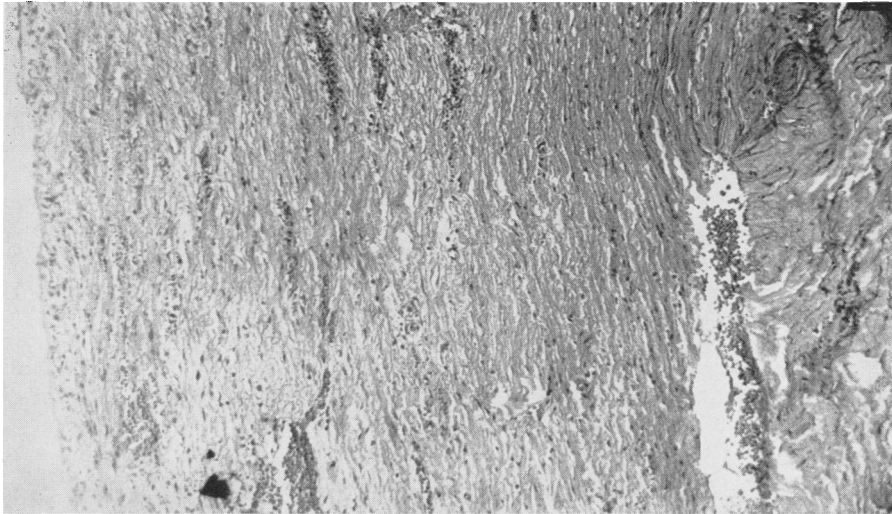


FIG. 2.—A photomicrograph of the cyst wall revealing the rather dense connective tissue and the lack of a definite lining membrane. (High power)

patient was discharged from the hospital on the twenty-seventh postoperative day asymptomatic and afebrile.

Pathologic Examination.—Microscopically the biopsy of the cyst wall was reported as showing moderately dense connective tissue which was relatively acellular and devoid of a proper lining (see Figure 2).

The biopsy of the liver histologically showed some excessive cellularity about the portal spaces and increased periportal fibrosis (see Figure 3).

The culture of the bile taken from the cyst revealed an almost pure growth of *Escherichia coli*.

Follow-up.—The patient was followed in the Outpatient Department for the first few weeks after discharge, his course for the most part being a steady improvement. Approximately six weeks after discharge from the hospital he experienced an episode suggestive of low-grade cholangitis, his mother stating that nausea, vomiting, temperature elevation, and a slightly icteric tinge to the sclera were noted. This attack, however, did not require hospitalization, his parents not even consulting the family physician, inasmuch as they had been warned before the child's discharge that such episodes might occur. He was last seen four months after operation, at which time he had gained approximately 5½ pounds and had been totally asymptomatic for two months.

COMMENT

The case presented would appear to be quite typical in practically all respects. The classical triad of mass, jaundice, and pain was present in this case, as were the less often emphasized symptoms of intermittent fever, occasional nausea and vomiting, and fluctuation in size of the mass. As would be expected, the findings characteristic of obstructive jaundice were present at the time the patient was admitted. Interestingly enough, as has been noted in the literature,³ the condition had previously been diagnosed as acute catarrhal jaundice and, on a second admission, as acute hepatitis. McLaughlin⁷ has remarked that an absolute preoperative diagnosis of choledochus cyst is impossible. However,

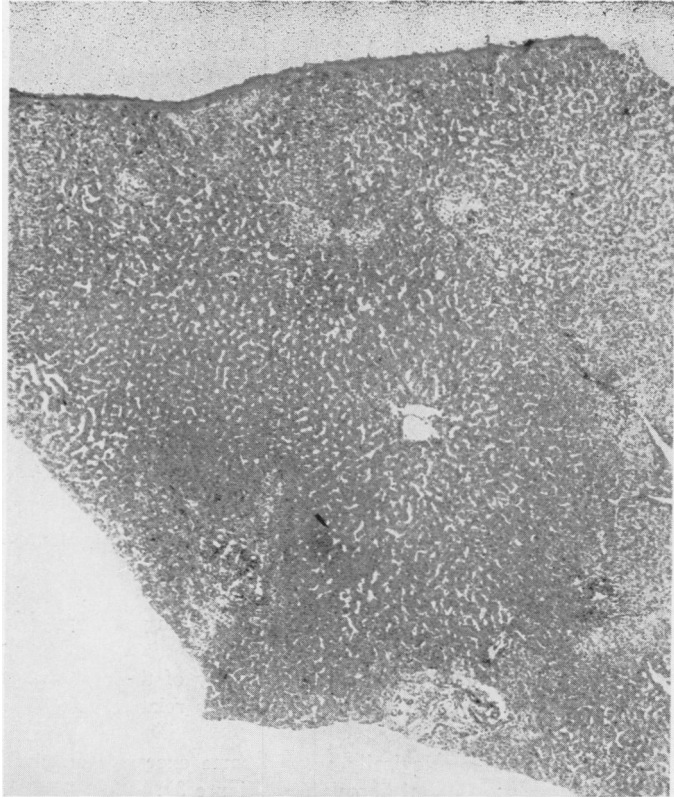


FIG. 3.—Photomicrograph of section of liver showing the increased cellularity about the portal spaces, as well as some increase in fibrosis. (Low power)

this case was considered to be such because of the typical and almost pathognomonic features of the case.

The surgical procedure carried out was that which apparently has been most generally recognized as giving the lowest mortality, namely, anastomosis of the cyst to the duodenum, which seems to us more accurately called choledochocystoduodenostomy than choledochoduodenostomy as in the past. Extensive dissection was not carried out, although more information could probably have been obtained by so doing. Inasmuch as most case reports, particularly those of Ladd and Gross,⁶ have demonstrated that prolonged dissection has often resulted in high mortality, only enough exploration was done to confirm the preoperative impression. Although the immediate postoperative course was quite stormy and complicated by wound dehiscence with resultant evisceration, the patient at his last examination four months later was asymptomatic and had regained his preoperative weight of 43 pounds, his discharge weight being 37½ pounds. An episode resembling mild cholangitis occurred six weeks after operation, presumably from retrograde infection from the large cystic pouch.

Pathologic examination of the liver revealed some increased periportal cellularity and fibrosis, which in general conforms to the microscopic picture of the case reports in which liver biopsy was done,¹⁴ although it was much less severe than in many. However, symptoms suggestive of marked liver involvement had subsided prior to the time of surgery. Examination of the cyst wall revealed a characteristic marked fibrosis with no evidence of a definitive lining membrane, this corresponding with most previous reports.^{6, 11, 14} According to the literature, many different organisms have been cultured from the contents of the cyst.^{11, 13, 14} *B. coli*, has often been found as was the case in this particular patient.

SUMMARY

A case of that unusual condition known as choledochus cyst diagnosed pre-operatively and apparently successfully treated by choledochocystoduodenostomy has been presented, as well as brief comments on its rarity and historical aspects. It is discussed briefly in the light of previously reported cases. Four months after operation the patient is asymptomatic, although initially he pursued a stormy course.

"The most recent check-up was made in June, 1948, at which time the patient was totally asymptomatic and weighed 48 pounds, this representing a weight gain of 10½ pounds over his discharge weight."

BIBLIOGRAPHY

- ¹ Berkley, H. K.: Idiopathic Dilatation of the Common Bile Duct in Childhood. *J. Pediat.*, **14**: 79, 1939.
- ² Blocker, T. G. and others: Traumatic Rupture of Congenital Cyst of Choledochus. *Arch. Surg.*, **34**: 695, 1937.
- ³ Bodley, J. W.: Choledochus Cyst; Case; *South. Surgeon*, **6**: 126-130, 1937.
- ⁴ Clark, J. H.: So-called Idiopathic Choledochus Cyst; Pathogenesis and Pathology; Report of Case with Review of Literature. *Internat. Clin.*, **1**: 78-103, 1932.
- ⁵ Judd, E. S., and E. L. Greene: Choledochus Cyst. *Surg. Gynec., & Obst.*, **46**: 317, 1928.
- ⁶ Ladd, W. E., and R. E. Gross: *Abdominal Surgery of Infancy and Childhood*. Philadelphia: W. B. Saunders Co., 1941.
- ⁷ McLaughlin, E. F.: Choledochus Cyst. *Ann. Surg.*, **123**: 1047, 1946.
- ⁸ McWhorter, G. L.: Congenital Cystic Dilatation of the Common Bile Duct. *Arch. Surg.*, **8**: 604, 1924.
- ⁹ Morley, J.: Congenital Cyst of the Common Bile Duct. *Brit. J. Surg.*, **10**: 413, 1923.
- ¹⁰ Saint, J. H.: Cystic Dilatation of the Common Bile Duct. *Brit. M. J.*, **230**: 1932.
- ¹¹ Shallow, T. A., F. A. Eger, and F. B. Wagoner, Jr.: Congenital Cystic Dilatation of the Common Bile Duct. *Ann. Surg.*, **117**: 355, 1943.
- ¹² Smith, D. C.: Cyst of Common Duct. *Arch. Surg.*, **44**: 963, 1942.
- ¹³ Taylor, J.: Cystic Dilatation of the Common Bile Duct: Record of an Example. *Brit. J. Surg.*, **16**: 327, 1928.
- ¹⁴ Zininger, M. M., and J. R. Cash: Congenital Cystic Dilatation of the Common Bile Duct. *Arch. Surg.*, **24**: 77, 1932.