

# PRESERVATION AND RESTORATION OF MANDIBULAR FUNCTION AND CONTOUR\*

LOUIS T. BYARS, M.D.

St. Louis, Mo.

FROM THE DEPARTMENT OF SURGERY, DIVISION OF PLASTIC SURGERY,  
WASHINGTON UNIVERSITY SCHOOL OF MEDICINE

MANDIBULAR FUNCTION AND CONTOUR are often jeopardized by operations, trauma, or infection. Immediate measures for preservation of function may suffice or be supplemented with secondary repair.<sup>3</sup>

## LIMITATION OF MOUTH OPENING

Trismus is a temporary inelasticity of the soft tissues between the jaws resulting from inflammation. Permanent fixation may be the result of several factors and may be classified as true or false ankylosis, depending upon whether or not the temporomandibular joints are involved. An accurate diagnosis of the cause is essential.

Surgery, trauma or infection in the neighborhood of the temporomandibular joints may result in either bony or fibrous obliteration of the joint (Figs. 1 and 2). Frequently the causative trauma is extensive and in addition to joint obliteration the coronoid process may be anchored to the zygoma. In such conditions adequate resection of the joint area, including the coronoid process if necessary, will give relief. More dependence should be placed on the adequate removal of bone at the site of the resection than on the application of some substance between the resected ends. All bone forming detritus must be removed.

This resection is commonly done from in front of the ear, reflecting the parotid gland and facial nerve forward and downward and elevating these structures outward from the bone. In certain simpler conditions it may be done from within the mouth. The most difficult ankylosis, represented by a broad, thick mass of bone and a short ramus, had best be approached from the neck, elevating all soft tissues, including the facial nerve and parotid gland, from the ramus of the mandible, beginning the resection on the ramus above the angle and working upward to include the condyle and coronoid process (Fig. 1). Such a resection causes very little dysfunction except to diminish the power of the bite and does not disturb dental occlusion, as does removal of the body of the mandible.

False ankylosis often follows depletion of the soft tissues connecting the jaws. Loss of mucosa, the full thickness of the cheek, or the skin of the cheek, if in large amounts, will have this effect. The removal of superficial lesions of cheek mucosa may be followed immediately or later by replacement with split thickness skin grafts. Deeper losses may require replacement with a pedicle flap.

---

\* Read before the Fifty-ninth Annual Session of the Southern Surgical Association, December 9-11, 1947, Hollywood, Florida.

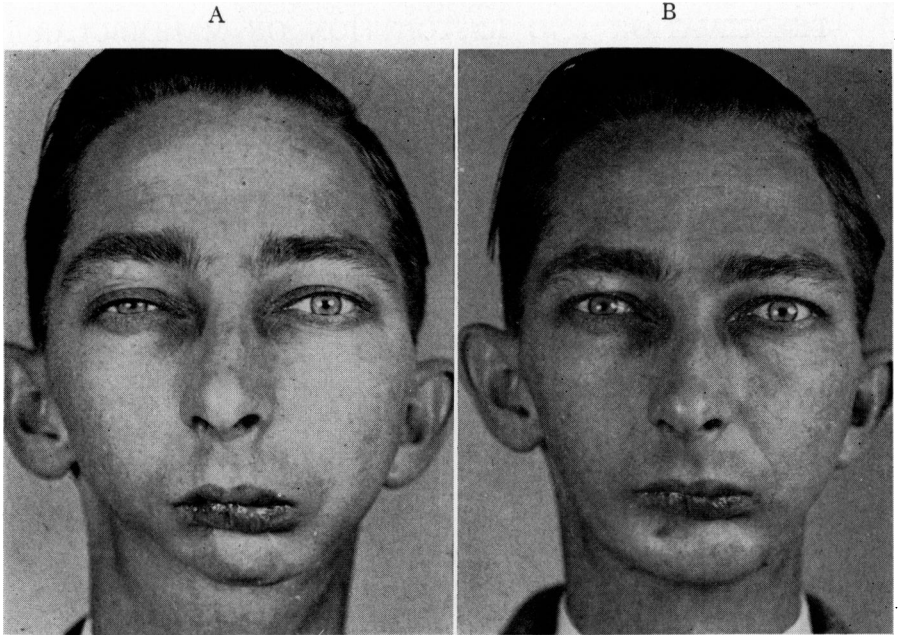


FIG. 1.—Ankylosis of 30 years' duration from infection in childhood. A. Note underdevelopment and asymmetry of mandible. Previous operations done elsewhere had failed because of reformation of bone at the site of the resection. Complete removal of the short, thickened ramus from angle up to the base of the skull on the affected side gave good mouth opening. The normal joint, though not used for 30 years, rapidly regained function. B. Note improvement of contour by overlaying mandible with implants of cartilage.

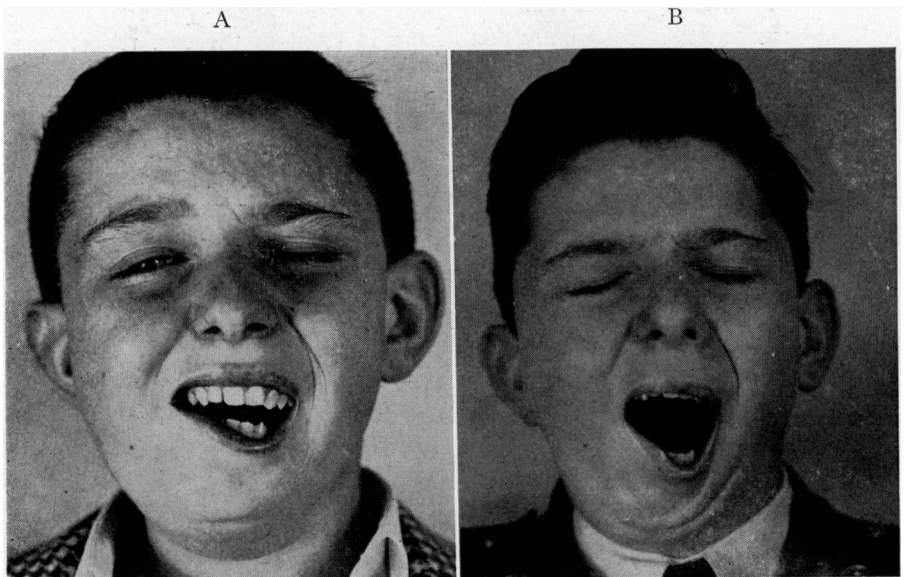


FIG. 2.—A. Partial ankylosis and paralysis of lower branch of facial nerve, from infection in infancy. B. Correction of ankylosis by resection of temporomandibular joint by a direct approach from in front of the ear, resecting an adequate amount of bone to prevent re-ankylosis.

Subsurface scarring in the region of scant clearance between the coronoid process and zygomatic arch may cause firm fixation in a closed position. Adequate resection of the coronoid process from within the mouth to release one point of scar anchorage will give relief. Depressed fractures of the zygomatic arch will produce impingement on the coronoid process, preventing mouth opening (Fig. 3).

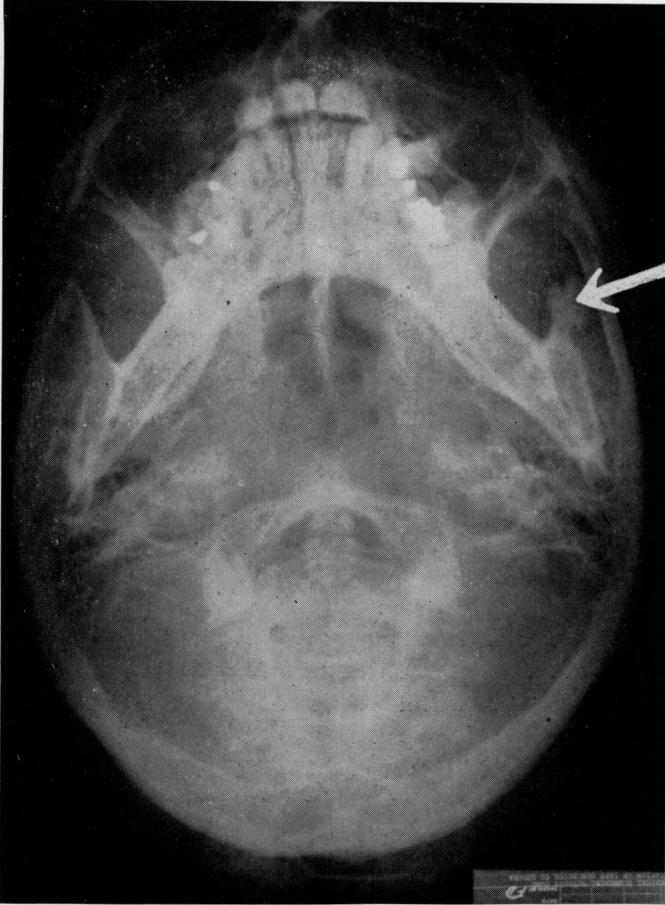

FIG. 3.—Illustrating one typical cause of limitation of mouth opening following fracture. A fragment of bone from the zygoma has been driven inward, impinging on the coronoid process, blocking its excursion. Removal of the coronoid process from within the mouth gave normal mouth opening.

#### SOFT TISSUE CONSIDERATIONS

At the time of injury or resection all possible soft tissue must be preserved (Fig. 4). In treating acute injuries of the face, debridement is not practiced to the extent often employed in wounds of other parts of the body. In operations for cancer large areas of soft tissues may be destroyed and

replaced later. Before a bone graft to the mandible is done, adequate covering for the graft must be present. If the quality or amount of tissue is

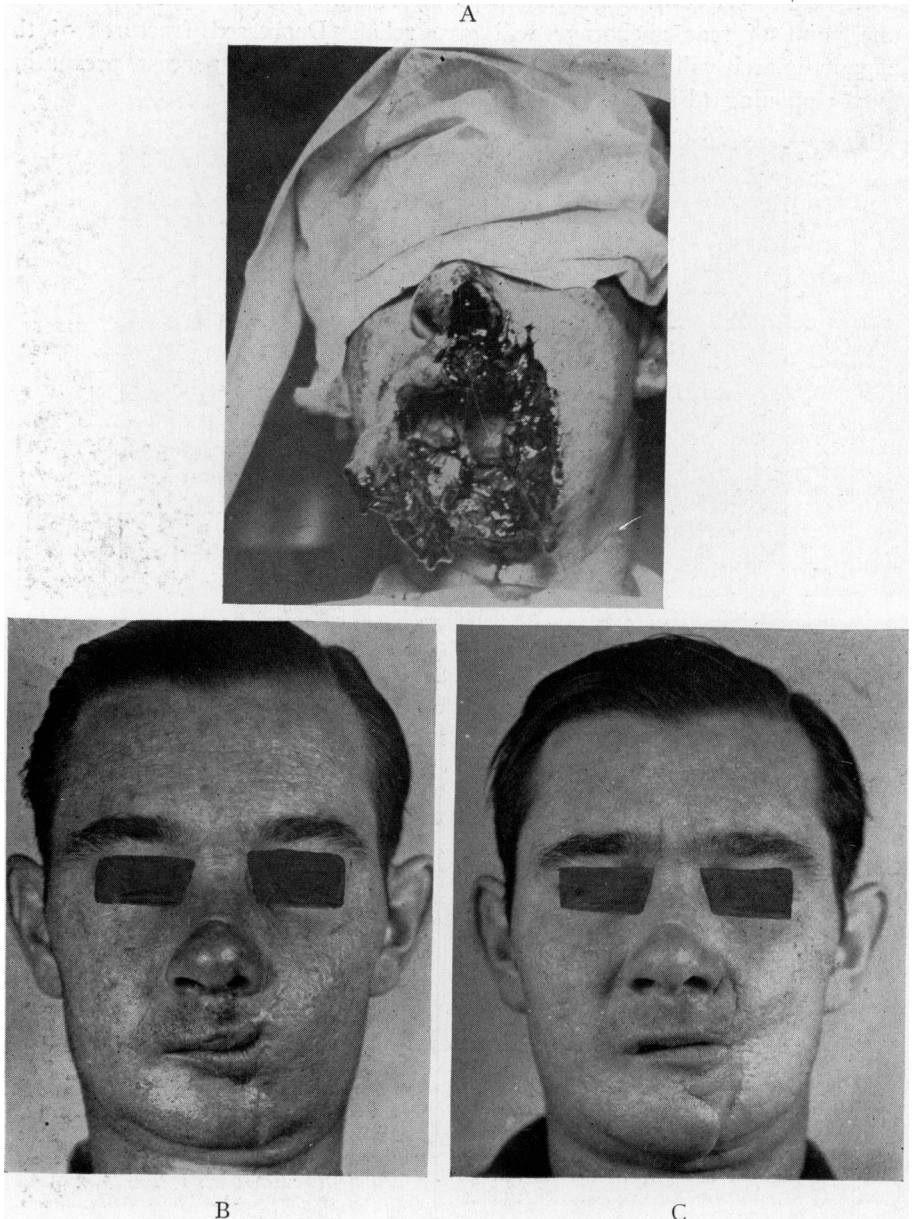
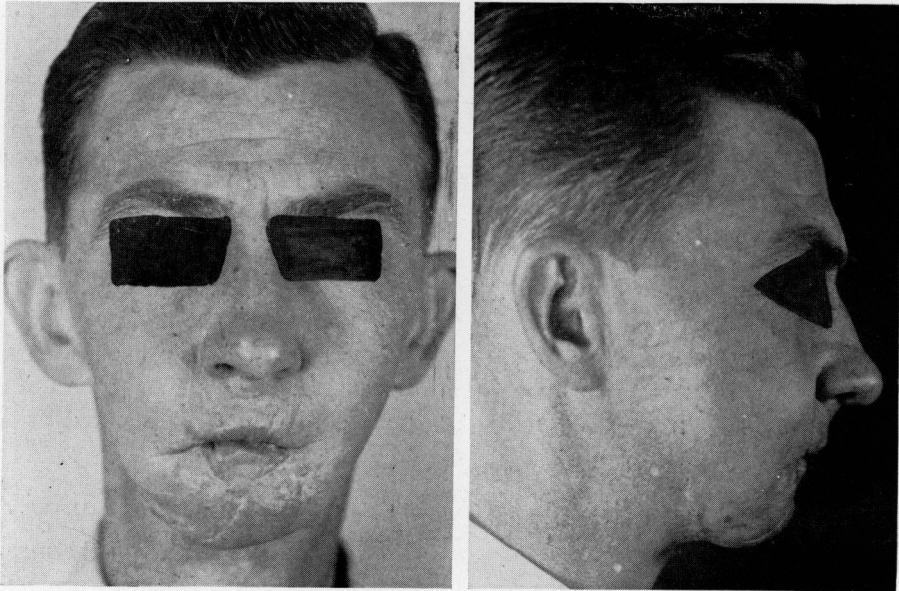
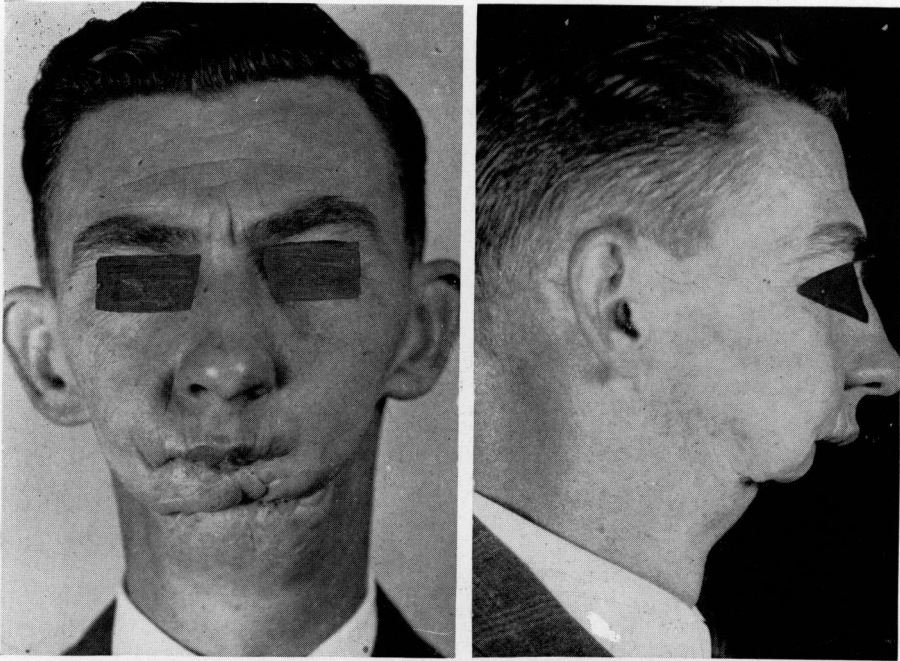


FIG. 4.—A. Extensive loss of soft tissue and bone of the symphysis region from gun shot wound. B. Result obtained at primary repair. All soft tissue possible was preserved. The remaining bone fragments were held in their proper relationship by interdental wiring. Note good contour of lower third of face as compared with narrowing from similar injury on patient shown in Fig. 5. C. Result following use of pedicle flap to inside and outside of mouth and successful bone graft to mandible. Pedicle flap similar to that illustrated in Fig. 6 was used.

A



B

FIG. 5.—A. Extreme soft tissue and bone loss from gun shot injury. Note narrowing of lower portion of face due to inward displacement of remaining bone fragments. B. Restoration by means of added soft tissue (Fig. 6) to give adequate covering for a bone graft and restoration of mandibular continuity by the use of two ribs extending from angle to angle, a double thickness of rib being used at the symphysis. Previous attempts at bone graft done elsewhere had failed because of inadequate soft tissue covering. (*Surg., Gynec., & Obst.*, 84: 870, 1947.)

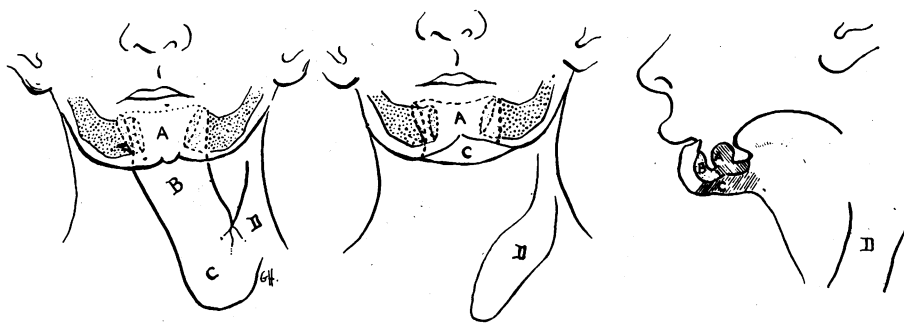


FIG. 6.—Diagram illustrating source and use of the pedicle flap for restoration of soft tissue loss in patient shown in Fig. 5. The tip of this flap was let into the mouth through a submental incision to replace the constricting and inadequate scar tissue between the ends of the bone. The center portion of the flap was used to line the labial sulcus; the proximal portion supplied the external covering of the chin and submental area; and the base of the flap was returned to the neck. (*Surg., Gynec. & Obst.*, 84: 870, 1947.)

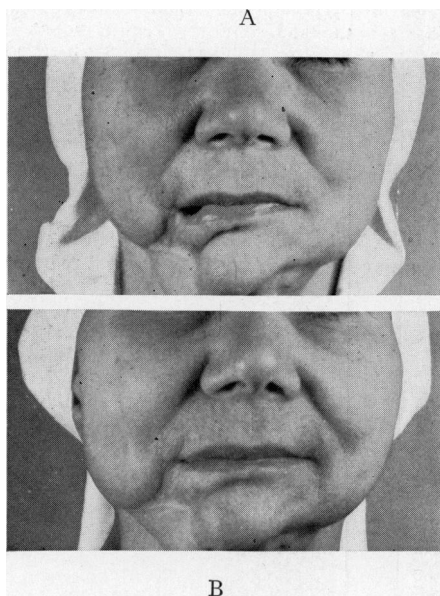


FIG. 7.—A. Original lesion was radiation necrosis of mandible and overlying skin of the cheek, lip, and chin. Patient shown after removal of damaged bone and full thickness replacement of soft tissue with pedicle flap from the lower neck and upper chest (Fig. 6). Continuity of the bone not re-established. B. Improved contour of the mouth and lower face following rib bone-cartilage graft to restore continuity of mandible and support of the soft tissues of mouth and pharynx and contour of face.

inadequate to cover the graft easily and heal readily afterward, it must first be supplemented with a skin graft pedicle flap, or by mobilization of local tissues. (Figs. 4, 5, 6, 7, 8).

Frequently the loss of a section of mandible is followed by a failure to maintain the remaining fragments in their proper relationship. This permits the ends of the bone to drift together by scar tissue pull so that the space occupied by the original fragment is no longer present. Under such circumstances the contracted scar tissue must be removed before a bone graft can be done. In some instances following this procedure a pedicle flap must be inserted prior to bone grafting.

#### MANDIBULAR RESECTION

Removal of a section of the mandible creates an immediate problem in management of the remaining fragments.<sup>1</sup> If not held in proper relationship, muscle pull may displace the fragments medially and backward, narrowing the pharyngeal

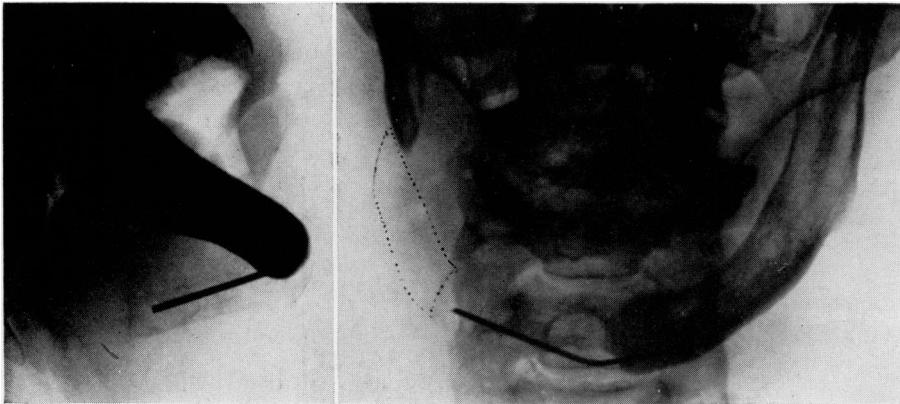


FIG. 8.—X-rays of patient shown in Fig. 7, mandibular restoration having been made with a rib and attached cartilage, the costochondral junction simulating the angle of the mandible. The inked-in portion represents unvisualized cartilage. Splinting was obtained by driving threaded bar into symphysis and impaling rib on this. The rib symphysis junction was strengthened by applying periosteum taken from other ribs. The cartilage end works in a soft tissue pocket in the region normally occupied by the upper ramus. In this particular type of restoration ordinary methods of splinting are not applicable.

TABLE I.—*Appliances Adequate to Control Fragments of Mandible Both after Resection and Bone Graft\**

A	
Posterior Fragment Edentulous	
a.	Arch bar or splint on mandible with posterior extension to hold posterior fragment in line
b.	As in "a" except splint attached to maxilla, supplemented by interdental wiring
c.	Internal bar fixation (Figs. 8, 9, 10, 11, 12)
B	
Both Fragments Edentulous or Teeth Not Suitable for Use	
a.	Open bite splint with circumferential wires (possibility of infection of bone graft)
b.	Internal bar fixation (Figs. 8, 9, 10, 11, 12)

\* Many appliances suitable for control of fragments after resection are not equally suitable for splinting bone graft because of danger of infection.

funnel, shutting off the airway, and making swallowing both painful and difficult (Fig. 9). When such a patient survives these initial hazards, the secondary repair of the bony defect is needlessly complicated by the necessity of restoring these fragments to their original relationship before the bone graft can be done. At the time of resection an accurate and careful soft tissue closure must be made, minimizing the drag of a contracting wound. Mandibular resection is usually performed as a planned proce-



ture so that an adequate scheme is prepared in advance.<sup>1</sup> Occasionally, however, one may be faced with a traumatic loss of bone, creating the same problem (Fig. 4). The simplest scheme for the control of bone fragments is to wire the teeth of the fragments to their corresponding maxillary teeth

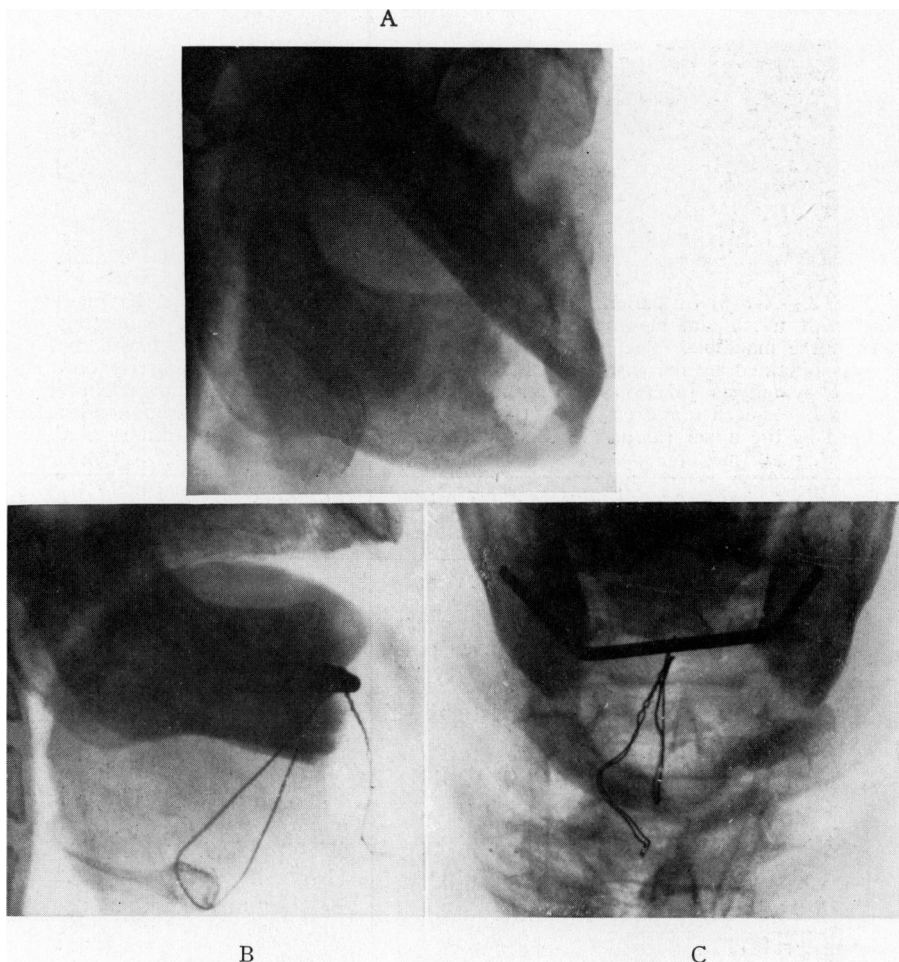


FIG. 9.—A. Roentgenogram of fibrosarcoma of the symphysis. B. and C. Same patient following resection of symphysis area with removal of considerable soft tissue. Symphysis resections especially jeopardize breathing because of the detachment of muscle support to the hyoid bone. The internal bar has been inserted in the fragments and the larynx is held forward in normal position by a stainless steel wire passed around the hyoid bone. Eventually this wire was removed. The bar has remained in place without complication. (*Surg., Gynec., & Obst.*, 84: 870, 1947.)

(Fig. 14). In the edentulous patient or in children, where dental development is inadequate, or in dealing with small posterior fragments, this method is not available. Table I indicates the mechanical possibilities which may be used to retain the fragments at the time of resection or as splints at the time of bone grafting under difficult conditions.



INTERNAL BAR FIXATION

A method of fixation applicable to traumatic loss of bone under adverse circumstances is the insertion of a bar of tantalum or stainless steel between the ends of the bones, replacing the resected or lost fragment with this sub-

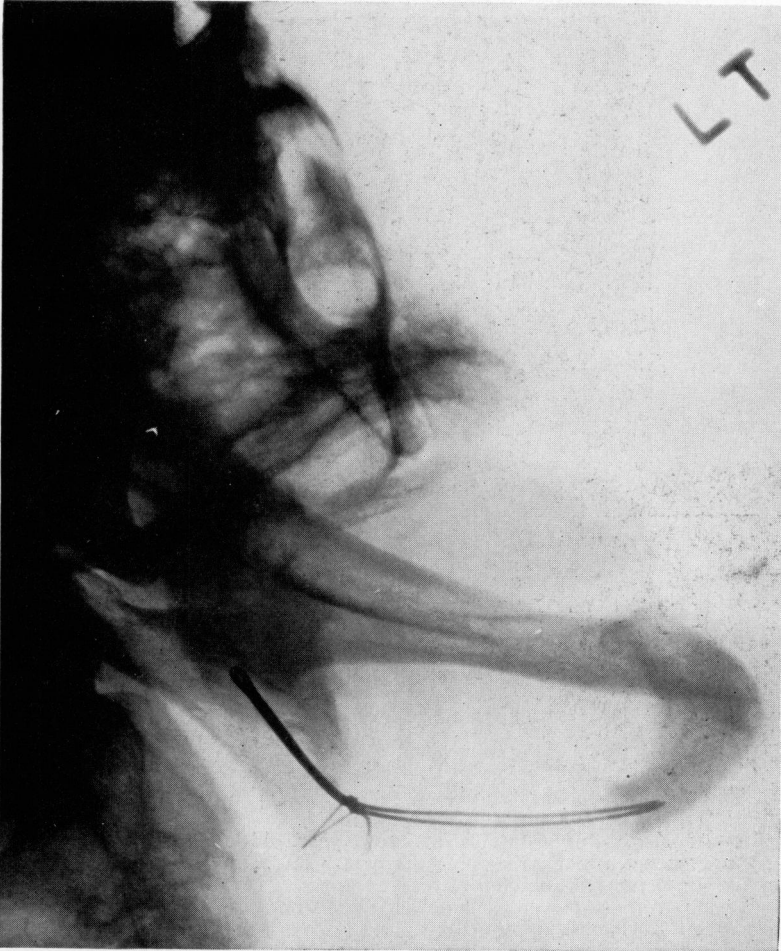

FIG. 10.—Mandible of an 85 year old man resected along with removal of large amount of soft tissue in treatment for carcinoma of alveolar mucosa. The internal bar as shown preserves pharyngeal support during the immediate postoperative period and although eventually extruded or removed, has remained in place in similar cases, sometimes for many months, giving the patient maximum comfort, even though age and prognosis do not warrant restoration of mandible. (*Surg., Gynec., & Obst.*, 84: 870, 1947.)

stitute<sup>3</sup> (Figs. 9, 10, 11, 12). Surprising rigidity results from this procedure, which may be regarded in some instances as a permanent splint for subsequent bone graft (Fig. 12), or in other instances merely as a temporary

stop-gap to carry the patient through the trying immediate postoperative time and the later period of wound healing (Fig. 10). Not infrequently mandibular resection with widespread soft tissue destruction is performed in cancer patients where restoration of mandibular continuity is not contem-

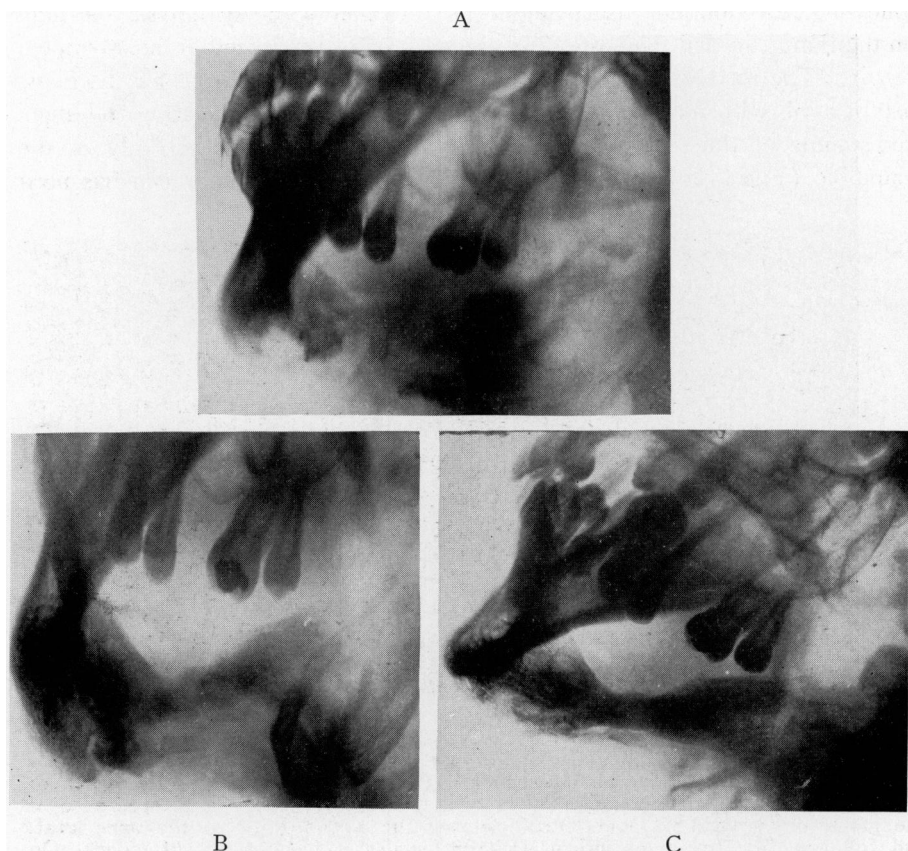


FIG. 11.—A. X-rays of mandible of an 8 year old child showing tumor later diagnosed microscopically as ossifying fibroma. B. X-ray following subperiosteal resection and insertion of stainless steel bar to control remaining fragments. No further fixation was employed and patient left the hospital healed in ten days. C. X-ray taken 28 months after operation showing strongly regenerated mandible and presence of original internal splint. The patient now is in her third postoperative year without any evidence of trouble from the stainless steel bar. X-ray evidence of regeneration was visible 7 weeks after the resection. The face is symmetrical. (*Plast. and Reconstruct. Surg.*, 1: 238, 1946.)

plated. Here it is desirable to maintain function as far as possible for the comfort and well being of the patient, as well as to have the remaining fragments eventually in as good a position as possible, even though their continuity has not been restored. Internal bar fixation has been very valuable under these circumstances. Such fixation has been maintained without difficulty for several months, in some instances, years, eventually working free. During this period, however, the open wound has healed without contracture,

which would pull the remaining fragments well out of position, had not such fixation been maintained. Even though the patient's age and disease may not warrant complete repair, the disability has been minimized. One extremely difficult problem has been the replacement of half the mandible following resection and disarticulation or resection at the symphysis and high on the ramus, so that the posterior fragment cannot be utilized in the attempted repair. The method which we have most commonly employed has been the use of a rib with its attached cartilage forming a curve simulating the angle and ramus of the mandible, the rib portion representing the body of the mandible (Fig. 7). With this type of repair the cartilaginous end has been

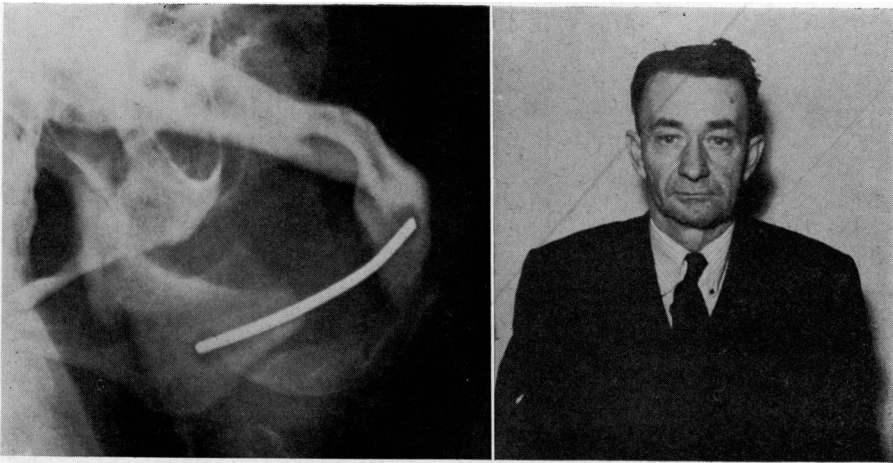


FIG. 12.—*a*. X-ray of resected edentulous mandible showing stainless steel bar inserted at time of resection and still in place six months later, having served as a splint for a bone graft done three months after the resection. No fixation or splinting other than this was used. Union is solid to palpation. *b*. Appearance of the patient subsequent to bone graft. During the period prior to the bone graft and following the resection, patient was comfortable and could eat soft foods. On palpation the bone fragments were not held rigid but were stable and the patient was comfortable.

inserted in the region near the temporomandibular joint and has worked as a false joint supported by soft tissue. The problem has been to get adequate fixation of the rib to the symphysis, inasmuch as there is no splinting of this fragment other than at the symphysis. All movements of talking or swallowing have a tendency to cause motion in the transplant. The drilling of a threaded stainless steel bar into the symphysis and the impalement of the rib on this bar, bent to the line of replacement, gives firm and adequate immediate fixation, which has been satisfactory for the support of the implant until bony union to the symphysis has occurred (Fig. 8). It is desirable to supplement the junction of the implant with the symphysis with other bone-forming material because of the small amount of bone in apposition when the end of the rib is abutted against the symphysis.

## SUBPERIOSTEAL RESECTION

Because resection of the mandible is a serious operation from the standpoint of disability, deformity, interruption of function, and difficulty of repair, it is desired to call attention to the operation of subperiosteal resection.<sup>2</sup> It has frequently been observed that the mandible will regenerate with sur-

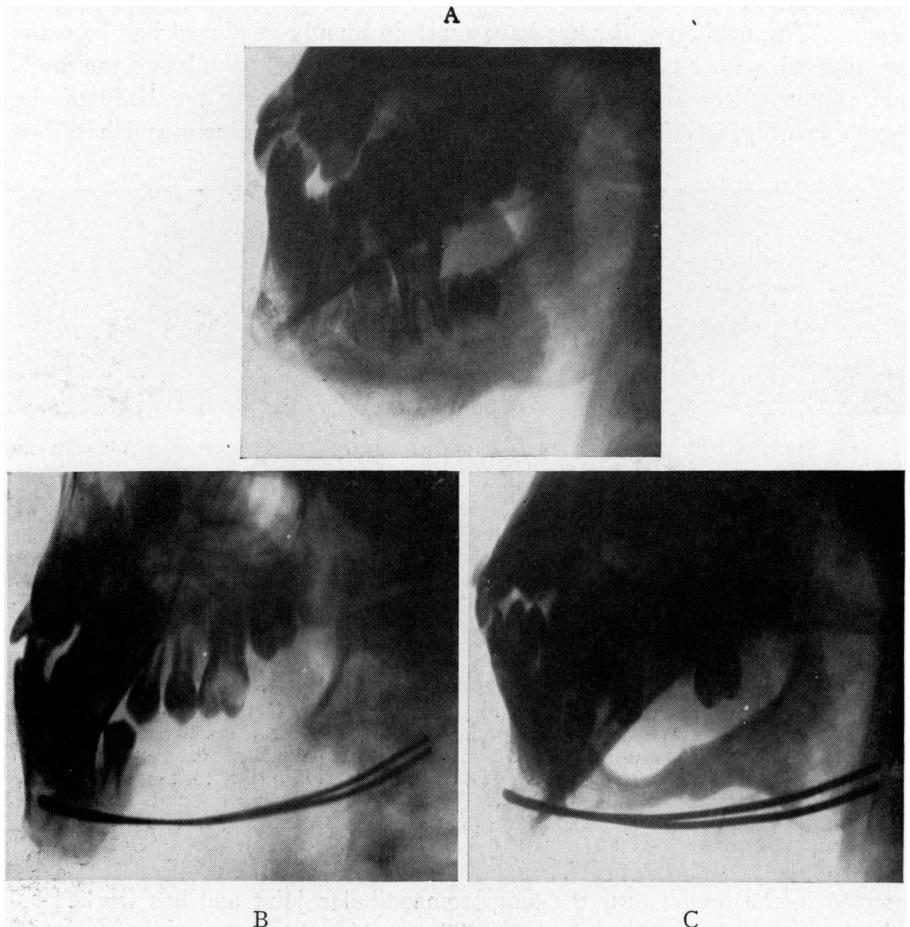


FIG. 13.—A. Destruction of mandible from osteomyelitis. There was a pathological fracture and subsequent sequestration of a large segment of mandible. B. Beginning regeneration 2 months later. C. Adequate regeneration 4 months after sequestrectomy. Similar regeneration occurs following subperiosteal resection. (*Surg., Gynec., & Obst.*, 84: 870, 1947.)

prising adequacy after the spontaneous sequestration of large segments following osteomyelitis (Fig. 13). Similar regeneration will occur following subperiosteal resection (Fig. 11). Obviously this procedure cannot have widespread application. Rarely would it be adequate in the treatment of any of the malignancies. Occasionally in dealing with the simpler tumors, such as adamantinomas, ossifying fibromas, or osteomas, which have caused extreme

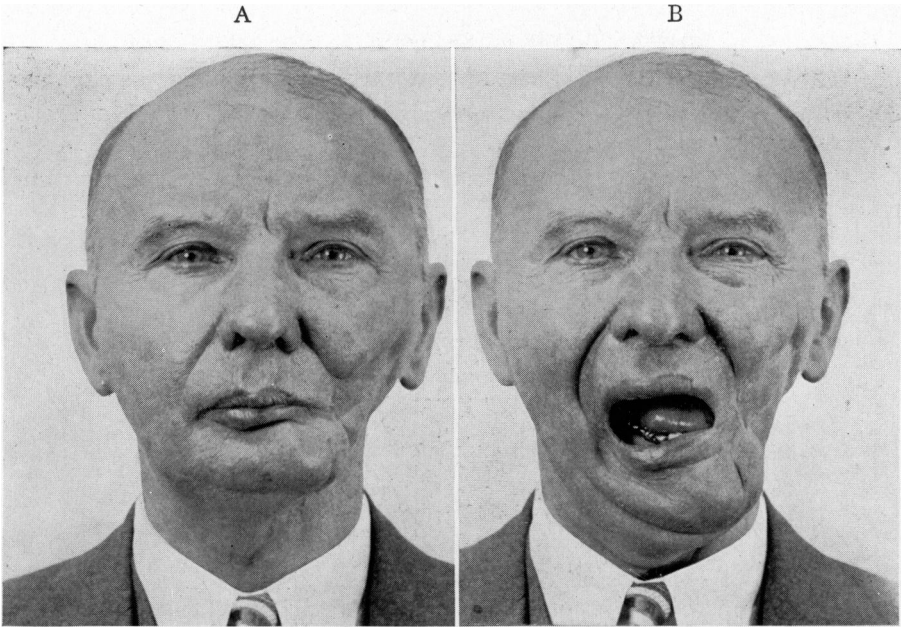


FIG. 14.—A. Resection of symphysis and disarticulation of half the mandible, along with removal of full thickness of the cheek for carcinoma. Such a wound may create sufficient traction in healing to displace remaining half of mandible markedly. Note relative symmetry of normal portion of face obtained by holding remaining fragment of mandible in occlusion throughout healing period. B. Mouth opening is possible because of the missing mandible on the left side. Such removal of soft tissue without replacement will greatly limit mouth opening if the mandible is intact. Maximum function short of reconstruction has been preserved. (*Surg., Gynec., & Obst.*, 84: 870, 1947.)

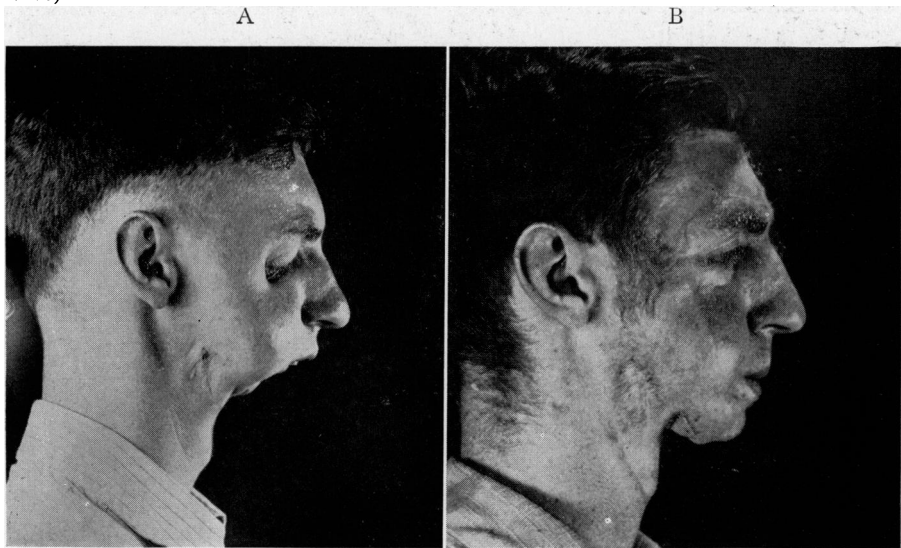


FIG. 15.—A. Extreme microgenia from early childhood infection. Functional improvement to a marked degree is not feasible because of weakness of the bite. However, some improvement in function and a great improvement in contour was gained ("B") by (1) building forward the mandible with cartilage implants, (2) supplying additional soft tissue to the chin, (3) creating skin graft lined pocket inside the lip, and (4) fitting with denture, utilizing a few remaining teeth and the cartilage implant for support.

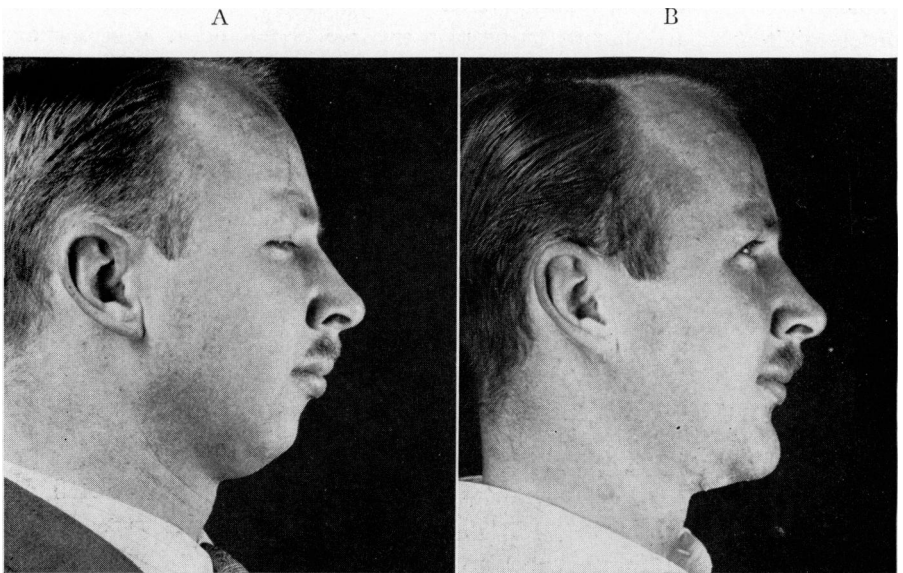


FIG. 16.—A. Congenital underdevelopment of the mandible with good function. Improvement of contour sought for professional reasons. B. Building forward the mandible with cartilage implant gave much more pleasing contour.

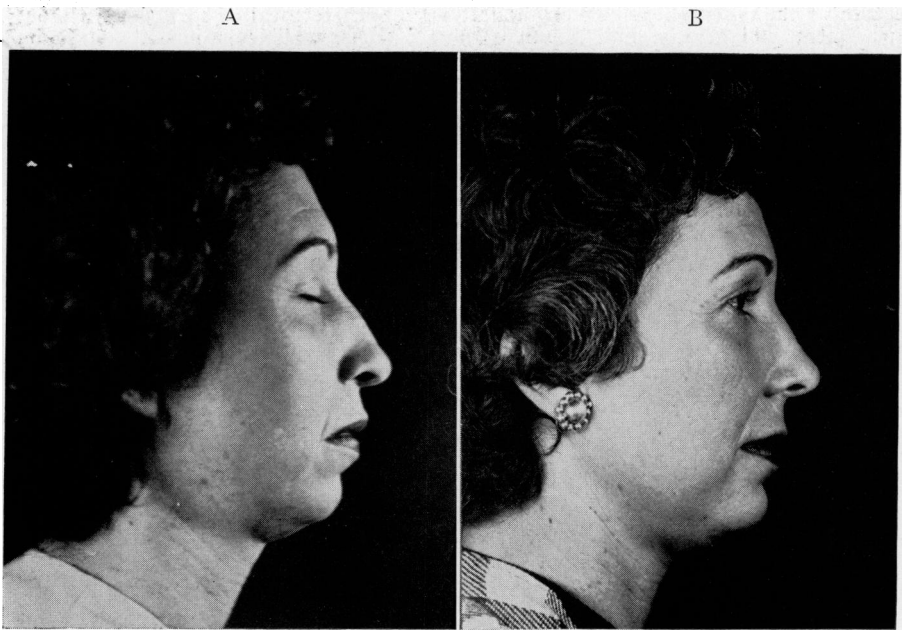

FIG. 17.—A. Congenital maldevelopment with unpleasing facial contour. B. Improved by bringing forward mandibular prominence with cartilage implant and correcting unattractive nose at the same operation by nasoplasty.



expansion of the bone, the entire thickness of the bone must be removed in order to effect a cure; but the periosteum is uninvolved and at least portions of it can be left bridging the gap between the ends. If these fragments are adequately controlled, regeneration will readily occur. In children especially the usual forms of splinting are often unsatisfactory, and in such cases internal bar fixation, counting on the bar to be permanent and to be rapidly supplemented as a supporting structure by regenerating bone, is the best scheme.

#### MANDIBULAR CONTOUR

In some instances of extreme underdevelopment or maldevelopment of the mandible, function cannot be restored to a normal degree because of

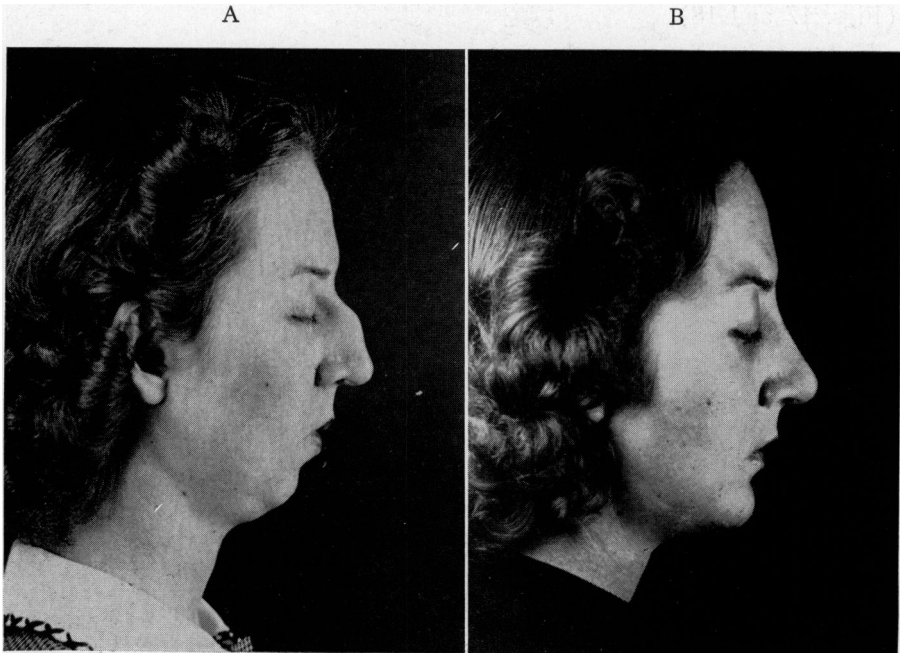


FIG. 18.—A. Condition similar to that illustrated in Fig. 17. B. Correction by cartilage implant to chin and nasoplasty. (*Surg., Gynec. & Obst.*, 84: 65, 1947.)

the lack of muscular power exercised by the closing muscles on the remnant of bone present. In such cases restoration of contour with good appearance of the patient is most important. In the extreme cases, not only must the solid prominence of the mandible be extended forward, but room for a denture to supplement the mandible still further must be created (Fig. 15). The first consideration involves the use of a cartilage or bone graft to the prominence of the mandible or to the flattened side, if asymmetry is present, to give as much prominence as possible (Fig. 1). In extreme cases soft tissue in the form of a pedicle flap must be supplied prior to the cartilage or bone implant in order to create room for it. Subsequently, additional space inside the lower lip must be obtained by the creation of a skin graft lined sulcus,

this combination building forward the solid portion of the mandible to form a shelf on which a denture can rest, and supplying room for the denture will give great improvement in appearance although there is little power to the bite. In less extreme cases where function is adequate, but the appearance is unpleasing, creating the missing contour with implants of cartilage applied directly to the bone as a single procedure will give good improvement in appearance. Such implants must be applied directly to the bone without a superimposed layer of soft tissue to insure solidity of the implant with the mandible (Fig. 16). Additional improvement in appearance may be often obtained by correction of other asymmetries of features, combining in some instances a nasoplasty with restoration of mandibular contour (Figs. 17 and 18).

#### OTHER CONSIDERATIONS

Fractures, limited removal of bone of the alveolus, as for tumor involving the alveolar ridge, or removal of soft tissue obliterating a sulcus, may interfere with the successful fitting of dentures. If an adequate alveolar ridge is present, the other factors usually may be corrected simply. Obliteration of the buccal sulcus can be corrected by adequate incision in the buccal sulcus and the application of a split thickness graft to maintain the depth of the sulcus.

#### REFERENCES

- <sup>1</sup> Byars, L. T., and B. G. Sarnat: *Surg., Gynec. & Obstet.*, **81**: 575-584, 1945.
- <sup>2</sup> Byars, L. T.: *Plast. & Reconstruct. Surg.*, **1**: 236-239, 1946.
- <sup>3</sup> Byars, L. T., and Frank McDowell: *Surg., Gynec. & Obstet.*, **84**: 870-877, 1947.

DISCUSSION.—DR. TRUMAN G. BLOCKER, JR., Galveston, Texas: I have enjoyed Doctor Byars' presentation a great deal and recognize his vast experience in handling cases requiring jaw restoration. In the army, where a large number of jaw reconstructions were necessary, our patients came to us with such loss of soft tissue or such intensive scarring in the area of bony loss that it was impossible to maintain occlusion of the intact fragment. We found, however, that when the scar tissue was replaced by a supple pedicle, the fragments tended to return to their approximate normal position, occasionally requiring elastic traction.

The toothless posterior fragment, even though it may be considerably misplaced, can frequently be brought into proper alinement at the time of bone grafting by stripping its muscular attachments and forcibly bringing it into position with a wire placed through the angle.

I feel that Doctor Byars' method of placing a bar between the fragments has considerable merit. But where there is loss of soft tissue or where the bone is exposed, I would be hesitant to use an internal splint because of the danger of infection.

DR. LOUIS T. BYARS, St. Louis, Mo. (closing): I have heard this method of repair criticized and the statement made that good results often were not obtained by it. I believe when the results are disappointing it is because the operator does not have the courage to do the tremendous amount of overcorrection that is necessary and, in the subsequent relaxation, the support is lost. I have never seen one that was overcorrected, and I have seen a number where strips had been tightened or should have been tightened later.