

RETROGRADE INTRAGASTRIC INTUSSUSCEPTION OF THE JEJUNUM FOLLOWING SUBTOTAL GASTRECTOMY*

REPORT OF A CASE, APPARENTLY THE SECOND SUCH IN THE LITERATURE

ALLEN E. GRIMES, M.D., F.A.C.S.

LEXINGTON, KENTUCKY

RETROGRADE INTUSSUSCEPTION of the jejunum following subtotal gastrectomy is so rare as to be a medical curiosity. A search of the literature reveals only one comparable case. It was reported by McNamara in 1944.

Case Report.—JKW, white, male, age 55, was seen first on December 26, 1945. His chief complaint was stomach trouble. It began 18 years ago characterized by bloating and epigastric pain which was relieved by soda. His first hemorrhage occurred 13 years ago, the vomitus had a coffee ground appearance and the stools were tarry for several days. In recent months the patient experienced severe heart burn and often vomited small amounts of sour material with relief. On November 16, 1945, he had a gastric hemorrhage and was given a transfusion of 1,000 cc. of blood. Pain and discomfort became more frequent after the hemorrhage, and was the reason for the patient entering the hospital. Roentgenograms over a period of years, done in Lexington and elsewhere, revealed a duodenal ulcer. In addition, during the past year the patient had nocturia 3 to 4 times and some dribbling. Eighteen years ago he had had a left inguinal hernia repaired and left orchidectomy, probably for an undescended testis. There was a recurrence of the hernia 6 years later. Appendectomy had been done 17 years ago. On 12-27-45, a subtotal gastrectomy was done by me for a recurrent, bleeding, chronic duodenal ulcer, and posterior Polya type of anastomosis was done. Convalescence was uneventful.

The patient re-entered the hospital 4-12-48 on the urological service of Dr. Douglas Scott, at which time his chief complaint was gradually increasing urinary frequency and difficulty in voiding. Since his stomach operation, he had only an occasional episode of upset stomach with slight vomiting. Urologic investigation revealed a bladder capacity of 8 ounces without residual. The K.U.B. was negative, B.U.N. 19 mg.%, Rbc. 4.6 million, Hgb. 91%, urine negative. On 4-15-48 at 8:35 A.M. the patient went to the operating room for a transurethral resection. Spinal anesthetic was induced with 8 mg. of procaine in glucose and spinal fluid between the 3rd and 4th lumbar vertebrae. One-quarter cc. of neosynephrin was given, hypodermically, at the same time. The systolic B.P. ranged from 110-124-92-112 during the operation. A trilobar enlargement with ball-like median lobe was found. Twenty-seven grams of benign tissue was removed and a right vasectomy was done. Before the operation was completed the patient became nauseated and retched violently several times. Vomiting persisted at frequent intervals after the patient returned to his room. The vomitus was at first dark reddish-brown and later appeared to be bloody. This was accompanied by severe cramping pain localized to the U.L.Q. It was not relieved by morphine, $\frac{1}{4}$ grain. I saw the patient the following afternoon and examined him at 4 P.M. He stated that since his stomach operation he had been relatively free from indigestion except for occasional nausea and vomiting of clear material and infrequent heart burn.

Examination revealed an acutely ill patient. His skin was pale and clammy. He was vomiting small amounts of dark bloody, odorous material at frequent intervals and complaining of severe cramping pains in the U.L.Q. The temperature was 97°; the pulse was 90, regular and of good quality. The B. P. was 108/88. The abdomen in this rather

* Submitted for publication, October, 1948.

INTRAGASTRIC INTUSSUSCEPTION

thin man was scaphoid and soft with slight tenderness in the U.L.Q. There was no rigidity, masses, or palpable organs. Upper right rectus, lower right rectus and left inguinal scars were present with a hernia in the latter. Clear urine was passing freely from the indwelling catheter. The R.B.C. was 4.9 million and the Hgb. 91%. Wangensteen suction was started and afforded the patient immediate relief. Blood, glucose, vitamins and amigen were given intravenously. For the next six days the patient continued to vomit at irregular intervals in spite of the indwelling intragastric tube which was in place most of the time. The vomitus was always a dark, foul, bloody material. The (R) temperature ranged from 99° to 100°. The pulse approximated 110. On 4-20-48 the leucocyte count was 18,100 with 72 polys. On 4-23-48 a barium meal was given which revealed a greatly dilated

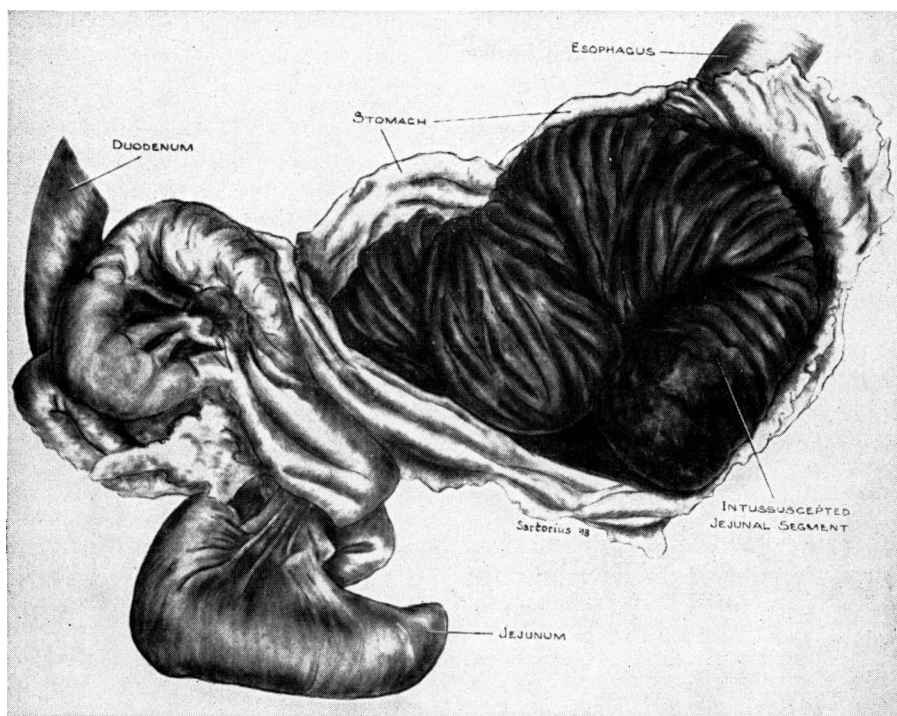


FIG. 1.—Postmortem specimen shows the opened stomach with the intussuscepted jejunum.

stomach of which the distal half had been removed. There was a deformity which suggested a penetrating ulcer at the junction of the jejunum with the stomach. The 5-hour film showed 90% gastric retention.

On 4-24-48 the patient's condition became worse and an enterostomy was done under local anesthesia through a small upper left rectus incision. Feedings of milk, custard and amigen were given through the tube at 2-hour intervals. The patient's condition was unimproved and vomiting continued. On 4-27-48, in spite of four transfusions of 500 cc. each of blood, the R.B.C. was 3.4 million, the Hgb. was 65%, the Wbc. was 24,900 with 84% polys. At 5:30 P.M. the abdomen became very tender, rigid and distended in the upper one-half. The pulse became weak and imperceptible, the skin cold and clammy and the patient died at 11:50 P.M.

Autopsy.—The abdomen was somewhat distended. On opening the peritoneal cavity there was found four or five hundred cc. of turbid, coffee colored fluid. Peritonitis extended from the pelvis to the under surface of the liver. The stomach was greatly

enlarged and when palpated a rough, soft mass could be felt within the lumen. The lower half of the stomach had been resected, and when the stomach was opened a large brownish-black corrugated mass was seen. A retrograde jejuno-gastric intussusception of the efferent portion of the jejunum had occurred through the gastrectomy stoma, making a cylindrical mass measuring 17 cm. in length and from 6 to 8 cm. in diameter. The distal end was necrotic and dark in color. The portion of the small intestine below the intussusception was grossly negative. The site of the recent prostatic transurethral resection was not unusual.

Discussion.—Intussusception is usually considered a disease of infants and young children. In these age groups it is one of the most important surgical emergencies. The process is often progressive and frequently without known cause. In adults the condition is usually brought about by some mechanical abnormality. In all age groups the direction of the intussusception is usually descending. According to Baumann there is one ascending to 200 descending types. In 1923 Drummond called attention to retrograde intussusception of the jejunum following gastro-jejunosomy. He reviewed the 11 cases previously recorded in the literature; two in England, nine on the Continent, and added his case which made 12 in all. His chief interest in the problem lay in the difficulty in explaining why it should occur in a few cases only and what steps could be taken in preventing it, or its relapsing as in the case of Baumann. He thought that occasionally rapid emptying of acid gastric content into the jejunum might result in forcible antiperistaltic action. The type of gastro-jejunosomy seemed to be of no consequence. In the first 12 cases reviewed, five were the anterior type, five were posterior type and no mention was made of the type in two cases. Enteroanastomosis had been done in five of the 12 cases. With the increasing popularity of gastro-jejunosomy in the treatment of peptic ulcer by 1935, Debenham was able to collect 35 cases of retrograde intussusception of the jejunum and added a case to the series. He was surprised that this complication was not reported until 1917, although gastro-jejunosomy was first performed in 1881. In the recorded cases the incident occurred from six days to 16 years after the original operation. The length of involved segment varied from 4 cms. to 2 metres and the type and size of the stoma apparently played no part in initiating the process.

Chesterman thought that the condition was of sufficient interest to warrant record by virtue of its rarity, the ease of diagnosis if its possibility is remembered, and the hopeless prognosis without early surgical intervention.

According to the collected reports the symptoms seem to follow a rather definite pattern. Following at variable periods after gastro-jejunosomy there is a sudden onset of cramp like upper abdominal pain which frequently doubles the patient up. This is followed by vomiting, first of food and bile and then bloody fluid. As the pain and vomiting continue the patient's skin becomes pale and clammy. Rigidity and distention do not appear early, nor is tenderness constant. The presence of a soft tumor in the upper abdomen has been noted in about one half of the reported cases. Early surgical intervention with reduction of the intussusception, or resection has yielded good results.

Sufficient interest has been aroused and attention focused on retrograde

jejuno gastric intussusception so that each year finds new cases added to the increasing number recorded in the literature. A very careful search, however, reveals but one case comparable to the one I report. In 1944, McNamara reported the first case of retrograde jejuno gastric intussusception through a subtotal gastrectomy stoma. So far as I can determine, the present case is the second such appearing in the literature. The etiology is speculative. However, since the onset was sudden and acute during an operative procedure one is inclined to carefully evaluate the anesthetic and the operation for contributing or precipitating influence. It is an accepted fact that patients receiving a spinal anesthetic may become nauseated and vomit. A transurethral resection rarely, if ever, initiates vomiting. I believe it more reasonable to attribute the vomiting in this patient to the anesthetic agent. Since it was so violent it is most likely that it was the influence in precipitating the retrograde intussusception. The repeated vomiting indicated a high obstruction, but the cause of the foul, bloody vomitus was erroneously deduced. In view of the past history of gastric resection for a bleeding ulcer and the subsequent, although mild recurrence of dyspepsia, the condition was first attributed to an obstructing, bleeding, marginal ulcer. Because of the high resection the remaining segment of stomach was beneath the thoracic cage and a tumor was never felt.

The explosiveness of the symptoms in the now two reported cases of retrograde jejuno gastric intussusception through the gastric stoma are quite similar to the same process in the more frequently occurring intussusception following gastro-jejuno stomy. Characteristics are the sudden onset of severe cramping abdominal pain, persistent vomiting of bloody material, shock and in some cases the presence of a soft tumor in the upper abdomen. If the condition is known and its possibility is remembered the diagnosis should not be too difficult. The prognosis is hopeless without early surgical intervention.

BIBLIOGRAPHY

- ¹ Baumann: Quoted by Drummond.
- ² Chesterman, J. T.: Retrograde Jejunogastric Intussusception. *Brit. J. Surg.*, **21**: 541, 1934.
- ³ Debenham, R. K.: Retrograde Intussusception of the Jejunum Following Gastro-Jejunostomy. *Brit. M. J.*, **1**: 250, 1934.
- ⁴ Drummond, Hamilton: Retrograde Intussusception of the Small Intestine after Gastro-enterostomy. *Brit. J. Surg.*, **11**: 79, 1923.
- ⁵ McNamara, W. L.: Retrograde Jejunogastric Intussusception Through a Subtotal Gastrectomy Stoma. *Amer. J. Surg.*, **120**: 210, 1944.