

THE SURGICAL TREATMENT AND THE PHYSIOPATHOLOGY OF COARCTATION OF THE AORTA* †

R. J. BING, J. C. HANDELSMAN, J. A. CAMPBELL,
H. E. GRISWOLD, AND ALFRED BLALOCK
BALTIMORE, MD.

FROM THE DEPARTMENT OF SURGERY OF THE JOHNS HOPKINS UNIVERSITY
AND THE JOHNS HOPKINS HOSPITAL

COARCTATION OF THE AORTA belongs to the group of congenital cardiovascular malformations in which arteriovenous shunts are absent, and in which there is no cyanosis. Fortunately, diagnosis is not difficult in most cases if one recalls that there is usually hypertension in the upper part of the body and hypotension below. There is usually evidence of increased collateral arterial pathways in the upper part of the body, absence or suppression of arterial pulsations in the lower extremities, and notching of the ribs in the older patients. A systolic murmur may be present. The stenosis or atresia can usually be visualized by angiocardiography. The complications associated with severe coarctation include those accompanying hypertension due to other causes.

This paper consists of a consideration of the surgical treatment and the physiopathology of coarctation of the aorta. The surgical treatment will be considered first.

The first method for treating coarctation was published by Blalock and Park¹ in March, 1944, in a paper entitled "The Surgical Treatment of Experimental Coarctation (Atresia) of the Aorta." In brief, this method consisted of using the left subclavian artery as a pathway by which the blood could be shunted beyond the point of stenosis. The use of this method was not attempted on patients at this time, and in the latter part of 1945 Crafoord and Nylin² and Gross and Hufnagel³ reported a better method. This consisted of excision of the stenotic area and the performance of an end-to-end anastomosis between the proximal and distal ends of the aorta. The first operation on a patient by Crafoord was on October 19, 1944, and that by Gross on June 28, 1945. Clagett⁴ of the Mayo Clinic was the first to use the subclavian artery to by-pass the point of stenosis in patients.

Everyone is agreed that the ideal operation is one in which the stenotic area is excised and the proximal and distal ends of the aorta are united by suture. Unfortunately there are some instances in which this does not appear to be feasible. Most frequent among these are those cases in which the atretic area is long and those in which the aorta is so diseased that end-to-end suture following excision is not feasible. The question has been raised as to whether one should employ the left subclavian to by-pass the point of stenosis if the ideal operation cannot be performed. It is our contention that this method

* Aided by a grant from The Commonwealth Fund for Physiological Study of Congenital Heart Disease, and The Carolyn Rose Strauss Foundation, Inc. for Diagnosis and Treatment of Congenital Cardiovascular Defects.

† Read before the American Surgical Association, Quebec, Canada, May 29, 1948.

should be used providing one does not have to sacrifice the large intercostal collateral arteries which arise from the aorta just beyond the point of stenosis. It is usually possible to save these blood vessels. It is our impression that the transposed subclavian artery will convey more blood to the lower part of the body than will the collateral vessels from the undivided subclavian artery.

There are several points about the technic of the operation which are worthy of brief comment. The first of these is concerned with the incision. In some of the earlier operations the posterior half of the fifth rib was removed and the paravertebral ends of the fourth and sixth ribs were divided. We now follow the recommendation of Crafoord in removing practically the entire length of a rib, usually the fifth, and it is not necessary to divide other ribs. An adequate exposure is obtained and there appears to be less discomfort and dyspnea in the postoperative period. Furthermore, there is less damage to intercostal blood vessels.

In the earlier operations which we performed, one or more pairs of intercostal arteries immediately distal to the point of coarctation were doubly ligated and divided. With additional experience we now follow the advice of Crafoord in trying to spare these arteries. In the first place these vessels are very large and thin walled, and one may encounter troublesome bleeding as a result of attempted ligation and division. In the second place these arteries are important collateral pathways, and it is particularly important to preserve them in case difficulty should be encountered in completing the anastomosis. The intercostals just distal to the coarctation may be occluded with one or more rubber-shod clamps. Fortunately, these vessels run upwards and do not interfere with approximation of the ends of the aorta while the anastomosis is being performed.

In the majority of patients with coarctation of the aorta the point of stenosis is only a short distance beyond the point of origin of the left subclavian artery. Obviously one can occlude the left subclavian artery as well as the aorta during the time required for excision of the stenotic area and the performance of an end-to-end anastomosis, but this decreases the quantity of blood which reaches the lower part of the body during this procedure. We have been able to escape this added danger by using a modified Potts arterial clamp which occludes the aorta completely, but permits some circulation through the subclavian artery. This clamp is introduced in the free space between the points of origin of the left common carotid and the left subclavian arteries. It is shown in place in Figure 1.

A single layer of sutures which includes the entire thickness of the wall of the aorta has been used in our operations and in those by Gross. This point is mentioned because Crafoord has attempted to avoid inclusion of the intima of arteries in his anastomoses. It is our opinion that one obtains a smoother intimal surface and a stronger arterial wall with less tendency to the formation of aneurysms when the entire thickness of the wall of the vessel is included in the suture.

It is probably a matter of personal choice as to whether one employs an everting or an overhand suture in performing the anastomosis. We prefer the former type because it leaves less suture material and smoother intimal surfaces in contact with the flowing stream of blood. The suture material which we use is 0000 silk on small round needles (Deknatel).

Following the completion of the anastomosis, we have followed the advice of Gross in releasing the occlusion of the aorta slowly and at the same time lowering the patient's head and introducing blood intravenously rather rapidly. In one patient the heart's action became slow and feeble but it improved on reapplication of the clamp. Subsequent removal of the clamp was tolerated without incident.

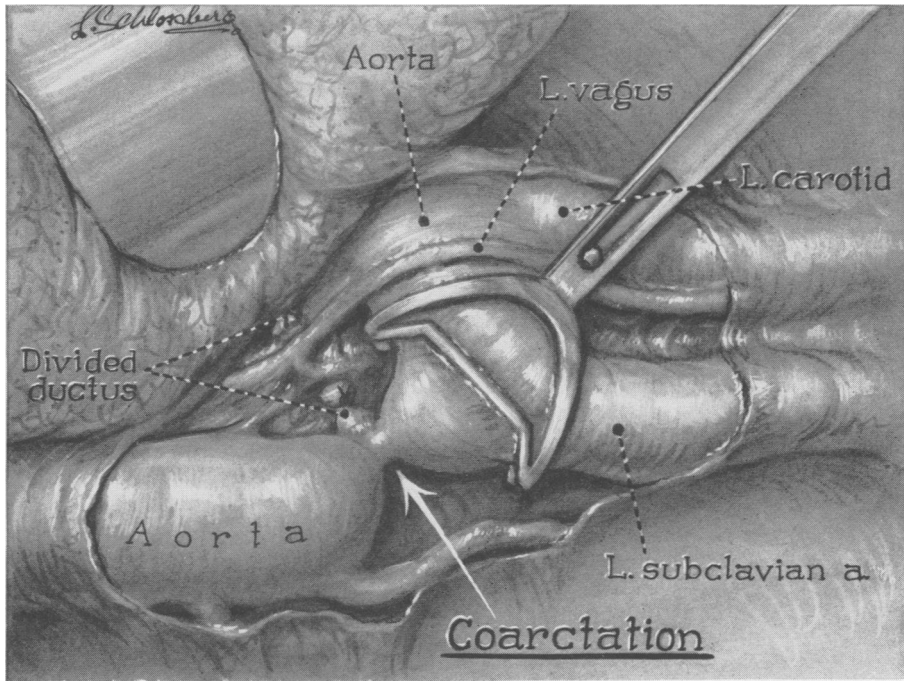


FIG. 1.—Illustrates the modified Potts clamp in position. It may be seen that while it occludes the aorta completely, it permits blood to flow through the subclavian artery.

Our operative experience is limited to 23 patients with coarctation of the thoracic aorta. The ages varied from 7 to 31 years. Thirteen of the patients were 20 or more years of age. An anastomosis was attempted in 22 of the 23 cases and was completed in 21 of them. In the one case in which the anastomosis was not attempted the site of coarctation was several interspaces below the usual site and the constriction was longer than usual. Furthermore, the distal aorta was somewhat hypoplastic and was surrounded by adhesions. In the case in which the anastomosis was attempted but not completed, the proximal aortic clamp became dislodged, resulting in sudden stoppage

of the heart after approximately one pint of blood had been lost. Even though control of the vessel was obtained quickly, efforts at resuscitation failed. As a result of this experience, a mechanism for locking the aortic clamps was devised.

An anastomosis was completed in 21 of the 23 cases. In 17 of these the site of coarctation was excised and an end-to-end anastomosis was performed between the proximal and distal ends of the aorta. The only fatality in this group was a 13-year-old boy in whom a cerebral thrombosis of the left internal

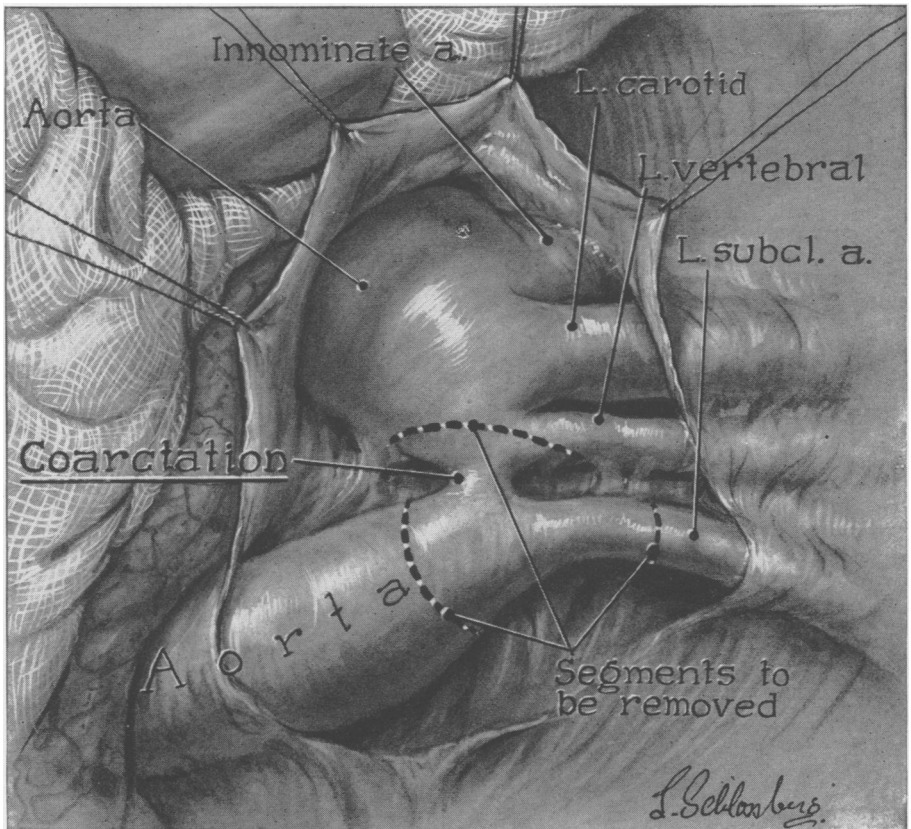


FIG. 2.—Reveals the findings in a patient in whom the subclavian artery arose distal to the point of stenosis.

carotid and left middle cerebral arteries occurred postoperatively. It was noted preoperatively that he stuttered quite badly. The operative procedure was an easy one and no difficulty was encountered. The only other complication in this group was the development of a sixth cranial nerve paralysis on the right in a recent patient. It was felt that this may have been caused by a pre-existing intracranial aneurysm.

In four patients the proximal segment of the aorta was considered to be too short for an end-to-end suture, and the left subclavian artery was used

to by-pass the point of stenosis. Most of these cases occurred in the early part of the series and it is likely that with additional experience an end-to-end anastomosis could have been performed in some of them. There was one death in this group. The patient was a child of seven who had evidence of heart failure with pulmonary hypertension preoperatively. Free pleural fluid and pulmonary edema were present at the time of operation. The anastomosis was performed without difficulty but the child died as the chest was being

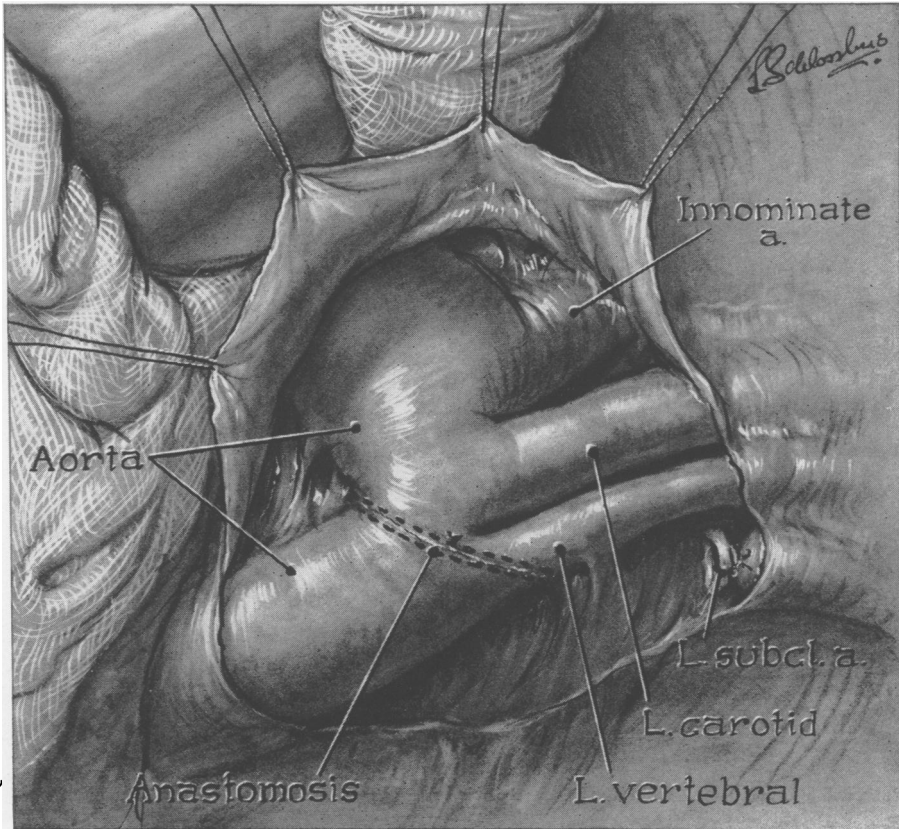


FIG. 3.—Shows the completed anastomosis. It may be seen that the subclavian artery has been divided, and that the suture line extends onto the base of the vertebral artery.

closed. Mitral stenosis, thickening of the tricuspid valve, pulmonary arterio- and arteriolar sclerosis, and pulmonary edema were found on postmortem examination. A second patient in this group developed a partial paralysis of the legs as a result of the operation. It was the opinion of the consulting neurologist that this was due to an occlusion of the anterior spinal artery which may have been aberrant.

If we consider the two groups together, it is to be observed that there were three deaths in the 22 cases. Two of these occurred in the younger age group

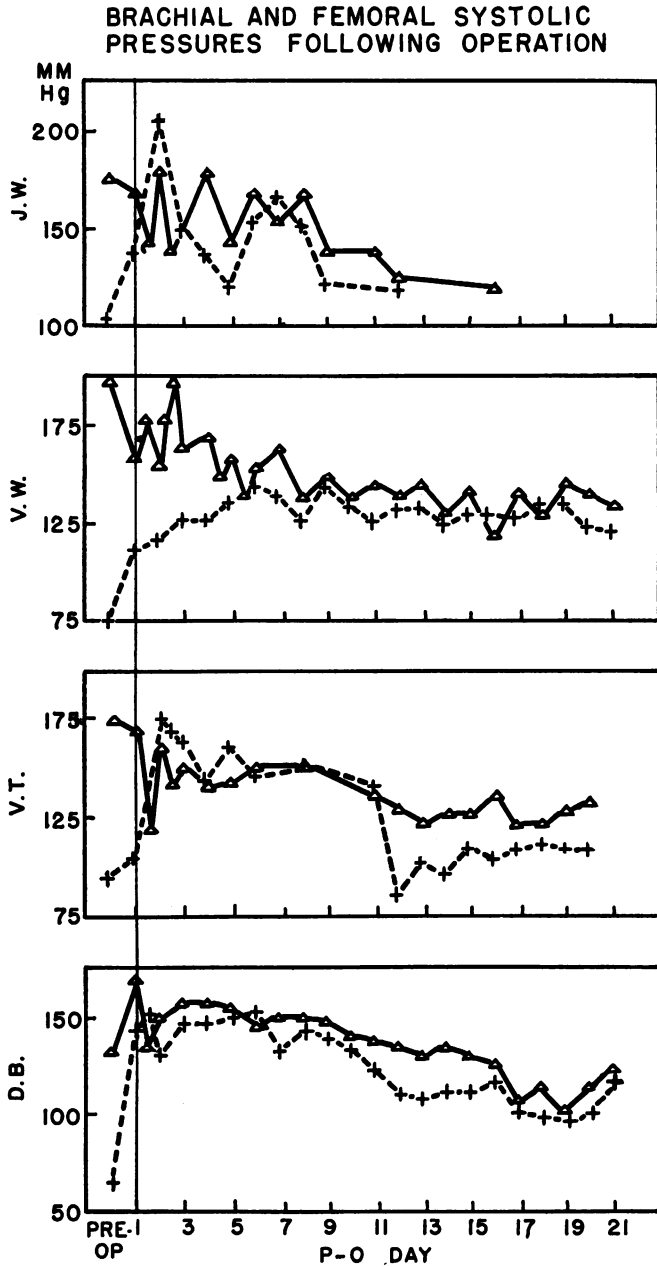


FIG. 4.—Charts the changes in blood pressure following resection of the stenosis. The solid line represents brachial systolic pressures; the broken line femoral systolic pressures.

and one in the older. The latter death was due to a technical error at the time of operation and should have been avoided. Cerebral thrombosis in one case and pulmonary edema in the presence of valvular disease and pulmonary sclerosis in the other accounted for the two deaths in the younger age group.

The findings in one of the cases were of sufficient interest to merit specific comment. Physical examination and angiocardiography in a female of 26 indicated that the coarctation was proximal to the orifice of the left subclavian artery. Arterial pulsations in the left arm were weaker than those in the right, and notching of the ribs was present on the right and not the left. On exploratory thoracotomy it was found that the left subclavian artery arose from the aorta immediately distal to the point of stenosis. Temporary occlusion of this artery did not cause a diminution in the radial pulse on the left; in fact, the anesthetist thought it caused the pulse to become stronger. The flow of blood in the left subclavian artery was the reverse of the normal direction. The orifice of the left subclavian was so close to the site of coarctation that it appeared to be necessary to sacrifice it in doing an excision of the stenotic area and an end-to-end anastomosis. A diagram of the operative procedure is shown in Figures 2 and 3. A satisfactory result has followed this operation.

During the three weeks postoperative period that our patients have remained in the hospital, two observations have been made which seems worthy of comment. In every case where headache has been a prominent preoperative symptom, it has been conspicuously absent postoperatively. It has also been noted that the systolic blood pressure in arm and leg require some five to ten days to stabilize. This is illustrated in Figure 4, and has been commented upon by Gross⁵ and Shick.⁶ Follow-up studies upon these patients are currently in progress.

Studies on the *physiopathology* of this malformation have dealt primarily with the etiology of hypertension in the upper part of the body. Therefore, most investigators have been concerned with the relationships of blood pressures, blood flows, and vascular resistance in the upper and lower extremities. Conclusions drawn from the studies have been controversial. Blumgart found normal arteriolar pressures in the arms and legs and concluded that the elevation in blood pressure was the result of the resistance offered by the aortic stricture and the collateral pathways.⁷ Similar conclusions were reached by Lewis, who found normal blood flow through the arm and leg, but observed vasodilatation in the head, neck, and hand.⁸ More recent studies, however, have emphasized the role of peripheral arteriolar resistance. Pickering postulated an increase in arteriolar resistance limited to the upper part of the body and attributable to vascular narrowing.⁹ Prinzmetal and Wilson found decreased blood flow through the arm and concluded that arterial hypertonus of vasomotor origin must be present in the upper limbs.¹⁰

The introduction of intra-arterial blood pressure measurements in man by Hamilton's method opened a new line of approach.¹¹ Using this technic, Steele

found elevations above normal of the diastolic pressure in the radial and femoral arteries. This was interpreted as evidence of a generalized increase in arteriolar tone throughout the body.¹² According to Rytand, interference with the renal blood supply caused by the stricture of the thoracic aorta was responsible for the increased resistance.¹³ This conclusion was supported by the finding of Goldblatt that hypertension occurred if the aorta was constricted

CARDIAC INDICES

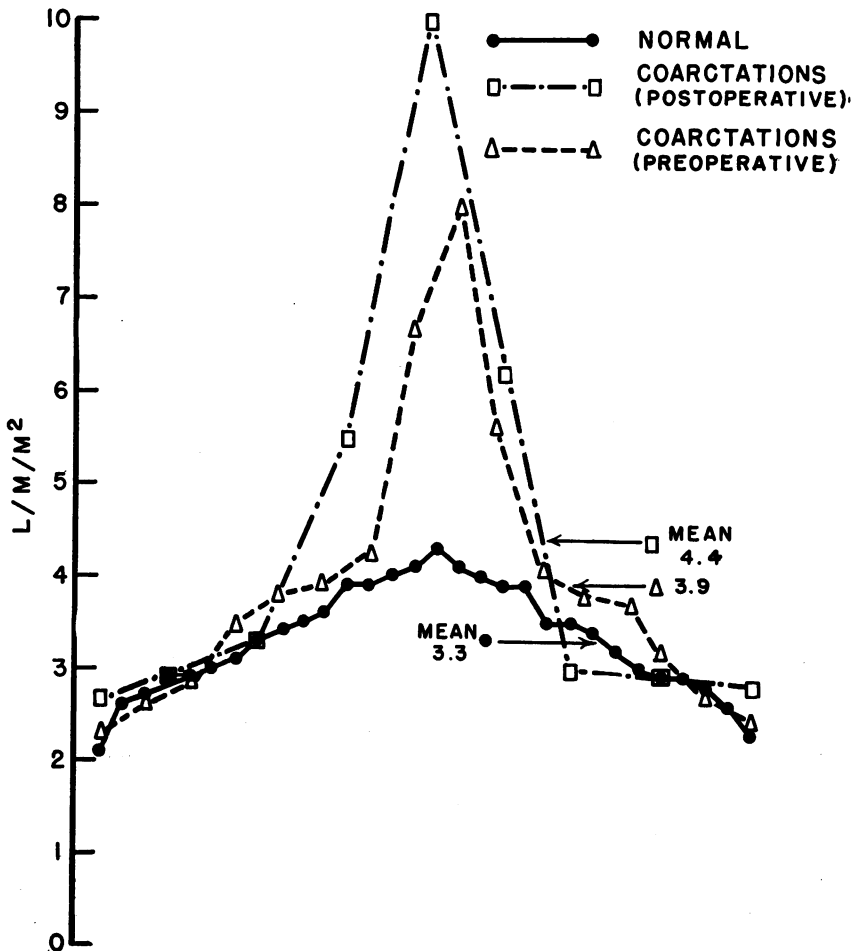


FIG. 5.—Illustrates the cardiac indices of normal individuals as well as patients with coarctation of the aorta both pre and postoperatively. It may be seen that the cardiac indices show no significant deviations from normal values.

above the level of the renal arteries and failed to appear when the aorta was constricted below.¹⁴ Increased renal vascular resistance, observed in cases of coarctation of the aorta, might be construed as further evidence of the participation of the kidney in the production of hypertension.¹⁵ On the other

hand, hypertension in the arm has been observed in several cases of coarctation where the stricture was below the level of the renal arteries. In one of these the renal blood flow was normal.¹⁶

This short review of the literature illustrates the variety of results and interpretations. The introduction of surgical therapy is of such recent date

ARM BLOOD FLOWS

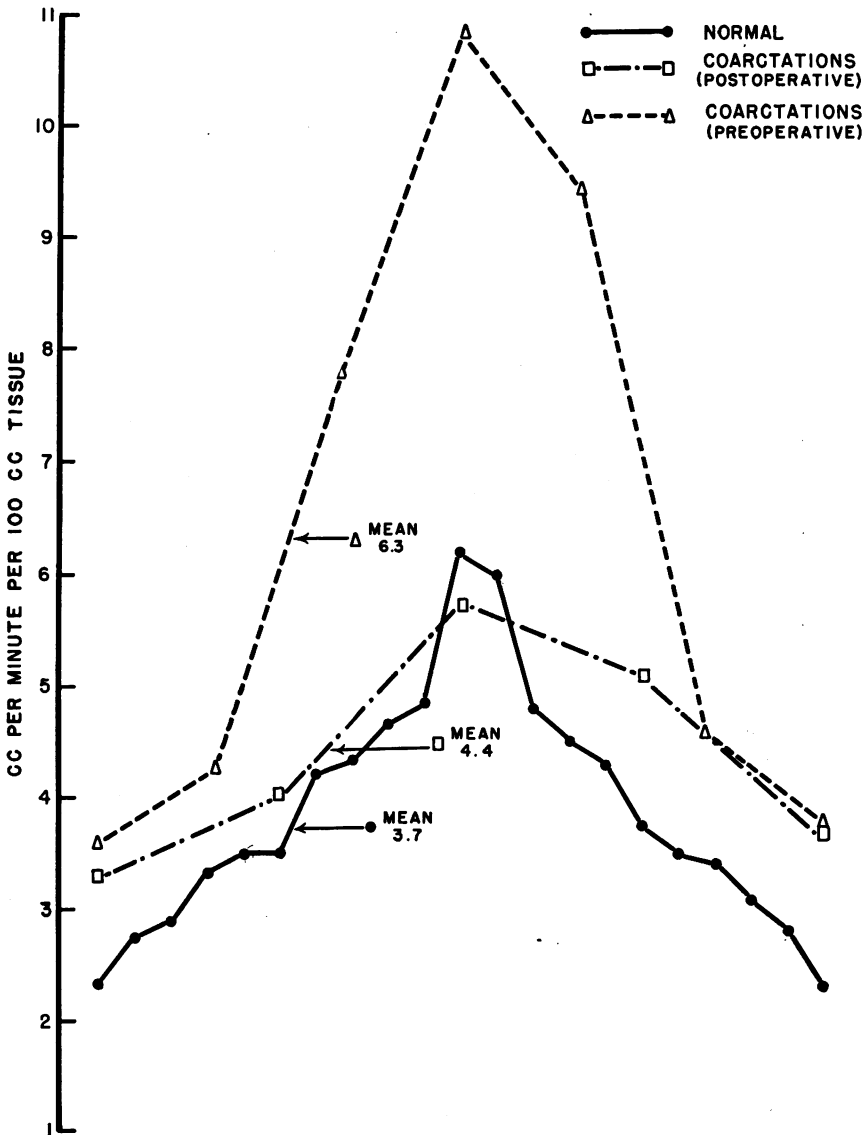


FIG. 6.—Shows that the mean preoperative blood flow through the forearm of patients with coarctation is markedly elevated. Postoperatively it falls to essentially normal levels.

that few reports dealing with postoperative changes have been published. The succeeding paragraphs of this paper deal with studies concerning the pre- and postoperative hemodynamics in coarctation. The mechanisms leading to hypertension will be discussed in the light of these findings.

A total of 22 patients were studied. Postoperative investigations were carried out three weeks following surgery. Cardiac output was determined according to the Fick principles using right heart catheterization for sampling of mixed venous blood.¹⁷ All cardiac outputs were expressed in liters per minute per square meter of body surface (cardiac index). Blood gas analyses

LEG BLOOD FLOWS

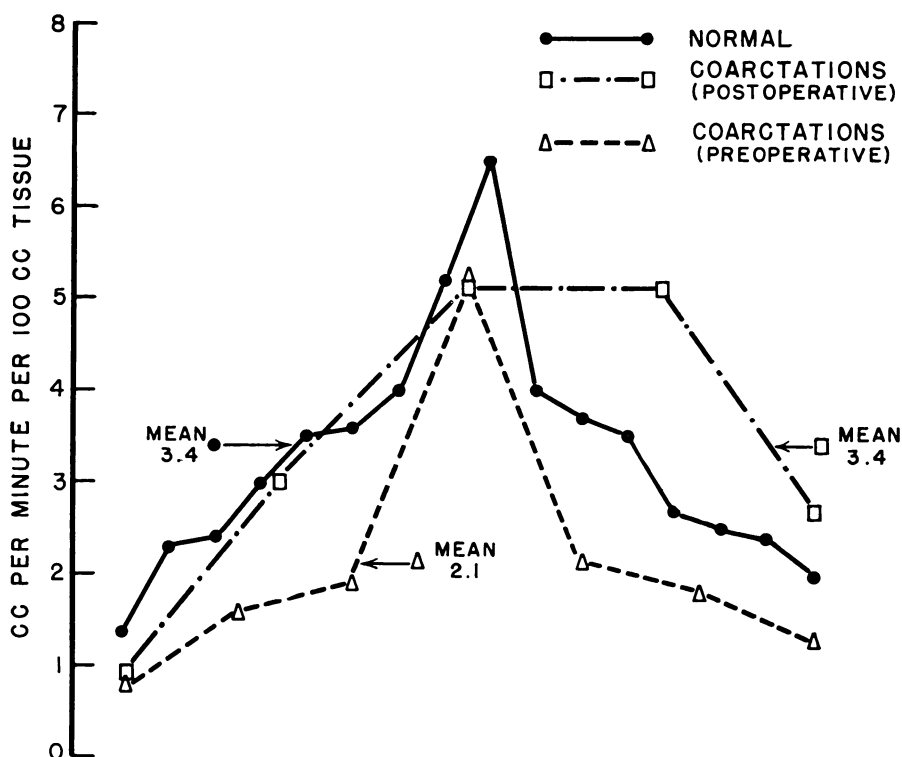


FIG. 7.—Illustrates that the mean preoperative blood flow through the calf is slightly below normal values, rising postoperatively.

were carried out in the manometric apparatus of Van Slyke and Neill.¹⁸ Analyses of respiratory gases were performed using the apparatus of Haldane¹⁹ and the Pauling oxygen analyzer. Intra-arterial blood pressures were determined using hypodermic strain gauge (Statham) or Hamilton manometer.¹¹ Mean pressures were derived by planimetric integration of the area under the pressure curve. Renal blood flow and glomerular filtration rate were determined in most of these individuals by Dr. Jacques Genest and co-workers using the

clearances of para-amino hippuric acid and sodium thiosulfate. Their studies form the subject of a separate report, but reference will be made to their results. Blood flows through the leg and forearm were measured at 32° C. with the plethysmograph described by Wilkins and Eichna.²⁰ Their results on 14 normal individuals agreed closely with those obtained on five normal individuals in this laboratory. The combined data were used in the statistical evaluation of normal blood flows through the forearm and leg. There is considerable disagreement in the literature concerning values for normal blood flow through the extremities.^{8, 12, 20} This appears to be primarily the result of differences in the apparatus used and of variations in the temperatures at which determinations were made.

COMPARATIVE PRE AND POSTOPERATIVE BLOOD PRESSURES

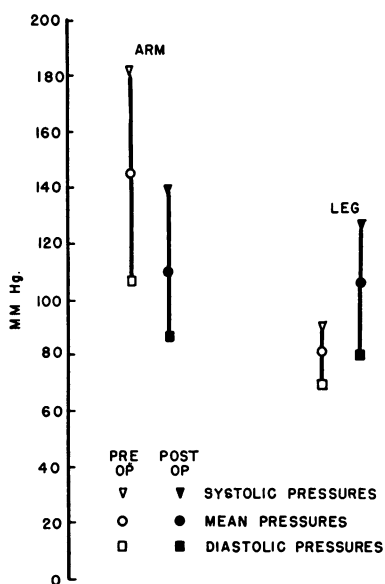


FIG. 8.—Shows the relationship of intraarterial systolic, diastolic, and mean pressure in arm and legs pre and postoperatively. It may be seen that after operation pressures tend to equalize.

significantly elevated above normal, with a mean value of 6.3 cc./min./100 cc. arm tissue, as compared with a normal of 3.7 cc. Postoperatively the blood flow through the forearm decreased toward normal. (Figs. 6 and 11.) In contrast, the preoperative blood flow through the calf, determined in the same individuals, was below the standard deviation of the normal, with a mean of 2.1 cc./min./100 cc. leg tissue as compared to 3.4 cc. in the normal. (Figs. 7 and 11.) Postoperatively the flow through the calf, measured in five cases, rose to normal levels. These findings are at variance with those obtained by

Figure 5 illustrates the preoperative cardiac indices of 16 individuals; in nine, the indices were determined postoperatively. It may be seen that there was some scatter of the figures. In three instances the pre- and postoperative values for cardiac outputs were significantly elevated above normal. However, the remainder of the data fell within the normal range established by Cournand and his associates. (Fig. 5.)²¹ It may be concluded, therefore, that the cardiac output of patients with coarctation of the aorta before and after resection of the stenosis is within normal limits.

The blood flow through the forearm was determined preoperatively in seven cases. Postoperative observations were made in five individuals. Figures 6 and 11 illustrate that the preoperative blood flows through the arm were sig-

Lewis, who found normal blood flows in both upper and lower extremities.⁸ Low flows through the arm and hand were described by Prinzmetal and Wilson.¹⁰ It is probable, however, that the results are not comparable because of the variations in the techniques.

Direct intra-arterial blood pressure determinations from the brachial and femoral arteries were performed in 17 preoperative cases. (Fig. 8.) In seven of these, pressures were recorded simultaneously. (Fig. 9.) Figure 9 shows the elevation of the systolic and mean pressures in the arm.* With two excep-

SIMULTANEOUS PRESSURE RECORDINGS
IN COARCTATION OF THE AORTA . .

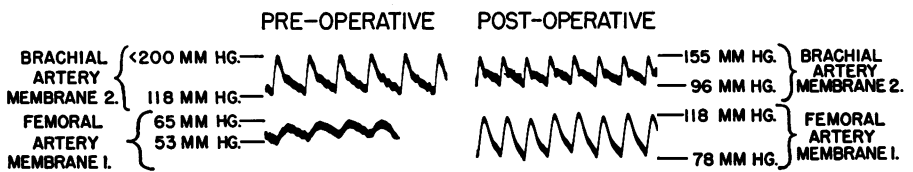


FIG. 9.—Is a simultaneous direct pressure recording from the brachial and femoral arteries before and after operation.

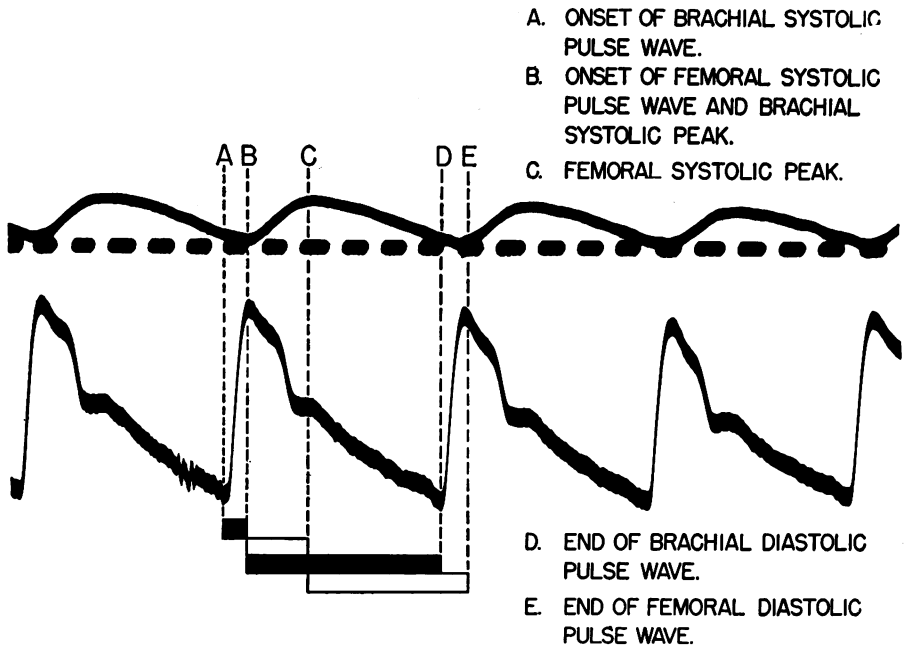


FIG. 10.—Shows the alterations in the components of the femoral pulse wave as compared with the brachial pulse wave. The delay in the onset of the femoral upstroke, and the difference in duration of brachial and femoral upstrokes is demonstrated.

* Following the criteria of the American Heart Association, the upper limit of normal systolic pressure was taken as 140, the upper limit of normal diastolic pressure was taken as 90 mm. Hg. The upper limit of normal mean pressure was considered to be 110 mm. Hg.

tions, the diastolic component was also elevated. The pulse pressure was increased. Postoperatively the systolic, diastolic and mean pressures fell in most instances. (Fig. 8, Table I.)

The systolic blood pressures taken from the femoral artery of 15 individuals were below normal in every instance. In only one patient was the diastolic pressure higher than normal. Mean pressures were not elevated. Postoperatively, the systolic and mean pressures rose, the diastolic component remaining almost constant. (Fig. 8.) These findings corroborate those of King, Steele, Gross, and others.^{22, 12, 5}

The contours of the femoral and radial pulse waves have been compared by Woodbury and by Brown and their associates.^{23, 24} These investigators found the brachial pulse contour of normal appearance. Pressure curves from the

TABLE I.—*Direct Blood Pressure Determinations in Coarctation*

Name	Preoperative				Postoperative			
	Arm		Leg		Arm		Leg	
	S/D mm. Hg	Mean	S/D mm. Hg	Mean	S/D mm. Hg	Mean	S/D mm. Hg	Mean
E. W.	205/122	150	105/89	97				
A. W.	196/107	136	98/80	91	157/77	98	154/92	122
M. O.	133/103	114	115/98	103	112/65	88	147/85	106
B. C.	200/115	162						
W. D.	171/93	135	125/52	91			148/90	110
H. S.	186/118	170	102/78	87			109/72	88
C. S.	150/38	142	88/66	77	160/140	147	89/72	78
D. P.	> 200/134	173	78/62	72	120/75	91	125/74	87
W. B.	> 200/118	174	65/53	61	155/96	128	118/78	93
C. C.	150/107	132						
B. A.	> 200/100	144	52/45	48				
V. W.	200/97	170	68/52	63	124/84	104	109/73	88
J. W.	178/91	144	100/77	92	144/71	96	112/66	88
R. K.	200/92	162	96/73	88	178/98	140	178/102	140
V. T.	175/88	127	97/74	84	134/70	108	142/73	125
A. P.	> 200/100	160	91/61	78				
D. B.	134/62	98	66/52	62	122/71	92	108/58	79
Arith.								
Mean	> 183/106	144	91/68	81	141/85	109	128/78	100

femoral artery, however, showed a retardation of the upstroke of the pulse wave and a broad rounded peak, making the pulse contour almost a smooth curve. Figure 10 illustrates the contrast between the configuration of the brachial and femoral pulse waves in a patient of this series. The shape of the femoral pulse wave is the result of damping of each wave as it passes through the area of resistance presented by the aortic stricture and the collateral channels. It has been pointed out that the effect of the insertion of a small to moderate resistance into the pathway of a transmitted wave is to dampen the amplitude of the curve, leaving the mean pressure relatively unaffected.²⁵ It is by this mechanism that femoral pulse pressure is reduced while mean pressure remains at or near normal levels.

Prolongation of the normal interval between the onset of the upstroke of the femoral and the brachial pulse waves has also been reported.²³ Similar observations were made in the patients of this series. It may also be seen in Figure 10 that the duration of the femoral arterial upstroke was more than

twice that of the brachial. Since the sum of the entire length of the pulse wave is the same for both brachial and femoral arteries, the downstroke component must be shortened in the femoral.

Analysis of the physiologic data. An analysis of the mechanisms of hypertension from the data presented must deal primarily with the relationship of vascular resistance, blood flow, and blood pressure. Since the cardiac output of patients of this series is normal, the hypertension must be due to an increase in vascular resistance. This could be the result of one of two mechanisms. The first mechanism was suggested by Blumgart, who believed that the site of resistance was in the aortic stricture and collateral vessels.⁷ The second mechanism, proposed by Steele,¹² by Stewart,²⁶ and by Rytand,¹³ postulated that the increase in resistance was generalized, affecting the whole peripheral vascular tree. Such a disturbance exists in renal and in essential hypertension. Rytand is of the opinion that in coarctation the kidney is responsible for the increased resistance because of interference with its blood supply.¹³ If this were the case, the overall arterial resistance exclusive of the stenosis and the collaterals should be elevated. However, calculation of an increase in overall peripheral resistance is not in itself sufficient evidence of a renal pressor mechanism, for in renal hypertension the resistance must also be equally distributed. By contrast, the increase in overall resistance which may be present in neurogenic hypertension produced by sectioning of the buffer nerves in dogs is of unequal distribution.²⁷ Therefore, if the hypertension in coarctation is renal, the increase in arterial resistance must affect all branches of the circulatory tree to an equal degree.

The resistance due to peripheral arterial tone alone may be estimated by subtracting from the total overall resistance a calculated value for the resistance of the stenosis and the collaterals. Let rc represent the resistance through the collaterals and the coarctation; R_T , the total overall resistance; and RP , the resistance due to peripheral arterioles alone; then

$$(1) \quad RP = R_T - rc.$$

With a simplified version of Poiseuille's formula $\left(\text{Resistance} = \frac{\text{Pressure}}{\text{Flow}} \right)$

the various resistances may be estimated.*

$$(2) \quad rc = \frac{PL}{F}$$

where rc represents the resistance through the collaterals and the coarctation; PL , the loss in pressure head across the coarctation and the collaterals; and F , the blood flow through the coarctation and the collaterals. Since it is not possible to ascertain the blood flow through this region, let F equal cardiac output. The rc thus derived then should be the lowest possible resistance for this portion of the vascular bed. Thus, R_T , the total overall resistance, would

* All resistances calculated by these formulae are expressed in arbitrary units.

represent the highest possible value, and RP would likewise be maximal.

$$(3) R_T = \frac{PA}{F}$$

where R_T represents the total overall resistance, including that of the coarctation and the collaterals, PA the mean pressure in the brachial artery, and F equals the cardiac output.

Table II illustrates that preoperative and postoperative values for the peripheral resistance exclusive of the stenosis and the collaterals are below normal. Since these values are maximal, true peripheral resistances must be

TABLE II.—*Peripheral Resistance in Coarctation of the Aorta*

Case	Preoperative			Postoperative		
	R_T^*	rc*	RP*	R_T^*	rc*	RP*
B. A.	39	26	13			
V. W.	41.5	26	15.5	38.5	6	32.5
J. W.	49.5	18	31.5	17.5	1.5	16
R. K.	38.5	17.5	21	14	0	14
V. T.	33.5	11	22.5	36	0	36
A. P.	24	12	12			
D. B.	26	9.5	16.5	33	4.5	28.5
MEAN			19			25
NORMAL*			29			29

* R_T = total resistance including stenosis and collaterals = brachial pressure/cardiac index.

rc represents the resistance of the stenosis and collaterals = drop in pressure/cardiac index.

R_p represents the peripheral resistance = $R_T - rc$.

Normal peripheral resistance calculated using a mean pressure of 96 mm. Hg and a cardiac index of 3.3.

lower. This finding differentiates the mechanism of hypertension in coarctation from that in renal and essential hypertension.

Further evidence for the absence of a renal mechanism in the pathogenesis of hypertension in coarctation is lack of proportional increase in resistance in various portions of the vascular tree. In an attempt to assess the resistance in various parts of the body, Steele¹² and Stewart²⁶ postulated an increase in the arteriolar resistance of the leg on the basis of an elevation of the diastolic pressure in the femoral artery. A similar increase in resistance was demonstrated in patients of this series despite the finding that only one out of 15 preoperative cases showed an increase in femoral diastolic pressure. This calculated increase in resistance accounts for the decrease in blood flow through the leg in the presence of a normal mean pressure. It is apparent from preceding discussions that conclusions regarding peripheral vascular resistance drawn from the height of the diastolic pressure alone are unjustified.

It is of interest that following the operation the blood flow through the leg approaches normal. (Figs. 7 and 11.) During the postoperative period of observation, however, there is a proportional rise in the mean pressure in the femoral artery, indicating that the postoperative resistance in the leg remains elevated. (Fig. 11.)

Blood pressures from the brachial artery obtained in the patients of this series agree with those of King, Steele, and others.^{22, 12} Figure 9 illustrates that brachial systolic, diastolic and mean pressures are elevated. The blood flow through the arm is markedly increased (Figs. 6 and 11), and consequently the mean resistance is normal or only slightly elevated. (Fig. 11.) On the other hand, in patients with essential and renal hypertension the arm flow is normal but the vascular resistance in the extremity is markedly elevated. Postoperatively the blood flow through the arm and the brachial arterial pressure decrease in the same proportion. Therefore, no appreciable change in the vascular resistance occurs.

There is general agreement that the vascular resistance in the kidney is increased in patients with coarctation.²⁸ As in essential and renal hyperten-

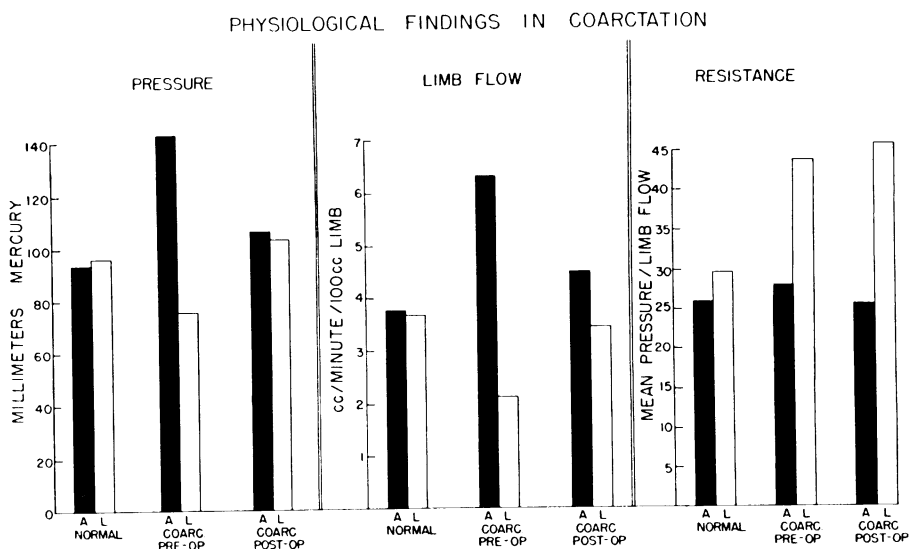


FIG. 11.—Compares mean pressures, blood flows through the limbs, and vascular resistance through the limbs before and after operation.

sion, the increased vascular tone is in the efferent arterioles. On the other hand, cases with severe hypertension in the upper extremity have been reported in which the coarctation was below the level of the renal arteries. In one of these, studied and explored at this hospital, the renal blood flow and the glomerular filtration rate were normal, but the vascular resistance in the leg was increased.¹⁶

Several findings in this report cast doubt on the theory that the hypertension in coarctation is the result of an increase in the peripheral resistance mediated through renal mechanisms. Estimated values for the overall arterial resistance exclusive of the coarctation and the collaterals are below normal. Furthermore, the existing peripheral resistance is unequally distributed. Since the resistance in the extremities is not lowered, other parts of the vascular bed must accommodate an increased blood flow. Investigations are in progress to determine the site of lowered vascular resistance. Finally, the increase in

the height of the diastolic pressure observed in both the upper and lower extremities, which has been used as evidence for increased arteriolar tone, can be readily explained as a result of damping of the pulse wave by the coarctation and the arterial collaterals.

SUMMARY

Twenty-three patients with coarctation of the thoracic aorta have been operated upon.* Thirteen of the patients were 20 years of age or above, while ten were younger. An anastomosis was completed in 21 cases of the 22 in which it was attempted. In 17 cases the stenosis was resected and an anastomosis of the proximal and distal ends of the aorta was performed. In four cases in which the proximal segment of the aorta was too short for end-to-end suture, the left subclavian artery was used to by-pass the stenosis. There were three deaths in the series, including one in a child who had multiple congenital defects which had been recognized preoperatively.

Physiologic investigations disclosed no significant deviation of the cardiac output from normal. Blood flows through the arm, which were elevated before operation, fell following surgery. The blood flow through the leg rose postoperatively. Hypertension in the upper part of the body and hypotension the legs was observed preoperatively. After operation, these pressures tended to equalize. Analysis of the physiologic data indicated no generalized elevation of peripheral vascular resistance. It is probable, therefore, that the hypertension in coarctation of the aorta is not attributable to a renal pressor mechanism, but is due to the resistance of the stenosis and collaterals.

BIBLIOGRAPHY

- ¹ Blalock, A., and E. A. Park: Surgical Treatment of Experimental Coarctation (Atresia) of the Aorta. *Ann. Surg.*, **119**: 445, 1944.
- ² Crafoord, C., and G. Nylin: Congenital Coarctation of the Aorta and its Surgical Treatment. *J. Thoracic Surg.*, **14**: 347, 1945.
- ³ Gross, R. E., and C. A. Hufnagel: Coarctation of the Aorta. Experimental Studies Regarding its Surgical Correction. *New England J. Med.*, **233**: 287, 1945.
- ⁴ Clagett, O. T.: Coarctation of the Aorta: Surgical Aspects. *Proc. Staff Meet., Mayo Clinic*, **22**: 131, 1947.
- ⁵ Gross, R. E.: Surgical Treatment for Abnormalities of the Heart and Great Vessels. The Beaumont Lecture. Baltimore, Charles C. Thomas, 1947.
- ⁶ Shick, R. M.: Surgical Treatment of Coarctation of the Aorta: Report of a Case. *Proc. Staff Meet., Mayo Clinic*, **22**: 127, 1947.
- ⁷ Blumgart, H. L., J. S. Lawrence and A. C. Ernestene: The Dynamics of the Circulation in Coarctation (stenosis of the isthmus) of the Aorta of the Adult Type. *Arch. Int. Med.*, **47**: 806, 1931.
- ⁸ Lewis, T.: Material Relating to Coarctation of the Aorta of the Adult Type. *Heart*, **16**: 205, 1933.
- ⁹ Pickering, G. W.: The Peripheral Resistance in Persistent Arterial Hypertension. *Clin. Sci.*, **2**: 209, 1935-1936.
- ¹⁰ Prinzmetal, M., and C. Wilson: The Nature of the Peripheral Resistance in Arterial Hypertension with Special Reference to the Vasomotor System. *J. Clin. Investigation*, **15**: 63, 1936.

* Seven additional patients with coarctation of the aorta have now been operated upon. End-to-end anastomosis was carried out in all these patients and there were no additional deaths. Of these seven patients, one was 41 years of age.

- ¹¹ Hamilton, W. F., G. Brewer, and I. Brotman: Pressure Pulse Contours in the Intact Animal. Analytical Description of a New High-Frequency Hypodermic Manometer with Illustrative Curves of Simultaneous Arterial and Intracardiac Pressures. *Am. J. Physiol.*, **107**: 427, 1934.
- ¹² Steele, J. N.: Evidence for General Distribution of Peripheral Resistance in Coarctation of the Aorta. Report of Three Cases. *J. Clin. Investigation*, **20**: 473, 1941.
- ¹³ Rytand, D. A.: The Renal Factor in Arterial Hypertension with Coarctation of the Aorta. *J. Clin. Investigation*, **17**: 391, 1938.
- ¹⁴ Goldblatt, H., J. R. Kahn, and R. F. Hanzal: Studies on Experimental Hypertension. IX. The Effect on Blood Pressure of Constriction of the Abdominal Aorta Above and Below the Site of Origin of Both Main Renal Arteries. *J. Exper. Med.*, **69**: 649, 1939.
- ¹⁵ Friedman, M., A. Selzer, and H. Rosenblum: The Renal Blood Flow in Coarctation of the Aorta. *J. Clin. Investigation*, **20**: 107, 1941.
- ¹⁶ Bahnon, H. T., R. Cooley, and R. Sloan: To be published.
- ¹⁷ Cournand, A.: Measurement of Cardiac Output in Man Using Right Heart Catheterization; Description of Technique, Discussion of Validity and of Place in Study of Circulation. *Federation Proc.*, **4**: 207, 1945.
- ¹⁸ Van Slyke, D. D., and J. M. Neill: The Determination of Gases in Blood and Other Solutions by Vacuum Extraction and by Manometric Measurement. *J. Biol. Chem.*, **61**: 523, 1924.
- ¹⁹ Haldane, J. S.: *Methods of Air Analysis*. London, Charles Griffin and Co., Ltd., 1912.
- ²⁰ Wilkins, R. A., and L. W. Eichna: Blood Flow to the Forearm and Calf. I. Vasomotor Reactions: Role of the Sympathetic Nervous System. *Bull. Johns Hopkins Hosp.*, **68**: 425, 1941.
- ²¹ Cournand, A., R. L. Riley, E. S. Breed, E. de F. Baldwin, and D. W. Richards, Jr.: Measurement of Cardiac Output in Man Using the Technique of Catheterization of the Right Auricle or Ventricle. *J. Clin. Investigation*, **24**: 106, 1945.
- ²² King, J. T.: The Blood Pressure in Stenosis of the Isthmus (coarctation) of the Aorta. Case Reports. *Ann. Int. Med.*, **10**: 1802, 1937.
- ²³ Woodbury, R. A., E. E. Murphey, and W. F. Hamilton: Blood Pressures in Aortic Coarctation. *Arch. Int. Med.*, **65**: 752, 1940.
- ²⁴ Brown, G. E., Jr., A. A. Pollack, O. T. Clagett, and E. H. Wood: Intra-arterial Blood Pressure in Patients with Coarctation of the Aorta. *Proc. Staff Meet., Mayo Clinic*, **23**: 129, 1948.
- ²⁵ Gomez, D. M.: *Hemodynamique et angiocinetique. Etude Rationelle des lois regissant les phenomenes cardio-vasculaires*. Paris, Hermann and Co., 1941.
- ²⁶ Stewart, H. J., and R. L. Bailey, Jr.: The Cardiac Output and Other Measurements of the Circulation in Coarctation of the Aorta. *J. Clin. Investigation*, **20**: 145, 1941.
- ²⁷ Bing, R. J., C. B. Thomas, and E. C. Waples: The Circulation in Experimental Neurogenic Hypertension. *J. Clin. Investigation*, **24**: 513, 1945.
- ²⁸ Genest, J., E. V. Newman, A. A. Kattus, B. Sinclair-Smith, and A. Genecin: Renal Function Before and After Surgical Resection of Coarctation of the Aorta. *Bull. Johns Hopkins Hosp.*, to be published.

DISCUSSION.—DR. CLARENCE CRAWFORD, Stockholm, Sweden: First of all I should like to express my gratitude for the opportunity of being present at this meeting and taking part in this discussion, which I feel is a great honor. From the excellent results we have just heard from Dr. Blalock and his co-workers, and from my own experience, I think we may state that radical treatment of coarctation of the aorta can no longer be considered as a surgical equilibristic procedure; I think it can be said that it is a sound surgical procedure. The results I have had support the conclusions which can be drawn from Dr. Blalock's presentation.

• We have now operated on 32 cases of coarctation; 31 of those were resected and