
Cellular and Molecular Effects of Developmental Exposure to Diethylstilbestrol: Implications for Other Environmental Estrogens

Retha Newbold

Environmental Toxicology Program, National Institute of Environmental Health Sciences,
Research Triangle Park, North Carolina

Concerns have been raised regarding the role of environmental and dietary estrogens as possible contributors to an increased incidence of various abnormalities in estrogen-target tissues of both sexes. These abnormalities include breast cancer, endometriosis, fibroids, and uterine adenocarcinoma in females, as well as alterations in sex differentiation, decreased sperm concentrations, benign prostatic hyperplasia, prostatic cancer, testicular cancer, and reproductive problems in males. Whether these concerns are valid remains to be determined; however, studies with the potent synthetic estrogen diethylstilbestrol (DES) suggest that exogenous estrogen exposure during critical stages of development can result in permanent cellular and molecular alterations in the exposed organism. These alterations manifest themselves in the female and male as structural, functional, or long-term pathological changes including neoplasia. Although DES has potent estrogenic activity, it may be used as a model compound to study the effects of weaker environmental estrogens, many of which may fit into the category of endocrine disruptors. — Environ Health Perspect 103(Suppl 7):83–87 (1995)

Key words: diethylstilbestrol, DES, estrogenic, estrogen, estrogen receptor, embryogenesis, perinatal exposure, reproductive tract development, genital tract, sex hormones, sex differentiation

Introduction

Diethylstilbestrol (DES), a potent synthetic estrogen, was prescribed to a large population of pregnant women to prevent miscarriage and other pregnancy complications. Subsequently, it was shown that the cohort of women exposed to DES *in utero* exhibited a wide range of reproductive tract abnormalities including a low, but significantly increased, incidence of vaginal adenocarcinoma (1). Likewise, it was reported that men exposed to DES *in utero* experienced a variety of reproductive tract problems including reduced fertility and retained testes. Similarly, experimental animals exposed prenatally or neonatally to DES developed comparable genital tract alterations. (A comparison of the effects of developmental exposure to DES in humans and

mice is shown in Tables 1 and 2.) Thus, the rodent provides an excellent model to study the mechanisms of developmental toxicity of estrogens. Future human risk assessment of the deleterious effects resulting from developmental exposure to estrogenic substances like DES will require in-depth knowledge of mechanisms that can be gained by studying the rodent model.

Murine Model of Developmental Exposure to Diethylstilbestrol

Several murine models have been described to study developmental exposure to estrogenic compounds including prenatal and neonatal exposure or a combination of both treatments. Since the neonatal model is so eloquently described by Iguchi et al. (2),

the following description will include only prenatal treatment. However, data obtained from both models are important in determining cellular and molecular mechanisms.

To study the effects of prenatal exposure to DES, outbred CD-1 mice were treated sc with DES on days 9 through 16 of gestation, the period of major reproductive tract organogenesis. The doses of DES ranged from 0.01 to 100 µg/kg during pregnancy, equal or less than doses given therapeutically to pregnant women. In fact, the lower DES doses are comparable to weaker estrogenic compounds found in the environment. Mice were born on day 19 of gestation, and both male and female offspring were followed.

To assess the effects of prenatal DES exposure on postnatal reproductive tract function, the fertility of DES female mice was determined using a continuous breeding protocol (3). The most striking effect observed was a dose-related decrease in reproductive capacity, ranging from minimal subfertility at the lower DES doses to a high frequency of total sterility at the highest DES doses (Figure 1). Over the course of the breeding schedule, even the low doses of DES exhibited subfertility. Reduced reproductive capacity appeared to be a reflection of a decrease both in the total number of litters and in litter sizes. A major component of the sterility seen in females that were given higher doses of

This paper was presented at the Symposium on Estrogens in the Environment, III: Global Health Implications held 9–11 January 1994 in Washington, DC. Manuscript received: March 15, 1995; manuscript accepted: April 4, 1995.

I gratefully acknowledge the valuable input, advice, and collaborative efforts of John McLachlan over the last two decades. I am also indebted to Bill Bullock, Bowman Gray School of Medicine, Winston Salem, NC, for the consultations in pathology of the DES-treated mice and his continued interest in the DES project. I also recognize the valuable discussions of estrogen receptor mechanisms with Kenneth Korach at NIEHS and the collaborative work on the immunocytochemical studies of the estrogen receptor with Shuyi Yamashita, Keio University Medical School, Tokyo, Japan. In addition, I thank Wendy Jefferson and Rita Hanson for their expert technical assistance and W. Jefferson, in particular, for her help on all aspects of this manuscript. Finally, I thank Vickie Englebright for coordinating the Estrogens in the Environment III meeting and for her advice and patience during the preparation of this manuscript.

Address correspondence to Retha Newbold, National Institute of Environmental Health Sciences (E4-02), P.O. Box 12233, Research Triangle Park, NC 27709. Telephone: (919) 541-3367. Fax: (919) 541-0696.

Abbreviations used: DES, diethylstilbestrol; ER, estrogen receptors; LF, lactoferrin; EGF, epidermal growth factor.

Table 1. Comparative developmental effects of prenatal exposure to DES in the female offspring of humans and mice.

Developmental effect	Observed in	
	Mouse	Human
Immune dysfunction	+	+
Mammary tumors	?	?
Ectopic pregnancy	?	+
Subfertility and infertility	+	+
Uterine tumors	+	?
Anatomical masculinization	+	+
Ovarian cysts	+	?
Ovarian tumors	+	?
Elevated serum testosterone levels	?	+
Elevated testosterone secreted by the ovary	+	?
Salpingitis isthmica nodosa of oviduct	+	+
Structural abnormalities of the uterus	+	+
Malformed cervical canal	+	+
Cervical and vaginal hood and polyps	+	+
Vaginal adenocarcinoma	+	+
Vaginal adenosis	+	+
Persistent vaginal cornification	+	?

DES was in the oviduct and ovary; the number of ova recovered from the ampulla of the oviduct after induced ovulation was less than 30% that of controls. Also observed were structural abnormalities of the oviduct, uterus, cervix, and vagina, which contributed to subfertility. These data suggest that *in utero* exposure to DES, even at low doses, results in the permanent impairment of female mouse reproductive capacity. Numerous reports of altered pregnancy outcomes in young women exposed *in utero* to DES (1), as well as accidental DES exposure to wildlife resulting in infertility, demonstrate the importance of these findings in mice and suggest that environmental estrogens play a role in decreased female fertility.

To assess the long-term effects of prenatal DES exposure on the female, mice were sacrificed at 12 to 18 months of age and reproductive tract tissues were studied for histological alterations (4). Histological examination revealed lesions throughout the reproductive tracts. The vagina was characterized by excessive keratinization and female hypospadias (urethra opens into vagina rather than the vulva), and at the highest dose (100 µg/kg), 5 of 20 mice had epidermoid tumors of the vagina. Vaginal adenocarcinoma was seen in the 2.5, 5, and 10 µg/kg DES dose groups, although its frequency was rare. The cervix of the DES-exposed offspring was often enlarged, but the cervical lumen was not

Table 2. Comparative developmental effects of prenatal exposure to DES in male offspring of humans and mice.

Developmental effect	Observed in	
	Mouse	Human
Subfertility	+	+
Sperm abnormalities	+	+
Decreased sperm counts	+	+
Epididymal cysts	+	+
Hypoplastic and cryptorchid testes	+	+
Testicular tumors	+	+
Interstitial cell tumors	+	?
Seminoma	+	+
Rete tumors	+	+
Anatomical feminization	+	+
Microphallus	+	+
Hypospadias	+	+
Retention of Müllerian duct remnants	+	?
Tumors in retained Müllerian duct remnants	+	?
Seminal vesicle tumors	+	?
Prostatic inflammation	+	+
Prostatic tumors	+	?
Immune dysfunction	+	?
Skeletal changes	+	?

different from controls. Stromal stimulation was responsible for the enlargement in the cervical region, and a low prevalence of benign (leiomyoma) and malignant (stromal cell sarcoma, leiomyosarcoma) tumors was seen. Evidence of epithelial and stromal stimulation in the uterine horns was also observed, and cystic endometrial hyperplasia was common even in the lower DES-dose animals; a low incidence of benign (leiomyomas) and malignant (adenocarcinoma, stromal cell sarcoma) uterine tumors was also observed. The ovaries of prenatally DES-treated females were often more cystic than controls; at the highest dose (100 µg/kg), ovarian tumors were noted and the oviducts were inflamed and

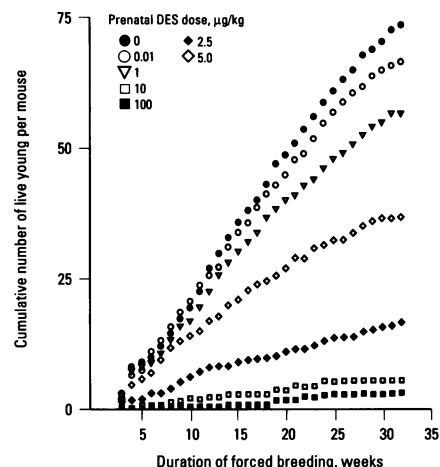


Figure 1. Total reproductive capacity of mice exposed prenatally to DES. Mice were CD-1 female offspring exposed prenatally to DES on days 9 to 16 of gestation. Postnatal fertility was determined by a repetitive forced breeding technique and expressed as the total number of live young born per mouse over an 8-month (32-week) interval. The cumulative number of young per mouse is plotted on the y-axis, while the duration of breeding is plotted on the x-axis. Note that there is a dose-related decrease in fertility at all DES doses and that even the mice exposed to low doses of DES exhibit decreased fertility as compared to corresponding control mice. This figure is reproduced with permission from McLachlan et al. (3).

congenitally malformed. A summary of the genital tract lesions seen in aged female mice is shown in Table 3. These data suggest that *in utero* exposure to DES results in long-term consequences including an increased risk of reproductive tract lesions. These findings in mice may be relevant for similarly exposed humans. For example, the vaginal adenocarcinoma seen in mice was similar in location and morphology to that reported clinically in humans (1).

Table 3. Histologically diagnosed genital tract lesions in aged female mice exposed prenatally to DES.

DES dose, µg/kg/day	Abnormalities		
	Vaginal	Cervical	Uterine
0	—	—	—
0.1	—	Leiomyoma	—
1	—	Papilloma	—
2.5	Adenocarcinoma	—	Leiomyoma
5	Adenocarcinoma	Stromal cell sarcoma	Stromal cell sarcoma
10	Abnormal urethral glands Adenocarcinoma	Epithelial atypia	Leiomyoma
100	Abnormal urethral glands Epidermoid tumors Adenocarcinoma	Leiomyosarcoma	Adenocarcinoma

DES, diethylstilbestrol. Females were aged offspring (12–24 months) of CD-1 mice treated sc with DES on days 9 to 16 of gestation. The prevalence of extragenital lesions was not significantly different between treatment groups. Note that lower DES doses exhibited tumor formation. Higher doses resulted in different types of tumors and an increased number of tumors. Data from McLachlan et al. (4) and Newbold and McLachlan (5).

Also, the developmentally arrested murine oviduct may be important in understanding structural abnormalities in the upper genital tract, including the T-shaped uterus observed by hysterosalpingography in humans (6) since both are examples of altered development of the Müllerian duct. The uterine malformation has been associated with reported menstrual irregularity and decreased favorable pregnancy outcome in women exposed prenatally to DES (6–8). These findings compare similarly to that already described for this mouse model (3).

Effects of prenatal DES exposure on the developing male genital tract were also examined (9). Fertility was assessed by breeding DES males to control female mice of the same strain. In the prenatal DES-exposed mouse, only the highest dose (100 µg/kg) was associated with noticeable changes in reproduction; 6 of 10 DES-male offspring treated with 100 µg/kg were sterile, while the nonsterile males had the same breeding performance as controls (Table 4). Several factors appeared to be related to this decreased fertility in the high-dose males including *a*) retained testes and Müllerian remnants; *b*) abnormal sperm morphology and motility; *c*) lesions in the reproductive tract; *d*) abnormal reproductive tract secretions and; *e*) inflammation (9). Thus, there were many examples of abnormalities in the male offspring that contributed to subfertility and infertility in the higher dose animals; lower dose males are currently being evaluated for any long-term changes in reproductive performance.

In the high-dose male DES offspring, a long-term, rare histological alteration was found that was apparently derived from a change in the mesonephric epithelium. During embryonic development, the mesonephric duct system gives rise to the rete testis and other male structures. The identification of tumors in the area of the

rete testis is exceptionally rare; in fact, rete testis tumors have been reported infrequently in the clinical literature and in experimental animals. It is interesting that treatment of pregnant CD-1 mice with DES (100 µg/kg) resulted in rete testis adenocarcinoma in 5% of their male offspring (Table 5). The high incidence of retained testis in mice (92%) following prenatal DES exposure and the occurrence of the rare rete testis adenocarcinoma raise the possibility of an association between prenatal DES exposure and the incidence of cryptorchidism and rete testis cancer. Although cryptorchidism resulted in decreased or lack of spermatogenesis in male mice, inactivity alone could not account for the higher prevalence of rete cancer because several of the mice with the tumor had spermatogenesis occurring in the same testis. In addition to rete cancer, increased incidence of lesions of the corpus testis and Müllerian duct remnants were also seen (11). Since these lesions were observed in high-dose DES males, males receiving lower DES doses are being followed for increased cancer risk, although their fertility was not significantly affected.

Vaginal adenocarcinoma in the female and rete testis adenocarcinoma in the male, both extremely rare findings in experimental animals and humans, represented only two examples of growth-control derangements seen as long-term defects in mice following prenatal DES exposure. Studying alterations in both sexes provides a better understanding of the developmental events and the mechanisms involved in decreased fertility and increased tumor prevalence following exposure to estrogenic compounds during critical stages of development.

Potential Mechanisms for Involvement of Estrogens in Dysregulation of Perinatal Development

Identifying molecular and cellular targets of estrogen in the developing reproductive tract may help to elucidate the mechanisms by which inappropriate exposure to estrogenic chemicals permanently alters reproductive tract growth and differentiation. One hypothesis is that developmental exposure to estrogen may cause the premature or permanent induction of genes normally under steroid control in older mature animals. The abnormal expression of these genes may contribute to the observed subfertility and increased tumor occurrence in both sexes. A recent report using the

Table 5. Testicular lesions in male mice exposed prenatally to diethylstilbestrol.^a

Lesion	Control	DES-100
Rete testis hyperplasia	23/96 (24) ^b	130/233 (56)*
Rete testis adenocarcinoma	0/96 (0)	11/233 (5)**

^aLesions in the testes of male mice exposed prenatally to DES (males were 10- to 18-month-old offspring of CD-1 mice treated with DES [100 µg/kg] on days 9 to 16 of gestation). ^bNumbers in parentheses are percent. Statistical significance of DES-exposed animals to corresponding age-matched controls by Fisher's exact test. **p*<0.0001; ***p*<0.05. Data from Newbold et al. (10).

murine DES model describes the persistent expression of two estrogen-dependent genes, lactoferrin (LF) and epidermal growth factor (EGF), in the DES mouse uterus and vagina (12). Earlier studies from our laboratory described the abnormal expression of LF in the seminal vesicle of DES-treated male offspring (13). LF regulation by estrogen has been described in detail by Teng (14). The deregulated synthesis of these two estrogen-inducible genes may be instrumental in the further development of growth and differentiation defects and in the etiology of preneoplastic and neoplastic lesions that are seen as long-term consequences following developmental estrogen exposure.

Another mechanism that may be involved in DES-associated defects is the estrogen receptor pathway. Reports of humans exposed to DES suggest that the developing fetus is extremely sensitive to exogenous estrogens; adults, however, are not as sensitive because treated mothers did not develop any of the lesions observed in their offspring. Studies with the mouse model support the idea of a critical exposure period: short-term DES exposure to a neonate results in 90% incidence of uterine adenocarcinoma later in life (15), but similar short-term treatment of the adult mouse does not induce adenocarcinoma (Newbold et al., unpublished data). The incidence of uterine adenocarcinoma only reaches 1.7% (16) in adult mice even during lifetime exposure to DES in their diet. Certainly the adult uterus is responsive to and stimulated by estrogen treatment since 95% of the mice demonstrate cystic endometrial hyperplasia. Spontaneous uterine adenocarcinoma in rats is also rare and only reaches 0.5% at 2 years of age; estrogen treatment in adult rats induces a variety of nonneoplastic proliferative lesions but cancer is rarely seen (17). Thus, the mature, differentiated rodent uterine epithelium responds to high

Table 4. Effect of prenatal exposure to diethylstilbestrol on fertility of male offspring.

Treatment, µg/kg/day	Number of sterile males
Corn oil, control	0/10
DES 0.1	0/10
DES 1	0/10
DES 10	1/10
DES 100	6/10

Males were 20- to 25-week-old offspring of pregnant CD-1 mice treated with DES on days 9 to 16 of gestation. Nonsterile males had the same breeding performance as controls. Data from Newbold and McLachlan (9).

doses of estrogen with sustained proliferation but it seldom undergoes neoplastic transformation. This observation suggests that the developing fetus and neonate have a unique feature that may contribute to their enhanced susceptibility to perturbation by estrogens. One of the most obvious differences is the relatively low amount of uterine epithelial estrogen receptor in these early stages of development. Studies from our laboratory show that developing uterine epithelial cells are relatively devoid of ER while epithelial cells of the oviduct and the cervix exhibit a low, but detectable, amount of ER, as demonstrated by immunocytochemistry using an anti-ER monoclonal antibody (Table 6). It is interesting to note that the uterine tissue compartment is more susceptible to neoplastic transformation than the oviductal or cervical compartment. Treatment with DES starting on day 9 of gestation induced the early appearance of ER in uterine epithelial cells; the number of positive epithelial cells and staining intensity gradually increased with age. Uterine stromal cells stained for ER were observed at all ages examined, but staining appeared to decrease with age in the control animals and with DES treatment. Similar results have been reported in male (18) and female (19) mouse reproductive tract tissues following neonatal exposure to DES (20). Additional information on the role of ER in embryonic tissues has been described by Gorski and Hou (21). It is feasible that these fetal epithelial ER have a physiological function because we have demonstrated the induction of the estrogen-responsive gene for LF in fetal uterine epithelial cells in response to estrogens (Newbold et al., unpublished data). It remains to be determined whether it is the ER-induced or the ER-deficient uterine epithelial cells that respond to DES in an aberrant manner; however, it has been proposed that the ER is a protective feature and that ER-poor cells are at risk (22).

In an attempt to further study the role of the ER in the induction of uterine tumors following developmental exposure to DES, transgenic mice that overexpress ER (MT-mER) have been created (23). These transgenic mice were treated with DES as previously described (5). No remarkable changes were seen in untreated wild-type (0/10) or untreated MT-mER (0/10) mice at 4 months of age; DES wild-type (10/10) and DES MT-mER (9/9) mice showed alterations including hypoplastic uteri with few or no glands except in the area of the uterine isthmus. Of particular interest was a DES MT-mER

Table 6. Estrogen receptor immunoreactivity in epithelial cells of reproductive tract tissues of CD-1 female mice.

Age, days	Control				Prenatal DES-100 ^a			
	Oviduct	Uterus	Cervix	Vagina	Oviduct	Uterus	Cervix	Vagina
Fetal								
13	-	-	-		±	±	±	
14	+	-	±		+	±	+	
15	+	-	±	±	+	+ ^b	+	
16	+	-	±		+2	+ ^b	+	+
17	+	-	±		+2	+		
18	+	-	±		+2	+	+	+
Neonatal								
1	+	-	+	+	+2	+		
4	+	+ ^b	+	+	+3	+2	+	
8	+2	+2	+2	+2				
10	+4	+4	+4	+4	+4	+4		
15	+5	+5	+5	+5				
17	+5	+5	+5	+5	+5	+5	+3	
22	+5	+5	+5 ^b	+5 ^b				

^aFemale CD-1 mice were exposed to DES on days 9 to 16 of gestation at 100 µg/kg/day. ^bEpithelial cells do not exhibit homogeneous staining. All sections were incubated with an equal concentration of anti-ER monoclonal antibody (Abbott Laboratories). A minimum of three fetuses or neonates, each from a different litter, were examined at each age. Staining intensity ranged from no staining (-), to strongly positive (+5). Stromal staining was also observed at all ages examined but it appeared to decrease with age in the control animals and with DES treatment.

mouse (1/9) that had atypical hyperplasia in the glands of the uterine isthmus. This pre-neoplastic lesion has never been seen in similarly treated outbred mice at this age. At 8 months of age, the control wild-type (0/12) and MT-mER (0/10) had no atypical changes in the uterus, while the DES wild-type [2/18 (11%)] and the DES MT-mER [16/23 (70%)] had uterine adenocarcinoma. The prevalence of this particular lesion increased with age so that, by 12 months of age, 78% of the DES wild-type and 100% of the MT-mER mice had uterine adenocarcinoma. A summary of this data is seen in Table 7. The induction of this lesion in this transgenic mouse model suggests that ER may play a role in DES toxic effects. These results also provide support to the hypothesis that the presence and levels of ER are important factors in the initiation as well as the maintenance of DES-induced tumors in

the female reproductive tract. Further study is underway to examine lesions in older mice and to determine possible cellular mechanisms that may be involved.

In summary, several mechanisms have been discussed that may be involved in the permanent induction of differentiation defects following developmental exposure to estrogens. This is an area that needs considerably more study, but the information that is gained will help in determining the potential risks involved in environmental estrogen exposure.

Conclusions

There are many possible cellular and molecular mechanisms that may be involved in the toxic response to DES and other environmental estrogens if an organism is exposed during critical stages of development. Several mechanisms have been discussed in this report. Studies with the developmentally DES-exposed murine model have duplicated and predicted many of the lesions seen in similarly DES-exposed humans and in the wildlife population. Currently, there is increased interest in the effects of other environmental estrogens and antiandrogens (24) on reproductive tract differentiation and development. Whether these compounds have effects similar to DES is uncertain, but since low doses of DES demonstrate alterations in both male and female exposed offspring, the possibility of adverse effects from other compounds with estrogenic and/or antiandrogenic activity must be considered.

Table 7. Prevalence of uterine adenocarcinoma in MT-mER^a mice following developmental treatment with diethylstilbestrol^b: preliminary data.

Treatment	Mouse	Age		
		4 months	8 months	12 months
Control	Wild-type	0/10	0/12	0/10
	MT-mER	0/10	0/10	0/10
DES	Wild-type	0/10	2/18 (11) ^c	7/9 (78)
	MT-mER	1/9 ^d	16/23 (70)	12/12 (100)

^aTransgenic mice are overexpressing the estrogen receptor; described by Davis et al. (23). ^bDiethylstilbestrol treatment was on days 1 to 5 of neonatal life (2 µg/pup/day) as described by Newbold and McLachlan (5). ^cNumbers in parentheses represent percent. ^dPreneoplastic lesion.

REFERENCES

1. Herbst AL, Bern HA. *Developmental Effects of Diethylstilbestrol (DES) in Pregnancy*. New York:Thieme-Stratton, 1981.
2. Iguchi T, Fukazawa Y, Bern HA. Effects of sex hormones on oncogene expression in the vagina and on the development of sexual dimorphism of the pelvis and anococcygeus muscle. *Environ Health Perspect* 103(Suppl 7):79–82 (1995).
3. McLachlan JA, Newbold RR, Shah HC, Hogan MD, Dixon RL. Reduced fertility in female mice exposed transplacentally to diethylstilbestrol (DES). *Fertil Steril* 38:364–371 (1982).
4. McLachlan JA, Newbold RR, Bullock BC. Long-term effects on the female mouse genital tract associated with prenatal exposure to diethylstilbestrol. *Cancer Res* 40:3988–3999 (1980).
5. Newbold RR, McLachlan JA. Vaginal adenosis and adenocarcinoma in mice exposed prenatally or neonatally to diethylstilbestrol. *Cancer Res* 42:2003–2011 (1982).
6. Haney AF, Hammond CB, Soules MR, Creasman WT. Diethylstilbestrol-induced upper genital tract abnormalities. *Fertil Steril* 31:142–146 (1979).
7. Bibbo M, Gill WB, Azizi F, Blough R, Fang VS, Rosenfeld RL, Schumacher GF, Sleeper K, Sonek MG, Wied GL. Follow-up study of male and female offspring of DES-exposed mothers. *Obstet Gynecol* 49:1–12 (1977).
8. Pomerance W. Post-stilbestrol secondary syndrome. *Obstet Gynecol* 42:12–18 (1973).
9. Newbold RR, McLachlan JA. Diethylstilbestrol associated defects in murine genital tract development. In: *Estrogens in the Environment* (McLachlan JA, ed). New York:Elsevier, 1985;288–318.
10. Newbold RR, Bullock BC, McLachlan JA. Lesions of the rete testis in mice exposed prenatally to diethylstilbestrol. *Cancer Res* 45:5145–5150 (1985).
11. Newbold RR, Bullock BC, McLachlan JA. Müllerian remnants of male mice exposed prenatally to diethylstilbestrol. *Teratog Carcinog Mutagen* 7:377–389 (1987).
12. Nelson KG, Sakai Y, Eitzman B, Steed T, McLachlan JA. Exposure to diethylstilbestrol during a critical developmental period of the mouse reproductive tract leads to persistent induction of two estrogen-regulated genes. *Cell Growth Differ* 5:595–606 (1994).
13. Newbold RR, Pentecost BT, Yamashita S, Lum K, Miller JV, Nelson P, Blair J, Kong H, Teng C, McLachlan JA. Female gene expression in the seminal vesicle of mice after prenatal exposure to diethylstilbestrol. *Endocrinology* 124:2568–2576 (1989).
14. Teng CT. Mouse lactoferrin gene: a marker for estrogen and EGF. *Environ Health Perspect* 103(Suppl 7):17–20 (1995).
15. Newbold RR, Bullock BC, McLachlan JA. Uterine adenocarcinoma in mice following developmental treatment with estrogens: a model for hormonal carcinogenesis. *Cancer Res* 50:7677–7681 (1990).
16. Highman B, Norvell MJ, Shellenberger TE. Pathological changes in female C3H mice continuously fed diets containing diethylstilbestrol or 17 β -estradiol. *J Environ Pathol Toxicol* 1:1–30 (1978).
17. Goodman DG, Hildebrandt PK. Adenocarcinoma, endometrium, rat. In: *The Genital System* (Jones TC, Mohr U, Hunt RD, eds). New York:Springer-Verlag, 1987;84–109.
18. Greco TL, Furlow JD, Duello TM, Gorski J. Immunodetection of estrogen receptors in fetal and neonatal male mouse reproductive tracts. *Endocrinology* 130(1):421–429 (1992).
19. Greco TL, Furlow JD, Duello TM, Gorski J. Immunodetection of estrogen receptors in fetal and neonatal female mouse reproductive tracts. *Endocrinology* 129(3):1326–1332 (1991).
20. Sato T, Okamura H, Ohta Y, Hayashi S, Takamatsu Y, Takusugi N, Iguchi T. Estrogen receptor expression in the genital tract of female mice treated neonatally with diethylstilbestrol. *In Vivo* 6:151–156 (1992).
21. Gorski J, Hou Q. Embryonic estrogen receptors: do they have physiological function? *Environ Health Perspect* 103(Suppl 7):69–72 (1995).
22. McLachlan JA, Newbold RR, Nelson KG, Korach KS. Control of uterine epithelial growth and differentiation: implications for estrogen-associated neoplasia. In: *Hormonal Carcinogenesis* (Li JJ, Nandi S, Li SA, eds). New York:Springer-Verlag, 1992;51–57.
23. Davis VL, Couse JF, Goulding EH, Power SGA, Eddy EM, Korach KS. Aberrant reproductive phenotypes evident in transgenic mice expressing the wild-type mouse estrogen receptor. *Endocrinology* 135(1):379–386 (1994).
24. Kelce WR, Monosson E, Gamcsik MP, Law SC, Gray LE Jr. Environmental hormone disruptors: evidence that vinclozolin developmental toxicity is mediated by antiandrogenic metabolites. *Toxicol Appl Pharmacol* 126:276–285 (1994).