

Retrospective Study of Possible α -2 μ -Globulin Nephropathy and Associated Cell Proliferation in Male Fischer 344 Rats Dosed with *t*-Butyl Alcohol

by Kimimasa Takahashi¹, Charles Lindamood, III,² and Robert R. Maronpot³

Tert-butyl alcohol, an important commodity chemical, additive to unleaded gasoline, and contaminant of drinking water, was evaluated for toxicity and was found to enhance nephropathy in male Fischer 344 rats. Because male rats treated with *t*-butyl alcohol for 2 years had a low incidence of renal cortical tumors, additional renal sections for the 90-day toxicity study were examined for the presence of hyaline droplet accumulation, nephropathy, and evidence of replicative DNA synthesis (S-phase nuclei) to indirectly and retrospectively investigate a possible role of α -2 μ -globulin in the pathogenesis of the nephropathy. Dose levels for *t*-butyl alcohol were 0, 0.25, 0.5, 1, 2, and 4% (w/v) administered in drinking water. Significant body weight gain depressions were observed in all treated males, and there was an absolute weight loss in the 4% male group, none of which survived to the end of the study. Except for the 4% dose group, there was a treatment-related increase in hyaline droplet accumulation in the renal proximal tubules with crystalline, rectangular, and rhomboid forms of the protein evident. The severity of nephropathy was enhanced in treated rats, except for the 4% dose group. Replicative DNA synthesis, as measured by immunohistochemical staining for proliferating cell nuclear antigen, was increased in proximal tubules of rats dosed with 2% *t*-butyl alcohol. It is concluded that *t*-butyl alcohol exacerbated nephropathy in male Fischer 344 rats and increased renal accumulation of hyaline protein material consistent with α -2 μ -globulin deposition.

Introduction

Tert-butyl alcohol is a clear liquid or crystalline substance with a camphor-like odor. It is used in the manufacture of drugs, perfumes, paint removers, plastics, lacquers, and oil-soluble polyester resins. In addition, it is a component of industrial cleaning compounds and

insecticidal formulations and an important additive to unleaded gasoline (1).

Preliminary evaluation of the National Toxicology Program 2-year carcinogenesis study of *t*-butyl alcohol suggested the possibility that there may be an increase in renal tubular neoplasms in male F344 rats treated with 0.5% *t*-butyl alcohol in drinking water (unpublished observation). This prompted a reexamination of existing kidney slides from the 90-day toxicity study of *t*-butyl alcohol to determine if there was histologic evidence suggestive of α -2 μ -globulin nephropathy. When such evidence was found in the male rats, it seemed reasonable to resection and more comprehensively reevaluate the kidney tissues from the 90-day study. The presence of an increase in protein droplets in renal tubular epithelial cells along with the occurrence of abnormally shaped cytoplasmic protein deposits is a hallmark of α -2 μ -globulin nephropathy (2,3). Since the proposed mechanism by which α -2 μ -globulin nephropathy leads to an increase in renal tumors supposedly involves cytotoxicity and secondary enhancement of

¹Institute of Environmental Toxicology, 2-772, Suzuki-cho, Kodaira-shi, Tokyo 187, Japan.

²Kettering-Meyer Laboratory, Southern Research Institute, Birmingham, AL 35225.

³National Toxicology Program, P.O. Box 12233, Research Triangle Park, NC 27709.

Address reprint requests to R. R. Maronpot, National Institute of Environmental Sciences, P.O. Box 12233, Research Triangle Park, NC 27709.

This paper was presented at the Symposium on Cell Proliferation and Chemical Carcinogenesis that was held January 14-16, 1992, in Research Triangle Park, NC.

cell proliferation (3-6), we retrospectively examined kidney sections to determine if there was enhanced replicative DNA synthesis as indicated by the presence of S-phase nuclei.

Proliferating cell nuclear antigen (PCNA) is a 36,000 molecular weight protein necessary for polymerase- δ activity associated with DNA replication (7-9). PCNA is synthesized late in G₁ and is especially abundant in S-phase nuclei of the cell cycle (9-11,15). Recently improved immunohistochemical procedures have permitted detection of PCNA in archival tissues of rats and mice (12). The use of this technique makes possible the retrospective assessment of cell replication in previously conducted rodent toxicity and carcinogenicity studies in which the animals had not been pretreated with a labeling agent. Treatment-induced alterations in S-phase cells were quantitated on archival kidney tissues from the 90-day *t*-butyl alcohol toxicity study.

Materials and Methods.

Ninety-day toxicity studies were conducted in male Fischer 344 (F344) rats using dosed water. Dose levels of *t*-butyl alcohol in drinking water were 0, 0.25, 0.5, 1, 2, and 4% (W/V). Ten animals were assigned to each group.

Blocks of formalin-fixed, paraffin-embedded kidneys from all male rats were serially sectioned at 5 μ m and stained with hematoxylin and eosin (H&E), Mallory Heidenhain (MH), and Lee's methylene blue basic fuchsin (LMBBF). Proliferating cell nuclear antigen was detected by an immunohistochemical procedure using microwave oven heating (12). The number of PCNA-positive nuclei was counted from proximal tubule epithelial cells (P1, P2, and P3 segments) in 20 microscopic fields, representing a total of 0.154 mm² of the cortex and outer medulla. The PCNA-positive nuclei that were counted were specifically of cells in S-phase.

Lesion Grading Criteria. Sections were graded numerically for amount of hyaline droplets in the proximal tubules based on the MH and LMBBF stains. Hyaline droplets scored included 0: droplets occupy 0-5% of the proximal tubule cytoplasm; 1: droplets occupy 6-30% of the proximal tubule cytoplasm; 2: droplets occupy 31-60% of the proximal tubule cytoplasm; and 3: droplets occupy greater than 60% of the proximal tubule cytoplasm.

Abnormally shaped hyaline deposits (crystalline, rhomboid structures) were graded as 0: not found; 1: rare; 2: frequent; and 3: very frequent. Nephropathy was assessed in the H&E sections. All changes represent early stages of nephropathy and lesions were graded as 0: no nephropathy observed; 1: occasional nephrons with tubular regeneration, tubular atrophy, and/or slightly thickened basement membranes; 2: several nephrons showing changes in grade 1; 3: numerous nephrons with changes in grade 1 along with dilated tubules and occasional protein casts.

Statistical Analysis. Data were analyzed by the Kruskal-Wallis and the Mann-Whitney *U*-test with *Z* scores corrected for ties. The level of significance was 0.05.

Results

All males treated with 4% *t*-butyl alcohol showed body weight loss and died between 5 and 12 weeks of the treatment. A statistically significant depression in body weight gain was observed in the 0.25-2% dose groups. At necropsy, the animals from the 4% dose group had several atrophic organs and occasional calculi in the urinary bladder and urinary tract. Except for one male in the 2% dose group that had calculi in the urinary bladder, no gross lesions were identified in the remaining treated groups (13).

Histopathological examination revealed a treatment-associated increase in the quantity of hyaline droplets and the number of intracytoplasmic deposits that were abnormal in shape (crystalline, rhomboid structures) in the 0.25-2% dose groups and a decrease in the 4% dose group (Figs. 1-3). These changes were detected only in the proximal epithelial cells of the cortex and outer medulla. Hyaline droplets observed in the control animals were usually small and round, and rarely formed crystals (Fig. 4). These hyaline droplets were not conspicuous in H&E sections but were clearly demonstrated by MH or LMBBF staining methods.

Nephropathy was exacerbated in male rats in all treated groups (Figs. 1 and 5) as compared with the control, except for the males in the 4% dose group. There was a direct relationship between the increased severity of nephropathy, hyaline droplet accumulation, and deposition of abnormal crystals.

The number of PCNA-stained S-phase nuclei was significantly increased in the 2% dose group; although not statistically significant, a similar increase was also present in the 1% group (Figs. 6 and 7). In the 4% dose group there was a significant decrease in PCNA-labeled renal tubular epithelial cells when compared to the control.

Discussion

Chemically induced renal cortical tumors have been observed in rats in several studies where the mechanism has been hypothesized to be related to accumulation of α -2 μ -globulin in the P2 segment of the proximal tubule and subsequent enhanced cell proliferation secondary to cytotoxicity (3-6). This proposed mechanism is restricted to male rats that have androgen-dependent synthesis of α -2 μ -globulin in the liver.

Little is known about nephrotoxicity of *t*-butanol or other butanol isomers, except the description of moderate and reversible fatty infiltration in the kidneys of mice exposed to the chemical (1). The nephropathy observed in dosed male rats in the present study was more severe than in controls and there was an increase

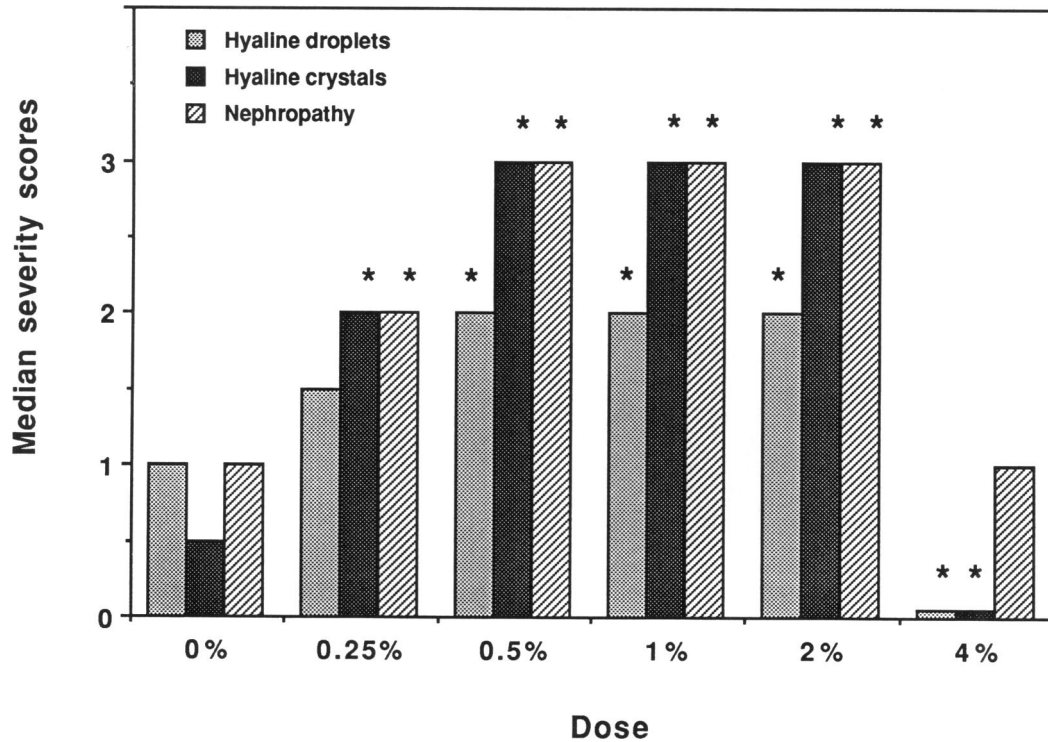


FIGURE 1. Histopathological results in male Fischer rats treated with *t*-butyl alcohol. (*) Statistically different from the control group at $p < 0.05$.

in the number and size of hyaline droplets, which were frequently abnormal in shape (crystalline, rhomboid structures). These renal changes in *t*-butanol-dosed rats were consistent with α -2 μ -globulin nephropathy. Definitive confirmation of this presumption would require a specific quantitative measurement of α -2 μ -globulin in appropriately preserved renal tissue.

Evidence of enhanced hyaline droplet deposition and hyaline crystals in tubular epithelium was observed in all treated groups of males with the exception of the 4% dose group, in which all rats died before the end of the study; in this latter group there was absolute body weight loss with atrophy of several organs. Enhanced cell proliferation, indicated by an increase in PCNA-

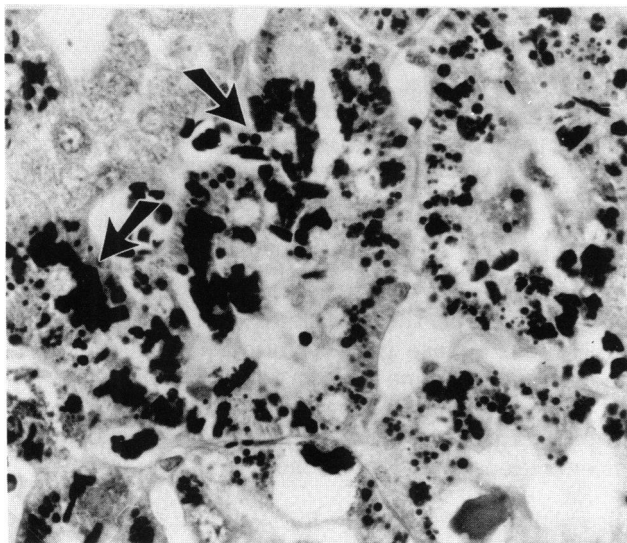


FIGURE 2. Kidney cortex from a male rat in the 2% dose group. Increased protein droplets together with many crystals (arrows) are present in proximal tubular epithelial cells. MH stain, 460 \times .

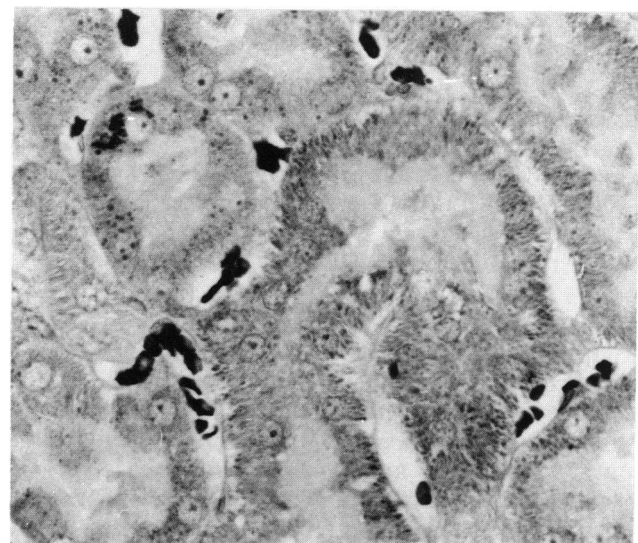


FIGURE 3. Kidney cortex from a male rat in the 4% dose group. Proximal tubular epithelial cells are almost devoid of protein droplets. MH stain, 460 \times .

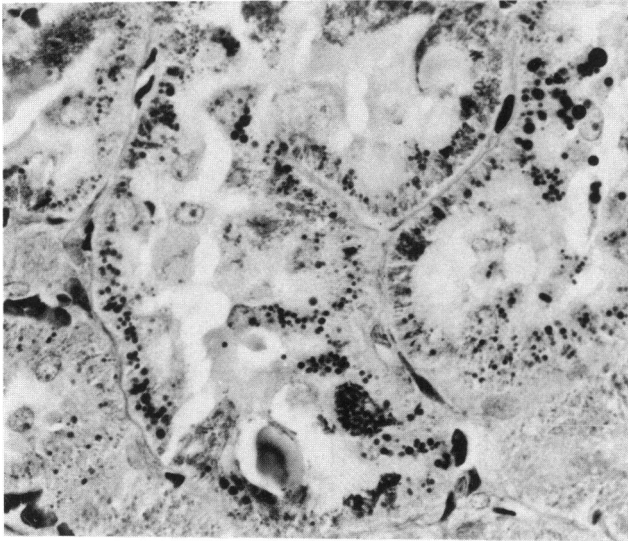


FIGURE 4. Kidney cortex from a control male rat. A small number of protein droplets are present in proximal tubular epithelial cells. MH stain, 460X.

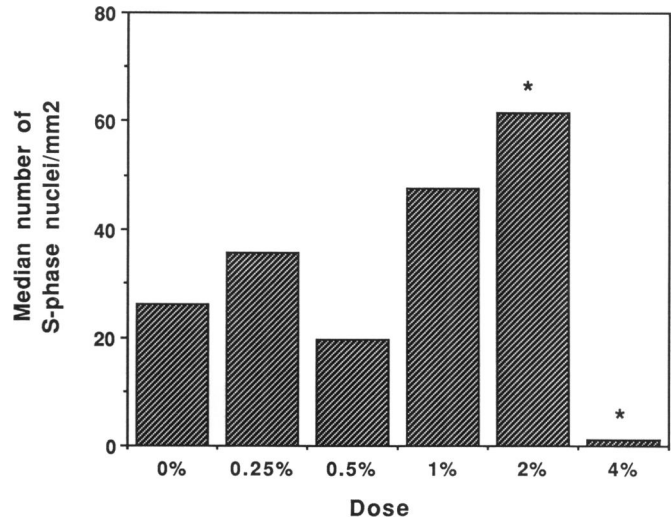


FIGURE 6. Replicative DNA synthesis in proximal tubules of male rats treated with *t*-butyl alcohol. (*) Statistically different from the control group at $p < 0.05$.

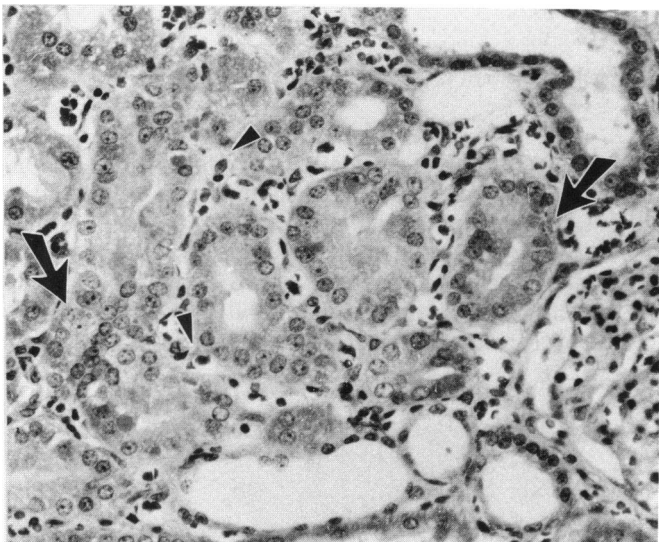


FIGURE 5. Mild nephropathy in a male rat in the 2% dose group showing tubular regeneration with crowded nuclei (arrows). Note minimal mononuclear cell infiltration (arrowheads). H&E, 208X.

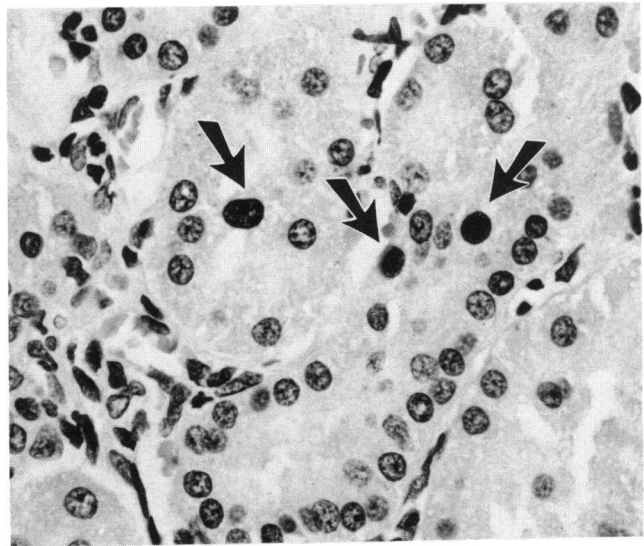


FIGURE 7. Proliferating cell nuclear antigen (PCNA) stain of kidney section from the 2% dose group. Three PCNA-positive nuclei (arrows) are present. Hematoxylin counterstain, 460X.

positive S-phase cells, was significant in the 2% dose group. The trend for this increase was seen in the 1% dose group, although not statistically significant. The increase in cell proliferation in this study (as measured by increased PCNA staining) generally supports the concept that the accumulation of excess hyaline droplets is a key factor in enhanced cell proliferation in the kidney of male rats (2,3). However, it does not explain the absence of an increase in PCNA staining in the 0.5% dose group, which had the same severity of renal changes as observed in the 1 and 2% dose groups.

It is possible that the hyaline droplet accumulation in the 1 and 2% dose groups had been present for a longer period of time than in the 0.5% dose group or that there was enhanced renal toxicity and increased cell proliferation as a direct result of higher exposure concentrations of *t*-butyl alcohol.

Special thanks to Beth Gaul for PCNA staining, to John L. Horton for photography, and to Mike Elwell and Burhan Ghanayem for help in preparing this paper. Information in this paper presents a more detailed description of selected data reported in *Fundam. Appl. Toxicol.* 19: 91-100 (1992).

REFERENCES

1. Cosmetic Ingredient Review Expert Panel. Final report on the safety assessment of *t*-butyl alcohol. *J. Am. Coll. Toxicol.* 8: 627-641 (1989).
2. Dietrich, D. R., and Swenberg, J. A. NCI-Black-Reiter (NBR) male rats failed to develop renal disease following exposure to agents that induce α -2 μ -globulin (α 2 μ) nephropathy. *Fundam. Appl. Toxicol.* 16: 749-762 (1991).
3. Short, B. G., Burnett, V. L., Cox, M. G., Bus, J. S., and Swenberg, J. A. Site-specific renal cytotoxicity and cell proliferation in male rats exposed to petroleum hydrocarbons. *Lab. Invest.* 57: 564-577 (1987).
4. Dietrich, D. R., and Swenberg, J. A. The presence of α 2 μ -globulin is necessary for d-limonene promotion of male rat kidney tumors. *Cancer Res.* 51: 3512-3521 (1991).
5. Goldsworthy, T. L., Lyght, O., Burnett V. L., and Popp, J.A. Potential role of alpha-2 μ -globulin, protein droplet accumulation, and cell replication in the renal carcinogenicity of rats exposed to trichloroethylene, perchloroethylene, and pentachloroethylene. *Toxicol. Appl. Pharmacol.* 96: 367-379 (1988).
6. Swenberg, J. A., Short, B., Borghoff, S., Strasser, J., and Charbonneau, M. The comparative pathology of α 2 μ -globulin nephropathy. *Toxicol. Appl. Pharmacol.* 97: 35-46 (1989).
7. Bauer, G. A., and Burgers, P. M. The yeast analog of mammalian cyclin/proliferating cell nuclear antigen interacts with mammalian DNA polymerase delta. *Proc. Natl. Acad. Sci. U.S.A.* 85: 7506-7510 (1988).
8. Bravo, R., Frank, R., Blundell, P. A., and MacDonald-Bravo, H. Cyclin/PCNA is the auxiliary protein of DNA polymerase delta. *Nature* 326: 515-517 (1987).
9. Celis, J. E., Madsen, P., and Celis, A. Cyclin (PCNA, auxiliary protein of DNA polymerase delta). *FEBS Lett.* 220: 1-7 (1987).
10. Celis, J., and Celis, A. Cell cycle dependent variations in the distribution of the nuclear protein cyclin proliferating cell nuclear antigen in cultured cells: subdivision of S phase. *Proc. Natl. Acad. Sci. U.S.A.* 82: 3262-3266 (1985).
11. Takasaki, Y., Deng, J. S., and Tan, E. M. A nuclear antigen associated with cell proliferation and blast transformation. Its distribution in synchronized cells. *J. Exp. Med.* 154: 1899-1909 (1981).
12. Greenwell, A., Foley, J. F., and Maronpot, R. R. An enhancement method for immunohistochemical staining of proliferating cell nuclear antigen in archival rodent tissues. *Cancer Lett.* 59: 251-256 (1991).
13. Lindamond, C., III, Farnell, D. R., Giles, H. D., Prejean, J. D., Collins, J. J., Takahashi, K., and Maronpot, R. R. Subchronic toxicity studies of *t*-butyl alcohol in rats and mice. *Fundam. Appl. Toxicol.* 19: 91-100 (1992).
14. Von Oettingen, W. F. The Aliphatic Alcohols. Health Bulletin No. 281, U. S. Public Health Service, Washington, D.C. 1943.
15. Kurki, P., and Vanderlaan, M. Expression of proliferating cell nuclear antigen (PCNA) cyclin during the cell cycle. *Exp. Cell. Res.* 166: 209-219 (1986).