

# Detecting Proliferating Cell Nuclear Antigen in Archival Rodent Tissues

by Arnold Greenwell,<sup>1</sup> Julie F. Foley,<sup>1</sup>  
and Robert R. Maronpot<sup>1</sup>

**The detection of proliferating cell nuclear antigen (PCNA), an endogenous cell replication marker, has lacked sensitivity in paraffin-embedded archival tissues fixed in formalin. An enhanced immunohistochemical procedure to detect PCNA has been successfully applied to rat and mouse tissues. Tissue sections are heated in a microwave oven in the presence of an antigen-retrieval solution of heavy-metal salts. Positive immunostaining of S-phase cells, an indication of DNA replicative activity, has been consistently obtained in tissues fixed for more than 24 months in formalin and in paraffin blocks stored for up to 19 months. Use of this technique will allow retrospective staining of rodent tissues from previously conducted toxicity and carcinogenicity studies.**

The role of sustained, enhanced cell proliferation in the induction of neoplasia has created renewed interest in and controversy over the mechanisms of carcinogenesis (1-4). Lack of cell proliferation data and the cost of repeating rodent toxicity and carcinogenicity studies has precluded the resolution of this issue.

Identification of proliferating cells is indirectly assessed by labeling cells when they are in S phase of the cell cycle and is quantitated by the labeling index. Historically, agents such as tritiated thymidine and bromodeoxyuridine, a thymidine analog, were administered before sacrifice and incorporated into cells during DNA synthesis (S phase of the cell cycle). More recently, proliferating cell nuclear antigen (PCNA), an auxiliary protein of DNA polymerase- $\delta$  (5-7), has been shown to be a highly stable protein found in all mammalian tissues (8) and serves as an endogenous cell replication marker. PCNA is present in normal and transformed proliferating tissue culture cells, cryostat sections, and alcohol- and formalin-fixed paraffin-embedded tissues (8-13). PCNA staining characteris-

tics in rat liver fixed overnight in formalin allow the identification of cells in the quiescent ( $G_0$ ), interphase ( $G_1$ , S,  $G_2$ ) and mitotic stages of the cell cycle (14). However, detection of PCNA has lacked sensitivity in paraffin-embedded tissues fixed in formalin for 1 week or more, as commonly occurs in toxicity and carcinogenicity bioassays.

An enhanced immunohistochemical procedure to detect PCNA has been successfully applied to formalin-fixed, paraffin-embedded archival rat and mouse tissues (15). Tissue fixation in formalin varied from 1 week to 27 months. The unmasking of antigenic sites was accomplished by heating tissue sections in a microwave oven in the presence of a commercially available antigen retrieval solution of heavy metal salts before PCNA immunostaining.

Current modifications to the PCNA immunohistochemistry to improve background staining problems included changes in the protein-blocking reagent, from 1% normal goat serum to 0.5% nonfat powdered milk, and the replacement of the link antibody to a biotinylated anti-mouse IgM ( $\mu$ -chain specific; Vector Laboratories, Burlingame, CA). Microwave times vary depending on tissues and chemical treatment. Two to five minutes on the highest power (700 watts) was found to be sufficient for all tissues tested.

Intense nuclear staining of S-phase cells, an indication of DNA replicative activity, was consistently obtained in tissues fixed for 27 months in formalin and in paraffin blocks stored for up to 19 months (Figure 1B, D). This technique has been successfully applied to liver, kidney, spleen, forestomach, glandular stomach,

<sup>1</sup>National Toxicology Program, National Institute of Environmental Health Sciences, P.O. Box 12233, Research Triangle Park, NC 27709.

Address reprint requests to A. Greenwell, National Institute of Environmental Health Sciences, P.O. Box 12233, Research Triangle Park, NC 27709.

This paper was presented at the Symposium on Cell Proliferation and Chemical Carcinogenesis that was held January 14-16, 1992, in Research Triangle Park, NC.

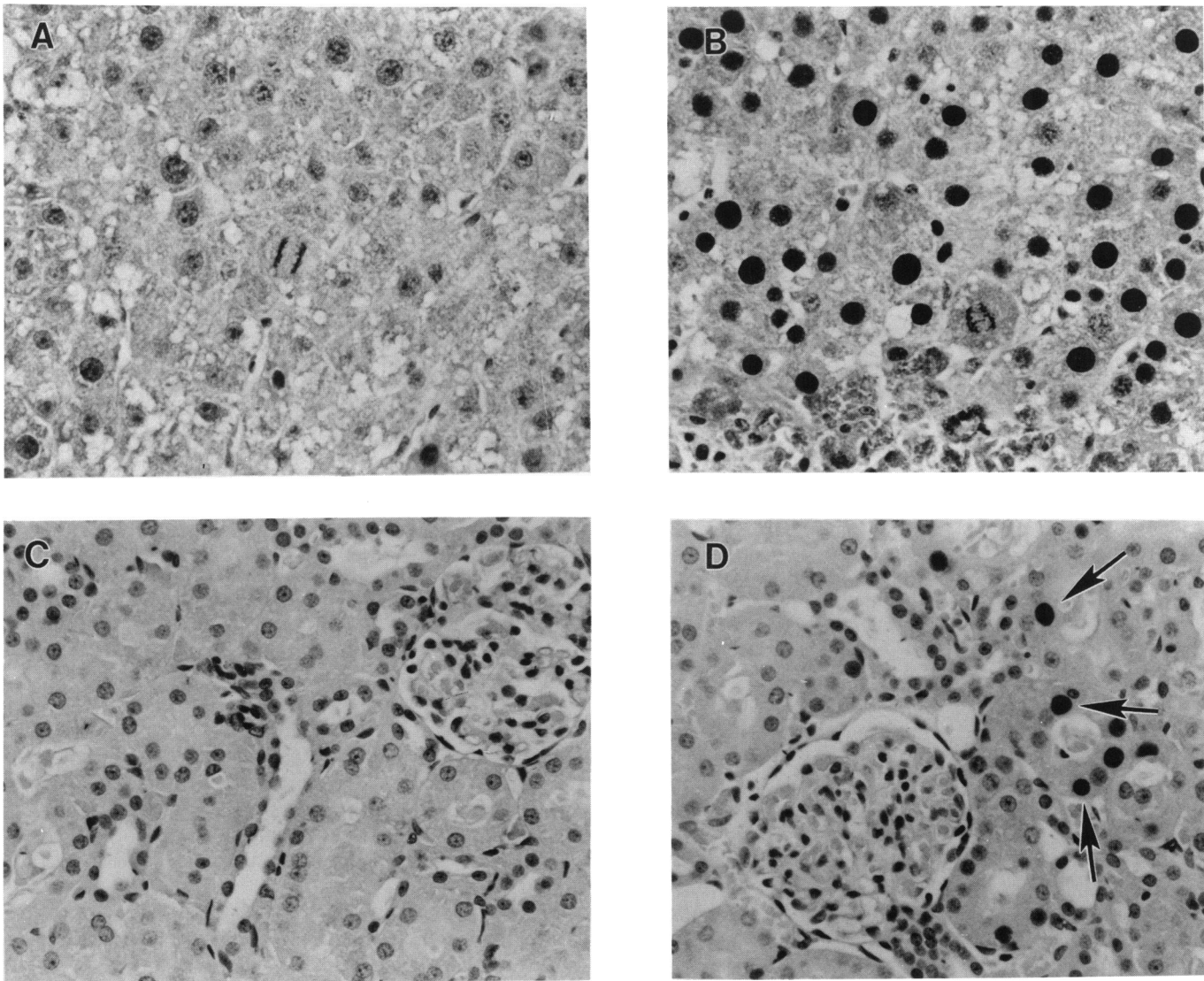


FIGURE 1. (A) Section from a Sprague-Dawley rat liver fixed in formalin for several months before paraffin embedding. The rat was treated with 620 mg/kg bromobenzene for 48 hr. No positively stained nuclei are apparent when stained in the absence of the antigen-retrieval solution. (B) Same section microwaved in the presence of the antigen-retrieval solution. Note the appearance of many proliferating cell nuclear antigen-positive nuclei. H&E 100 $\times$ . (C) Kidney section from the same rat stained without the antigen-retrieval solution. No nuclear staining is apparent. (D) Many positively stained nuclei (arrows) are present after pretreatment with the antigen retrieval solution. Hematoxylin, 100 $\times$ .

small intestine, esophagus, testis, and lung. Late  $G_1$  cells showed light nuclear staining of PCNA, whereas cells in  $G_2$  and mitosis had diffuse cytoplasmic staining. Archival tissues stained in the absence of the antigen-retrieval solution showed minimal to no nuclear staining (Figure 1A, C). Similarly, predigestion of tissue sections with a battery of proteolytic enzymes did not unmask antigenic sites in the absence of pretreatment with the antigen-retrieval solution.

Formalin fixation results in protein cross-links in tissues. Continued formalin exposure increases the degree of cross-linking and masks antigenic sites such that they cannot react with specific antibodies. The antigen-retrieval technique based on microwave heat-

ing of tissue sections in the presence of heavy-metal salts permits enhancement of immunohistochemical staining of tissue antigens in a variety of formalin-fixed, paraffin-embedded tissues (16). Use of this technique will allow retrospective staining of rodent tissues in previously conducted toxicity and carcinogenicity studies in which the animals were not pretreated with a labeling agent.

#### REFERENCES

1. Ames, B. N., and Gold, L. S. Chemical carcinogenesis: too many rodent carcinogens. *Proc. Natl. Acad. Sci. U.S.A.* 87: 7772-7776 (1990).

2. Ames, B. N., and Gold, L. S. Too many rodent carcinogens: mitogenesis increases mutagenesis. *Science* 249: 970-971 (1990).
3. Cohen, S. M., and Ellwein, L. B. Cell proliferation in carcinogenesis. *Science* 249: 1007-1011 (1990).
4. Weinstein, I. B. Mitogenesis is only one factor in carcinogenesis. *Science* 251: 387-388 (1991).
5. Bauer, G. A., and Burgers, P. M. The yeast analog of mammalian cyclin/proliferating cell nuclear antigen interacts with mammalian DNA polymerase delta. *Proc. Natl. Acad. Sci. U.S.A.* 85: 7506-7510 (1988).
6. Bravo, R., Frank, R., Blundell, P. A., and MacDonald-Bravo, H. Cyclin/PCNA is the auxiliary protein of DNA polymerase delta. *Nature* 326: 515-517 (1987).
7. Celis, J. E., Madsen, P., and Celis, A. Cyclin (PCNA, auxiliary protein of DNA polymerase delta). *FEBS Lett.* 220: 1-7 (1987).
8. Kurki, P., and Vanderlaan, M. Expression of proliferating cell nuclear antigen (PCNA)/Cyclin during the cell cycle. *Exp. Cell Res.* 166: 209-219 (1986).
9. Celis, J. E., Bravo, R., Larsen, P. M., and Fey, S. J. Cyclin: a nuclear protein whose level correlates directly with the proliferative state of normal as well as transformed cells. *Leukemia Res.* 8: 143-157 (1984).
10. Galand, P., and Degraef, C. Cyclin/PCNA immunostaining as an alternative to tritiated thymidine pulse labelling for marking S phase cells in paraffin sections from animal and human tissues. *Cell Tissue Kinet.* 22: 383-392 (1989).
11. Garcia, R. L., Coltrera, M. D., and Gown, A. M. Analysis of proliferative grade using anti-PCNA/cyclin monoclonal antibodies in fixed, embedded tissues: Comparison with flow cytometric analysis. *Am. J. Pathol.* 134: 733-739 (1989).
12. Hall, P. A., Levison, D. A., Woods, A. L., Yu, C. C.-W., Kellock, D. B., Watkins, J. A., Barnes, D. M., Gillett, C. E., Camplejohn, R., Dover, R., Waseem, N. H., and Lane, D. P. Proliferating cell nuclear antigen (PCNA) immunolocalization in paraffin sections: an index of cell proliferation with evidence of deregulated expression in some neoplasms. *J. Pathol.* 162: 285-294 (1990).
13. Thaete, L., Ahnen, D., and Malkinson, A. Proliferating cell nuclear antigen (PCNA/cyclin) immunocytochemistry as a labeling index in mouse lung tissues. *Cell Tissue Res.* 256: 167-173 (1989).
14. Foley, J. F., Dietrich, D. R., Swenberg, J. A., and Maronpot, R. R. The detection and evaluation of proliferating cell nuclear antigen (PCNA) in rat tissue by an improved immunohistochemical procedure. *J. Histochemol.* 14(4): 237-241 (1991).
15. Greenwell, A., Foley, J. F., and Maronpot, R. R. An enhancement method for immunohistochemical staining of proliferating cell nuclear antigen in archival rodent tissues. *Cancer Lett.* 59: 251-256 (1991).
16. Shi, S.-R., Key, M. E., and Kalra, K. L. Antigen retrieval in formalin-fixed, paraffin-embedded tissues: an enhancement method for immunohistochemical staining based on microwave oven heating of tissue sections. *J. Histochem. Cytochem.* 39: 741-748 (1991).