

# Relationships between Hepatic Neoplasms and Related Lesions and Exposure to Toxic Chemicals in Marine Fish from the U.S. West Coast

by Mark S. Myers,\* John T. Landahl,\* Margaret M. Krahn,\* and Bruce B. McCain\*

English sole (*Parophrys vetulus*) inhabiting polluted waterways and embayments of Puget Sound, Washington, are affected with a variety of multiple, co-occurring idiopathic hepatic lesions, including unique degenerative conditions, putatively preneoplastic foci of cellular alteration, and neoplasms. Results of a statistical analysis of the patterns of co-occurrence of these lesions in wild English sole are consistent with the concept that these lesions represent morphologically identifiable steps forming a sequence of progression ultimately leading to the development of hepatic neoplasms. This progressive sequence parallels the pattern identified in experimental models of chemically induced hepatocarcinogenesis in rodents. The rationale for the hypothesis that these lesions in wild English sole can be caused by exposure to certain hepatotoxic and hepatocarcinogenic xenobiotic compounds in the marine environment is based on the demonstration of significant and consistent statistical associations between levels of aromatic hydrocarbons (AHs) in sediment and prevalences of these idiopathic liver lesions; a significant contribution by sediment AHs to the variability in hepatic neoplasm prevalence in a logistic regression model; significantly increased probabilities for several idiopathic lesions in sole from chemically contaminated sites in Puget Sound; significant correlations between uptake of polycyclic aromatic hydrocarbons, as measured by levels of fluorescent metabolites of aromatic compounds in bile of sole, and prevalences of several hepatic lesion types; and experimental induction of unique degenerative, proliferative, and putatively preneoplastic focal lesions in English sole injected with either benzo(a)pyrene or a polycyclic aromatic hydrocarbons (PAH) enriched fraction of an extract from a contaminated urban sediment from Puget Sound. Similar types of idiopathic hepatic lesions have been detected in white croaker (*Genyonemus lineatus*) captured from contaminated marine sites in the vicinity of Los Angeles, California. Although the evidence also suggests involvement of xenobiotic contaminants in the etiology of hepatic lesions in this species, no strong statistical association between lesion prevalence and contaminant exposure have been established, primarily due to the low prevalences of these lesions detected in white croaker. Data are not sufficient to conclusively establish the existence of a human health risk due to consumption of contaminant-exposed English sole and other fish species affected by hepatic neoplasms or related lesions. Because PAHs are extensively metabolized in the liver of fish, sensitive and reliable methods for detection of PAH metabolites in fish tissues need to be developed before credible assessments of human health risk due to consumption of PAH-contaminated fish muscle can be conducted.

## Introduction

For the past 15 years, our laboratory has been engaged in fish pathology research in Puget Sound and other marine coastal areas of the United States, using a multidisciplinary approach to study the deleterious effects in fish resulting from exposure to sediment-associated xenobiotic chemicals. This strategy combines histopathologic examination of resident fish with chemical analyses of sediment and various fish tissues and bile and analyses of several activation/detoxication enzymes in fish tissues. This sampling design was developed subsequent to the

documentation of significant prevalences of hepatic neoplasms in English sole from the Duwamish Waterway, an urban waterway in Seattle that receives industrial, municipal, and agricultural wastes (1). The bottom sediments in this waterway contain high levels of carcinogenic polynuclear aromatic hydrocarbons [including benzo(a)pyrene (BaP) and benzanthracene], various heavy metals, polychlorinated biphenyls (PCBs), and other chlorinated hydrocarbons (2).

Extensive, long-term studies in Puget Sound (2-10) have further assessed and described the hepatic histopathology of several demersal marine fish species, focusing on the English sole (*Parophrys vetulus*) as the primary indicator organism, from over 50 sites exhibiting a broad range of sediment pollutant profiles and concentrations. Results from these field studies have provided strong evidence supporting the hypothesis that liver neoplasms and other liver lesions in this species are the result of

\*Environmental Conservation Division, Northwest Fisheries Center, National Marine Fisheries Service (NOAA), 2725 Montlake Boulevard E., Seattle, WA 98112.

Address reprint requests to M. S. Myers, Northwest Fisheries Center, 2725 Montlake Boulevard E., Seattle, WA 98112.

exposure to sediment-associated chemical contaminants. To date, of the identifiable sediment-associated chemicals, polycyclic aromatic hydrocarbons (PAHs) appear to be the most likely chemical etiologic agents for these liver lesions.

The vertebrate liver is well recognized as a target organ for effects of xenobiotic chemicals and carcinogens; we have therefore directed our efforts in the area of fish pathology to detecting potentially toxicopathic liver lesions in wild fish, especially English sole. Because certain hepatic lesions in wild fish resemble conditions induced in rodents and fish by controlled exposure to toxicants and carcinogens, these lesions represent potential indicators of effects from exposure to xenobiotic chemicals in the environment. The advantage of this approach, when combined with supportive data demonstrating exposure to and uptake of xenobiotic chemicals, is that the presence of liver lesions in wild fish that are morphologically identical to those induced by hepatotoxins/hepatocarcinogens in lab studies provides a direct method of assessing the potential sublethal effects of xenobiotics on wild fish. The major goal of our research has been to investigate the etiology of liver neoplasms and other related lesions, primarily in bottomfish species in contact with contaminated sediments, and by doing so, determine the significance of these lesion types as reliable biological indicators of effects of toxic/carcinogenic chemical exposure. To date our research goals have not specifically included the investigation of human health effects resulting from consumption of chemically contaminated fish. However, the results of our studies have a strong bearing on studies related to human health risk because they demonstrate the exposure of commercially and recreationally important fish species to chemical toxicants and carcinogens.

## Hepatic Pathology of Wild English Sole

Of the species studied in Puget Sound, English sole is the most useful indicator species and displays a spectrum of multiple, co-occurring idiopathic liver lesions (Table 1) that is quite similar to the variety of hepatic lesions induced experimentally by chemical hepatotoxins and carcinogens in the mouse, rat, and certain fish species (11). These lesions are found almost strictly, or at significantly higher prevalences, in English sole captured from highly polluted urban estuaries and embayments in Puget Sound as compared to relatively unpolluted reference stations (2,5-10). This geographic pattern of lesion distribution in English sole is closely paralleled by other bottom-dwelling species in Puget Sound, including rock sole (*Lepidopsetta bilineata*) and starry flounder (*Platichthys stellatus*), but lesions are observed at lower prevalences in these species (12). By virtue of their morphologic similarity to lesions induced by experimental exposure to hepatotoxins and hepatocarcinogens in rodents and fish and the geographic distribution of affected fish within Puget Sound, we have hypothesized these lesion types to be a likely result of contaminant exposure.

The pathologic anatomy of these lesion types in English sole has recently been comprehensively described (11). The most frequently encountered idiopathic hepatic lesion, appearing first in young of the year or juvenile fish (10) is a unique, non-proliferative degenerative condition characterized by a marked increase in nuclear and cellular diameters in affected hepatocytes, nuclear hyperchromasia, and various cytoplasmic degenerative changes including hyalinization and hydropy.

**Table 1. Significant idiopathic hepatic lesions in English sole.**

Lesion type/category	Description
Hepatocellular necrosis/degeneration	Nonspecific, degenerative, includes spongiosis hepatitis
Nuclear pleomorphism	Unique, degenerative
Megalocytic hepatitis	Unique, degenerative
Hepatocellular degeneration	Proliferative, nonneoplastic
Clear cell focus of cellular alteration	Preneoplastic
Eosinophilic focus of cellular alteration	Preneoplastic
Basophilic focus	Preneoplastic
Liver cell adenoma	Benign neoplasm
Hepatocellular carcinoma	Malignant neoplasm
Cholangioma	Benign neoplasm
Cholangiocellular carcinoma	Malignant neoplasm
Mixed hepatobiliary carcinoma	Malignant neoplasm
Cholangiofibrosis	Proliferative, nonneoplastic
Hemosiderosis	Storage disorder
Steatosis/fatty change	Storage disorder

Because there is no appreciable accompanying cellular inflammatory response, this lesion is termed megalocytic hepatitis. Megalocytic hepatitis and its related precursor condition, nuclear pleomorphism, are identical to the early changes induced by a spectrum of hepatotoxicants and carcinogens in rodent models and are interpreted as manifestations of the chronic to subchronic hepatotoxicity of these compounds. Such hepatic degeneration and necrosis is known to be an essential early step in hepatic carcinogenesis, and functions to provide a stimulus for the compensatory proliferative response that actually fixes the molecular lesions in the hepatocellular DNA that are responsible for neoplastic transformation and initiation (13).

The lesion that most frequently co-occurs (11) with megalocytic hepatitis is hepatocellular regeneration. This lesion represents the compensatory proliferative response to the degeneration and necrosis manifest in megalocytic hepatitis that is a necessary step in the process of hepatic neoplasia (14,15). These regenerative cells may be the population of proliferative cells from which initiated hepatocytes develop, according to the two-stage initiation-promotion model of hepatocarcinogenesis, and may represent a population of cells that are resistant to the cytotoxic effects (16) of the carcinogens present in the polluted sediments in which the English sole resides.

Also frequently co-occurring with megalocytic hepatitis and regenerative hepatocytes are discrete, spherical foci or micronodules of three basic types (11), based on their tinctorial qualities in the standard hematoxylin and eosin stain. These foci of cellular alteration generally first appear in fish at least 1 year of age (10). These foci are considered to be preneoplastic lesions in rodent hepatocarcinogenesis models (17), from which true neoplasms may develop under the correct conditions and which represent an obligatory precursor step in the induction of hepatic neoplasms (18). The borders of these focal lesions blend into the surrounding parenchyma, and there is no compression. The three basic types of foci of cellular alteration seen in English sole are the eosinophilic, basophilic, and clear cell focus. All three types of foci can be recognized histochemically by a reduction or absence in cytoplasmic iron in both English sole (11) and rodents (19) and rarely contain other hepatic elements such as bile ducts, pancreatic acini, blood vessels, or melanomacrophage centers (macrophage aggregates). The relationship among these

foci types in terms of their role and fate in hepatocarcinogenesis is not well understood. However, it is commonly believed that the basophilic focus is the focal lesion most proximate, in the temporal sense, to the development of true hepatocellular neoplasms in rodents (20,21) and is considered a small hepatocellular carcinoma in the rainbow trout model (22).

Substantial prevalences (up to 25%) of hepatic neoplasms are also found in adult English sole generally at least 2 years of age (10) and almost strictly from polluted sites in Puget Sound. These lesions are typically obvious grossly (11), and often multiple nodules form the bulk of the liver. The basic histologic types of hepatic neoplasms found are, of necessity, classified strictly on their morphologic appearance because we have little information on their biological behavior and no information as to the eventual clinical outcome in affected fish. Liver cell adenomas are characterized by compression of the surrounding parenchyma, well defined separation of proliferative tissue from normal tissue, fairly normal architecture, and relative absence of other hepatic elements. Liver cell adenomas are usually basophilic, but eosinophilic and vacuolated variants do occur. As is the case for all hepatocellular neoplasms in English sole, the composite hepatocytes are resistant to iron accumulation (11).

Hepatocellular neoplasms with accepted histologic features of malignancy are also found in English sole. These hepatocellular carcinomas are typically multiple, with irregular borders, and show compression and invasion. They have an irregular trabecular architecture and are composed of polygonal, pleomorphic, anaplastic, and occasionally vacuolated hepatocytes showing loss of cellular polarity with respect to their orientation toward the sinusoids. Occasionally found within adenomas are areas of hepatocytes with a morphology consistent with a carcinoma. These nodules within nodules suggest progression from an adenoma to a carcinoma as one possible pathway of carcinoma development (11).

A distinct class of hepatic neoplasms originate from epithelial cells of the intrahepatic biliary system. These neoplasms are characterized by a proliferation of biliary epithelium assuming relative degrees of tubular organization. Well-organized and benign-appearing tumors of biliary origin are rare, and the cholangiocellular carcinoma composed of irregular tubular profiles that invade and insinuate into the surrounding hepatocellular parenchyma is typically found. All neoplasms of this type are invasive, replace high proportions of the parenchyma, and can metastasize (11). We can therefore confidently diagnose tumors with similar morphology as carcinomas. The histologic and ultrastructural detail of this class of neoplasms in English sole has recently been described (23). Occasionally we detect carcinomas with a mixed biliary and hepatocellular origin (11).

No evidence of a viral etiology for any of these lesions in English sole has been revealed through ultrastructural observation by transmission electron microscopy (23,24).

## Patterns of Hepatic Lesion Co-Occurrence in Wild English Sole

Livers of English sole from polluted sites in Puget Sound are affected by a spectrum of multiple, co-occurring idiopathic liver lesions that closely parallels (11) the degenerative, regenerative, preneoplastic, and neoplastic hepatic lesions induced experi-

mentally by chemical hepatotoxins and hepatocarcinogens in the mouse, rat (7) and certain fish species (22,25). To clarify the role of these lesion types within the context of the process of liver neoplasia in English sole, we conducted a statistical analysis of lesion type co-occurrence in English sole from Eagle Harbor, Washington (11), a site with sediments severely polluted by polycyclic aromatic hydrocarbons (4) released from a nearby creosote plant (26). The inferences from this analysis are that lesions which co-occur at levels of statistical significance may be caused by etiologic agents that are associated with each other and/or may be temporally related to one another. One possible temporal association would include involvement in a series of lesions progressing toward hepatic neoplasms, as has been clearly demonstrated in rodent hepatocarcinogenesis models (17,27). This type of analysis represents an attempt to interpret, in a temporal sense, the profusion of multiple hepatic lesion types typically encountered in wild English sole, a pattern consistent with what one would expect under a situation of continuous exposure to chemical hepatocarcinogens (28).

The significant patterns emerging from this analysis are shown in Figure 1 and are consistent with the experimentally determined temporal histogenesis of chemically induced hepatic neoplasia in the mouse and rat (17) and rainbow trout (22). Megalocytic hepatitis is viewed as the initial degenerative lesion resulting from the cytotoxic effects of the hepatocarcinogens English sole are exposed to in the sediment. This is because megalocytic hepatitis appears first in fish less than 1 year of age (10), and is the most common hepatic lesion detected in juvenile sole (10; Myers, unpublished observations), is associated with other degenerative and necrotic conditions of the liver (11), is the most common idiopathic lesion detected in juvenile or adult sole from contaminated sites (10,11; Myers, unpublished observations), and appears identical to the initial lesions resulting from experimental exposure to certain hepatocarcinogens in the mouse, rat, and certain fish species.

Megalocytic hepatitis is strongly associated with hepatocellular regeneration, manifesting the compensatory proliferative response to the liver degeneration and necrosis seen in and associated with this lesion, and which is an essential step in neoplasia in chemically induced, experimental hepatocarcinogenesis in rodents (15). Megalocytic hepatitis is also associated with all three major types of foci of cellular alteration (FCA) (clear cell, eosinophilic, and basophilic focus), which are considered preneoplastic lesions in rodent hepatocarcinogenesis models from which true neoplasms may develop under the correct conditions (18). In rodent hepatocarcinogenesis models, development of these focal lesions represents an obligatory precursor step in the induction of hepatocellular neoplasms. Focal lesions occur earliest in sole at least 1 year of age and are found at higher prevalences in older adults (10). Based on these strong associations, the age of affected fish, and the established temporal histogenesis of liver neoplasia in rodents, we believe that the regenerative and preneoplastic focal lesions follow the initial hepatotoxic lesion, megalocytic hepatitis.

Strong, consistent associations also exist among all of the preneoplastic FCA and between these focal lesions and hepatic neoplasms, especially the liver cell adenoma. These patterns strongly suggest that the focal lesions in English sole are, in fact, preneoplastic lesions. The lack of a strong association between

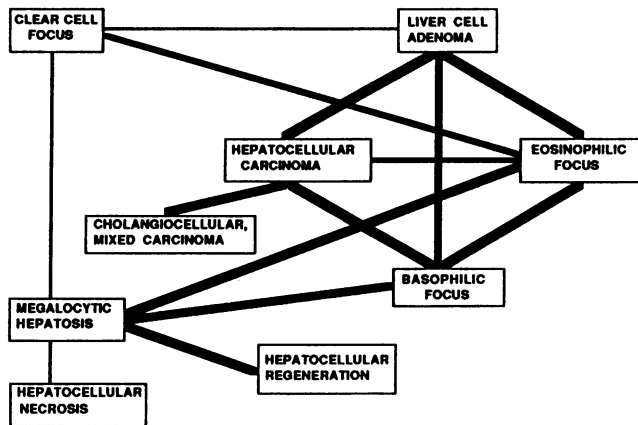


FIGURE 1. Histogenetic relationships (associations determined by three-way contingency analysis) among idiopathic lesions involved in hepatic neoplasia in feral English sole. Lines between lesion types indicate significant associations between those lesions, in terms of their frequency of co-occurrence. Thickness of lines shows the relative consistency of that association. Diagram adapted from Myers et al. (11).

megalocytic hepatitis and the hepatic neoplasms also suggests that these lesions are sufficiently separated in the temporal sequence of lesion progression that they tend not to co-occur.

In summary, this analysis strongly suggests that the co-occurring lesion types observed in English sole from polluted areas of Puget Sound comprise a temporal sequence of lesions progressing toward hepatic neoplasms that parallels the same process in experimental mouse and rat hepatocarcinogenesis. These results are the first confirmation, in any wild vertebrate population exposed to hepatotoxins and carcinogens in the environment, of the experimentally derived histogenesis of chemically induced hepatic neoplasia (11). This evidence also indirectly suggests that xenobiotic chemical hepatotoxicants and carcinogens in the environment may be the inducers of these lesions in English sole liver.

This model also strongly indicates the need to consider hepatic lesion types other than neoplasms as indicators of effects of contaminant exposure when conducting fish liver histopathology monitoring studies, especially when individuals of the target species are young juveniles (0+ or 1+, age in years). Results from recently completed field studies on bioindicators of contaminant exposure in juveniles of three flatfish species (English sole, rock sole, and starry flounder) from Puget Sound further indicate that the hepatic lesion types megalocytic hepatitis/nuclear pleomorphism and foci of cellular alteration are reliable indicators of exposure to hepatotoxic and hepatocarcinogenic compounds, especially in the two former species (Myers, unpublished observations).

## Statistical Associations among Liver Lesions and Indices of Contaminant Exposure

The results thus far presented support the hypothesis that liver lesions are the result of exposure to environmental contaminants

by virtue of the similarity of these lesions to lesions induced by experimental exposure to hepatotoxicants and carcinogens/and by the unique geographic distribution of these conditions among the sampling sites in Puget Sound. Idiopathic hepatic lesions are detected primarily in fish from estuaries and embayments in close proximity to urban centers or major sources of chemical contamination (2-10,29). In a more direct approach to this issue we have documented several strong associations between these lesions and the presence of and exposure to certain chemical contaminants in the environment.

Positive statistical associations of these lesions with contaminant exposure have been demonstrated by comparing lesion prevalences with actual concentrations of aromatic hydrocarbon contaminants in sediment by the Spearman's rank correlation method. Using this approach, we have shown significant correlations between overall idiopathic liver lesion prevalence in fish and concentrations of summed aromatic hydrocarbons (AHs) in sediment (2). This same association has subsequently been established between hepatic neoplasms and summed AHs (2,6); foci of cellular alteration and summed AHs (30) (Table 2); and megalocytic hepatitis and summed AHs (30) (Table 2).

A fundamental tenet of analytical epidemiology maintains that, while the strength of a particular statistical association in one study is important in establishing a relationship, of perhaps greater importance is the consistency of that relationship among multiple studies of a similar type. Accordingly, we have demonstrated a consistently positive association between liver neoplasm prevalence and sediment-associated AHs across six separate field studies (30). A strong, consistent association of the same type also exists for megalocytic hepatitis and for foci of cellular alteration (Table 2).

We have also developed a logistic regression model (Fig. 2) that incorporates neoplasm prevalence, sediment contaminant levels, interactions among different classes of chemicals, and fish size (an indirect measure of fish age) from multiple studies in Puget Sound (30,31). These results further strengthen the hypothesized role of AHs in sediment as a major etiologic agent of liver neoplasms in English sole, as the variation in levels of chemicals in this group accounts for about 12% of the variation in prevalence of hepatic neoplasms, more than for any other identifiable contaminant group. The model also points out the significant positive influence of fish size (age), and to a lesser extent, PCB contamination on neoplasm prevalence. However, the fact that less than 35% of the variation in neoplasm prevalence can be explained by this model suggests the importance of other potential factors such as fish movement, unidentified chemicals, and metabolites that may be involved in the explanation of the variability in prevalence of these neoplasms. For example, it is estimated that we can currently and reliably identify only a fraction of the chemical contaminants present in sediments (U. Varanasi, personal communication).

We have also documented significant correlations between levels of fluorescent aromatic compounds (FACs) in bile of English sole [including metabolites of BaP, pyrene, fluorene, fluoranthene, dibenzofuran, and phenanthrene (32)] and prevalences of liver lesions in sole from multiple sampling sites (29,33). Although the positive correlation between these bile metabolites and neoplasms has received much attention, equally

**Table 2. Correlations between aromatic hydrocarbon concentrations in sediment and the occurrence of hepatic neoplasms, putative preneoplastic lesions, and megalocytic hepatitis.<sup>a</sup>**

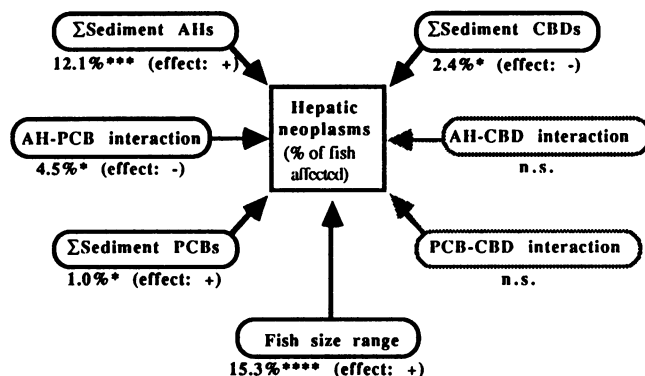
Study	Period	Number of stations	Number of fish examined	$r_s$ (significance)		
				Hepatic neoplasms <sup>b</sup>	Prenoplastic lesions	Megalocytic hepatitis
1	1979–80	31	1823	0.48 (0.003)	0.47 (0.004)	0.54 (0.001)
2	1982	4	200	0.60 (0.200)	0.00 (0.500)	0.80 (0.100)
3	1983	2	66	1.00 (0.500)	1.00 (0.500)	1.00 (0.500)
4	1983–84	11	229	0.35 (0.148)	0.00 (0.500)	0.36 (0.136)
5	1984	4	74	1.00 (0.001)	0.80 (0.100)	0.80 (0.100)
6	1984	9	265	0.54 (0.065)	0.54 (0.065)	0.23 (0.273)
Number of studies in agreement				6	6	6
Fisher's combined probability statistic				39.296	25.274	30.999
Degrees of freedom				12	12	12
Adjusted significance level				0.013	0.013	0.013
Significance <sup>c</sup>				0.0001*	0.014	0.002*

<sup>a</sup>The adjusted significance level takes into account the number of individual statistical tests performed.

<sup>b</sup>Correlation coefficient from the Spearman rank correlation method.

<sup>c</sup>From Fisher's combined probability test.

\*Indicates significance was below the critical value (adjusted significance level).



**FIGURE 2.** Model summarizing logistic regression analyses relating sediment concentrations of aromatic hydrocarbons (AHs), polychlorinated biphenyls (PCBs), and chlorinated butadienes (CBDs) to prevalences of liver neoplasms in English sole on Puget Sound. The model [AHs + PCBs + fish size – CBDs – (AH + PCB interaction)] accounts for 35.3% of observed variation in neoplasm prevalence. (%) Percentage variation in neoplasm prevalence explained; (n.s.) effect not significant ( $p > 0.05$ ); (\*) effect significant ( $p \leq 0.01$ ); (\*\*) effect significant ( $p \leq 0.001$ ); (\*\*\*\*) effect significant ( $p \leq 0.00001$ ). An earlier version of this model has been previously published (6).

strong correlations exist between these metabolites and prevalences of megalocytic hepatitis and foci of cellular alteration (Table 3). This is apparently due to the fact that the associations shown among the lesion types and metabolite levels are not truly direct. Bile metabolite levels simply provide a more direct measure than sediment contaminants of recent exposure to PAHs, and are not a direct reflection or predictor of the presence of lesions. Furthermore, no evidence exists to suggest that differences

in FAC levels result from alterations in PAH metabolism, bile production, or other biliary function caused by the presence of hepatic lesions. For example, within a site, bile metabolite levels in sole with or without lesions are generally not significantly different, regardless of lesion type considered (30).

**Table 3. Spearman's rank correlation coefficients  $r_s$  and significance levels for prevalences of hepatic lesions and mean concentrations of bile metabolites measured at benzo(a)pyrene wavelengths in English sole from sites in Puget Sound.<sup>a</sup>**

Lesion type	$r_s$	Significance level
Neoplasms	0.853	< 0.002
Foci of cellular alteration	0.773	< 0.01
Megalocytic hepatitis	0.891	< 0.001
Steatosis/hemosiderosis	0.409	< 0.5 (not significant)

<sup>a</sup>Adapted from Krahn et al. (29).

**Table 4. Calculated odds ratios of significant ( $p < 0.05$ ) risk factors for four categories of idiopathic hepatic lesions.<sup>a</sup>**

Lesion type	Risk factor	Odds ratio
Neoplasms	Upper Duwamish Waterway	8.7
	Lower Duwamish Waterway	8.2
	Age	1.6
Foci of cellular alteration	Upper Duwamish Waterway	4.2
	Lower Duwamish Waterway	2.4
	Age	1.4
Nuclear pleomorphism/megalocytic hepatitis	Upper Duwamish Waterway	4.9
	Lower Duwamish Waterway	3.4
	North Seattle Waterfront	4.0
	South Seattle Waterfront	2.7
Steatosis/hemosiderosis	Upper Duwamish Waterway	2.9
	Age	1.4
	Winter season	0.0001

<sup>a</sup>Odds ratios for the site of collection are interpreted relative to the reference site of Port Madison. Odds ratios for age represent the effect of each additional year of age on the odds of lesion occurrence. Adapted from Rhodes et al. (10).

Consequently, bile FACs levels are interpreted as being linked to lesion prevalences only by virtue of their nature as indicators of recent contaminant exposure, uptake, and metabolism; they do not reliably predict the presence of specific hepatic lesions in individual fish.

Additional support for the hypothesis of a chemical contaminant etiology for hepatic lesions in wild English sole is derived from an epidemiologic analysis of a multiyear study (1979–1984) investigating the significance of potential risk factors associated with lesion prevalences in English sole, including age, gender, and site, season, and year of capture (10). Table 4 summarizes the important pertinent results of this study, showing odds ratios for particular risk factors as applied to the major lesion categories. Certain risk factors inherent to the Duwamish Waterway (e.g., xenobiotic contaminants) significantly influence the prevalence of not only neoplasms, but also of preneoplastic foci of cellular alteration, and the related degenerative conditions of nuclear pleomorphism and megalocytic hepatitis. Other less contaminated urban sites (2) in Elliott Bay (N. Seattle waterfront, S. Seattle waterfront) show elevated odds ratios only for nuclear pleomorphism and megalocytic hepatitis. Fish age is also shown as a significant risk factor for all lesion categories with the exception of the latter two lesion types. In summary, the results of this epizootiologic study demonstrate the lack of influence of fish gender on the probability of hepatic lesion development; the relative insignificance of season or year of capture as significant factors for most of the lesion types; the positive influence of fish age and implied increased time of exposure to chemical contaminants on the probability of developing preneoplastic and neoplastic hepatic lesions; the earliest age at which sole become affected with specific lesions; and the significantly increased risk of being affected with certain lesions for sole from chemically contaminated areas of Puget Sound.

## Chemical Induction of Idiopathic Hepatic Lesions in English Sole

The types of evidence discussed earlier supporting a xenobiotic chemical etiology for neoplasms and other associated liver lesions in English sole rely mainly on demonstrating statistical correlations and associations and are not generally interpreted as proof of a direct cause-and-effect relationship. We have recently addressed this question directly by conducting a series of long-term laboratory exposure studies with English sole, in which sole were injected with a PAH-enriched fraction of an extract from a contaminated sediment, or a model hepatocarcinogen (BaP), with appropriate controls (31,34). To briefly summarize this work, only injection of an extract from Eagle Harbor and the model hepatocarcinogen, BaP, induced high incidences of the unique hepatotoxic lesions, nuclear pleomorphism (up to 83%) and megalocytic hepatitis (up to 60%), and associated degenerative lesions. The most important result of this study was the induction, again only in the exposure groups mentioned above, of basophilic foci of cellular alteration. This lesion type is an essentially proven preneoplastic lesion in rodent hepatocarcinogenesis models, is thought to be the immediate precursor of hepatic neoplasms in these models, and is

considered a microcarcinoma in the model for rainbow trout. All of these lesion types were induced within 18 months after the initial exposure. The results from this laboratory exposure study directly implicate certain chemical contaminants in the sediments, especially PAHs, as the agents of hepatocellular nuclear pleomorphism/megalocytic hepatitis, regeneration, preneoplastic foci of cellular alteration, and, at least by association, hepatic neoplasms in English sole from Puget Sound.

## Levels of PAHs in Liver Tissue of English Sole from Puget Sound

A comprehensive study specifically investigating the relationship between the presence or absence of specific liver lesions and levels of PAHs in liver tissue of the same English sole has yet to be conducted. The premise for this type of study rests on the hypothesis that lesion presence is a predictor of tissue burdens of PAHs. The primary reason such studies have not been done is due to the well-known fact that fish effectively metabolize parent PAHs (35) to compounds that are not detectable by routine methods. For this reason, metabolites of PAHs measured as FACs are routinely assayed in the bile of English sole, and the relationship between prevalences of hepatic lesions and FACs levels has been discussed previously. PAH levels in liver tissue that have been reported are typically very low, quite variable within a species at a particular site, and no clear relationship between the presence of liver lesions and levels of PAHs in liver tissue from the same fish has been established. For example, earlier studies in Puget Sound (2) showed that the concentration of individual AHs in liver tissue of English sole was usually below or close to the limit of detection for samples from either the polluted sites of Hylebos Waterway (Commencement Bay) and the Duwamish Waterway (Elliott Bay), or the nonurban reference sites of Case Inlet and Port Madison. However, in a limited number of English and rock sole liver samples analyzed, PAHs were detected in some samples, with the most commonly detected compounds being benzothiophene, dibenzothiophene, pyrene, and chrysene (8). However, because of the extensive metabolism of PAHs in the teleost liver (35), the level(s) of parent compounds in this organ is not considered a reliable measure of PAH exposure. The quantitation of levels of genotoxic compounds (including metabolites of PAHs) covalently bound as adducts to hepatic DNA of English sole and other species (36) may eventually prove to be a reliable hepatic indicator of exposure to genotoxic PAHs.

## Levels of PAHs in Muscle of English Sole from Puget Sound

Although the results of our field and laboratory research strongly indicate that sediment-associated PAHs can be an etiologic agent of the hepatic lesions seen in wild English sole, a direct extrapolation of these findings to a presumed human health risk from consumption of muscle from these same fish cannot yet be made, primarily because of the paucity of reliable data on levels of PAHs and/or their metabolites in edible flesh of English sole (37–40).

**Table 5. Prevalences of idiopathic liver lesion types in white croaker from sampling stations in the Los Angeles vicinity.**

Sampling station	Lesion type <sup>a</sup>						n
	MH/NP	EF/BF	LCA	HC	CC/CA	HN	
Dana Point (reference)	3.4	0	0	0	0	0	116
Queensway Bay/Long Beach	4.2	1.7	0	0	2.5	2.5	120
Cerritos Channel	40.0 <sup>†</sup>	2.0	2.0	0	0	2.0	50
Reservation Point/San Pedro	13.9 <sup>†</sup>	0.9	0	0.9	1.7	2.6	115
outer harbor	0	0	0	0	5.9*	5.9*	34
Hyperion/Santa Monica Bay							
White Point	0	0	0	0	0	0	25
Seal Beach	0	0	0	0	0	0	29
San Pedro Canyon	0	0	0	0	0	0	27

<sup>a</sup>Lesion types: MH/NP, megalocytic hepatitis/nuclear pleomorphism; EF/BF, eosinophilic focus/basophilic focus; LCA, liver cell adenoma; HC, hepatocellular carcinoma; CC/CA, cholangiocellular carcinoma/cholangioma; HN, hepatic neoplasm.

\*Significantly higher than prevalence at reference site by Fisher's exact test,  $p \leq 0.05$ .

<sup>†</sup>Significantly higher than prevalence at reference site by Fisher's exact test,  $p \leq 0.005$ .

**Table 6. Concentrations of aromatic and chlorinated compounds (ng/g dry weight) in sediment and livers of white croaker from the vicinity of Los Angeles and a reference area, Dana Point (4).**

Site	AHs		DDTs		PCBs	
	Sediment	Liver	Sediment	Liver	Sediment	Liver
Queensway Bay	2800	— <sup>a</sup>	100	41,000	460	13,000
Cerritos Channel	890	—	31	24,000	170	23,000
Reservation Point	1700	—	51	22,000	150	5,300
White Point	560	—	1300	100,000	520	7,500
Hyperion	370	—	120	6,600	320	4,100
Dana Point	54	—	2	1,500	6	900

<sup>a</sup>AH levels were not measured in liver.

**Table 7. Concentration of metabolites of aromatic compounds, measured at benzo(a)pyrene and naphthalene wavelengths, in bile of white croaker from the vicinity of Los Angeles (4).**

Site	Equivalents, mean $\pm$ SD, ng/g (wet weight)	
	Benzo(a)pyrene	Naphthalene
Queensway Bay	330 $\pm$ 160	140,000 $\pm$ 52,000
Cerritos Channel	5500 $\pm$ 1200	330,000 $\pm$ 100,000
Reservation Point	3700 $\pm$ 3100	410,000 $\pm$ 230,000
White Point	960 $\pm$ 1600	170,000 $\pm$ 61,000
Hyperion	78 $\pm$ 25	64,000 $\pm$ 47,000
Dana Point	79 $\pm$ 75	39,000 $\pm$ 13,000

## Prevalences of Idiopathic Hepatic Lesions in White Croaker from the Los Angeles Vicinity

Turning our attention to the marine waters adjacent to the Los Angeles area, white croaker (*Genyonemus lineatus*) from several sites in this area are affected with idiopathic hepatic lesions (4) that are similar to those seen in English sole from Puget Sound. However, the prevalences of these conditions are much lower in white croaker. Table 5 summarizes these data for some of the more important lesion types, showing a high prevalence of megalocytic hepatitis/nuclear pleomorphism (MH/NP) at Cerritos Channel and Reservation Point and lower prevalences of either the putatively preneoplastic focal lesions [eosinophilic foci/basophilic foci (EF/BF)] or hepatic neoplasms at Cerritos Channel, Queensway Bay, Reservation Point, and the Hyperion sewage outfall. Most of the detected neoplasms were tumors of the intrahepatic biliary elements. Although the evidence linking these lesions to exposure to chemical contaminants is far less conclusive than in the situation for English sole from Puget

Sound, the lesions in white croaker were generally found at sites with more contaminated sediments, especially those with high levels of PAHs (Table 6). However, lesion prevalences among the sites, especially for the neoplasms and focal lesions, were low and generally not statistically distinguishable (Table 5). In general, the sites showing highest levels of BaP-like metabolites in croaker bile (Table 7) were also sites exhibiting non-zero prevalences of hepatic focal lesions, neoplasms, or megalocytic hepatitis (Table 5).

The etiology of liver lesions in white croaker from this area remains an open issue, and no strong associations between exposure to aromatic hydrocarbons and the presence of liver disease have been established to date. In response to the potential problem regarding human exposure to elevated chlorinated hydrocarbons in the flesh of white croaker and other sportfish from this area, a number of studies have addressed the issue of contaminant levels in edible flesh of white croaker (42–44). No study has yet been conducted specifically examining the relationship(s) between idiopathic hepatic lesion presence/absence and tissue burdens of chemical contaminants in white croaker. Recently, the state of California has been funding research on these potential health impacts of consumption of chemically contaminated fish (including white croaker) by sportfishermen. To our knowledge, this study has not been completed and no results have yet been released.

## Summary

Results from field and laboratory studies investigating the etiology of hepatic neoplasms and other lesions involved in hepatic neoplasia in English sole support a causal relationship between exposure to sediment-associated contaminants, primarily polycyclic aromatic hydrocarbons, and the development of these hepatic lesions. Major lines of evidence supporting this view are: a) construction of a model of the histogenesis of hepatic neoplasia in English sole that parallels the multistep neoplastic process demonstrated in experimental hepatocarcinogenesis models; b) the development of a logistic regression model that accounts for about 35% of the variation in neoplasm prevalence in wild English sole and attributes 12% of the total variation to levels of PAHs in sediment; c) the creation of a separate logistic regression model showing significant increases in the probability of most hepatic lesions occurring in sole from contaminated sites and in older fish exposed to contaminants for longer periods;



d) the demonstration of significant positive correlations between FACs levels in bile and prevalences of hepatic lesion types in wild English sole; and e) the experimental induction of unique hepatotoxic, regenerative, and putatively preneoplastic focal lesions in English sole by repeated and extended exposure to a model hepatotoxicant/hepatocarcinogen (BaP) or a PAH-enriched extract of a contaminated sediment from a site in Puget Sound.

Research on hepatic neoplasia in English sole has been greatly facilitated by the existence of a kind of natural laboratory in Puget Sound from which has been developed a strong epizootiological database that implicates xenobiotic contaminants in the etiology of neoplasms and other related hepatic lesions. This information has led us to certain hypotheses that have been tested and at least partially verified in experimental laboratory exposure studies. Consequently, our studies on hepatic neoplasia in English sole are not affected by the central problem inherent to other fish and rodent hepatocarcinogenesis models; namely, the inability to relate results of laboratory studies directly to those derived from observations in the environment.

However, regardless of the significant progress thus far achieved in elucidating aspects of the etiology of hepatic neoplasia in English sole, more research is certainly needed on the multiple genetic and epigenetic factors and the mechanisms that are operant in the process of hepatic neoplasia in this species. The fact that we can currently identify factors that account for only 35% of the variation in neoplasm prevalence in wild English sole in the logistic regression model points to the obvious need for further investigation into etiological factors not explicitly included in this model. These factors could include xenobiotic chemical agents not currently identifiable that may act as carcinogens, co-carcinogens or promoters, the role of these or other factors in activation of protooncogenes, etc. Greater knowledge of these additional influencing factors would contribute to a strengthening of the model we have partially developed, and would help guide further laboratory studies delineating the mechanisms comprising the multistep pathway of hepatocarcinogenesis in English sole that can be extrapolated to other fish species.

The issue of whether or not a human health risk exists due to consumption of English sole and other fish species affected by hepatic neoplasms and/or related lesions cannot be resolved from the types and amounts of evidence currently available. Although reported levels in muscle tissue of the xenobiotic chemicals (PAHs) shown to be important etiologic agents of hepatic neoplasia are very low or absent in this species, such data are fragmentary and often unreliable. Moreover, fish extensively metabolize PAHs (35); consequently, it must be a future goal to develop more sensitive and reliable methods for detection of these metabolites in fish muscle.

#### REFERENCES

- Pierce, K. V., McCain, B. B., and Wellings, S. R. Pathology of hepatomas and other abnormalities in English sole (*Parophrys vetulus*) from the Duwamish River Estuary, Seattle, Washington. *J. Natl. Cancer Inst.* 60: 1445-1453 (1978).
- Malins, D. C., McCain, B. B., Brown, D. W., Chan, S. L., Myers, M. S., Landahl, J. T., Prohaska, P. G., Friedman, A. J., Rhodes, L. D., Burrows, D. G., Gronlund, W. G., and Hodgins, H. O. Chemical pollutants in bottom-dwelling fish in Puget Sound, Washington. *Environ. Sci. Technol.* 18: 705-713 (1984).
- Malins, D. C., Krahn, M. M., Brown, D. W., Rhodes, L. D., Myers, M. S., McCain, B. B., and Chan, S. L. Toxic chemicals in marine sediment and biota from Mukilteo, Washington: relationships with hepatic neoplasms and other hepatic lesions in English sole (*Parophrys vetulus*). *J. Natl. Cancer Inst.* 74: 487-494 (1984).
- Malins, D. C., Krahn, M. M., Myers, M. S., Rhodes, L. D., Brown, D. W., Krone, C. A., McCain, B. B., and Chan, S. L. Toxic chemicals in sediments and biota from a creosote-polluted harbor: relationships with hepatic neoplasms and other hepatic lesions in English sole (*Parophrys vetulus*). *Carcinogenesis* 6: 1463-1469 (1985).
- Malins, D. C., McCain, B. B., Myers, M. S., Brown, D. W., Krahn, M. M., Roubal, W. T., Schiewe, M. H., Landahl, J. T., and Chan, S. L. Field and laboratory studies of the etiology of liver neoplasms in marine fish from Puget Sound. *Environ. Health Perspect.* 71: 5-16 (1987).
- Malins, D. C., McCain, B. B., Landahl, J. T., Myers, M. S., Krahn, M. M., Brown, D. W., Chan, S. L., and Roubal, W. T. Neoplastic and other diseases in fish in relation to toxic chemicals: an overview. *Aquat. Toxicol.* 11: 43-67 (1988).
- McCain, B. B., Brown, D. W., Krahn, M. M., Myers, M. S., Clark, R. C., Chan, S. L., and Malins, D. C. Marine pollution problems, North American West Coast. *Aquat. Toxicol.* 11: 143-162 (1988).
- Malins, D. C., McCain, B. B., Brown, D. W., Sparks, A. K., and Hodgins, H. O. Chemical contaminants and Biological Abnormalities in Central and Southern Puget Sound. NOAA Technical Memorandum, 1980, OMPA-2, National Oceanic and Atmospheric Administration, Boulder, CO.
- Malins, D. C., McCain, B. B., Brown, D. W., Sparks, A. K., Hodgins, H. O., and Chan, S. L. Chemical Contaminants and Abnormalities in fish and invertebrates from Puget Sound. NOAA Technical Memorandum, 1982, OMPA-19, National Oceanic and Atmospheric Administration, Boulder, CO.
- Rhodes, L. D., Myers, M. S., Gronlund, W. D., and McCain, B. B. Epizootic characteristics of hepatic and renal lesions in English sole, *Parophrys vetulus*, from Puget Sound. *J. Fish Biol.* 31: 395-407 (1987).
- Myers, M. S., Rhodes, L. D., and McCain, B. B. Pathologic anatomy and patterns of occurrence of hepatic neoplasms, putative preneoplastic lesions, and other idiopathic hepatic conditions in English sole (*Parophrys vetulus*) from Puget Sound, Washington. *J. Natl. Cancer Inst.* 78: 333-363 (1987).
- Myers, M. S., and Rhodes, L. D. Morphologic similarities and parallels in geographic distribution of suspected toxicopathic liver lesions in rock sole (*Lepidopsetta bilineata*), starry flounder (*Platichthys stellatus*), Pacific staghorn sculpin (*Leptocottus armatus*), and Dover sole (*Microstomus pacificus*) as compared to English sole (*Parophrys vetulus*) from urban and non-urban embayments in Puget Sound, Washington. *Aquat. Toxicol.* 11: 410-411 (1988).
- Tsuda, H., and Farber, E. Resistant hepatocytes as putative preneoplastic cells induced by carcinogenic polycyclic aromatic compounds. *Int. J. Cancer* 25: 137-139 (1980).
- Ying, T. S., Sarma, D. S. R., and Farber, E. Role of acute hepatic necrosis in the induction of early steps in liver carcinogenesis by diethylnitrosamine. *Cancer Res.* 41: 2096-2102 (1981).
- Columbano, A., Rajalakshmi, S., and Sarma, D. S. R. Requirement for cell proliferation for the initiation of liver carcinogenesis as assayed by three different procedures. *Cancer Res.* 41: 2079-2083 (1981).
- Solt, D. B., Medline, A., and Farber, E. Rapid emergence of carcinogen-induced hyperplastic lesions in a new model for the sequential analysis of liver carcinogenesis. *Am. J. Pathol.* 88: 595-618 (1977).
- Farber, E., and Sarma, D. S. R. Biology of disease—hepatocarcinogenesis: a dynamic cellular perspective. *Lab. Invest.* 56: 4-22 (1987).
- Farber, E., and Cameron, R. The sequential analysis of cancer development. *Adv. Cancer Res.* 31: 297-321 (1980).
- Williams, G. M. Phenotypic properties of preneoplastic rat liver lesions and applications to detection of carcinogens and tumor promoters. *Toxicol. Pathol.* 10: 3-10 (1982).
- Bannasch, P., Mayer, D., and Hecker, H. J. Hepatocellular glycogenosis and hepatocarcinogenesis. *Biochim. Biophys. Acta* 605: 217-245 (1980).
- Enzman, H., and Bannasch, P. Potential significance of phenotypic heterogeneity of focal lesions at different stages of hepatocarcinogenesis. *Carcinogenesis* 8: 1607-1612 (1987).
- Hendricks, J. D., Meyers, T. R., and Shelton, D. W. Histological progression of hepatic neoplasia in rainbow trout (*Salmo gairdneri*). *Natl. Cancer Inst. Monogr. Ser.* 65: 321-336 (1984).



23. Stehr, C. S., and Myers, M. S. The ultrastructure and histology of cholangiocellular carcinomas in English sole (*Parophrys vetulus*) from Puget Sound, Washington. *Toxicol. Pathol.*, in press.
24. Stehr, C. S., Rhodes, L. D., and Myers, M. S. The ultrastructure and histology of hepatocellular carcinomas of English sole (*Parophrys vetulus*) from Puget Sound, Washington. *Toxicol. Pathol.* 16: 418-431 (1988).
25. Couch, J. A., and Courtney, L. A. N-Nitrosodiethylamine-induced hepatocarcinogenesis in estuarine sheepshead minnow (*Cyprinodon variegatus*): neoplasms and related lesions compared with mammalian lesions. *J. Natl. Cancer Inst.* 79: 297-321 (1987).
26. Krone, C. A., Burrows, D. G., Brown, D. W., Robisch, P. A., Friedman, A. J., and Malins, D. C. Nitrogen-containing aromatic compounds in sediments from a polluted harbor in Puget Sound. *Environ. Sci. Technol.* 20: 1144-1150 (1986).
27. Bannasch, P. Preneoplastic lesions as end points in carcinogenicity testing. I. Hepatic preneoplasia. *Carcinogenesis* 7: 689-695 (1986).
28. Farber, E. Chemicals, evolution and cancer development. *Am. J. Pathol.* 108: 270-275 (1982).
29. Krahn, M. M., Rhodes, L. D., Myers, M. S., Moore, L. K., MacLeod, W. D., Jr., and Malins, D. C. Associations between metabolites of aromatic compounds in bile and the occurrence of hepatic lesions in English sole (*Parophrys vetulus*) from Puget Sound, Washington. *Arch. Environ. Contam. Toxicol.* 15: 61-67 (1986).
30. Myers, M. S., Landahl, J. T., Krahn, M. M., Johnson, L. L., Schiewe, M. S., and McCain, B. B. Studies on liver carcinogenesis in English sole from Puget Sound, Washington, USA: evidence for a xenobiotic chemical etiology. I. Pathology and epizootiology. *Sci. Tot. Environ.* 94: 33-50 (1990).
31. Schiewe, M. S., Landahl, J. T., Myers, M. S., Plesha, P. D., Jacques, F. J., Stein, J. S., McCain, B. B., Weber, D., Chan, S. L., and Varanasi, U. Relating field and laboratory studies: cause and effect research. Proceedings of the First Annual Meeting on Puget Sound Research, Vol. 1. Puget Sound Water Quality Authority, Seattle, WA, 1988, pp. 577-584.
32. Krahn, M. M., Burrows, D. G., MacLeod, W. D., Jr., and Malins, D. C. Determination of individual metabolites of aromatic compounds in hydrolyzed bile of English sole (*Parophrys vetulus*) from Puget Sound, Washington. *Arch. Environ. Contam. Toxicol.* 15: 61-67 (1987).
33. Krahn, M. M., Myers, M. S., Burrows, D. G., and Malins, D. C. Determination of metabolites of xenobiotics in bile of fish from polluted waterways. *Xenobiotica* 14: 633-646 (1984).
34. Schiewe, M. H., Weber, D. D., Myers, M. S., Jacques, F. J., Reichert, W. L., Krone, C. A., Malins, D. C., McCain, B. B., Chan, S. L., and Varanasi, U. Induction of foci of cellular alteration and other hepatic lesions in English sole (*Parophrys vetulus*) exposed to benzo(a)pyrene on an extract of an urban marine sediment. *Cancer Res.*, submitted.
35. Varanasi, U., Stein, J. E., and Nishimoto, M. Biotransformation and disposition of PAH in fish. In: *Metabolism of Polycyclic Aromatic Hydrocarbons in the Aquatic Environment* (U. Varanasi, Ed.), CRC Press, Boca Raton, FL, 1989 pp. 93-150.
36. Varanasi, U., Reichert, W. L., and Stein, J. E. <sup>32</sup>P-postlabeling analysis of DNA adducts in liver of wild English sole (*Parophrys vetulus*) and winter flounder (*Pseudopleuronectes americanus*). *Cancer Res.* 49: 1171-1177 (1989).
37. Landolt, M., Hafer, F., Nevissi, A., van Belle, G., Van Ness, K., and Rockwell, C. Potential Toxicant Exposure among Consumers of Recreationally Caught Fish from Urban Embayments of Puget Sound. NOAA Technical Memorandum, 1985, NOS OMA-23.
38. Landolt, M., Kalman, D., Nevissi, A., van Belle, G., Van Ness, K., and Hafer, F. Potential Toxicant Exposure among Consumers of Recreationally Caught Fish from Urban Embayments of Puget Sound: Final Report. NOAA Technical Memorandum, 1987, NOS OMA-33.
39. Assessment of Human Health Risk from Ingesting Fish and Crabs from Commencement Bay. Prepared by Versar, Inc., Springfield, VA, for J. Krull, Washington State Dept. of Ecology, Olympia, WA. Environmental Protection Agency, 910/9-85-129, 1985.
40. Health Risk Assessment of Chemical Contamination in Puget Sound Seafood, Final Report. Prepared by Tetra Tech, Inc. for US EPA, Region X-Office of Puget Sound, Seattle, WA. Environmental Protection Agency, 910/9-88-249, 1988.
41. Malins, D. C., McCain, B. B., Brown, D. W., Myers, M. S., Krahn, M. M., and Chan, S. L. Toxic chemical, including aromatic and chlorinated hydrocarbons and their derivatives, and liver lesions in white croaker (*Genyonemus lineatus*) from the vicinity of Los Angeles. *Environ. Sci. Technol.* 21: 765-770 (1987).
42. Gossett, R. W., Puffer, H. W., Arthur, R. H., Alfafara, J. F., and Young, D. R. Levels of trace organic compounds in sportfish from southern California. In: *Southern California Coastal Water Research Project, Biennial Report* (W. Bascom, Ed.), Southern California Coastal Water Research Project, Long Beach, CA, 1981-1982, pp. 29-37.
43. Gossett, R. W., Puffer, H. W., Arthur, R. H., and Young, D. R. DDT, PCB, and benzo(a)pyrene levels in white croaker (*Genyonemus lineatus*) from Southern California. *Mar. Pollut. Bull.* 14: 60-65 (1983).
44. Brown, D. A., Gossett, R. W., and Jenkins, K. D. Contaminants in white croakers *Genyonemus lineatus* (Ayres, 1855) from the southern California Bight: II. Chlorinated hydrocarbon detoxification/toxication. In: *Physiological Mechanisms of Pollutant Toxicity. Symposium on Pollution and Marine Organisms* (W. B. Vernberg, A. Calabrese, F. P. Thurberg, and F. J. Vernberg, Eds.), Academic Press, New York, 1982, pp. 197-214.