

Hypothalamic and pituitary injury

C. S. TREIP

Cambridge

The hypothalamic-pituitary axis is recognized to an increasing extent as a physiological unit which influences and is influenced by endocrine and autonomic function. Anatomically, however, a clear distinction is to be drawn, with regard to both cellular and vascular anatomy, between the neural (hypothalamus and neurohypophysis) and the glandular epithelial (pars distalis) components of the axis. The anatomical situation of lesions which may cause physiological disturbances of the hypothalamic-pituitary axis has to be considered, as it appears in some cases at least that a precise location may be required to disrupt the physiological integrity of the axis. Despite present-day refinements of biochemical diagnosis, the final word regarding the correlation of clinical findings with anatomical lesions still rests with the histopathologist. In the present paper the infundibulum is considered with the hypothalamus and the pituitary stalk and neurohypophysis with the pituitary gland, for although these structures form an anatomical continuum the interposition of the diaphragma sellae between the infundibulum and neurohypophysis results in the development of different lesions in these two areas after head injury.

The effects of trauma on the hypothalamic-pituitary axis have been observed and recorded for nearly a century, one of the oldest observations being that of Kahler (1886), who reported polyuria following a basal fracture which ran through the pituitary fossa. Most of the reports, however, have been clinical, without pathological correlation. The few published pathological reports have been concerned mainly with the changes in the pituitary gland in long survivors (for references see Daniel and Treip, 1961 and 1966a). Even fewer descriptions of post-traumatic hypothalamic changes are available (Vonderahe, 1940; Henzi, 1952; Goldman and Jacobs, 1960; Orthner and Meyer, 1967).

Hypothalamic Lesions

The lesions described in this paper are based on a personal series of 15 cases of fatal head injury, surviving from three to over 300 days, in which serial histological sections of the hypothalamus were examined. The lesions may for convenience be divided into four anatomical groups: (1) lesions of the supraoptic and paraventricular nuclei; (2) lesions of the infundibulum; (3) lesions in and around the third ventricle; and (4) lesions of the mamillary bodies. Lesions of all four areas are commonly found in one brain and sometimes in association with pituitary lesions; not infrequently, however, the pituitary gland is histologically intact. Injury of the brain elsewhere is almost always present (Vonderahe, 1940) and fracture of the base of the skull is often, but not invariably, found.

THE SUPRAOPTIC AND PARAVENTRICULAR NUCLEI

The supraoptic nucleus is the most vulnerable area of the hypothalamus and haemorrhages of varying size, mostly petechial, were present in one or both nuclei in nearly every one of the acutely injured patients (dying within 30 days of injury). Acute neuronal damage, such as pyknosis, is rare; central chromatolysis is difficult to assess with certainty (Daniel, 1966). Acute cell loss is also uncommon, but may be seen if there is direct injury to the nucleus; such injury is seen when there is tearing or distortion of the optic chiasma or of the optic tracts (Figs. 1 and 2). Neurosecretory material persists in the damaged nucleus, but may be diminished in amount. Abscess formation and infarction within the nucleus may be seen if there is meningitis or extensive haemorrhage nearby. Cell loss resulting from retrograde atrophy is seen in long

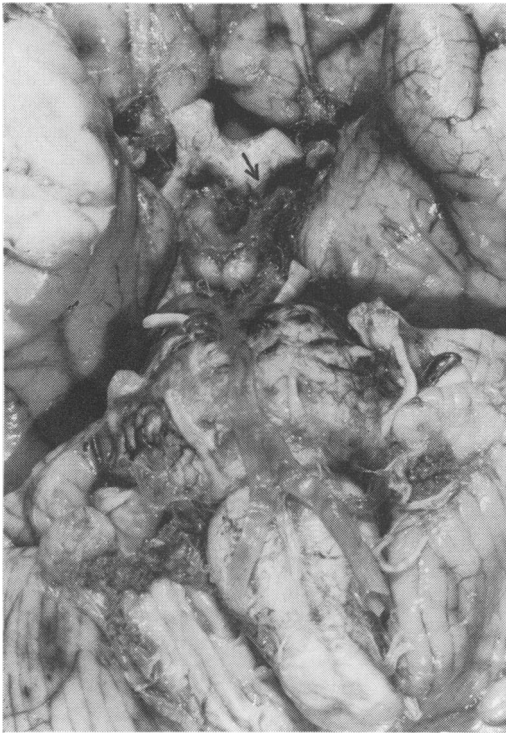


Fig. 1 Male, aged 17 years. Survived three days. Base of brain, showing tearing of left optic tract (arrow), with chiasmal distortion. The stump of the (transected) pituitary stalk is haemorrhagic $\times 1.5$.

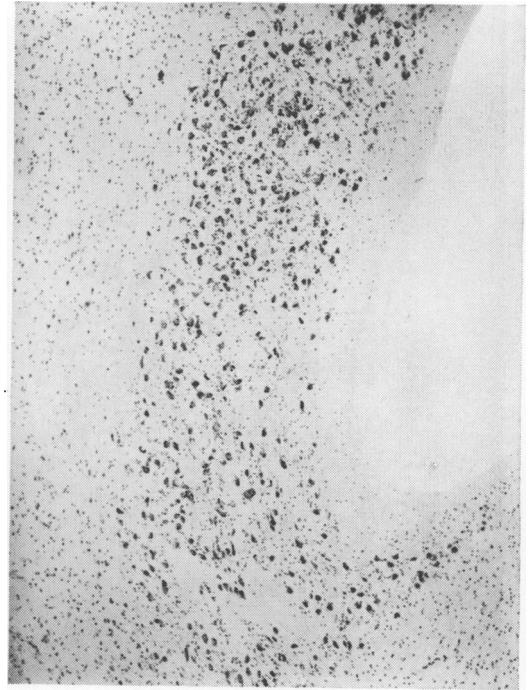


Fig. 3a Normal supraoptic nucleus. Nissl $\times 40$.

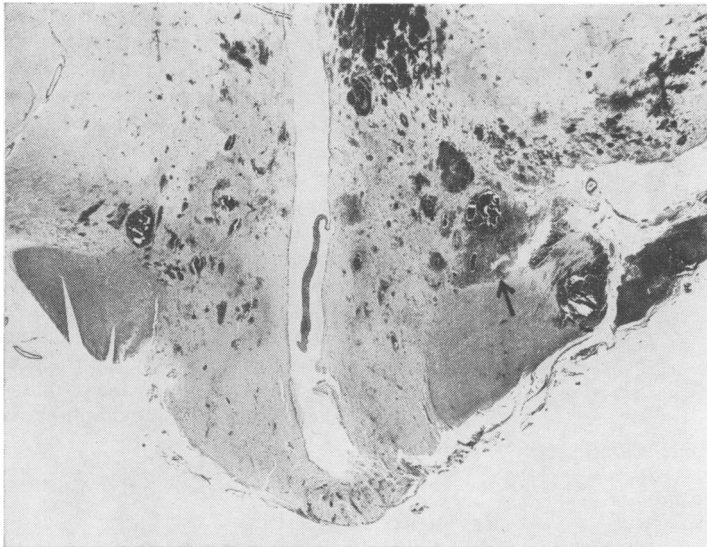

Fig. 2 Same case as in Figure 1. Coronal section through hypothalamus to show tearing of left optic tract and supraoptic nucleus (arrow), which contain recent haemorrhages (on right of figure). Haemorrhages are also present in the periventricular region and right supraoptic nucleus. Luxol fast blue/cresyl violet $\times 5$.

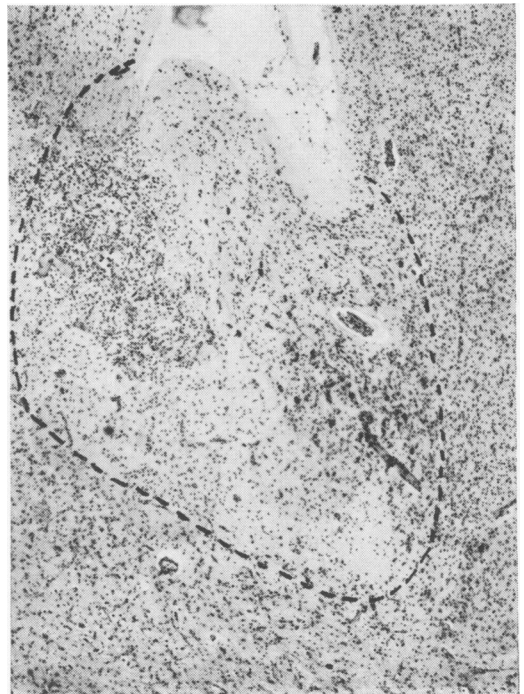


Fig. 3b Male, aged 23 years. Survived 10 months. The supraoptic nucleus (within dotted line) contains very few neurons and is partly replaced superiorly by an infarct containing many macrophages. Nissl $\times 40$.

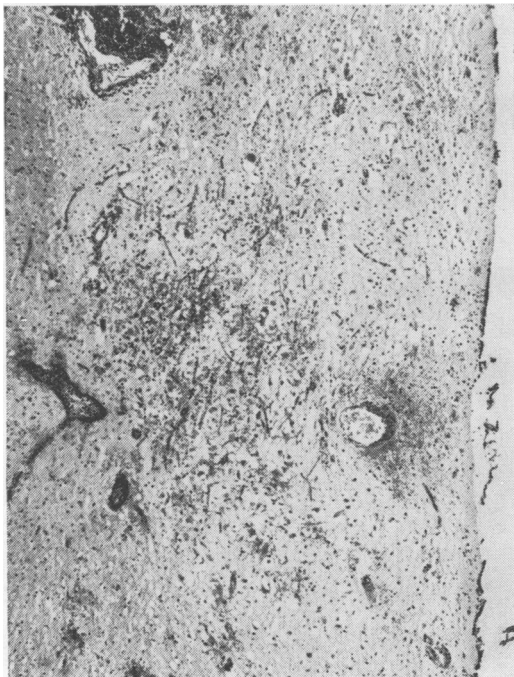

Fig. 4 Same case as in Figure 1. Haemorrhages and oedema within the paraventricular nucleus. Haematoxylin and eosin. $\times 40$.

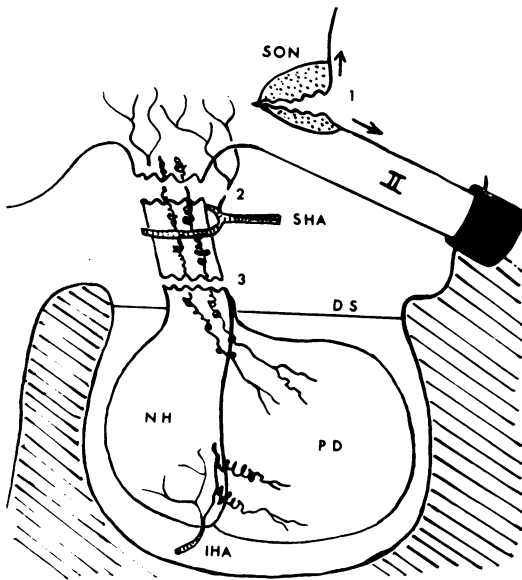


Fig. 5 Diagram to illustrate possible mechanisms of hypothalamic and pituitary damage. (1) Dural tethering of the optic nerve at the optic foramen results in tearing of the supraoptic nucleus with sudden movements of the brain. (2) High transection of the pituitary stalk results in rupture of the tuberal and infundibular vessels, the portal vessels to the pars distalis escaping injury. (3) Low stalk transection results in rupture of the long portal vessels to the pars distalis. II = optic nerve. DS = diaphragma sellae. IHA = inferior hypophysial artery. NH = neurohypophysis. PD = pars distalis. SHA = superior hypophysial artery. SON = supraoptic nucleus.

survivors (Fig. 3a and b) (Henzi, 1952; Goldman, and Jacobs, 1960). The atrophy is a slow process and may not be apparent for weeks or months (Orthner and Meyer, 1967). Similar changes, of a less conspicuous nature, are found in the paraventricular nucleus, with the exception of direct tears, which are not seen. The paraventricular nucleus sometimes shows a striking looseness of texture, possibly oedema, associated with petechial haemorrhages (Fig. 4).

The vulnerability of the supraoptic nucleus to injury may perhaps be explained in the following way. The optic nerve is tethered rostrally at the optic foramen by the dural sheath which closely invests it. Caudally it forms with the lamina terminalis an angle within which the superior portion of the supraoptic nucleus lies, separated from the surface by a thin layer of neuropil. As one side of the angle is fixed, sudden movements of the brain such as occur with trauma, could readily result in abrupt changes of the angle and tearing or compression of the supraoptic nucleus (Fig. 5). The rich supply of thin-walled blood vessels to this nucleus (Daniel, 1966) accounts for its predisposition to haemorrhage.

THE INFUNDIBULAR REGION

Infarction is the commonest lesion in the infundibulum, taking the form of small areas of necrosis, usually in the midline of the tuber cinereum or upper infundibular stem (Fig. 6). Characteristic of these infarcts are the pooling of neurosecretory material around their periphery and the presence of axonal swellings adjacent to them (Orthner and Meyer, 1967). Similar accumulations of neurosecretory material and axonal swellings are seen after experimental section of the pituitary stalk (Beck and Daniel, 1961). Linear and petechial haemorrhages are also seen in this region, where they are in a position to interrupt the supraoptico-hypophysial tract. Scarring of the infundibulum was seen in one long-surviving patient (Fig. 7). Haemorrhages into the ventromedial nuclei may occur and, occasionally, bilateral infarction of these nuclei is seen (Fig. 8). The vulnerability of the lower infundibulum may to some extent be explained by the traction exerted on it and its blood vessels by the pituitary stalk, which is tethered below by the diaphragma sellae (Fig. 5).

THE THIRD VENTRICLE

Subependymal haemorrhages around the third ventricle are of common occurrence and may impinge upon the paraventricular nuclei. Haemorrhages and infarcts in the floor of the ventricle merge with infundibular lesions. Purulent ventriculitis may occur as a consequence of skull fractures. In long survivors a granular ependymitis may develop, with a macrophage (sidero-

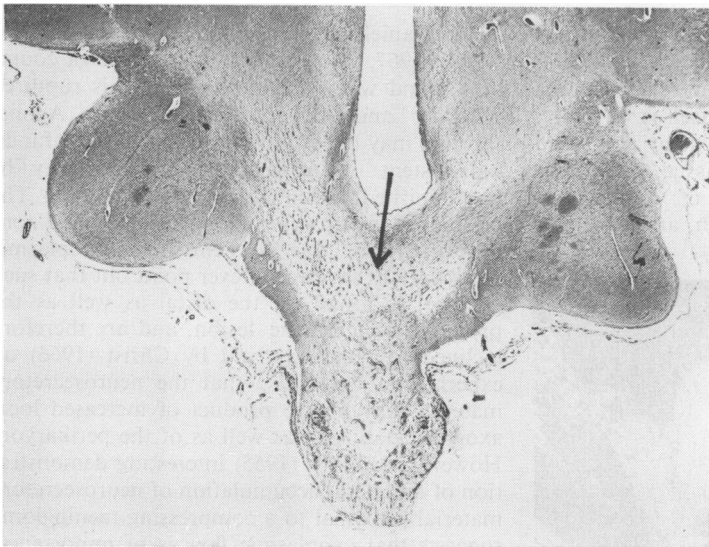


Fig. 6.

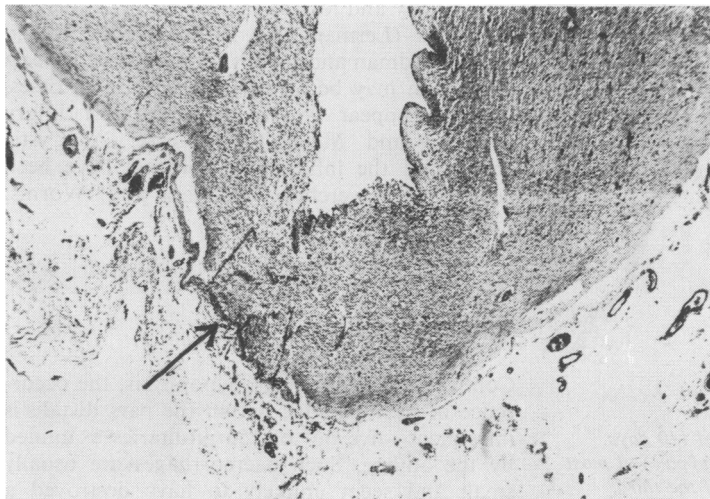


Fig. 7.

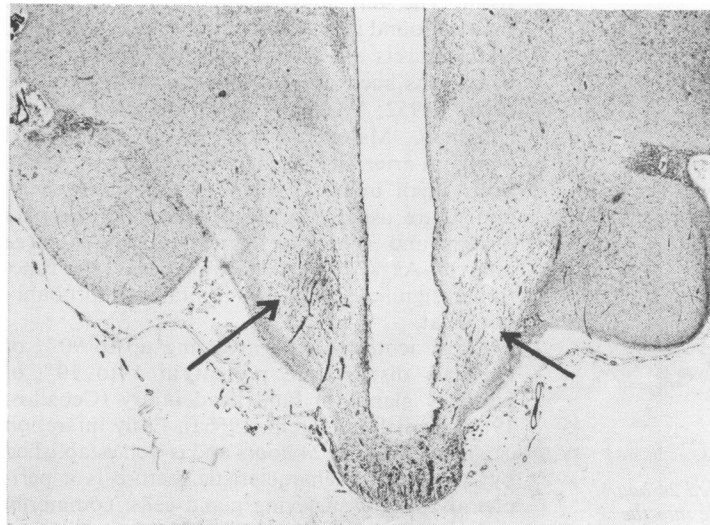


Fig. 8.

Fig. 6 *Male, aged 41 years. Survived 27 days; severe hypernatraemia. Acute infundibular infarction immediately above pituitary stalk (arrow). Haematoxylin and eosin $\times 6$.*

Fig. 7 *Male, aged 23 years. Survived 10 months. Diabetes insipidus for one month. One side of the infundibulum (tuber) is scarred and puckered (arrow). Nissl $\times 6$.*

Fig. 8 *Same case as in Figure 6. Bilateral acute infarction of the ventromedial nuclei (arrows). Haematoxylin and eosin $\times 6$.*

phore) reaction to intraventricular haemorrhage and marginal gliosis. The readiness with which ependyma reacts to damage was noted by Russell (1949).

THE MAMILLARY BODIES

Petechial and larger haemorrhages, which may occupy half of the medial mamillary nucleus, are not uncommonly found in association with lesions elsewhere in the hypothalamus. Infarcts occur less frequently and gliosis and loss of neurones may be seen in longstanding cases.

Elsewhere in the hypothalamus infarction of the lateral hypothalamic area may be seen when there are extensive haemorrhages or infarction involving structures nearer the midline (Fig. 9).

Pituitary Lesions

Scattered pathological reports of traumatic pituitary damage were reviewed by Daniel and Treip (1961 and 1966a). Larger series have been studied by Ceballos (1966—102 cases) and by Daniel and Treip (1966a—156 cases). Orthner and Meyer (1967) review much of the relevant literature with particular reference to diabetes insipidus. In the present account the pituitary is divided anatomically into the neurohypophysis, comprising the upper and lower infundibular stem (upper and lower stalk) and infundibular process (posterior lobe) and the pars distalis (anterior lobe).

THE NEUROHYPOPHYSIS

The commonest finding (70 out of 156 cases) in the infundibular stem and process was acute haemorrhage, often petechial, but sometimes (20 cases) large enough to cause appreciable damage to the infundibular process (Fig. 10). The possible clinical significance of this lesion will be discussed later. Infarction of the infundibular stem was not found by Daniel and Treip (1966a), but was found in six cases by Ceballos (1966); as the anatomical distinction between

infundibulum and upper infundibular stem is difficult to make, the difference between the two series may be more apparent than real. Necrosis within the infundibular process itself is very rare. Denervation changes are shown by increased cellular density of the neural tissue, sometimes associated with the presence of argyrophilic retraction bulbs (Daniel, Duchon, and Prichard,

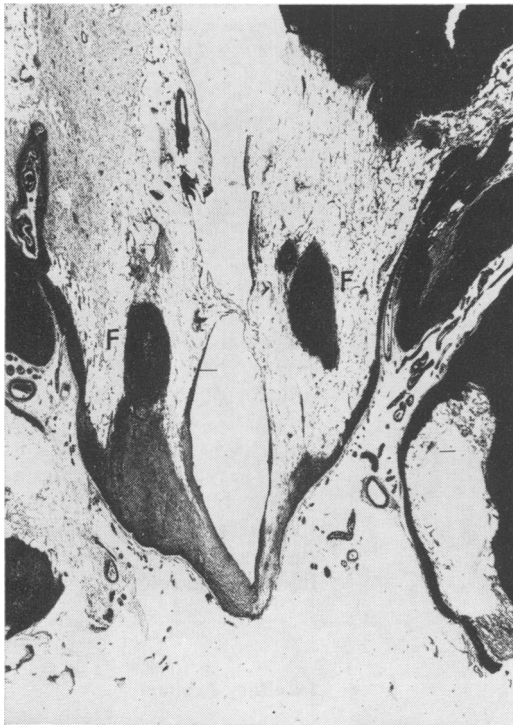

Fig. 9 Male, aged 65 years. Survived 110 days. Persistent hypothermia. Old infarction (pale) of most of hypothalamus, including the wall of the third ventricle, but sparing the fornices (F). Loyez $\times 5.5$.

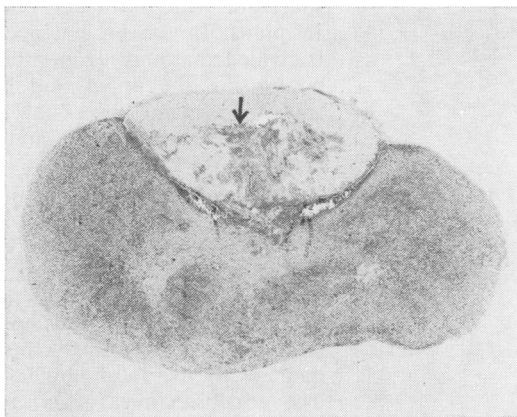


Fig. 10 Male, aged 20 years. Survived 24 hours. Acute, moderately severe haemorrhage into the neurohypophysis (arrow). Normal pars distalis. Haematoxylin and eosin $\times 7$.

1964; Daniel and Prichard, 1966; Orthner and Meyer, 1967, case 3). Such changes are of course also found when the pituitary stalk is ruptured (Orthner and Meyer, 1967, case 3). Agonal thrombi may be seen in the vessels of the infundibular stem. Neurosecretory material may be undiminished (Orthner and Meyer, 1967). The pooling of neurosecretory material around torn fibres may be due to centrifugal axoplasmic flow, but Orthner and Meyer point out that such material is found on the distal as well as the proximal side of the lesion, and are therefore inclined to the view, held by Christ (1966) on experimental grounds, that the neurosecretory material may be the product of increased local axonal metabolism as well as of the perikaryon. However, Müller's (1955) interesting demonstration of unilateral accumulation of neurosecretory material proximal to a compressing meningioma suggests that axoplasmic flow is of importance.

Chronic changes seen in the neurohypophysis are atrophy and loss of cellular elements such as pituicytes (Lerman and Means, 1945; Henzi, 1952; Goldman and Jacobs, 1960). Haemosiderin deposition may be found in longstanding cases, but can appear within eight days of injury (Orthner and Meyer, 1967, case 3). Cystic changes in the infundibular process have been described (Reverchon, Delater, and Worms, 1923; Marañón, 1926).

THE PARS DISTALIS

Compared with the neurohypophysis, the occurrence of haemorrhage within the pars distalis is infrequent—five out of 156 pituitaries examined by the author. Such haemorrhages are usually small and seem unlikely to have destroyed a significant amount of functioning glandular tissue. The same may be said of the small recent infarcts found in a similar number (six) of glands. Such infarcts are not infrequently seen in other conditions such as raised intracranial pressure (Plaut, 1952; Wolman, 1956), diabetes mellitus (Brennan, Malone, and Weaver, 1956), and temporal arteritis (Sheehan and Summers, 1949). Such small infarcts, when they occur in head injury, are usually in the periphery of the pars distalis and show the same features as large infarcts. As with small haemorrhages, the functional significance of small infarcts is probably not great.

Large acute infarcts, involving up to 90% of the pars distalis, are present in 5 to 10% of pituitary glands in fatal head injury (Ceballos, 1966; Daniel and Treip, 1966a). Early infarction can be seen within 24 hours and is well established by 36 hours. A characteristic feature is a peripheral zone of surviving gland cells, commonly at its widest adjacent to the infundibular process (Fig. 11). The infarcted area consists of amor-

phous cell debris, necrotic blood vessels, pyknotic nuclei, and epithelial ghost cells. An inflammatory reaction around the infarcted area is not normally seen, but there is sometimes capillary engorgement. The picture resembles that seen after surgical transection of the stalk (Adams, Daniel, and Prichard, 1966) or in postpartum pituitary necrosis (Sheehan, 1937). The essential mechanism of infarction is thought to be an interruption of the portal blood supply running down the stalk to the pars distalis, as a result of stretching or transection of the stalk, by analogy with surgical and experimental findings (Adams *et al*, 1966; Daniel and Prichard, 1957 and 1958). Confinement of the pituitary within the sella turcica by the diaphragma sellae makes the stalk as well as the infundibulum especially vulnerable to shearing strains (Kornblum and Fisher, 1969). Orthner and Meyer (1967), however, consider the infarct to be the result of shock following trauma, combined with anoxia, a state of affairs similar to Sheehan's postpartum infarction; as evidence they adduce the occurrence of infarction with an intact pituitary stalk in their cases 1 and 2. Whatever the mechanism of vascular damage may be, the final cause of infarction is a deprivation of oxygen to the pars distalis, be it the result of mechanical interruption or damage of the portal vessels, or of slowing or arrest of blood flow in these vessels which form a low-pressure (and therefore, relatively vulnerable) end circulation. The absence of infarcts in the neurohypophysis, which has an independent and arterial supply, would appear to support the argument. Of interest are those cases in which there is clear evidence of traumatic rupture of the pituitary stalk, with an intact pars distalis (Daniel, Prichard, and Treip, 1959, case 6; Orthner and Meyer, 1967, case 3). Daniel *et al* explained this apparent anomaly by showing that there

had been a high transection of the stalk which passed above the superior hypophysial artery. Such a lesion would spare the portal vessels, but would be expected to involve the vascular supply to the infundibulum (Fig. 5), and in fact there was extensive necrosis of the tuber cinereum in the case of Orthner and Meyer.

The lesions of the pars distalis in chronic traumatic hypopituitarism have rarely been reported (for references, see Daniel and Treip, 1966a). There may be reduction in size of the lobe, haemosiderin deposition, and lymphocytic foci. Sometimes the pars distalis is histologically normal, but in one such case (Goldman and Jacobs, 1960) it is clear that the principal damage was hypothalamic. Fibrosis, which might be expected to occur with some frequency after necrosis, appears to be an inconstant finding (Ceballos, 1966). Some cases show clear evidence of previous damage to the pituitary stalk. The rarity of long-surviving cases, in which there is a clear association between head injury and the development of hypopituitarism, has resulted in a lack of sufficient pathological material on which to base a general picture of the histopathology. In view of the finding of Daniel and Treip (1966b) that the pars distalis appears to have little power of anatomical regeneration it may be inferred, from the infrequency with which posttraumatic pituitary atrophy and hypopituitarism are found, that massive traumatic pituitary infarction with survival is in fact a relatively rare event.

Clinicopathological Correlations

The relation between clinical syndromes and pathological lesions in traumatic injuries, as in other disorders of the hypothalamic-pituitary axis, depends on the current state of knowledge of the anatomical and physiological connexions of the axis. For the neurohypophysis the anatomical relationship between the neurosecretory nuclei, the supraoptico-neurohypophysial tract, and the infundibular process is well established, while the functional relationship, as demonstrated initially in the monograph by Fisher, Ingram, and Ranson (1938), is also accepted. The theory of the hypothalamic (neurohumoral) control of the adenohypophysis via the hypophysial portal circulation, proposed by Green and Harris (1947), was supported by much indirect physiological evidence (Harris, 1955), but the demonstration and isolation of the hypothalamic neurohumours (releasing factors) concerned has been partly accomplished relatively recently (Harris, Reed, and Fawcett, 1966; McCann and Porter, 1969). In brief, it may be said that releasing factors for luteinizing, follicle-stimulating, thyrotrophic, adenocorticotrophic, and somatotrophic hormones have been found; for prolactin,

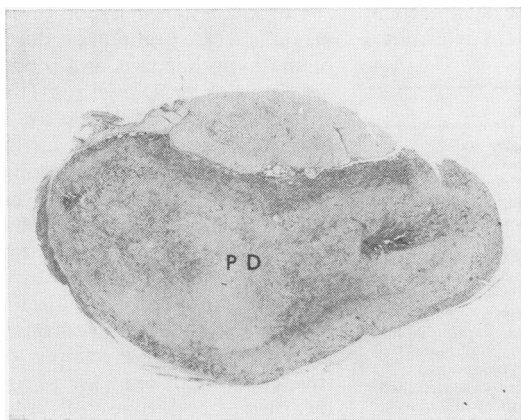


Fig. 11 Male, aged 21 years. Survived five days. Massive infarction of the pars distalis (PD), leaving a darker rim of surviving cells, thickest adjacent to the normal neurohypophysis. Haematoxylin and eosin $\times 7$.

however, the factor appears to be inhibitory rather than stimulating. All the factors seem to be located in the median eminence (tuber cinereum) of the infundibulum; chemically they are probably basic peptides, but their purification presents great technical difficulties, as analytical methods capable of estimating nanomolar quantities of peptides are required. There is some evidence that the hypophysial portal blood contains significantly larger amounts of luteinizing releasing factor than systemic blood (Fink, Nallar, and Worthington, 1966).

The functional link between the hypothalamus and pituitary, and hence the functional unity of the axis, is thus being demonstrated to an increasing extent. There have recently been attempts to differentiate clinically between disturbances of pituitary and hypothalamic function (Greenwood and Landon, 1966; Jasani, Boyle, Grieg, Dalakos, Browning, Thompson, and Buchanan, 1967; Jacobs and Nabarro, 1969). Such tests may be of value in the anatomical location of the level of a lesion, but it seems increasingly evident that a severe enough lesion of any part of the hypothalamic-pituitary axis will lead to loss of endocrine homeostasis, and that the axis should be regarded from the clinical point of view as a single unit.

Some of the more puzzling features of the clinical syndromes following head injury can be clarified when considered in this way.

POSTTRAUMATIC DIABETES INSIPIDUS

This is discussed in detail by Orthner and Meyer (1967). It is clinically a relatively rare event, Porter and Miller (1948) finding 18 examples in 5,000 cases of head injury. Orthner and Meyer consider that it arises only in cases of severe injury (though minor degrees of polyuria may be easily overlooked), and that it is usually transient, due to the large functional reserve of the neurosecretory system. The symmetrical structure of the neurosecretory system determines

that a lesion which will effectively reduce the production of antidiuretic hormone should be in the midline—either in the tuber cinereum or in the pituitary stalk. Lesions of the neurohypophysis alone may not result in diabetes insipidus if the neurosecretory nuclei are intact. These assumptions are borne out by Table I.

POSTTRAUMATIC ANTERIOR HYPOPHYSITARISM

The only evidence of disturbed adeno-hypophysial function which can be observed in the acute stage of head injury is electrolyte imbalance such as hypernatraemia (Taylor, 1962) and hyperchloraemia (Higgins, Lewin, O'Brien, and Taylor, 1951 and 1954). This could be ascribed to interruption of ACTH production and could theoretically arise as a result of massive necrosis of the pars distalis, or from a lesion of the infundibulum (affecting corticotrophin-releasing factor). Evidence that this may occur can be found in case 3 of Orthner and Meyer (1967), in which both hypernatraemia and hyperchloraemia were found, together with widespread necrosis of the tuber cinereum. Similarly, in a personal series of cases of fatal head injury, hypernatraemia was found in the acute phase in four cases and chronically in a fifth patient. In the hypothalamus of all five there was either necrosis or haemorrhage in the infundibulum. In three of the available pituitary glands the pars distalis, as in the case of Orthner and Meyer, was normal histologically. In the patient with the most severe hypernatraemia infundibular infarction was widespread, involving the tuberal nuclei and both ventromedial nuclei (Figs. 6, 8). Diabetes insipidus was not recorded in these five patients. It is possible, though difficult to prove, that the prolonged coma sometimes associated with massive necrosis of the pars distalis is a manifestation of acute pituitary failure (Daniel and Treip, 1961).

Chronic anterior hypopituitarism of traumatic origin is a rare event and reports of the pathology of the hypothalamus and pituitary in such cases are even scarcer. Daniel and Treip (1961) recorded six reports in the literature with pathological findings, to which two further cases may be added (Goldman and Jacobs, 1960; Orthner 1961). The interval of 14 years between head injury and the onset of Cushing's syndrome in Orthner's (1961) case seems rather long and the association may be fortuitous, particularly as an adenoma of the pars distalis was found at necropsy. The target syndromes described in the above reports were mainly of gonadal origin (five cases) with one case of myxoedema, one of dwarfism, and one of 'pituitary cachexia'. Obesity was present in two patients. Such syndromes could theoretically have arisen as a result either of infundibular lesions affecting releasing factors or of massive necrosis of the pars distalis. The latter lesion is difficult to assess retrospectively

Author	Lesion
Marañon and Pintos (1917) Reverchon, Worms, and Rouquier (1921) Henzi (1952)	Ruptured pituitary stalk Atrophy of neurohypophysis (suggesting late denervation)
Goldman and Jacobs (1960)	Ruptured pituitary stalk; atrophy of supraoptic and paraventricular nuclei
Orthner and Meyer (1967)	Fibrosis of basal hypothalamus; atrophy of supraoptic and paraventricular nuclei; fibrosis of neurohypophysis
	Case 1 Necrosis of infundibulum; pituitary stalk intact
	Case 2 Infundibulum torn; pituitary stalk stretched
	Case 3 Necrosis of tuber cinereum; rupture of pituitary stalk
Present study	Scarring of infundibulum (Fig. 7); atrophy of supraoptic and paraventricular nuclei

Table I *Posttraumatic diabetes insipidus*

and definite atrophy of the pars distalis is recorded in only three cases (Schereschewsky, 1927; Berblinger, 1934; Lerman and Means, 1945). In the case of Goldman and Jacobs (1960) the pars distalis was found to be normal, with severe fibrosis of the basal hypothalamus. In three other cases the findings did not suggest massive infarction of the pars distalis. The evidence, admittedly scanty, suggests that though massive infarction of the pars distalis certainly occurs in head injury, it is rarely survived for any length of time, and that hypothalamic damage may be less immediately fatal, consequently permitting deficiency syndromes to develop later. Further histological studies of the hypothalamus are needed to clarify this point.

AUTONOMIC AND OTHER DISTURBANCES

Injection of pressor amines into the cerebral ventricles may cause either a rise or a fall of body temperature (Feldberg and Myers, 1964; Cooper, 1965). The mechanism of temperature control is thought to be hypothalamic (Feldberg, 1965).

In a personally observed series of cases of head injury hypothermia (persistent in three long survivors) and persistent bradycardia (in one long survivor) were thought to be of hypothalamic origin. In one case there was scarring of the infundibulum and necrosis of the anterior fornix; in another, necrosis of the left side of the infundibulum and purulent ventriculitis; in a third case, there was massive infarction involving the wall of the third ventricle (Fig. 9). Persistent bradycardia was also present in the first case. In two cases of chronic posttraumatic hypopituitarism (Marañon and Pintos, 1917; Marañon, 1926) obesity was noticed; in one the infundibulum was normal, in the other the state of the third ventricle was not recorded.

Summary

The effects of trauma on the hypothalamus (15 cases) and pituitary (158 cases) were studied and a correlation of the lesions found with clinical syndromes of posttraumatic hypothalamic pituitary deficiency has been attempted.

In the hypothalamus the supraoptic nucleus was involved, in order of frequency, by haemorrhages, infarcts, and abscess formation. Retrograde degeneration of magnocellular neurones usually occurred slowly, in long-surviving cases. An explanation for the vulnerability of the supraoptic nucleus to traumatic damage is offered. The paraventricular nucleus was less commonly and less severely involved by similar lesions. Infarction and haemorrhages were observed in the infundibulum and lateral hypothalamus, less frequently in the mamillary bodies.

In the neurohypophysis acute haemorrhages were most commonly seen. Hypercellularity as a sign of denervation was seen at a later stage: atrophy and haemosiderin deposition in the chronic phase. Accumulation of neurosecretory material and retraction bulbs were evidence of ruptured axons. In the pars distalis the significant acute lesion was a massive infarct, most probably due to interruption of the hypophysial portal vessels of the stalk, as it closely resembled the infarcts produced by experimental and surgical stalk section. Atrophy of the pars distalis was an inconstant finding in chronic cases.

The hypothalamic-pituitary axis should be regarded as a functional unit and signs of endocrine disturbance may arise when the infundibular area (the site of pituitary hormonal releasing factors), the neurosecretory nuclei and supra-optic-hypophysial pathway (producing anti-diuretic hormone and controlling its release), or the pars distalis (producing pituitary trophic hormones) are damaged by trauma. Thermoregulatory disturbances may occur when the cavity or lining of the third ventricle are damaged.

The author wishes to thank Professor P. M. Daniel for constant support and valuable criticism; Mr W. S. Lewin for permission to examine clinical records; the Joint Committee for Clinical Research of Addenbrooke's Hospital for generous grants towards technical assistance; and the various technical assistants whose patient and skilful work made this study possible.

References

- Adams, J. H., Daniel, P. M., and Prichard, M. M. L. (1966). Transection of the pituitary stalk in man: anatomical changes in the pituitary glands of 21 patients. *J. Neurol. Neurosurg. Psychiat.*, 29, 545-555.
- Beck, E., and Daniel, P. M. (1961). Degeneration and regeneration in the hypothalamus. In *Cytology of Nervous Tissue*. Proc. Anat. Soc., p. 60. Taylor and Francis, London.
- Berblinger, W. (1934). Zur Kenntnis der Simmondsschen Krankheit (Hypopituitarismus totalis). *Endokrinologie*, 14, 369-383.
- Brennan, C. F., Malone, R. G. S., and Weaver, J. A. (1956). Pituitary necrosis in diabetes mellitus. *Lancet*, 2, 12-16.
- Ceballos, R. (1966). Pituitary changes in head trauma (analysis of 102 consecutive cases of head injury). *Ala. J. med. Sci.*, 3, 185-198.
- Christ, J. F. (1966). Nerve supply, blood supply and cytology of the neurohypophysis. In *The Pituitary Gland*, ed. G. W. Harris and B. T. Donovan, vol 3, pp. 62-130. Butterworth, London.
- Cooper, K. E. (1965). The role of the hypothalamus in the genesis of fever. *Proc. roy. Soc. Med.*, 58, 740.
- Daniel, P. M. (1966). The anatomy of the hypothalamus and pituitary gland. *Neuroendocrinology*, 1, 15.
- Daniel, P. M., Duchon, L. W., and Prichard, M. M. L. (1964). The cytology of the pituitary gland of the rhesus monkey: Changes in the gland and its target organs after section of the pituitary stalk. *J. Path. Bact.*, 67, 385-393.
- Daniel, P. M., and Prichard, M. M. L. (1957). Anterior pituitary necrosis in the sheep produced by section of the pituitary stalk. *Quart. J. exp. Physiol.*, 42, 248-254.
- Daniel, P. M., and Prichard, M. M. L. (1958). The effects of pituitary stalk section in the goat. *Amer. J. Path.*, 34, 433-469.

- Daniel, P. M., and Prichard, M. M. L. (1966). Observations on the vascular anatomy of the pituitary gland and its importance in pituitary function. *Amer. Heart J.*, **72**, 147-152.
- Daniel, P. M., Prichard, M. M. L., and Treip, C. S. (1959). Traumatic infarction of the anterior lobe of the pituitary gland. *Lancet*, **2**, 927-931.
- Daniel, P. M., and Treip, C. S. (1961). The pathology of the pituitary gland in head injury. In *Modern Trends in Endocrinology*, edited by H. Gardiner-Hill, second series, pp. 55-68. Butterworth, London.
- Daniel, P. M., and Treip, C. S. (1966a). Lesions of the pituitary gland associated with head injuries. In *The Pituitary Gland*, ed. G. W. Harris and B. T. Donovan, vol. 2, pp. 519-534. Butterworth, London.
- Daniel, P. M., and Treip, C. S. (1966b). The regenerative capacity of pars distalis of the pituitary gland. In *The Pituitary Gland*, ed. G. W. Harris and B. T. Donovan, vol. 2, pp. 535-554. Butterworth, London.
- Feldberg, W. (1965). A new concept of temperature control in the hypothalamus. *Proc. roy. Soc. Med.*, **58**, 395-404.
- Feldberg, W., and Myers, R. D. (1964). Effects on temperature of amines injected into the cerebral ventricles. A new concept of temperature regulation. *J. Physiol. (Lond.)*, **173**, 226-231.
- Fink, G., Nallar, R., and Worthington, W. C., Jr. (1966). Determination of luteinising hormone releasing factor (L.R.F.) in hypophysial portal blood. *J. Physiol. (Lond.)*, **183**, 20-21P.
- Fisher, C., Ingram, W. R., and Ranson, S. W. (1938). *Diabetes insipidus and the Neuro-hormonal Control of Water Balance*. Edwards, Ann Arbor, Michigan.
- Goldman, K. P., and Jacobs, A. (1960). Anterior and posterior pituitary failure after head injury. *Brit. med. J.*, **2**, 1924-1926.
- Green, J. D., and Harris, G. W. (1947). The neurovascular link between the neurohypophysis and adenohypophysis. *J. Endocr.*, **5**, 136-146.
- Greenwood, F. C., and Landon, J. (1966). Assessment of hypothalamic pituitary function in endocrine disease. *J. clin. Path.*, **19**, 284-292.
- Harris, G. W. (1955). *Neural Control of the Pituitary Gland*. Arnold, London.
- Harris, G. W., Reed, M., and Fawcett, C. P. (1966). Hypothalamic releasing factors and the control of anterior pituitary function. *Brit. med. Bull.*, **22**, 266-272.
- Henzi, H. (1952). Zur pathologischen Anatomie des Diabetes insipidus. *M Schr. Psychiat. Neurol.*, **123**, 292-316.
- Higgins, G., Lewin, W., O'Brien, J. R. P., and Taylor, W. H. (1951). Metabolic disorders in head injury. *Lancet*, **1**, 1295-1300.
- Higgins, G., Lewin, W., O'Brien, J. R. P., and Taylor, W. H. (1954). Metabolic disorders in head injury. *Lancet*, **1**, 61-67.
- Jacobs, H. S., and Nabarro, J. D. N. (1969). Tests of hypothalamic-pituitary-adrenal function in man. *Quart. J. Med.*, **38**, 475-491.
- Jasani, M. K., Boyle, J. A., Grieg, W. R., Dalakos, T. G., Browning, M. C. K., Thompson, A., and Buchanan, W. W. (1967). Corticosteroid-induced suppression of the hypothalamo-pituitary-adrenal axis: observations on patients given oral corticosteroids for rheumatoid arthritis. *Quart. J. Med.*, **36**, 261-276.
- Kahler, O. (1886). Die dauernde Polyurie als cerebrales Herdsymptom. *Z. Heilk.*, **7**, 105-220.
- Kornblum, R. N., and Fisher, R. S. (1969). Pituitary lesions in craniocerebral injuries. *Arch. Path.*, **88**, 242-248.
- Lerman, J., and Means, J. H. (1945). Hypopituitarism associated with epilepsy following head injury. *J. clin. Endocrin.*, **5**, 119-131.
- McCann, S. M., and Porter, J. C. (1969). Hypothalamic pituitary stimulating and inhibiting hormones. *Physiol. Rev.*, **49**, 240-284.
- Marañon, G. (1926). Über die hypophysäre Fettsucht. *Dtsch Arch. klin. Med.*, **151**, 129-153.
- Marañon, G., and Pintos, G. (1917). Lésion traumatique pure de l'hypophyse. Syndrome adipo-génital et diabète insipide. *Nouv. Iconogr. Salpêtr.*, **28**, 185-195.
- Müller, W. (1955). Neurosekretstauung im Tractus supraoptico-hypophysäus des Menschen durch einen raumbeengenden Prozess. *Z. Zellforsch.*, **42**, 439-442.
- Orthner, H. (1961). Hirntrauma, Hypothalamus und Cushingsche Krankheit. *Acta. neuroveg. (Wien)*, **23**, 75-87.
- Orthner, H., and Meyer, E. (1967). Der posttraumatische Diabetes insipidus. *Acta neuroveg. (Wien)*, **30**, 216-250.
- Plaut, A. (1952). Pituitary necrosis in routine necropsies. *Amer. J. Path.*, **28**, 883-899.
- Porter, R. J., and Miller, R. A. (1948). Diabetes insipidus following closed head injury. *J. Neurol. Neurosurg. Psychiat.*, **11**, 258-262.
- Reverchon, L., Delater, G., and Worms, G. (1923). Contribution à l'étude de lésions traumatiques de l'hypophyse. Volumineux kyste hémorrhagique de cette glande, consécutif à une contusion du crâne. *Rev. neurol.*, **30**, 217-225.
- Reverchon, L., Worms, G., and Rouguier (1921). Lésions traumatiques de l'hypophyse et paralysies multiples des nerfs crâniens. *Presse méd.*, **29**, 741-743.
- Russell, D. S. (1949). Observations on the pathology of hydrocephalus. *Spec. Rep. Ser. med. Res. Counc. (Lond.)*, **265**, 119.
- Schereschewsky, N. A. (1927). La symptomatologie et le diagnostic de la maladie de Simmonds (cachexie hypophysaire). *Rev. franç. Endocr.*, **5**, 275-281.
- Sheehan, H. L. (1937). Post-partum necrosis of the anterior pituitary. *J. Path. Bact.*, **45**, 189-214.
- Sheehan, H. L., and Summers, V. K. (1949). The syndrome of hypopituitarism. *Quart. J. Med.*, **18**, 319-378.
- Taylor, W. H. (1962). Hypernatraemia in cerebral disorders. *J. clin. Path.*, **15**, 211-220.
- Vonderahe, A. R. (1940). Changes in the hypothalamus in organic disease. *Res. Publ. Ass. nerve. ment. Dis.*, **20**, 689-712.
- Wolman, L. (1956). Pituitary necrosis in raised intracranial pressure. *J. Path. Bact.*, **72**, 575-586.