

The Contribution of Cerebral Angiography in Diagnosis

R. B. RANEY, M.D., and AIDAN A. RANEY, M.D., *Los Angeles*

SUMMARY

Angiography is important in the diagnosis of central nervous system disorders. In operable lesions it not only discloses the location of the lesion but also gives valuable information regarding its character and surrounding vascular architecture.

The technique of both the percutaneous and the open methods is described. The advantages of the controlled automatic arteriograph are described as well as pertinent information regarding cerebral circulation time.

The choice of contrast media and the advantages and disadvantages of each are described.

The three phases of angiography important in diagnosis—the arterial phase, the capillary phase and the venous phase—are discussed.

The indications and contraindications are briefly outlined with respect to neoplasms, trauma, hemorrhage, aneurysms and other such operable lesions.

The characteristic changes produced by aneurysms, vascular malformations, neoplasms and other space-occupying lesions as related to the circulatory apparatus show variations characterizing the type of lesion encountered.

Angiography in traumatic conditions, while limited, is of exceptional value in the diagnosis of obscure lesions, particularly the subdural hematomas.

THE importance of angiography in the diagnosis of central nervous system disorders cannot be overemphasized. While it does not in any way replace a thorough neurological examination, it does serve as a valuable supplement. Actually, it may be more informative than pneumoencephalography or ventriculography.

By its use, the vascular architecture and often the pathologic character of operable lesions can be determined before surgical intervention. Such information is of the greatest importance in the plans of a successful operation. It is perhaps the only positive method for differentiating between the types of progressive cerebrovascular disease and expanding lesions. Other more obscure lesions, such as an-

eurysms, arteriovenous complexes, and telangiectases, often cannot otherwise be positively identified.

The gravity of the situation demanding angiography is invariably greater by far than the small risk involved. While the procedure has been slow in gaining popularity, it now ranks with the most important supplementary aids in neurologic diagnosis.

HISTORY

In 1927 Moniz and Tima established the diagnosis of a temporal lobe tumor in a cadaver by injecting radiopaque material into the carotid artery. They found that a solution of sodium iodide gave good contrast pictures and could be injected so as to visualize cerebral vessels with reasonable safety. Subsequently the procedure became routine in their clinic in suitable cases. The speed of blood flow through the brain was studied. The characteristic difference in the angiographic pattern between meningioma and astrocytoma was established. Changes resulting from trauma, especially subdural hematoma, were reported. Tonnis pointed out the differentiating feature of glioblastoma multiforme and cerebral abscess. Dyes and Fisher elaborated on tumor localization by angiography. Lorenz attempted to classify tumors on the basis of their angiographic pattern (cited by Engset).⁶

Saccular aneurysms were described by Hermann,¹⁰ Dott,^{2, 3, 4} and Jefferson.^{11, 12, 13} Details of a vascular malformation were reported by Bergstrand, Olivecrona and Tonnis (cited by Engset).⁶ In more recent years List,^{14, 15, 16, 17} Gross,^{8, 9} Poppen,²¹ Norlen,¹⁹ Elvidge,⁵ Culbreth,¹ Gass,⁷ and others have stressed the value of angiography in surgical lesions. These contributions, among others of equal and supplemental importance, have established angiography as another indispensable method of studying diseases of the central nervous system.

TECHNIQUE

As in all roentgenographic studies, good films are essential. Since rapidly moving dye in the cerebral circulations must be photographed, proper equipment and an experienced team are required. Three phases of the circulation are important—the arterial phase, the capillary phase, and the venous phase. The average length of time for blood to travel from the carotid artery in the neck through the brain and back to the jugular vein in the neck is 4.5 seconds. Therefore, a series of films must be exposed during this period of time.

The authors use an automatic film changer which furnishes six exposures in 4.5 seconds.²² This gives a complete picture of the cerebral circulatory apparatus as well as an evaluation of the circulation

Presented as part of the Symposium on Diseases of the Central Nervous System before the Section on General Medicine at the 79th Annual Meeting of the California Medical Association, San Diego, April 30-May 3, 1950.

time. Thus alterations of the circulatory mechanism which occur in disease can readily be visualized. Since the blood in the carotid artery moves rapidly, the dye should be injected in a single burst through a 17-gauge needle. Film exposure must be started as the last of the dye leaves the needle. This gives proper timing of films, and 3 cc. of dye when injected rapidly gives adequate concentration in all parts of the vascular system. Anteroposterior and lateral exposures are usually sufficient. Occasionally an oblique view may be desirable and this can be determined by studying the wet films before removing the needle from the artery.

The choice of dye has been the subject of considerable controversy. In this country Thorotrast® and Diodrast® are the most commonly employed. Thorotrast is the least irritating, gives the best pictures, and therefore enjoys the greater popularity. However, it is objected to by a few on the ground that it is radioactive.^{18, 20, 23, 24} After injection it is finally deposited in the reticuloendothelial system. In large doses it has been known to cause unfavorable changes in experimental animals. However, experience has shown that the amount required for angiography can be used with safety equal to other media. Diodrast in 35 per cent solution unfortunately is irritating and occasionally causes complications. Further, it gives only fair roentgenographic

detail. The authors use both Diodrast and Thorotrast as media. Diodrast is probably preferable for introduction by direct puncture. Further, it should be used if repeated angiographic studies are to be done, in order to avoid an accumulative dose of Thorotrast. In the case of iodine sensitivity Thorotrast should be used in preference to Diodrast.

The introduction of dye into the desired vessel may be accomplished either by the open method or by direct puncture. The open method is commonly indicated for study of aneurysms, certain tumors, arteriovenous fistulae. By this method tolerance to ligation of the vessel can be tested. If compression of the contralateral carotid artery allows the contralateral arterocerebral artery to fill, the anterior communicating artery is adequate and carotid ligation will probably be tolerated.

THE NORMAL ANGIOGRAPHIC PATTERN

Three phases of the circulatory apparatus as previously mentioned must be photographed because study with a single exposure is at best a hit-and-miss proposition. With an automatic film changer permitting six exposures during the circulation time, the three angiographic phases can be readily demonstrated. Usually the first two films demonstrate the arterial system. In the third and fourth films the dye is generally ill-defined since it is broken up in

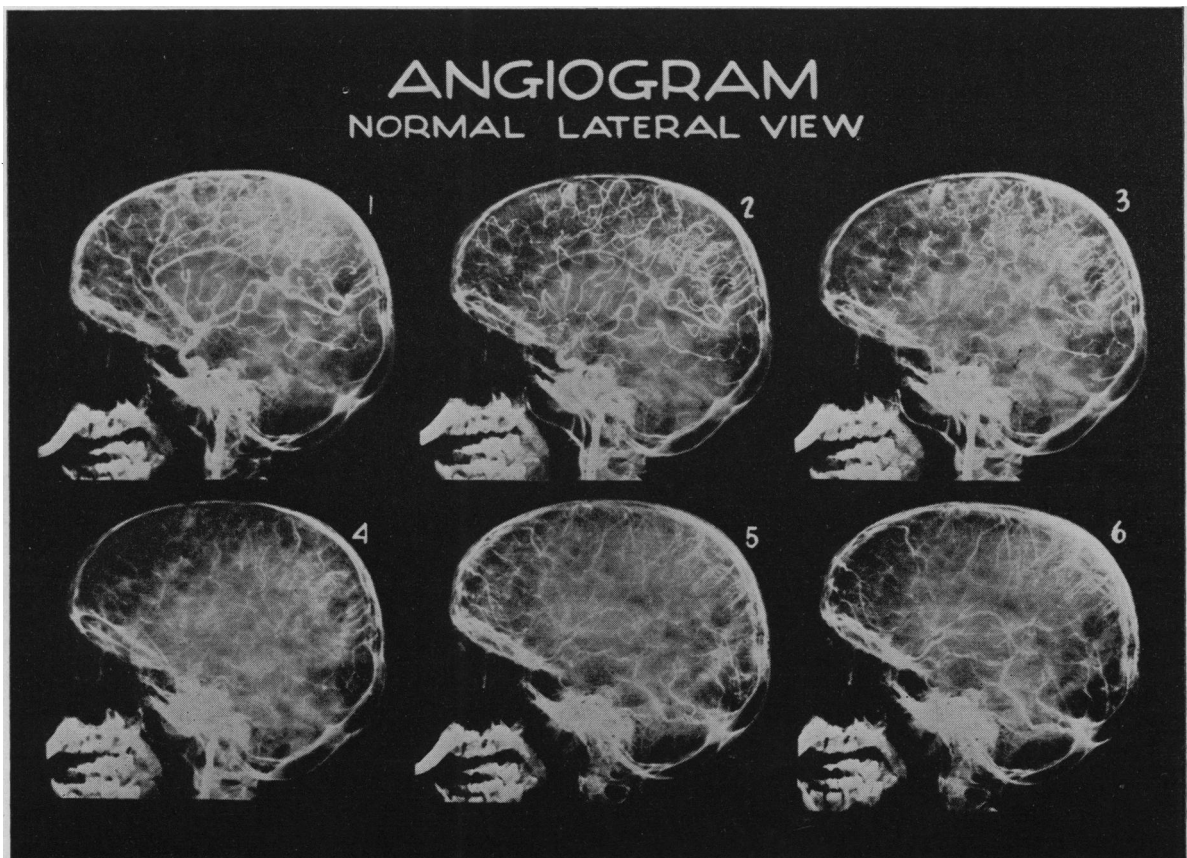
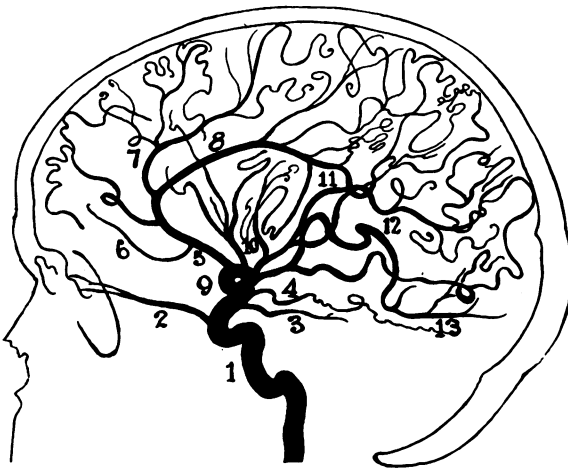
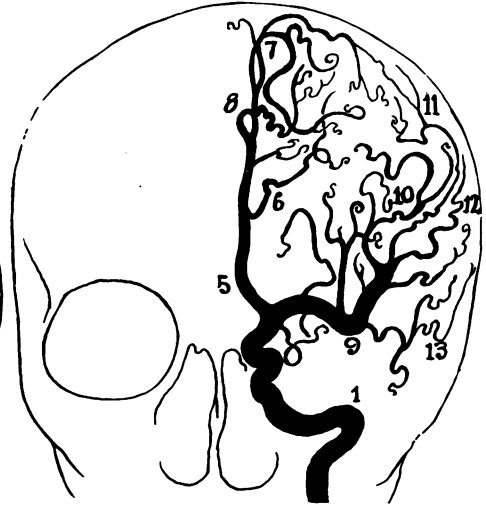

Figure 1.—First films in series show arterial phase. Films 3 and 4 show dye broken up in smaller vessels and capillaries. Film 6 shows large veins and sinuses.

NORMAL CAROTID ANGIOGRAM



- 1- INT. CAROTID
- 2- OPHTHALMIC
- 3- POST. COMM.
- 4- ANT. CHOROIDAL
- 5- ANT. CEREBRAL
- 6- FRONTOPOLAR
- 7- CALLOSOMARGINAL



- 8- PERICALLOSAL
- 9- MID. CEREBRAL
- 10- ASC. FRONTOPARIETAL
- 11- POST. PARIETAL
- 12- ANGULAR
- 13- POST. TEMP.

Figure 2.—Drawing made from arteriograms showing principal arteries.

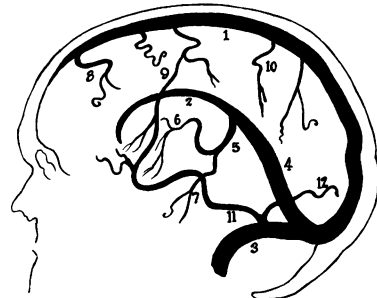
the arterioles, capillaries and venules. In the last two films the dye becomes visible again in the veins and dural sinuses (Figure 1). For practical illustration the blood vessels, which can ordinarily be demonstrated by angiography, have been copied from actual roentgenograms. The cerebral anatomical pattern is shown in Figure 2. The pattern of the veins and sinuses is illustrated in Figure 3. The vertebral pattern is shown in Figure 4.

INDICATIONS

Like other comparable methods of examination, angiography must be employed judiciously. Even though the risk involved is minimal, it can hardly become a routine roentgenographic procedure. On the other hand, most intracranial disorders of an uncertain nature merit its use. Regardless of the type of lesion, if knowledge of the vascular architecture in a particular case is important for surgical repair, angiography is practically mandatory. In the presence of unexplained spontaneous subarachnoid hemorrhage, it is a necessary procedure. It is required for intelligent planning of the surgical management of aneurysms, vascular malformations, arteriovenous fistula, etc. In cases of cerebral lesions with high intracranial pressure, angiography often gives as much information as ventriculography, sometimes more; and it is by far the safer of the two procedures.

The contraindications are sufficiently clear that they require little more than mention. The usual

NORMAL VENOGRAM

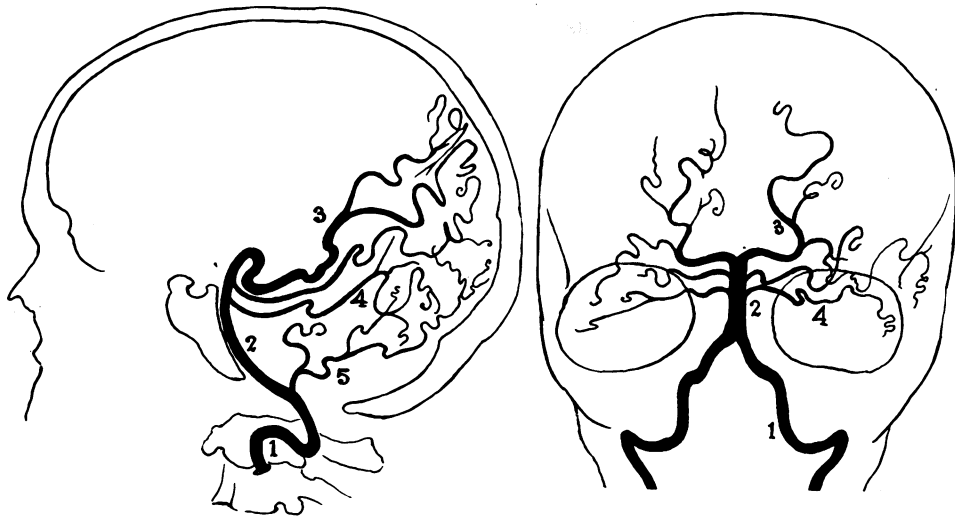


- 1- SUP. SAG. SINUS
- 2- INF. SAG. SINUS
- 3- TRANSV. SINUS
- 4- STRAIGHT SINUS
- 5- GR. CEREBRAL VEIN OF GALEN
- 6- INT. CEREBRAL V.
- 7- BASAL V. OF ROSENTHAL
- 8- FRONT. ASC. V.
- 9- ROLANDIC V. OF TROLARD
- 10- PAR. ASC. V.
- 11- COMM. TEMP. V. OF LABBE
- 12- DESC. TEMPORO-OCCIP.

Figure 3.—Drawing showing the principal veins and sinuses.

contraindications to minor surgical procedures of an elective nature are generally contraindications to angiography. Further, when the diagnosis is certain, it should not be employed as a routine procedure in conditions for which surgical treatment cannot be of benefit—for example, thrombosis or hemorrhage in arteriosclerotic hypertensive vascular disease. On the other hand, it may be very important in the presence of clinical symptoms simulating those of progressive cerebral thrombosis when

NORMAL VERTEBRAL ANGIOGRAM



- 1- VERTEBRAL
- 2- BASILAR
- 3- POST. CEREBRAL

- 4- SUP. CEREBELLAR
- 5- POST. INF. CEREBELLAR

Figure 4.—Characteristic pattern of arteries demonstrable by vertebral arteriography.

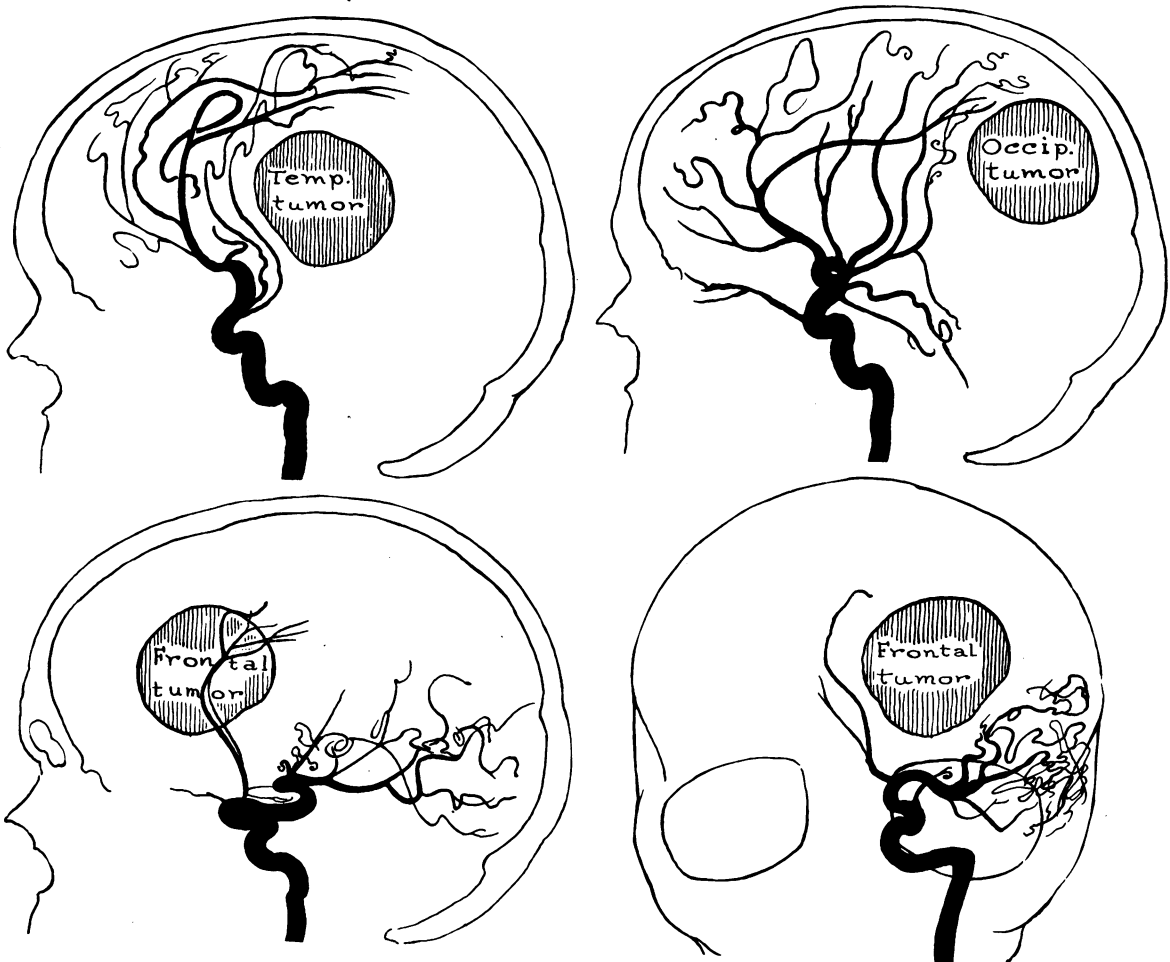


Figure 5.—Characteristic distortion of vessels caused by neoplasms or other comparable space-consuming masses within the brain.

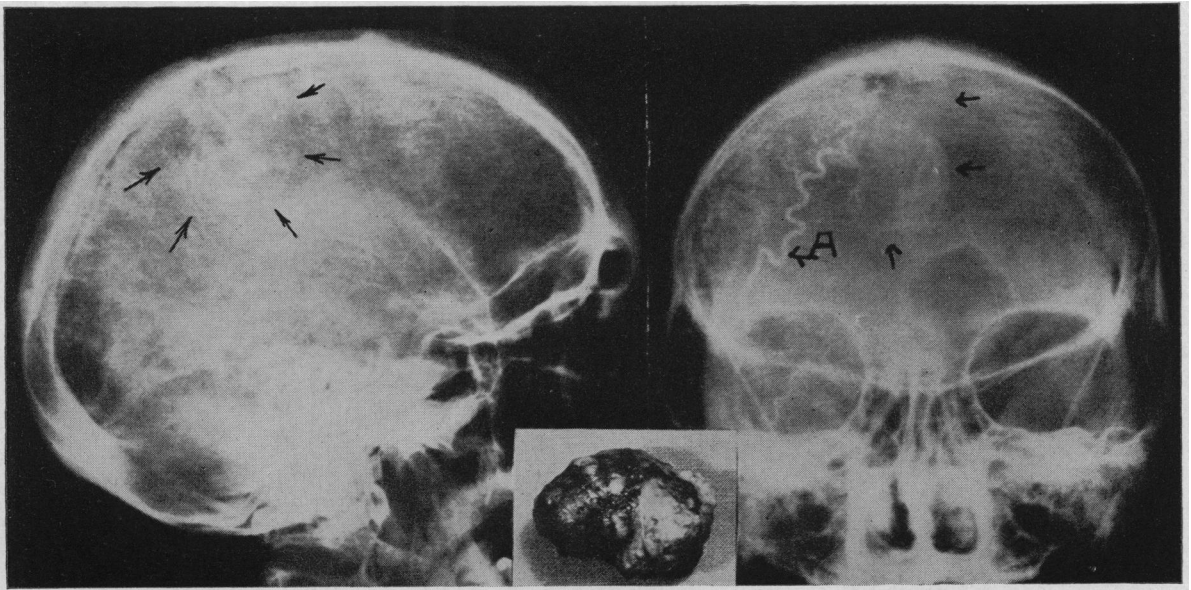


Figure 6.—Angiogram showing capillary phase and concentration of dye in a typical meningioma. (a) Occipital artery feeding tumor. Extirpated tumor shown in insert.

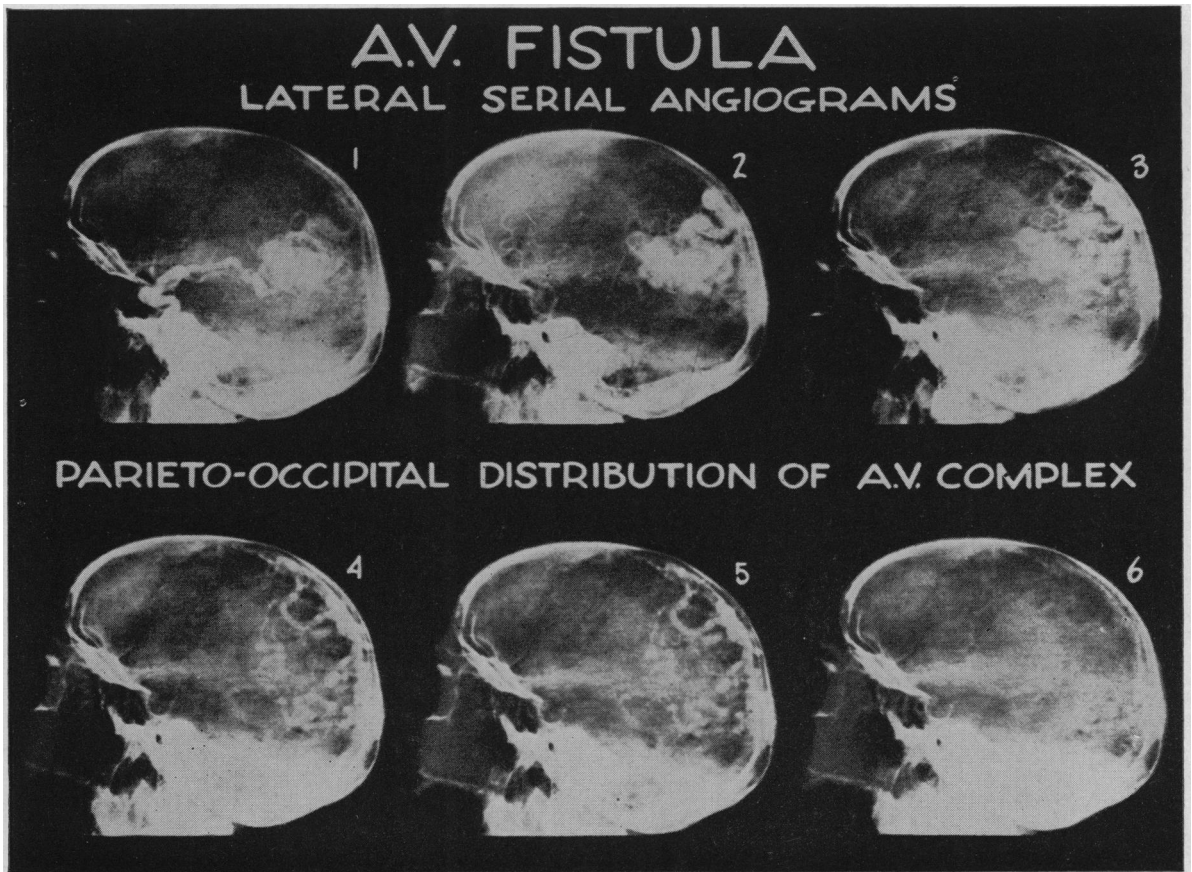


Figure 8.—Angiogram showing the dye concentrated in a typical arteriovenous malformation.

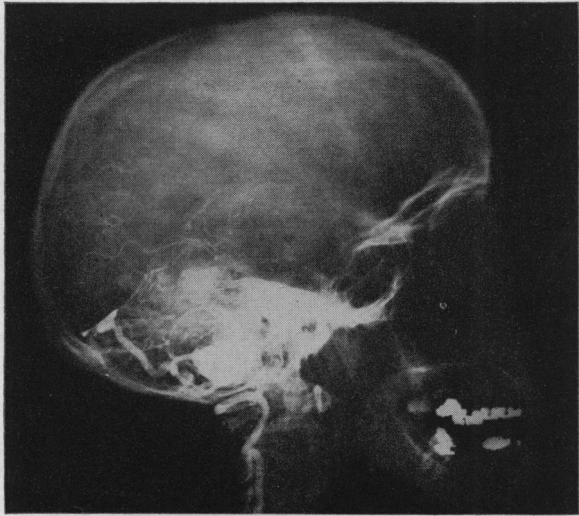


Figure 7.—Vertebral angiogram in a case of Lindau's disease. Dye can be seen concentrated in large hemangiomatic vascular sinuses. The angiogram discloses the location of these vessels, which is a great aid to the surgeon planning operation.

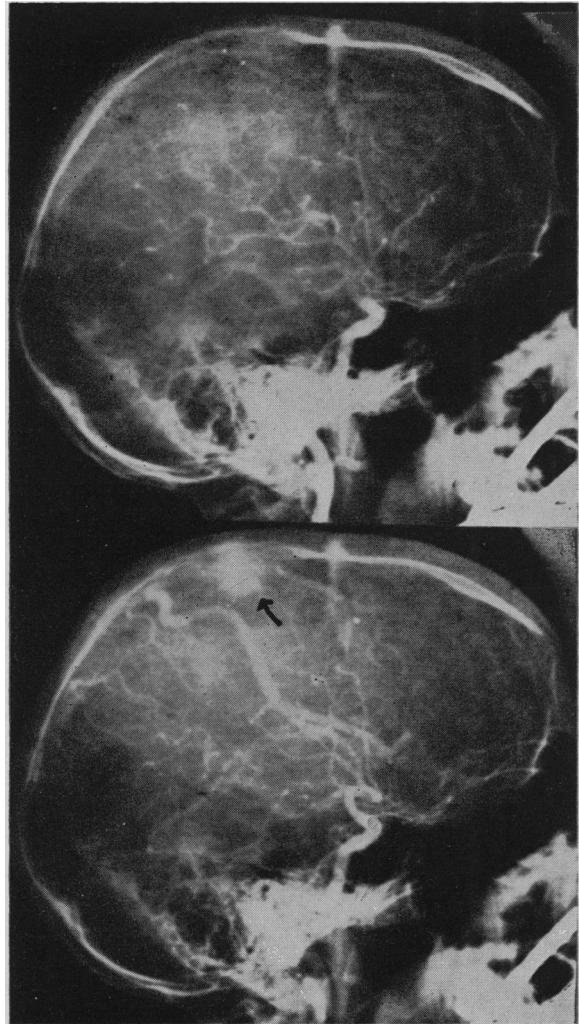


Figure 9.—Arrow points to typical telangiectatic lesion of the cerebral hemisphere that would have been missed entirely without controlled serial cerebral angiography.

hypertension and arteriosclerosis are not too pronounced. Neoplasms often produce such a picture.

PATHOLOGIC CHANGES

Intracranial space-consuming lesions, provided they are sufficiently large, tend to distort the normal arrangement of the vascular pattern. Lesions in the occipital region will usually cause a forward displacement of the vessels. Those in the frontal sector cause posterior or downward displacement, whereas others in the temporal zone cause an upward shift, etc. (Figure 5). These generalities are fairly constant provided the lesion is sufficiently large. However, the degree of displacement and of alteration depends on the size of the lesion and the lines of force it creates.

Neoplasms near the surface, in addition to their displacing qualities, usually have a blood supply of their own which offers a fertile field for angiographic investigation. Deep-seated tumors and especially those within the ventricles are ordinarily best demonstrated by pneumographic visualization. Malignant glioblastic tumors often have areas of necrosis and cyst formation in which an absence of vascularity is observed. In other areas, vascular proliferation is commonly visualized. Overlying convolutions are often widened, displacing the surface veins. Other tumors of the glioma group at times are said to show suggestive characteristic vascular changes. The classification of tumors by angiography, however, should certainly be exercised with caution and subjected to final microscopic verification. Angiography serves chiefly as a localizing agent and may reveal vascular structures which aid considerably in surgical planning.

Meningiomas cause distortion of the vascular system in a manner comparable to the changes caused by other space-consuming lesions. Since their blood supply is often from the external carotid artery, inclusion of this vessel in the angiogram is important. Dye can often be seen entering the tumor through the meningeal arteries. These tumors are ordinarily quite vascular; hence, the capillary phase of the angiogram frequently shows the tumor as a white mass resembling a snowball (Figure 6).

Tumors about the optic nerves or chiasm (for example, pituitary adenoma, craniopharyngioma, meningioma on the tuberculum sellae, and optic nerve tumors) seldom present a diagnostic problem and can be recognized by the usual clinical means. Occasionally, however, unusual lesions are encountered and aneurysms must be considered. Therefore, angiography is frequently indicated in cases in which aneurysm in the area is suspected. Tumors of other cranial nerves can likewise be recognized by characteristic history and findings. The acoustic neuroma is probably the most common of these neoplasms and seldom presents diagnostic difficulty.

Rarely do tumors of the posterior fossa offer great difficulty in diagnosis. Angiomatosis retinae at times is associated with hemangioblastic tumors in the cerebellum, and in such instances angi-

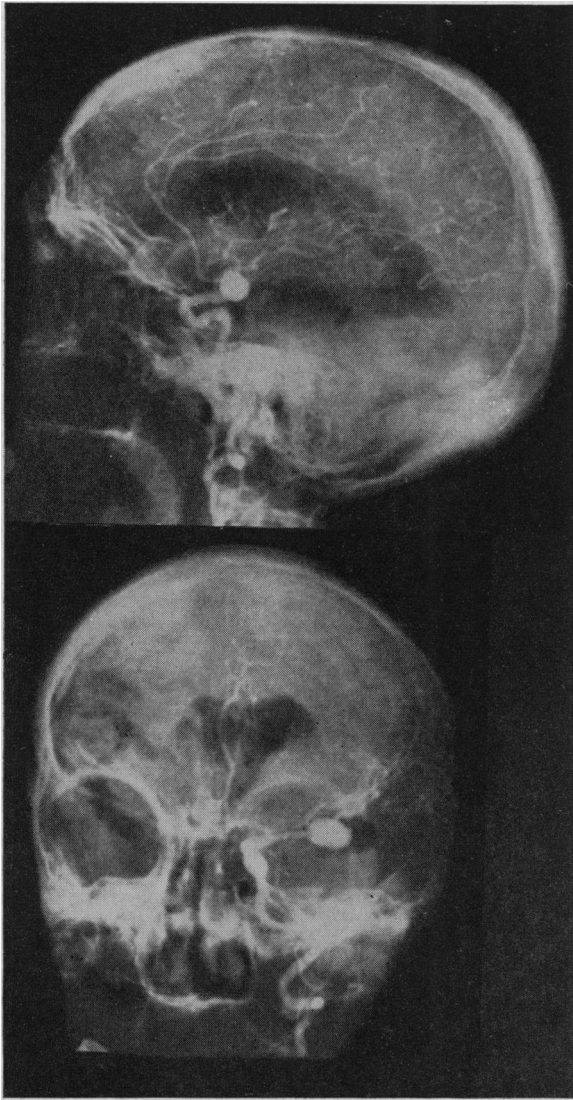


Figure 10.—Angiogram showing location of typical pedunculated saccular arterial aneurysm.

ography may aid in the solution of technical problems before operation (Figure 7).

Intracranial arteriovenous malformations are not uncommon. When symptoms are present they are usually mild. Occasionally a bruit is audible over the scalp, but this is the exception rather than the rule. Pneumoencephalography rarely if ever gives conclusive information in such cases. Electroencephalography may establish which side the abnormality is on but never gives reliable information as to the character of the lesion. Angiography, however, establishes the diagnosis and location with certainty (Figure 8). Likewise, telangiectatic lesions can be demonstrated only by angiography. Furthermore, like other lesions they are liable to be missed entirely unless a complete serial angiographic study is done (Figure 9).

Congenital aneurysms are the most common cause of spontaneous subarachnoid hemorrhage. Therefore, unless clinical study shows hypertension,

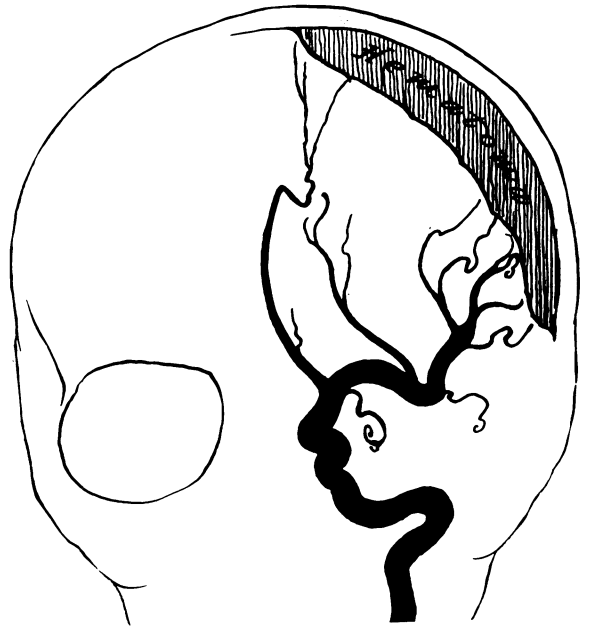


Figure 11.—Artist's drawing from an angiogram showing the vascular shift seen in the case of either subdural or extradural hemorrhage.

hemophilia, polycythemia vera, Dicumarol[®] intoxication, or other such conditions to be the cause of hemorrhage, angiography should be carried out. Often with rest and conservative management the leaking will temporarily stop and all symptoms will clear. Some of the lesions are small and undoubtedly heal by thrombosis. Nevertheless, the majority of such aneurysms remain a potential cause of fatal attack unless demonstrated and repaired (Figure 10).

As a rule, angiography is not required for appraisal of lesions resulting from craniocerebral trauma. On the other hand, obscure post-traumatic states, such as chronic subdural hematoma, may be clarified by the procedure. These accumulations of blood cause a characteristic shift of the cortical vascular architectures away from the skull, and as a rule a general shift of the entire vascular pattern away from the lesion (Figure 11). Extradural hemorrhages usually have acute onset a few hours after injury and diagnosis seldom is difficult. Occasionally, however, angiography may be helpful.

1136 West Sixth Street.

REFERENCES

1. Culbreth, G., Walker, A., and Curry, R. W.: Cerebral angiography in "brain tumor suspects," *J. Neurosurg.* 7: 127-138, Mar. 1950.
2. Dott, N. M.: Intracranial aneurysms: Cerebral arteriography: Surgical treatment, *Trans. Med.-Chir. Soc. Edinb.*, 219-234, 1932-1933.
3. Dott, N. M.: Cephalic aneurysmal formation, *J. Neurol. Psychiat. n.s.*, 6:158-159, 1943.
4. Dott, N. M.: Intracranial aneurysmal formation. Read at a meeting of British Neurological Surgeons, Lisbon, April 10, 1947.
5. Elvidge, A. R., and Feindel, W. H.: Surgical treatment of aneurysms of the anterior cerebral and of the anterior

communicating arteries diagnosed by angiography and electroencephalography, *J. Neurosurg.*, 7:13-30, Jan. 1950.

6. Engeset, A.: Cerebral angiography with Perabrodil, Oslo, 1944.

7. Gass, H., Weinberg, S., Craig, A., Thompson, J. J., and Dreisinger, Frank: Cerebral angiography recorded cinefluorographically, *J. Neurosurg.*, March 1950.

8. Gross, S. W.: Cerebral arteriography. Its place in neurologic diagnosis, *Arch. Neurol. Psychiat.*, Chicago, 46:704-714, Oct. 1941.

9. Gross, S. W.: Cerebral arteriography, *Surg. Clin. N. Amer.*, 28:405-411, April 1948.

10. Hermann, K., Obrador, S., and Dott, N. M.: Intracranial aneurysms and allied clinical syndromes. Cerebral arteriography in their management, *Lisbon Med.*, 14:782-814, 1937.

11. Jefferson, G.: Compression of the chiasma, optic nerves and optic tracts by intracranial aneurysms, *Brain*, 60:444-497, 1937.

12. Jefferson, G.: On the saccular aneurysms of the internal carotid artery in the cavernous sinus, *Brit. J. Surg.*, 26:267-302, Oct. 1937.

13. Jefferson, G.: Isolated oculomotor palsy caused by intracranial aneurysm, *Proc. Roy. Soc. Med.*, 40:419-432, June 1947.

14. List, C. R., Burg, C. H., and Hodges, F. J.: Intracranial angiography, *Radiology*, 45:1-14, July 1945.

15. List, C. F., and Hodges, F. J.: Angiographic diagnosis of expanding intracranial lesions by vascular displacement, *Radiology*, 47:319-333, Oct. 1946.

16. List, C. F., and Hodges, F. J.: Differential diagnosis of intracranial neoplasms by cerebral angiography, *Radiology*, 48:493-508, May 1947.

17. List, C. F., and Hodges, F. J.: Intracranial angiography. 1. The diagnosis of vascular lesions, *J. Neurosurg.*, 3:25-45, Jan. 1946.

18. Martland, H. S.: Radium poisoning. In: *A Textbook of Medicine* by American Authors, R. L. Cecil, E. Philadelphia, W. B. Saunders Co., 4th ed., 1,614 pp. (see pp. 551-555), 1937.

19. Norlen, G.: Arteriovenous aneurysms of the brain. A report of ten cases of total removal of the lesion, *Jnl. Neurosurg.*, 4:476-494, Nov. 1949.

20. Northfield, D. W. C., and Russell, D. S.: The fate of thorium dioxide (Thorotrast) in cerebral arteriography, *Lancet*, 1:377-381, Feb. 1937.

21. Poppen, J. L.: Intracranial aneurysm in 51 proved cases, *Arch. Neurol. Psychiat.*, Chicago, 55:293-296, 1946.

22. Raney, R., Raney, A. A., and Sanchez-Perez, J. M.: The role of complete cerebral angiography in neurosurgery, *J. Neurosurg.*, 6:222-237, May 1949.

23. Reeves, D. L., and Stuck, R. M.: Clinical and experimental results with Thorotrast, *Medicine*, 17:37-73, Feb. 1938.

24. Stuck, R. M., and Reeves, D. L.: Dangerous effects of Thorotrast used intracranially with special reference to experimental production of hydrocephalus, *Arch. Neurol. Psychiat.*, 40:86-115, July 1938.

25. Turnbull, F.: Cerebral angiography by direct injection of the common carotid artery, *Amer. J. of Radiology*, p. 166, 1938.

