

# CASE REPORTS

- **P. Vivax Malaria**
- **Falciparum Malaria**
- **A Complication of Pyloromyotomy**
- **Sarcoidosis**

## **P. Vivax Malaria**

### **A Case with Anemia, Cardiomegaly, Hepatomegaly and Renal Involvement**

EUGENE B. LEVIN, M.D., Los Angeles

*PLASMODIUM VIVAX* MALARIA is a protean disease. Signs and symptoms mimicking those of acute and chronic diseases involving the liver, spleen, kidneys, blood, gastrointestinal tract, brain and respiratory system have been reported.<sup>5</sup> In the present case, anemia, hepatomegaly, cardiomegaly and renal abnormalities were present.

#### **CASE REPORT**

A 29-year-old white man was admitted to Letterman Army Hospital on June 25, 1953, with diagnosis of malaria. He had served in Korea from July until December 1952, at which time he had suppressive antimalarial therapy and was evacuated because of injury to the right thumb, which had to be amputated. He was well until mid-June 1953, when he began noting gradual development of undue fatigue on moderate exertion, malaise and mild swelling of both ankles. A week later there was sudden onset of severe chills, fever, headache, low backache and mild nonproductive cough.

Upon physical examination the patient appeared to be fairly acutely ill. Oral temperature was 102.4° F., the pulse rate 96, respirations 22 per minute and the blood pressure 130/84 mm. of mercury. The skin, mucous membranes and nail beds were pale. The lungs were clear to percussion and auscultation. A Grade I pulmonary systolic murmur was present. The liver edge, which was palpated three fingerbreadths below the right costal margin in the mid-clavicular line, was smooth and slightly tender. Slight pitting edema of the ankles was noted.

The hemoglobin content of the blood was 8.1 gm. per 100 cc., the packed cell volume was 26 per cent of the whole blood, the erythrocyte sedimentation rate was 21 mm. in one hour (Wintrobe method) and leukocytes numbered 4,300 per cu. mm.—41 per

cent neutrophils, 52 per cent lymphocytes, 6 per cent monocytes and 1 per cent eosinophils. The mean corpuscular volume was 98 cubic micra, the mean corpuscular hemoglobin was 31 gamma gamma, and the mean corpuscular hemoglobin concentration was 31 per cent. The reticulocyte count was 6 per cent the day after admission. *P. vivax* was observed upon examination of a specimen of blood.

Upon microscopic examination of the urine on the day of admittance a trace of albumin, 4+ reaction for occult blood and numerous leukocytes were noted. A week later, urinary concentration, Addis counts and the urea nitrogen content of the blood were normal. On June 26, a sulfobromophthalein test was done and there was retention of 6 per cent of the dye after 45 minutes. On June 27 the serum bilirubin was 0.1 mg. per 100 cc. at one minute and 0.4 mg. after 30 minutes. The urinary urobilinogen excretion in two hours was 1.6 Ehrlich units (Table 1).

A roentgenogram of the chest showed the heart grossly enlarged as compared with a film taken during the previous hospitalization in February 1953. The transverse diameter now was 159 mm., an increase of 48 mm. (Figure 1). Repeated electrocardiograms were interpreted as normal. Routine stool examinations revealed ova of *ascaris lumbricoides* on several occasions. No occult blood was present.

On admission the patient received a single dose of 0.8 mg. of amodiaquine hydrochloride (Camoquine), and the temperature, pulse and respirations promptly returned to normal. Certain unusual features were apparent: Moderately severe anemia of recent origin without evidence of internal or external hemorrhage, hepatomegaly, cardiomegaly with ankle edema and microscopic hematuria and pyuria. On special investigation of the cardiovascular-renal system no gross abnormality was noted. The venous pressure was 120 mm. of water and the Decholin arm-to-tongue circulation time was 15 seconds. The pulmonary systolic murmur disappeared, the ankle edema subsided, and the liver edge receded by the fifth hospital day. Slowly the hemoglobin content of the blood returned to normal and the heart size decreased (Figure 1 and Table 1). A two-week course of primaquine was given without untoward

From the Department of Medicine, Letterman Army Hospital, San Francisco.

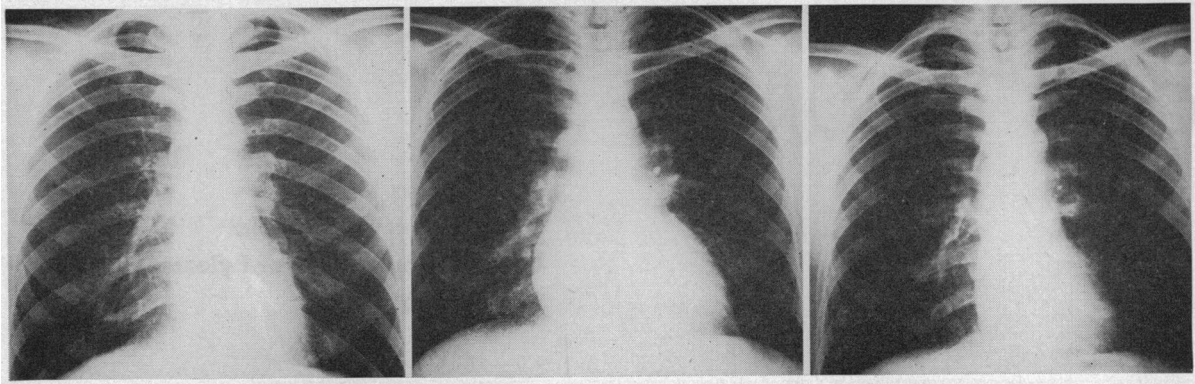


Figure 1.—*Left*, routine x-ray film of chest taken at time patient was hospitalized in February, 1953, for surgical procedure. Transverse diameter was 101 mm. *Center*, taken June 26, 1953, one day after admission to hospital for *P. vivax* malaria. Transverse diameter was 159 mm. *Right*, three weeks later, transverse diameter was 119 mm.

TABLE 1.—Laboratory findings

	April 1953	June 25, 1953	June 30	July 7	July 14	July 21
Hemoglobin (gm.).....	14.9	8.1	9.7	10.7	14.4	14.0
Reticulocytes (per cent).....		6.0	1.8	0.9	0.9	1.0
Cephalin Flocc.						
24 hour.....			3 plus	2 plus	1 plus	1 plus
48 hour.....			4 plus	3 plus	2 plus	1 plus
Thymol turbidity (units).....			14	10	9	7
Serum globulin (gm. per 100 cc.).....			4.2	4.9	4.3	4.2
Serum albumin (gm. per 100 cc.).....			2.0	3.4	3.7	3.5
Urine analysis						
Albumin.....	None	Trace	None	None	None	None
Erythrocytes per high power field.....	0	Numerous	3-4	0	Rare	2-4
Leukocytes per high power field.....	0	Numerous	1-2	0	1-2	2-4
Casts.....	0	0	3-4	0	0	0
			hyaline and granular casts			
Transverse cardiac diameter (mm.).....	101	159	146	130	119	127

reactions. After this, the mild *ascaris lumbricoides* infestation was treated with hexyl resorcinol crystals. The patient returned to his former physical condition and was discharged from the hospital 50 days after admission.

#### DISCUSSION

Despite the fact that all United States military personnel in the Far East receive 0.5 gm. of Chloroquine each week as suppressive antimalarial therapy, plus two weeks of curative therapy with Primaquine (15 mg. per day) en route home via ship, a few cases of *P. vivax* malaria have been seen at various military and civilian hospitals.<sup>4</sup>

The patient in the present case had symptoms of malaise, weakness and the unusual feature of swelling of the ankles for about one week before the onset of classical chills and fever. However, in addition, he had severe anemia, cardiomegaly, hepatomegaly, hypoalbuminemia, albuminuria and abnormal cellular elements in his urine. These abnormalities all abated within a week during which the only medication was a single dose of Camoquine.

The anemia in *P. vivax* malaria is attributed to erythrocyte destruction caused by the malarial parasite and is usually normocytic and normochronic. It

may be owing in part to the toxic inhibition of bone marrow activity, for the reticulocytes which are low during the active phase increase temporarily after the parasites are destroyed by therapy. This inhibitory effect is also suggested by the leukopenia present.<sup>9</sup> The lack of pronounced changes in the serum bilirubin and urinary urobilinogen in the present case would indicate that either the active phase of hemolysis was over by the time the test was done or no hemolysis was present. That there was a marrow inhibitory factor was strongly supported by the finding of an increase in reticulocytes after therapy, and persistent leukopenia. The presence of anemia in patients with *P. vivax* malaria is variable; it occurred in only two out of ten patients with the disease who were observed at the same time as the patient in the present case.

In a review of the literature no previous reports of cardiomegaly in cases of malaria were found. In the present case the anemia may have been the predisposing factor, although Porter and James<sup>7</sup> pointed out that cardiac enlargement is usually seen in chronic anemia but that if present in acute anemia it is a result of the presence of other cardiovascular disease such as hypertension, arteriosclerosis or valvular disease. None of these factors was present in

the present case and there was no evidence of congestive failure.

Ankle edema has been previously noted in *P. vivax* malaria and has been ascribed to the low serum albumin that is often observed.<sup>2</sup> The latter is a result of changes in the reticuloendothelial system, primarily in the liver, which together with the increased globulin account for the abnormalities in results of liver flocculation tests.<sup>6</sup>

Finally, albuminuria, cylindruria and microscopic hematuria and pyuria may be due to the alterations reported pathologically in the renal glomeruli and tubules.<sup>1</sup> These are not common in *P. vivax* malaria and when present are transient, mild and reversible. Renal disease varying from that typical of nephrosis, seen mainly with *P. malariae* malaria, to renal failure secondary to hemoglobinuria due to *P. falciparum* malaria, has also been reported.<sup>3, 8</sup>

#### SUMMARY

An unusual case of *P. vivax* malaria, with anemia, cardiomegaly, ankle edema, hepatomegaly and renal

involvement, has been reported. The mechanisms have been discussed.

2515 South Highland Avenue, Los Angeles.

#### REFERENCES

1. Ash, J. E., and Spitz, S.: Pathology of Tropical Diseases, p. 210, W. B. Saunders, Philadelphia, 1945.
2. Boyd, M. F., and Proske, H. O.: Observations on the blood proteins during malaria infections, *Am. J. Trop. Med.*, 21:245, 1941.
3. Menon, T., and Annamalai, D. R.: Nephrosis in malaria, *J. Trop. Med. and Hyg.*, 36:379, 1933.
4. Hansen, J. E., Cleve, E. A., and Pruitt, F. W.: Relapse of vivax malaria with Primaquine and report of one case of cyanosis (mechemoptobismia) due to Primaquine. To be published, *Am. J. Med. Sci.*
5. Most, H.: Management of vivax malaria in the veteran, *Vet. Admin. Tech. Bul.*, Aug. 4, 1948.
6. Maclagan, N. F.: Flocculation tests: chemical and clinical significance, *Brit. Med. J.*, 2:892, 1948.
7. Porter, N. B., and James, C. W. III: The heart in anemia, *Circulation*, 8:111, 1953.
8. Strong, R. P.: *Stitt's Diagnosis, Prevention and Treatment of Tropical Diseases*, vol. I, pp. 1-136. Blakiston Co., Philadelphia, 1943.
9. Wintrobe, M. M.: *Clinical Hematology*, pp. 569-570. Lea and Febiger, Philadelphia, 1952.

## Falciparum Malaria

### Report of a Fatal Case and Autopsy Findings

EDWARD E. HARNAGEL, M.D., and  
FLORENCE V. RHUDY, M.D., Los Angeles

MALARIA, although considered to be one of "humanity's chief scourges"<sup>2</sup> is an uncommon disease in the civilian populace of California. In Los Angeles County, for example, the median incidence of this disease in a five-year period (1948-1952) was one case per year.<sup>4</sup> In most of these cases the causative organism was plasmodium vivax. Malaria due to *P. falciparum* is rare; in all California only one case in 1953 and only two in 1952 (one of which was listed as "probable") were reported to the Bureau of Acute Communicable Diseases.<sup>7</sup> Moreover, symptomatic responses to falciparum malaria are much less distinctive than those to vivax or quartan infections and frequently offer little help in reaching a presumptive diagnosis. A disease that is rare and without distinctive features presents a formidable diagnostic problem. In the case here presented the disease was successively presumed to be influenza, intestinal obstruction and acute cholecystitis before a correct diagnosis was made on the basis of observation by an alert laboratory technician.

#### REPORT OF A CASE

A 65-year-old woman had fever, lassitude, generalized arthralgia and myalgia of three days' duration. Chilly sensations had been present at the onset, for a few hours only. The patient had returned from a vacation in Mexico only a few days before be-

coming ill. On questioning she said that she had been in a region where malaria is endemic but that rainfall had been unusually light and there had been no mosquitoes about.

The body temperature was 101 degrees F. A provisional diagnosis of influenza was made and symptomatic therapy was prescribed. The patient was not improved the following day, and since she lived alone she was admitted to the hospital for care. The body temperature at the time of admittance was 99.4 degrees F., the pulse rate was 70, respirations were 22 per minute and the blood pressure was 146/88 mm. of mercury. There was slight tenderness in the right upper quadrant of the abdomen and very slight abdominal distention.

On the second hospital day, the patient awoke very nauseated and vomited a small amount of clear fluid containing brownish flecks which by chemical test were found to contain blood. She also complained of severe abdominal pain; and an increase in abdominal distention and some diffuse abdominal tenderness was noted. The body temperature was subnormal most of this day. Because of the many stab cells and diminished number of platelets noted on examination of the blood the day of admittance, the pathologist requested additional specimens (see Appendix A—additional laboratory data). These were taken on the third hospital day but revealed nothing diagnostic. Abdominal pain and distention continued and the patient was not able to retain even liquids by mouth. The possibility of intestinal obstruction was considered. A plain film of the abdomen showed a large amount of gas in the large bowel and also in the right upper quadrant a pyriform shadow of increased density, which was con-